

Clinical study on the treatment of thoracolumbar fractures with single plane screw percutaneous internal fixation

S. CAO, Y.-B. ZHANG, X.-S. TAO, Y. LI, T. XUAN, R.-Z. YU

Department of Spine Surgery, Anhui No. 2 Provincial People's Hospital, Hefei, Anhui Province, China

Abstract. – **OBJECTIVE:** The aim of the study was to investigate the clinical effect of single plane screw percutaneous internal fixation in the treatment of simple thoracolumbar fractures.

PATIENTS AND METHODS: The subjects of this study were 84 patients with simple thoracolumbar fractures treated in our hospital from January 2018 to December 2020. The patients were grouped by different treatment methods (42 cases in each group). The single plane group was treated by percutaneous single plane screw internal fixation and the universal group was treated with percutaneous universal screw. The surgery completion status and the incidence of complications were recorded. The visual analogue scale (VAS) and the Oswestry Disability Index (ODI) of the two groups were recorded before the surgery, 3 days after the surgery, and 7 days after the surgery. The anterior edge height ratio of the fractured vertebra and the kyphotic Cobb angle were marked before the surgery, immediately after the operation, and at the last follow-up.

RESULTS: Difference between groups in surgery time, blood loss and hospital stay was not statistically significant ($p>0.05$); the single plane group had a substantially lower incidence of complications than the universal group ($p<0.05$). At the last follow-up, the single plane group had greatly higher anterior edge height ratio of the injured vertebra than the universal group, while kyphotic Cobb angle was greatly higher in the universal group ($p<0.05$).

CONCLUSIONS: Both single plane screw and universal screw percutaneous internal fixation were feasible for the treatment of simple thoracolumbar fractures, but single plane screw showed better vertebral height recovery and kyphosis correction effect, which could reduce postoperative correction loss.

Key Words:

Single plane screw, Universal screw, Percutaneous internal fixation, Simple thoracolumbar fractures.

Introduction

With the speedy development of the transportation industry, construction industry, etc., there is increasing incidence of thoracolumbar fractures caused by traffic accidents and construction accidents over the past two decades, which seriously affects patients' quality of life. As minimally invasive spine surgery improves by leaps and bounds, more and more doctors and patients choose percutaneous minimally invasive internal fixation for simple thoracolumbar fractures without nerve or spinal cord injury. Universal screw is mostly used¹. However, with the in-depth clinical application, universal screw has poor restoration effect on vertebral height and cannot completely correct the local kyphosis, resulting in gradually prominent postoperative deficiency in delayed kyphosis. In recent years, some scholars² have designed a single plane screw without mobility in the sagittal plane, but the screw tail can swing left and right in the horizontal plane, and there is small difficulty in installing the connecting rod during the surgery. Hence, it achieves good correction effect in the treatment of idiopathic scoliosis. However, there is still a lack of clinical reports on the use of single plane screws for internal fixation of thoracolumbar fractures. Therefore, this study included 84 patients with simple thoracolumbar fractures and made comparison with traditional universal screws to discuss the efficacy and feasibility of single plane screw percutaneous internal fixation in the treatment of simple thoracolumbar fractures. The study is reported as follows.

Patients and Methods

General Data

The subjects of this study were 84 patients with simple thoracolumbar fractures treated in

our hospital from January 2018 to December 2020. The medical records were retrospectively analyzed, and the patients were grouped according to different treatment methods, 42 cases in each group. The universal group was treated by percutaneous universal screw internal fixation and the single plane group was treated by percutaneous single plane screw internal fixation. In the single plane group, there were 22 males and 20 females, aged 36-60 years, with an average age of (43.76 ± 7.78) years; regarding fracture sites, there were 7 cases of T_{11} , 19 cases of T_{12} , 10 cases of L_1 , and 6 cases of L_2 . The universal plane group had 25 males and 17 females, aged 31-57 years, with an average age of (45.45 ± 6.71) years; regarding fracture sites, there were 5 cases of T_{11} , 17 cases of T_{12} , 13 cases of L_1 , and 7 cases of L_2 . Difference in general data between groups was not statistically significant ($p > 0.05$) (Table I).

The study was evaluated and approved by the Medical Ethics Committee of Anhui No. 2 Provincial People's Hospital in terms of compliance with the Helsinki principles (Date: 10.07.2022, Approval No. 2022051). All patients have signed informed consent.

Inclusion and Exclusion Criteria

Inclusion criteria

The inclusion criteria were as follows: (1) Age 18-60 years old; (2) Fracture of a single vertebral body; (3) No nerve or spinal cord injury, injury class E according to American Spinal Injury Association (ASIA); (4) Fracture AO type A³, the spinal canal occupation is less than 1/3, no spinal canal decompression is required; (5) No history of thoracolumbar fracture or surgery; (6) Voluntary cooperation to complete the clinical trial.

Exclusion criteria

The exclusion criteria were as follows: (1) Complicated with a history of thoracolumbar tuberculosis, osteoporosis, degenerative scoliosis, etc.; (2) Complicated with fractures of lower limbs, pelvis and other parts; (3) Complicated with serious diseases in brain, heart, and lungs. (4) Patients with incomplete clinical data.

Method

After general anesthesia, the patient took prone position, and the fractured vertebra was reduced using the hyperextension position of the operating bed. The projection points of the pedicles of the fractured vertebra and the adjacent upper and lower vertebral bodies were observed under fluoroscopy and marked on the body surface, and the puncture point was about 1 cm away from the projection point. The puncture needle was inserted layer by layer percutaneously, and the point where the tip of the needle touched the intersection between the outer edge of the superior articular process and the midline of transverse process was observed under fluoroscopy; this point was selected as the entry point of the vertebral pedicle. The needle was further inserted to the posterior wall of vertebra. The puncture needle should not damage the medial wall of vertebral pedicle, the puncture needle was pushed forward into the vertebral body by about 2cm parallel to the upper endplate. After pulling out the needle core, inserted the guide wire, followed by tapping, depth measurement, and implantation of a single plane screw (Beijing Fuller Technology Co., Ltd.). Totally six single plane screws were inserted *via* the injured vertebra. The connecting rod was appropriately pre-bent in accordance with the compression degree of the fractured vertebra and the size of kyphotic Cobb angle. At the same time,

Table I. Comparison of general clinical data between the two groups (n/%).

Index	Single plane group (n = 42)	Universal group (n = 42)	t/ χ^2	p
Age (years)	43.76 ± 7.78	45.45 ± 6.71	-0.742	> 0.05
Gender				
Male	22	25	0.178	> 0.05
Female	20	17	-	-
Fracture site				
T11	7	5	0.167	> 0.05
T12	19	17	-	-
L1	10	13	-	-
L2	6	7	-	-

the connecting rods on both sides were installed to avoid the cutting of the screw tunnel due to excessive stress concentration. The height recovery of the fractured vertebra and the correction of the kyphosis were observed under fluoroscopy after proper distraction, and the incision was sutured after confirming the good effect (Figure 1). After the surgery, functional exercises such as low back muscle exercises and activities under the protection of braces were gradually performed. The universal group was treated by percutaneous universal screw internal fixation. The procedure was the same as that of the single plane group except that the screws inserted during the surgery were universal screws. Different from universal screw, the inner core part of single plane screw is a symmetrical flat surface, and the screw tail can only swing in a single plane. This unique design can not only facilitate the placement of the rod during the surgery, but also overcome the difficulty that common universal screw has insufficient strength when performing vertebral distraction (Figure 2).

Observation Index

The completion of the surgery and the occurrence of complications were collected; the follow-up was 12-15 months, with a mean of (13.36 ± 1.32) months; the visual analogue scale (VAS)⁴ and the Oswestry Disability Index (ODI)⁵ were recorded for the two groups before surgery, 3 days and 7 days after the operation. The anterior edge height ratio of the fractured vertebrae (Figure 3) and the kyphotic Cobb angle were recorded for the two groups before surgery, immediately after the operation, and at the last follow-up (Figure 4).

Statistical Analysis

Statistical analysis was performed using SPSS 22.00 software (IBM Corp., Armonk, NY, USA), count data were expressed as "n/%", and differences between groups were tested by χ^2 . With insufficient condition for Chi-square test, Fisher's exact test was performed. Measurement data are represented by " $\bar{x} \pm s$ ", independent samples *t*-test was used to compare the means between

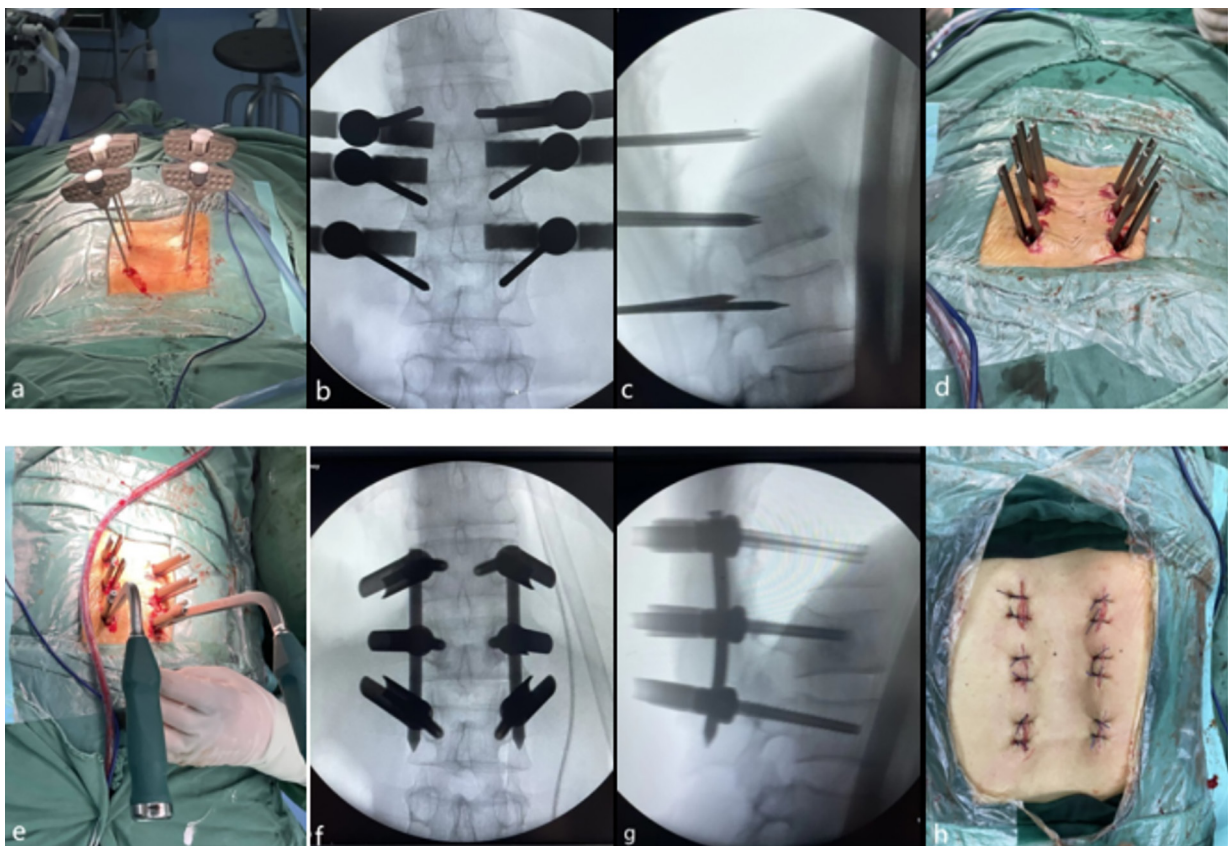


Figure 1. a-c, Percutaneous puncture positioning of the puncture needle, the puncture needle should not damage the medial wall of vertebral pedicle, Process should be observed under fluoroscopy. d, Insert the screw along the guide needle according to the screw tunnel. e-g, Install the connecting rod and spread it moderately, observe the recovery of the fractured vertebra and the correction of kyphosis under fluoroscopy after proper distraction. h, Suture the incision without indwelling the drainage tube.



Figure 2. a-b, Due to its unique flat inner core, when the single plane screw is placed in the vertical coronal plane, the screw tail can only move left and right in the horizontal plane and cannot move up and down in the sagittal plane. c-d, The universal screw has spherical inner core, which can swing in both the sagittal plane and the horizontal plane.

the different groups, and repeated ANOVA was used to compare the indexes at different time points within the group. $p < 0.05$ indicated that the difference was statistically significant.

Results

Comparison of Surgical Completion and Complications Between the Two Groups

The difference between the two groups in blood loss, surgery time and length of hospital stay was not statistically significant ($p > 0.05$); the

single plane group had substantially lower incidence of complications than the universal group ($p < 0.05$), as shown in Table II.

Comparison of Follow-Up Indexes Between the Two Groups

The VAS scores and ODI scores of the two groups at 3 days and 7 days after surgery were greatly lower than those on the preoperative period ($p < 0.05$), and there was no significant difference between groups ($p > 0.05$), as shown in Table III.

Immediately after operation and at the last follow-up, the anterior edge height ratio of the fractured vertebra in both groups was significantly higher than that before surgery, and the kyphotic Cobb angle was significantly lower than that before surgery ($p < 0.05$). Difference in the two indexes between groups was not statistically significant immediately after surgery ($p > 0.05$), but at the last follow-up, the anterior edge height ratio of the fractured vertebra was substantially higher in the single plane group than in the universal group, and the kyphotic Cobb angle was significantly higher in the universal group ($p < 0.05$), as shown in Table IV.

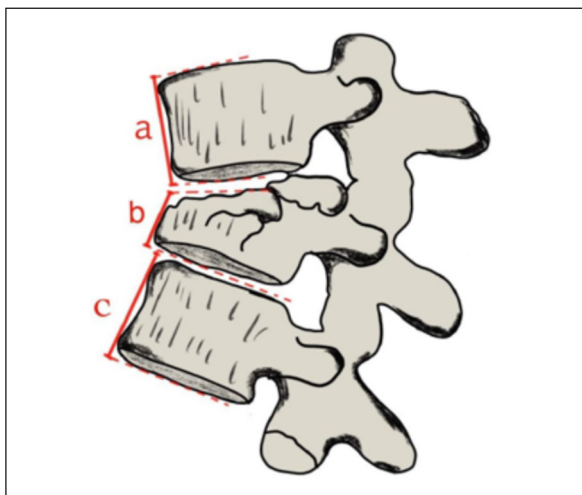


Figure 3. Schematic diagram regarding measurement of the anterior edge height ratio of the injured vertebra. Calculate the anterior edge height of the fractured vertebra (b) and the anterior edge height of the upper and lower vertebrae (a, c). Anterior edge height ratio of injured vertebra = $b / [(a+c)/2] \cdot 100\%$.

Discussion

Thoracolumbar fractures area common disease in spinal surgery and occurs in many people. For the surgical treatment of simple thoracolumbar fractures, pedicle screw internal fixation has always been the gold standard for surgery. However, traditional open surgery has many short-

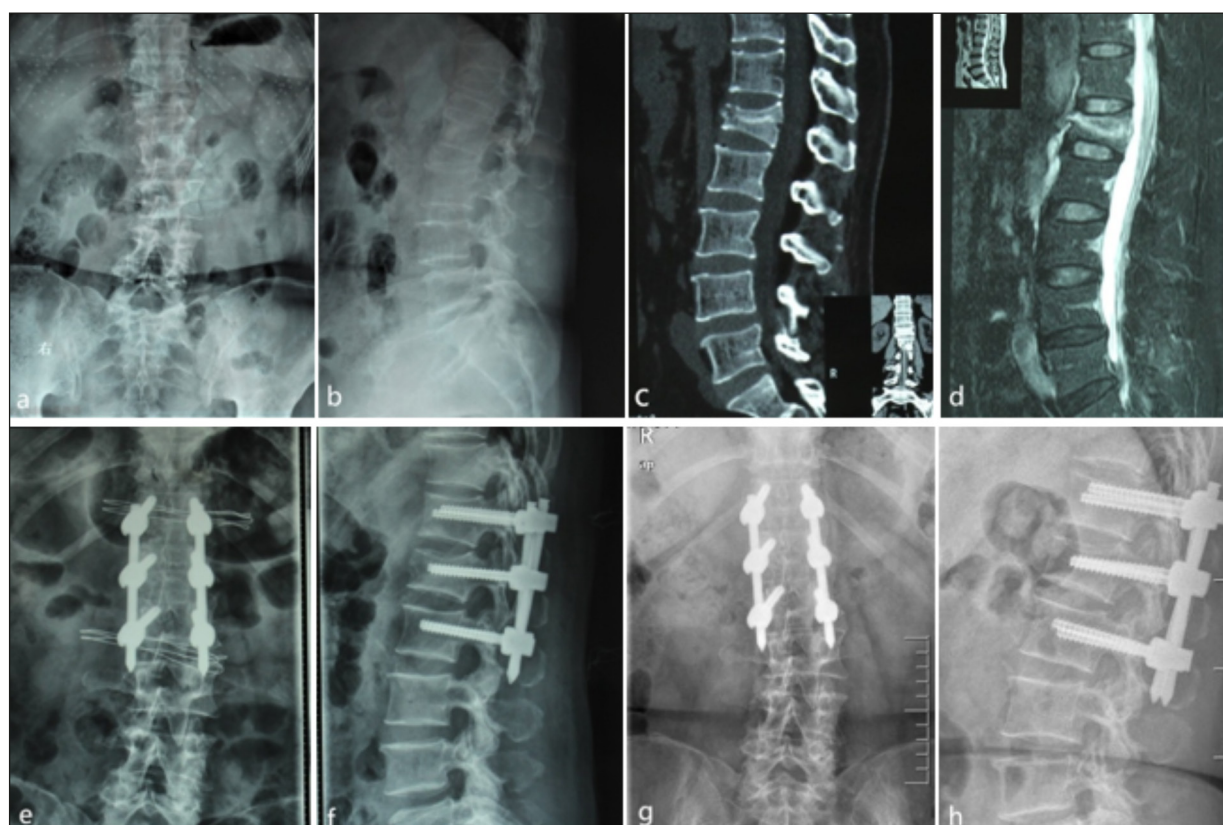


Figure 4. Typical case: A female patient of 55 years old was admitted to the hospital with low back pain and limited movement for 5 hours due to a car accident. The admission diagnosis was L₁ compression fracture, and percutaneous single plane screw internal fixation was performed in our hospital. **a-b**, Preoperative frontal and lateral X-ray films showed L₁ compression fracture and thoracolumbar kyphosis. **c-d**, Preoperative CT and MRI showed that there was no spinal canal bone space occupying and no spinal cord injury. **e-f**, Frontal and lateral X-ray films immediately after surgery show deformity correction and restoration of L₁ vertebral body height. **g-h**, Anterior and lateral X-ray films at the last follow-up showed no remarkable height loss of the injured vertebra.

Table II. Comparison of surgical indexes and complications between the two groups.

Index	Single plane group (n = 42)	Universal group (n = 42)	t/χ ²	p
Surgery time	94.36 ± 7.61	98.12 ± 8.92	-2.781	> 0.05
Blood loss	52.34 ± 8.53	50.96 ± 9.76	1.342	> 0.05
Hospital stay	10.52 ± 1.21	11.34 ± 0.96	-0.453	> 0.05
Pulmonary infection	1	1	-	-
Transient low back pain	1	0	-	-
Correction loss	1	7	-	-
Complication rate	3 (7.14%)	8 (19.04%)	-0.312	< 0.05

Table III. Comparison of VAS and ODI scores between the two groups at different time points.

Index	Single plane group (n = 42)	Universal group (n = 42)	t	p	
VAS	Preoperative	5.28 ± 0.71	5.61 ± 0.53	-1.081	> 0.05
	3 days after surgery	3.17 ± 0.84*	2.83 ± 0.94*	1.103	> 0.05
	7 days after surgery	1.81 ± 0.46*	1.98 ± 0.51*	-0.572	> 0.05
ODI	Before surgery	63.46 ± 2.71	65.31 ± 2.53	-1.412	> 0.05
	3 days after surgery	20.85 ± 2.43*	21.41 ± 2.83*	-0.659	> 0.05
	7 days after surgery	14.32 ± 1.75*	13.28 ± 1.82*	1.870	> 0.05

*p < 0.05 vs. preoperative.

Table IV. Comparison of anterior edge height ratio and kyphotic Cobb angle between the two groups at different time points.

Index		Single plane group (n = 42)	Universal group (n = 42)	t	p
Anterior edge height ratio	Preoperative	57.03 ± 5.01	59.25 ± 4.91	-1.408	> 0.05
	Immediately after surgery	92.72 ± 4.38*	89.57 ± 4.75*	1.630	> 0.05
	Last follow-up	89.21 ± 3.17*	84.36 ± 3.31*	3.219	< 0.05
Kyphotic Cobb angle	Before surgery	17.71 ± 2.43	16.75 ± 2.75	1.191	> 0.05
	Immediately after surgery	4.53 ± 1.48*	5.19 ± 1.68*	-1.271	> 0.05
	Last follow-up	5.24 ± 1.26*	7.15 ± 1.38*	-4.873	< 0.05

* $p < 0.05$ vs. preoperative.

comings: excessive muscle stripping, damage of posterior ligament complex, denervated muscle atrophy, postoperative intractable low back pain, etc^{6,7}. With the rapid development of spinal surgery techniques and the gradual promotion of the concept of minimally invasive surgery, since Magerl first reported⁸ treatment of thoracolumbar fracture with percutaneous pedicle screw system in 1982, percutaneous internal fixation has become one important method for simple thoracolumbar fractures⁹. This procedure has minor damage to soft tissue, faster postoperative recovery, which can significantly reduce the pain associated with low back muscle injury after traditional open surgery^{10,11}. However, the current percutaneous minimally invasive system mainly adopts universal screws. There is a risk of correction loss in the medium and long term, and the biomechanical stability is worse compared to unidirectional screws. How to reduce postoperative correction loss has become an important research direction in treatment of simple thoracolumbar fractures with Percutaneous pedicle screw internal fixation¹². Long-arm singleplane screw fixation in the sagittal plane retains the mobility in the horizontal plane. Therefore, it may have better biomechanical properties than traditional universal screws in the treatment of simple thoracolumbar fractures with percutaneous pedicle screw internal fixation.

The results of this study indicated that difference in surgery time, blood loss and hospital stay between the two groups was not statistically significant ($p > 0.05$). The VAS score, ODI score and kyphotic Cobb angle at different time points were significantly lower after surgery, and the anterior edge height ratio of fractured vertebra was significantly higher after surgery, indicating that single plane screw is practically feasible for the treatment of simple thoracolumbar fractures with percutaneous pedicle screw internal fixation, which

has good deformity correction results while reducing surgical trauma. Immediately after the surgery, difference in the anterior height ratio of the fractured vertebrae and the kyphotic Cobb angle between the two samples was not statistically significant, indicating that the two groups had comparable short-term correction effect after the surgery. This point is different from the conclusion of scholars such as Yang et al¹³. They believed that, due to the characteristics of sagittal plane fixation, single plane screw has a stronger distraction effect on the anterior vertebral column and the anterior longitudinal ligament, which help restore anterior edge height of fractured vertebra and correct kyphosis. The authors agree with his point of view. The reason for the different results is that we attach great importance to the use of the hyperextension position of the bending operating bed to restore the injured vertebra before surgery¹⁴. With moderate intraoperative distraction, orthopedic force is provided without excessive reliance on twisting force of the screw rod. In this way, it is possible to effectively avoid the cutting of the screw tunnel, prevent the loosening of the nail rod or the existence of broken screw and rods in the later stage¹⁵. The loss of vertebral height is a relatively common phenomenon after internal fixation of thoracolumbar fractures. The author believes that the main reason is that the supporting structure of the trabecular bone in the injured vertebra is damaged, which may cause an "eggshell"-like bone defect inside the vertebral body after the shape reduction, resulting in loss of vertebral height. Comparison between groups showed that at the last follow-up, the anterior edge height ratio of the fractured vertebra was greatly higher in the singleplane group than those in the universal group, the kyphotic Cobb angle was substantially higher in the universal group, and there was lower incidence of postoperative correction loss, suggesting that singleplane screw

fixation can better help the recovery and maintenance of injured vertebra height, which reduces the delayed kyphosis and the loss of the injured vertebra height after surgery.

We believe that compared with universal screw and the traditional unidirectional screw, single-plane screw demonstrates the following advantages: (1) The singleplane mobility of the singleplane screw enables it to remain fixed in the sagittal plane. As the unidirectional screw in traditional surgery, it has a strong distraction effect on the anterior longitudinal ligament during reduction, which can better correct kyphosis and restore the injured vertebra height¹⁶. (2) In the design of the singleplane screw, its tail cannot move on the sagittal plane, but can move greatly on the horizontal plane. During percutaneous fixation, it not only retains the advantages of universal screws in easy installation of connecting rods, but also displays internal fixation stability of unidirectional screws¹⁷. (3) By placing screws in injured vertebra, when the single plane screw is installed with connecting rod for correction, the upper endplate of the fractured vertebral body can be raised, the reduction effect of fractured vertebra can be improved, so that the height of the injured vertebra can be maintained. Qiu et al¹⁸ reported that percutaneous singleplane screw pedicle internal fixation for treatment of single-segment thoracolumbar fractures without nerve injury had lower anterior edge height ratio of fractured vertebra and lower loss of Cobb angle than the traditional universal screw at the last follow-up, which is in accordance with the results of this study. However, some scholars¹⁹ believe that, when placing screws in injured vertebra, the choice of universal screw can reduce stress of the screw rod and cutting of the vertebral body through its micro-movement function, thus reducing the risk of internal fixation fracture. Nonetheless, in this study, there were no patients with screw fracture or internal fixation failure until the last follow-up. Whether the placement of singleplane screws in the injured vertebra will reduce local micro-movement and reduce load sharing needs to be further explored through biomechanical tests. Regardless of whether a single plane screw or a universal screw is used, percutaneous fixation needs to pay attention to improving the imaging data in order to achieve ideal puncture and screw placement effect. Before the surgery, the injured vertebra should be reduced using the hyperextension position of the bending operating bed. During surgery, attention should be paid to the accurate placement

of screws and proper prebending of connecting rods, so as to guarantee the distraction, reduction effects and the fixing strength.

Limitations

This study is a clinical retrospective observational study, there may be case selection bias, and the number of cases is limited. Multi-center, prospective, randomized controlled clinical studies are needed in later studies for verification and improvement.

Conclusions

Minimally invasive percutaneous internal fixation with single plane screw can achieve good clinical results in the treatment of thoracolumbar fractures. Compared with traditional universal screws, it can provide a better long-term correction effect and reduce the loss of postoperative correction, which is worthy of extensive promotion in clinical practice.

Conflict of Interest

The Authors declare that they have no conflict of interests.

Acknowledgements

We would like to thank all participants who enrolled in our study.

Informed Consent

A voluntary consent form was obtained from each participant.

Authors' Contribution

S. Cao contributed to study conception and design. X.-S. Tao, Y. Li and T. Xuan collected, analyzed clinical data and wrote the manuscript. Y.-B. Zhang and R.-Z. Yu were involved in submitting and revising the paper. The final version of manuscript was read and approved by all authors.

Ethics Approval

The study was evaluated and approved by the Medical Ethics Committee of Anhui No. 2 Provincial People's Hospital in terms of compliance with the Helsinki principles (Date: 10.07.2022, Approval No. 2022051).

Funding

No fundings.

ORCID IDs

S. Cao: 0000-0003-2709-568X; Y.-B. Zhang: 0000-0003-3551-7440; X.-S. Tao: 0000-0001-5339-6545; Y.-Li. 0000-0002-4488-2741; T. Xuan 0000-0002-4778-5357; R.-Z. Yu: 0000-0001-5506-6400.

References

- 1) Huang WZ. Comparison of unilateral and universal screw percutaneous pedicle internal fixation for thoracolumbar fracture. *J Cervicodynia Lumbodysnia* 2019; 40: 248-250.
- 2) Ma J, Li ZH, Dai J, Lin T, Zhou XH. Apical vertebral derotation by using uniplanar pedicle screw in Lenke 5 adolescent idiopathic scoliosis. *J Spinal Surg* 2018; 16: 327-330.
- 3) Maximilian R, Laurent A, John SK, Carlo B, LiYD, Cumhur OF. AO spine injury classification system: a revision proposal for the thoracic and lumbar spine. *Eur Spine J* 2013; 22: 2184-2201.
- 4) Yuan H, Chang Q, Chen J, Wang YT, GanZJ, Wen S, Li TT, Xiong LL. A retrospective analysis of the effects of different analgesics on the pain of patients with traumatic thoracolumbar fractures in the peri-treatment period. *J OrthopSurg Res* 2021; 16: 268-268.
- 5) Werneke M, Hayes D, Deutscher D. Clinical utility of the Oswestry Disability Index for measuring the function of patients with low back pain. *Spine J* 2018; 18: 712-713.
- 6) Jan K, Martin K, Tomas K, Tomas N. Percutaneous versus open pedicle screw fixation for treatment of type A thoracolumbar fractures. *Eur J Trauma Emerg* 2020; 46: 145-152.
- 7) Gelb D, Ludwig S, Karp JE, Chung EH, Werner C, Kim T, Poelstra K. Successful treatment of thoracolumbar fractures with short-segment pedicle instrumentation. *J Spinal Disord Tech* 2010; 23: 293-301.
- 8) Magerl F. External skeletal fixation of the lower thoracic and lumbar spine in: Unthoff HK, Stahl E. Current concepts of external fixation of fractures. New York; Spring Verlag 1982: 353-366.
- 9) Zhou YJ, MengXJ. Research progress of minimally invasive percutaneous pedicle screw internal fixation for thoracolumbar fractures. *Chin J Trauma* 2016; 32: 464-468.
- 10) Colangeli S, Capanna R, Bandiera S, Ghermandi R, Girolami M, Parchi PD, Pipola V, Sacchetti F, Gasbarrini A. Is minimally-invasive spinal surgery a reliable treatment option in symptomatic spinal metastasis? *Eur Rev Med Pharmacol Sci* 2020; 24: 6526-6532.
- 11) Pishnamaz M, Schemmann U, Herren C, Horst K, Lichte P, Hildebrand F, Pape HC, Kobbe P. Muscular changes after minimally invasive versus open spinal stabilization of thoracolumbar fractures: A literature review. *J Musculoskel Neuron* 2018; 18: 62-70.
- 12) Wang BW, Wu ZX, FengYF, Wang H, Liu SC, Wang FQ, Yang Z, Wang J, Hu XK, Lei W. A retrospective study on pertacuneous and open pedicle screw fixation for traumatic thoracolumbar fractures without neurological deficits. *Chin J Bone Joint Injury* 2017; 32: 1127-1130.
- 13) Fu Y, Li X, Duan LQ, Zhang F, Cai HP, Chen X, Wang XW, Zhang WZ. Evaluation of the therapeutic effect of percutaneous vertebral single plane screw combined with traumatic universal nail in the treatment of thoracolumbar fractures. *J Cervicodynia Lumbodysnia* 2020; 41: 272-276.
- 14) Xie XF, Zheng B, Gu XP, Wang WY. Three-dimensional finite element analysis of hyperextension reduction in the treatment of thoracolumbar compression fractures. *J Traumatic Surg* 2017; 19: 737-740.
- 15) Zhao QP, Zhang HP, Hao DJ, Guo H, Wang B, He BR. Complications of percutaneous pedicle screw fixation in treating thoracolumbar and lumbar fracture. *Medicine* 2018; 97: e11560.
- 16) Kang H, Xu F, Xiong CJ, Xi JT, Wu BY. Clinical research of percutaneous monoplanar screw internal fixation via injured vertebrae for thoracolumbar fracture. *Chin J Repair Reconstruc Surg* 2020; 34: 308-312.
- 17) Eleftherios A, Florian R, Sven K. Maintenance of Integrity of Upper Facet Joints during Simulated Percutaneous Pedicle Screw Insertion Using 2D versus 3D Planning. *J Neurol Surg A Cent Eur Neurosurg* 2019; 80: 269-276.
- 18) Qiu DQ, Zhang WZ, Li X, DuanLQ, He R, Tang K. The efficacy comparison of percutaneous monoaxial screw and open treatment for treatment of thoracolumbar fractures with pedicle screw system. *J ClinOrthop* 2016; 19: 262-265.
- 19) Ming Y, Qin PZ, Ding JH, Zhen C, Shi CL, Xin HY. Comparison of clinical results between novel percutaneous pedicle screw and traditional open pedicle screw fixation for thoracolumbar fractures without neurological deficit. *Int Orthop* 2019; 43: 1749-1754.