

A comparison of computerized tomography and flair-SWI MRI results of patients with head injury attending the emergency department

M.A. DURAK¹, Ş. GÜRBÜZ², S. DERYA³, İ.O. YILDIRIM⁴, M. EKMEKYAPAR³, B. TETİK¹, C. ÇOLAK⁵

¹Department of Neurosurgery, School of Medicine, Inonu University, Malatya, Turkey

²Department of Emergency Medicine, School of Medicine, Inonu University, Malatya, Turkey

³Department of Emergency Medicine, Malatya Education and Research Hospital, Malatya, Turkey

⁴Department of Radiology, School of Medicine, Inonu University, Malatya, Turkey

⁵Department of Biostatistics, School of Medicine, Inonu University, Malatya, Turkey

Abstract. – OBJECTIVE: Detection of traumatic brain injury (TBI) is of vital importance in patients who apply to the emergency department with a history of trauma. The aim of initial imaging in patients with suspected TBI is to detect trauma-related injury quickly and accurately. In this study, the effectiveness of prospectively cranial computed tomography (CT) and fluid attenuation inversion recovery (FLAIR) and susceptibility weighted imaging (SWI) sequence magnetic resonance imaging (MRI) examination results of patients diagnosed with TBI in the emergency department in terms of bleeding detection was investigated in the light of the literature.

PATIENTS AND METHODS: Patients with traumatic brain injury who applied to the emergency department between 2016 and 2020 were included in this prospective study. Cranial CT and MRI images containing SWI-FLAIR sequence were taken on the same day, immediately after cranial CT, for a total of 500 patients.

RESULTS: In our study, TBI was detected in 242 males (70.8%) and 100 females (29.2%), for a total of 342 patients. The mean age was 41.45, the mean GCS was 13.35. There was a history of trauma such as falling in 155 patients (45.3%), traffic accidents in 171 patients (50%), and trauma in 16 patients (4.7%). In the comparative evaluation of CT and FLAIR-SWI MRI examinations no bleeding was detected in the FLAIR-SWI sections of 239 patients who did not have bleeding on CT; however, bleeding was detected in FLAIR-SWI sections in 14 patients who did not have bleeding on CT.

CONCLUSIONS: FLAIR-SWI MR, which is a more reliable examination method, should be performed before control CT, especially in patients with incompatible clinical and admission CT.

Key Words:

SAH, SWI, Emergency, Flair.

Introduction

The imaging-based detection of traumatic brain injury (TBI) is critical for patients who visit the emergency department after traumatic injury. These images enable determination of injury type, potential secondary events, and the treatment methods that may be needed to prevent such events. In patients with head trauma, cranial computed tomography (CT) is the preferred imaging method during the initial evaluation by emergency services, based on its rapid access and extraction time, along with its sensitive detection of acute hemorrhagic lesions that require surgical intervention¹. Many factors, such as the amount of time elapsed since the onset of bleeding, as well as the patient's hemoglobin level, can affect the detection of traumatic subarachnoid hemorrhage (SAH) by CT². Extravasated blood with a hemoglobin concentration of 9-11 g exhibits attenuation similar to the brain³. Therefore, brain parenchyma and bleeding may be difficult to identify in patients with severe anemia or patients with hyperacute bleeding³. Moreover, the sensitivity of CT to bleeding tends to decrease over time^{4,5}. For these situations, fluid attenuation inversion recovery (FLAIR) and susceptibility weighted imaging (SWI) sequence magnetic resonance imaging (MRI) has become increasingly adopted in recent years because of its effective tissue contrast.

FLAIR sequences (in acute hemorrhage) and SWI sequences (in acute, subacute, and chronic hemorrhage) are extremely informative because of their sensitivities to deoxyhemoglobin, hemosiderin, iron, and calcium. Although FLAIR-SWI MRI is a sensitive method for the detection of intracranial hemorrhage in trauma patients^{6,7,8}, difficulties with its interpretation in terms of bleeding have hindered its wider use. Consequently, CT remains routinely used in busy emergency rooms with rapid workflows⁹. In this study, the effectiveness of CT and FLAIR-SWI MRI, in terms of detecting bleeding, were prospectively examined in patients diagnosed with TBI in a single-center emergency department. The results are argued with findings reported in the literature.

Patients and Methods

Patient Selection

Patients with TBI who visited the emergency department in our hospital between 2016 and 2020 were included in this prospective study. Cranial CT immediately followed by MRI containing FLAIR-SWI sequences was performed in 500 patients. Patients were excluded from the study if they had bleeding secondary to diseases such as concomitant tumor, aneurysm, stroke, or arteriovenous malformation. Additionally, 158 patients were excluded because their image quality was strongly affected by motion artifacts. The results of the remaining 342 patients were analyzed. Control CT scans were acquired on the next day in patients who had TBI-related bleeding that did not require urgent surgical intervention and in whom neurological observation was continued.

MRI and CT

All magnetic resonance images in this series were obtained using a 12-channel phased array head coil on a 1.5 T clinical scanner (Avanto-SQ Engine; Siemens Healthcare, Erlangen, Germany). The following FLAIR and SWI sequence parameters were used: repetition time, 48 ms; echo time, 40 ms; flip angle, 20; bandwidth, 80 kHz; section thickness, 2 mm, with 56 sections in a single slab; and matrix size, 512 × 256. An echo time of 40 ms was chosen to avoid phase aliasing, and a flip angle of 20 was used to avoid invalidating signals from pial veins surrounded by cerebral spinal fluid. The acquisition time was 2.58 min and iP-AT factor-2 was used. After post-processing, 9 to 12-mm-thick minimum intensity projection slabs

were generated along the z-axis. CT scans of the brain were performed on a Somatom S16 scanner (Siemens Healthcare). The following scan parameters were used: tube current, 200-220 mA; tube voltage, 120 kV; convolution kernel, H41s; slice thickness, 1.5 mm; and field of view, 220 mm.

Data Evaluation

TBI-related hemorrhages were categorized as subdural, epidural, or subarachnoid. Subdural and epidural hemorrhages were each divided into two regions: supratentorial and infratentorial. Subarachnoid hemorrhage was thoroughly evaluated in accordance with the eight anatomical regions described by Wu et al: frontoparietal, temporo-occipital, interhemispheric fissure, Sylvian fissure, perimesencephalic cisterns, posterior fossa cisterns, superior cerebellar cistern, and intraventricular areas⁶. In total, 12 regions were evaluated.

The data of TBI patients were evaluated by two neuroradiologists with 7 and 20 years of experience. FLAIR-SWI MRI data were evaluated first, followed by CT data. The prominence of bleeding on both image sets was graded by consensus using a 5-point scale: 1, no visible bleeding; 2, minimal visible bleeding; 3, moderate visible bleeding; 4, heavy visible bleeding; and 5, extremely visible bleeding.

Statistical Analysis

Data are expressed as means and standard deviations or frequencies and percentages, depending on the overall variable distribution. Normality was assessed using the Shapiro-Wilk test. Qualitative data were analyzed using the Pearson Chi-Squared test and Fisher's exact test. Groups were compared using independent samples *t*-tests. *p*-values < 0.05 were considered indicative of statistical significance. Statistical analyses were conducted using IBM SPSS version 23.0 for Windows (IBM Corp., Armonk, NY, USA).

Results

In this study, TBI was detected in 242 male (70.8%) and 100 female (29.2%) patients. The mean age of the 342 patients was 41.45 years; the mean Glasgow Coma Score was 13.35. TBI was caused by falls in 155 patients (45.3%), traffic accidents in 171 patients (50%), and other causes in 16 patients (4.7%). A history of anticoagulant use was reported by 22 patients (6.4%). Bleeding

was not detected on the initial entry CT examination of 253 patients (74%); however, SAH was present in 67 patients (19.6%), epidural hematoma was present in 4 patients (1.2%), and subdural hematoma was present in 18 patients (5.3%). Fractures were observed on the CT images of 77 (23%) patients (in 1 patient, fracture could not be clearly evaluated because of technical problems); contusions were present in 5 patients (15.2%). In the FLAIR-SWI MRI evaluation, bleeding was detected in 52 patients (15.2%).

In the control CT performed on the day after trauma, SAH was observed in 32 patients (9.4%), epidural hematoma was observed in 1 patient (0.3%), and subdural hematoma was observed in 8 patients (2.3%). Seventy-five patients (21.9%) were discharged after 24 h of observation, 167 patients (48.8%) were hospitalized and followed up by the daily follow-up service, and 100 patients (29.2%) were hospitalized in the intensive care unit. Eight patients (2.3%) died during follow-up.

Comparative evaluation of CT and FLAIR-SWI MRI revealed the following findings. Among the 253 patients without bleeding on CT, FLAIR-SWI confirmed the absence of bleeding in 239 patients but showed bleeding in 14 patients (Figure 1). Among the 67 patients with SAH on CT, only 24 exhibited SAH on FLAIR-SWI. Among the 4 patients with an epidural hematoma evident on CT, 2 also had an epidural hematoma on FLAIR-SWI. Among the 18 patients with a subdural hematoma evident on CT, 12 also had a subdural hematoma evident on FLAIR-SWI. Among the 290

patients without evidence of contusions on CT, 263 also showed no contusions on FLAIR-SWI. Contusions were present in the CT images of 27 patients, but they were confirmed by FLAIR-SWI in only 25 patients.

After 24 h of follow-up, 282 patients did not have bleeding on control CT but 18 additional patients had SAH on FLAIR-SWI. On the follow-up control CT, 6 patients had SAH; FLAIR-SWI showed SAH in 26 patients. Although no additional epidural hematoma was detected on the control CT scans, it was observed in 1 patient on FLAIR-SWI. Subdural hematoma was detected in 1 patient on the control CT and in 7 patients on FLAIR-SWI.

Discussion

Head trauma is observed in most patients who visit the emergency department after experiencing physical trauma. Some of these patients have isolated head trauma, whereas others have polytrauma^{10,11}. Patients with head trauma, that includes TBI, may develop various deficiencies (e.g., cognitive, mental, sensory, and motor) that have lifelong adverse effects on patients and their family¹². TBI is caused by external mechanical forces and may be direct or indirect. It is often accompanied by partial or full loss of consciousness^{13,14}. CT is the diagnostic method of choice for the initial evaluation of acute head trauma because it is rapid, widely available, and able to detect skull frac-

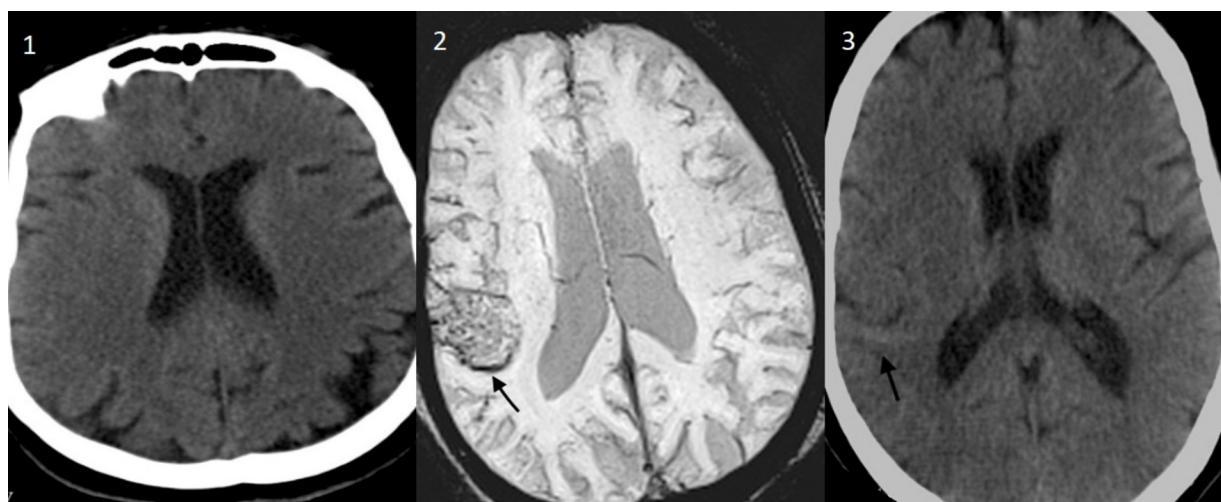


Figure 1. 1, No SAH in the cranial tomography taken at admission. 2, Traumatic SAH appearance in the posteriolateral aspect of the right lateral ventricle in the SWI sequence image of the patient (arrow). 3, SAH image detected in the control tomography taken 24 hours later.

tures and acute intracranial hemorrhage with high sensitivity. When extensive evidence of injury is detected on an admission CT scan, or if the clinical picture does not match the radiological image, follow-up scans should be performed; in one of every six patients, evidence of hemorrhage is first detected on the control CT¹⁴. For this reason, all patients in our study underwent a follow-up CT control after 24 h. MRI is recommended for patients with acute TBI when their neurological findings cannot be explained by CT scan results. MRI is also the modality of choice for the evaluation of patients with subacute or chronic TBI. However, mild TBI remains difficult to diagnose with current imaging technology^{15,16}. Factors that affect the radiological detection of traumatic SAH include the time elapsed from bleeding onset and the hemoglobin level¹⁷. Because extravasated blood with a hemoglobin concentration of 9-11 g has attenuation similar to the brain, brain parenchyma and hemorrhage may be difficult to differentiate on admission CT images of patients with severe anemia or patients with hyperacute hemorrhage¹⁷. Moreover, the sensitivity of CT for detecting bleeding tends to decrease over time; FLAIR and SWI MRI can effectively demonstrate tissue contrast and are thus increasingly used for the detection of intracranial hemorrhage¹⁸⁻²¹. FLAIR sequences are informative in the acute, subacute, and chronic stages of bleeding, whereas the sensitivity of SWI sequences originates from their detection of deoxyhemoglobin, hemosiderin, iron, and calcium. In this study, CT and MRI with simultaneous FLAIR-SWI sequences were performed on admission, and CT examinations were performed during follow-up, for 500 patients with TBI; of these patients, 342 had data with sufficient quality for evaluation. Within this group, SAH was identified on the initial entry CT examination in 67 patients (19.6%); epidural hematoma was identified in 4 patients (1.2%), and subdural hematoma was identified in 18 patients (5.3%). In the FLAIR-SWI MRI evaluation, bleeding was found in 52 patients (15.2%). In the comparative evaluation of CT and FLAIR-SWI MRI, the FLAIR-SWI MRI findings confirmed the absence of bleeding in 239 of the 253 patients who did not have bleeding on CT; bleeding was detected in the remaining 14 patients. SAH was detected in the FLAIR-SWI sequences in only 24 of the 67 patients who exhibited SAH on CT. Only 2 of the 4 patients diagnosed with epidural hematoma on CT exhibited hematoma on FLAIR-SWI MRI. Subdural hematoma was confirmed by FLAIR-

SWI in 12 of the 18 patients who exhibited subdural hematoma on CT. Among the 290 patients without evidence of contusions on CT, FLAIR-SWI confirmed this finding in 263 patients; however, contusions were identified by FLAIR-SWI in 27 patients. Of the 27 patients with contusions on CT, contusions were evident on FLAIR-SWI in 25. After 24 h of follow-up, 282 patients did not have bleeding on the control CT, but 18 additional patients had SAH on FLAIR-SWI. Six patients had SAH on the control CT, compared with 26 patients who had SAH on FLAIR-SWI. No additional epidural hematoma was detected on the control CT, but it was observed in 1 patient on FLAIR-SWI MRI. Subdural hematoma was detected in 1 patient on the control CT and in 7 patients on FLAIR-SWI. These results indicate that FLAIR-SWI MRI provides more detailed and reliable information in patients with SAH and cerebral contusions, consistent with previous reports.

Limitations

This study also had several limitations. First, we did not compare the FLAIR-SWI images of SAH patients with FLAIR-SWI images of healthy controls. Second, there was no external standard to determine which of the two methods provided accurate findings. However, CT is generally regarded as the standard because it is used to identify patients with SAH and to validate the results of SWI.

Conclusions

The results of this prospective single-center epidemiological study are consistent with previous findings that FLAIR-SWI MRI examinations are effective for identifying traumatic SAH and cerebral contusions, even if neither is detected on CT. As a more reliable examination method, FLAIR-SWI MRI should be performed before control CT, particularly for patients with incompatible clinical and admission CT findings.

Conflict of Interest

The authors of this article do not declare any relationship with any company whose products or services may be related to the subject of the article.

Ethics Approval

The study was approved by the Inonu University Ethics Committee (No.: 2014/154).

Informed Consent

All patients were informed that they participated in the study and an informed consent form was signed.

References

- 1) Newberg AB, Alavi A. Neuroimaging in patients with head injury. *Semin Nucl Med* 2003; 33: 136-147.
- 2) van Gijn J, Kerr RS, Rinkel GJ. Subarachnoid haemorrhage. *Lancet* 2007; 369: 306 -318.
- 3) New PF, Aronow S. Attenuation measurements of whole blood and blood fractions in computed tomography. *Radiology* 1976; 121: 635-640.
- 4) Smith WP Jr, Batnitzky S, Rengachary SS. Acute isodense subdural hematomas: a problem in anemic patients. *AJR Am J Roentgenol* 1981; 136: 543-546.
- 5) Sames TA, Storrow AB, Finkelstein JA, Magoon MR. Sensitivity of new generation computed tomography in subarachnoid hemorrhage. *Acad Emerg Med* 1996; 3: 16 -20.
- 6) Wu Z, Li S, Lei J, An D, Haacke EM. Evaluation of traumatic subarachnoid hemorrhage using susceptibility-weighted imaging. *American Journal of Neuroradiology* 2010; 31: 1302-1310.
- 7) Verma RK, Kottke R, Andereggen L, Weisstanner C, Zubler C, Gralla J, Kiefer C, Slotboom J, Wiest R, Schroth G, Ozdoba C, El-Koussy M. Detecting subarachnoid hemorrhage: comparison of combined FLAIR/SWI versus CT. *Eur J Radiol* 2013; 82: 1539-1545.
- 8) S. Neri, M. Ascoli, E. Africa, P. Versace, A. Porcelli, A. Armentano, D. Santangelo, A. Pascarella, L. Manzo, C. Lobianco, G. Mastroianni, V. Cianci, S. Gasparini, U. Aguglia, E. Ferlazzo The relevance of MRI blood-sensitive sequences in the diagnostic assessment of late-onset epilepsy. *Eur Rev Med Pharmacol Sci* 2022; 26: 1178-1182.
- 9) Morales H. Pitfalls in the Imaging Interpretation of Intracranial Hemorrhage. *Semin Ultrasound CT MR* 2018; 39: 457-468.
- 10) Endo H, Fujimura M, Tominaga T. Subarachnoid Hemorrhage. *No Shinkei Geka* 2021; 49: 220-228.
- 11) Kraus JF, McArthur DL. Epidemiologic aspects of brain injury. *Neurologic Clinics* 1996; 14: 435-450.
- 12) Rutland-Brown W, Langlois JA, Thomas KE, Xi YL. Incidence of traumatic brain injury in the United States, 2003. *J Head Trauma Rehabil* 2006; 21: 544-548.
- 13) Tintinalli JE, Kelen GD, Stapczynski JS. *Emergency medicine: a comprehensive study guide*. 6th ed. New York: McGraw-Hill, Medical Pub. Division 2004.
- 14) Anderson T, Heitger M, Macleod AD. Concussion and mild head injury. *Practical Neurology* 2006; 6: 342-357.
- 15) Servadei F, Murray GD, Penny K, Teasdale GM, Dearden M, Iannotti F, Lapierre F, Maas AJ, Karimi A, Ohman J, Persson L, Stocchetti N, Trojanowski T, Unterberg A. The value of the "worst" computed tomographic scan in clinical studies of moderate and severe head injury. *European Brain Injury Consortium. Neurosurgery* 2000; 46: 70-77.
- 16) Smith LGF, Milliron E, Ho ML, Hu HH, Rusin J, Leonard J, Sribnick EA. Advanced neuroimaging in traumatic brain injury: an overview. *Neurosurg Focus* 2019; 1: 47: E17.
- 17) Endo H, Fujimura M, Tominaga T. [Subarachnoid Hemorrhage]. *No Shinkei Geka* 2021; 49: 220-228.
- 18) McKinney AM, Sarikaya B, Gustafson C, Truwit CL. Detection of microhemorrhage in posterior reversible encephalopathy syndrome using susceptibility-weighted imaging. *AJNR* 2012; 33: 896-903.
- 19) Shao L, Wang M, Ge XH, Huang HD, Gao L, Qin JC. The use of susceptibility-weighted imaging to detect cerebral microbleeds after lacunar infarction. *Eur Rev Med Pharmacol Sci* 2017; 21: 3105-3112.
- 20) Miki T, Ikeda Y, Utsugi O, Ito H. Evaluation of traumatic subarachnoid haemorrhage on computed tomography. *J Clin Neurosci* 1998; 5: 49-57.
- 21) Yuan MK, Lai PH, Chen JY, Hsu SS, Liang HL, Yeh LR, Chen CK, Wu MT, Pan HB, Yang CF. Detection of subarachnoid hemorrhage at acute and subacute/chronic stages: comparison of four magnetic resonance imaging pulse sequences and computed tomography. *J Chin Med Assoc* 2005; 68: 131-137.