

Carvacrol mitigates vancomycin-induced nephrotoxicity *via* regulation of I κ B α /p38MAPK and Keap1/Nrf2 signaling pathways: an experimental study with *in silico* evidence

M.M. KHALAF¹, S.M. HASSAN², A.M. SAYED³, A.M. ABO-YOUSSEF¹

¹Pharmacology and Toxicology Department, Faculty of Pharmacy, Beni-Suef University, Beni-Suef, Egypt

²Pharmacology and Toxicology Department, Faculty of Pharmacy, Fayoum University, Fayoum, Egypt

³Biochemistry Laboratory, Chemistry Department, Faculty of Science, Assiut University, Assiut, Egypt

Abstract. – OBJECTIVE: Despite its evident renal toxicity, vancomycin is considered an effective glycopeptide antibiotic against life-threatening positive bacterial contagions. The current study aimed to investigate the potential protective effects of carvacrol as well as its underlying mechanism against vancomycin-induced nephrotoxicity.

MATERIALS AND METHODS: The animals were randomly classified into four groups (8 rats per group). Group I, which served as a control group, received only vehicles. Group II received a single i.p. injection of 50 mg/kg of carvacrol for seven days. Group III received vancomycin (200 mg/kg, i.p.) as a singular daily dose for seven days. Carvacrol was administered to Group IV seven days prior to the daily vancomycin dose.

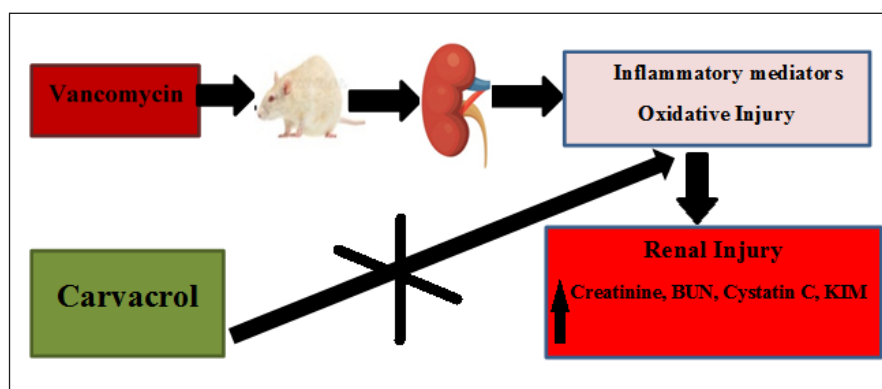
RESULTS: The results revealed that carvacrol minimized vancomycin-induced renal injury as evidenced by lower serum cystatin C levels and kidney injury molecule-1 (KIM-1), in addition to a decline in renal damage caused by vancomycin as indicated in histopathological assessment. Furthermore, carvacrol significantly attenuat-

ed oxidative stress parameters and inflammatory mediators. Moreover, it downregulated Keap1, mitogen-activated protein kinase (p38MAPK), and nuclear factor kappa B (NF- κ B) genes and proteins, along with controlling the NF- κ B inhibitory protein (I κ B α) and nuclear factor erythroid 2-related factor 2 (Nrf2) genes and proteins observed through streamlining its genes. A molecular docking technique was also used to investigate the potential interactivity between carvacrol and proteins involved in regulating oxidative injury and inflammatory responses.

CONCLUSIONS: The current study findings revealed that carvacrol administration before vancomycin could be a promising therapeutic approach for maceration of renal damage stimulated by vancomycin via controlling I κ B α /MAPK and Keap1/Nrf2 signaling molecules.

Key Words:

Nephrotoxicity, Carvacrol, Vancomycin, MAPK, I κ B α , Keap1.



Graphical Abstract. Carvacrol ameliorated vancomycin-induced renal injury by regulation of GSH, HO-1, Nrf2 and reduction of MDA, iNOS, Keap1. Carvacrol prompts its anti-inflammatory status through streamlining both I κ B α /p65 NF- κ B and Nrf2/HO-1 signaling pathways.

Abbreviations

GFR: glomerular filtration rate, GSH: reduced glutathione, HO-1: heme oxygenase-1, IL-1 β : interleukin 1 β , iNOS: inducible nitric oxide synthase, I κ B α : nuclear factor kappa B light polypeptide gene enhancer in B-cells inhibitor alpha, ROS: reactive oxygen species, Keap1: Kelch-like ECH Associated Protein1, MDA: malondialdehyde, NF- κ B: nuclear factor kappa B, NGAL: neutrophil gelatinase-associated lipocalin, Nrf2:(erythroid-derived-2) like 2, p38 MAPK: mitogen-activated protein kinase.

Introduction

Vancomycin is one of the most commonly utilized tricyclic glycopeptide antibiotics in hospital infections, sepsis, pneumonia cases, and soft tissue abscesses¹. Interestingly, it is a unique glycopeptide that is prescribed for patients hypersensitive to penicillin and cephalosporin. It acts by inhibiting bacterial peptidoglycan biosynthesis, thus preventing the second stage of cell wall synthesis of the anaerobic and aerobic pathogenic cocci^{2,3}. Hypersensitivity, fever, phlebitis, hypotension, tachycardia, lacrimation, and thrombocytopenia are the most prevalent side effects of vancomycin³.

The most common side effect of vancomycin is nephrotoxicity, which limits its effectiveness, dosage, and duration of treatment⁴. Cystatin C, which is almost entirely reabsorbed by tubular epithelial cells and is highly sensitive to changes in glomerular filtration rate, is one of the most sensitive indicators of glomerular filtration rate (GFR)⁵. Likewise, kidney injury molecule-1 (KIM-1) expression was significantly elevated in kidney injury, playing a vital role in macrophage and cytokine activation *via* the mitogen-activated protein kinase (MAPK) pathway⁶.

The mechanisms of vancomycin-induced kidney injury are complicated and multifactorial, with the major pathways including renal oxidative stress, apoptosis, and inflammation⁷. Under normal conditions, oxidants and antioxidants are in balance within the cell. Cellular stress disrupts mitochondrial activity with increased production and reactive oxygen species (ROS) aggregation, followed by corrosion of cell membrane lipid components, denaturation of proteins, and enzymatic inactivation^{8,9}.

Nuclear factor erythroid 2-related factor 2 (Nrf2) is an influential regulator of cellular oxidative strain and inflammation, and it plays an integrative role in inducing the expression of genes encoding enzymes involved in antioxidant production and

the reduction in pro-oxidants, such as heme oxygenase-1 (HO-1) that represents an essential effect in the protective impacts of oxidative and apoptotic damages¹⁰. Aside from apparent vancomycin cell poisoning, the prominence of inflammatory signs in the emergence of vancomycin nephrotoxicity is gradually achieved. Immunoregulatory cytokines play a substantial role in several inflammatory and contagious morbidities, and their stimulation highly depends on ROS¹¹.

Nuclear factor-kappa B (NF- κ B) is a ubiquitous transcriptional factor induced by numerous stimuli leading to catalyzing of assorted gene series implicated in immune, inflammatory, and cell propagation behaviors^{12,13}. It stimulates the expression of inducible nitric acid synthase (iNOS) that affects protein-encoding manipulated in the inflammatory controlling and cell defense mechanisms¹⁴. Mitogen-activated protein kinase is invigorated by cytokines and cellular tension, leading to the production of inflammatory signaling molecules, including (IL-1 β) and neutrophil gelatinase-associated lipocalin (NGAL), which is considered a precursor protein of inflammatory conditions¹⁵⁻¹⁷.

Carvacrol (2-methyl-5-(1-methylethyl)-phenol) is a prevalent phenolic monoterpene derivative found in aromatic plants of the family *Labiatae* involving *Satureja*, *Thymbra*, *Origanum*, *Thymus*, *pepperwort* and *Coridothymus* species¹⁸. It revealed numerous biological and pharmacological activities, including antioxidant¹⁹, anti-inflammatory²⁰, anticancer²¹, antimicrobial²², anxiolytic, anti-depressant²³ and hepatoprotective effects²⁴. Similarly, carvacrol is utilized in the recent production of dosage forms for anti-aging, beauty supplements, and health beverages, conserving the nervous system and cardiovascular care²⁵.

Although carvacrol has been shown to have a variety of physiological activities, its relationship to nephroprotection or the reduction of renal injury has never been investigated. Subsequently, the main objective of the current work was to investigate the potential nephroprotective effects of carvacrol against vancomycin-induced nephrotoxicity in rats, as well as the prospective underlying mechanisms.

Materials and Methods

Experimental Animals

Male Wistar rats with an average weight (200-210 g) were obtained from the National Research Center, Cairo, Egypt. Animals were housed in

clean plastic cages in a standard laboratory facility with free access to food and water. In addition, they were left seven days before the onset of the experiments to acclimate.

Drugs and Chemicals

Vancomycin was purchased from Mylan (Saint-Priest, Lyon, France), whereas carvacrol, DMSO, and buffered formalin were purchased from Sigma Aldrich (St. Louis, MO, USA). Creatinine and BUN serum kits were obtained from BioAssay Systems, (Corporate Place, Hayward, USA) (DICT014, DIUR021). Serum Cystatin C and HO-1 kits were purchased from Enzo Life Sciences, (Butler Pike, Plymouth Meeting, PA, USA) (CSB-E08385r, ADI-EKS-810A). Reduced glutathione (GSH) kit (E02G0367) was purchased from Shang Hai Blue Gene Biotech Co., (Songjiang District, Shanghai, China). The lipid peroxidation kit (STA-832) was purchased from Cell Bio-labs Inc., (Arjons Dr, San Diego, CA, USA). Interleukin-1 β , NGAL, and iNOS kits (CSB-E08055r, CSB-E09409r, CSB-E08325r), respectively, were obtained from Cusabio Technology (Fannin St, Houston, TX, USA). An NF- κ B kit (MBS722386) was obtained from BioSource, (Dorval, QC H9S 5J9, Canada). The PCR primers for NF- κ B, I κ B α , Nrf2, keap1, and HO-1 were purchased from Qiagen RNeasy, (Qiagen Str., Hilden, Germany) (205311). RNA extraction and cDNA synthesis kits, antibodies of p65 NF- κ B, I κ B α , MAPK, Nrf2, and HO-1, were obtained Bio Basic Inc., (Konrad Crescent, Markham, Canada).

Experimental Design

The animals were randomly allocated into four groups (8 rats per group), and the experimental design was constructed as follows: Group I received only vehicles and served as a normal control group. Group II was injected with 50 mg/kg carvacrol in a single i.p. dose for seven consecutive days. Carvacrol was dissolved in 5% DMSO and administered to animals at 50 mg/kg, i.p., for seven successive days²⁶. Vancomycin (200 mg/kg, i.p) was given to Group III as a singular daily dose for seven successive days²¹. Group IV received a daily dose of carvacrol for seven days before the vancomycin²¹.

Blood Sample Collection and Kidney Tissue Pretreatment

When the experimental course was terminated, blood samples were collected after fasting

for 12h by the retro-orbital sampling and then centrifuged at 1.957 xg for 10 min. The clear separated serum used for the assessment of creatinine, blood urea nitrogen (BUN), cystatin C, kidney injury molecule-1 (KIM-1), reduced glutathione (GSH), malondialdehyde (MDA), heme oxygenase-1 (HO-1), inducible nitric oxide synthase (iNOS), interleukin 1 β (IL-1 β), neutrophil gelatinase-associated lipocalin (NGAL) and nuclear factor-kappa B (NF- κ B).

Subsequently, animals were euthanized, and the kidney tissues were enucleated and blotted between two filter sheets after being soaked in ice-cold saline. One part of the tissues was soaked in 10% neutral buffered formalin for histopathological and immunohistochemical evaluations of iNOS, P38MAPK, and NF- κ B, whereas the other part of the renal specimen was used for molecular biomarkers using quantitative real-time polymerase chain reaction (qRT-PCR) and western blotting including Keap1, Nrf2, HO-1, I κ B, NF- κ B, and MAPK.

Evaluation of biomarkers for renal performance

Creatinine and blood urea nitrogen levels in serum were evaluated using a commercially available colorimetric kit from BioAssay Systems (USA)^{27,28}. Both levels were measured using the same unit mg/dL. In addition, serum cystatin C level was evaluated using quantitative sandwich commercially available enzyme-linked immunosorbent assay (ELISA) Enzo Life Sciences kit²⁹. Values were expressed as ng/mL. Furthermore, the serum level of KIM-1 was determined using the Cusabio Technology ELISA kit (USA)³⁰, and values were expressed as ng/mL.

Assessment of serum oxidative overwork biomarkers (GSH, MDA, and HO-1)

Serum glutathione was assessed using the commercially available ELISA kit (Shang Hai Blue Gene Biotech Co. China)³¹. GSH levels were calculated as nmol/mL. Malondialdehyde level was measured colorimetrically (Cell Bio-labs Inc. USA) as lipid peroxidation indicator in serum and as nmol/mL³². Furthermore, the Enzo Life Sciences ELISA kit (UK) allows for detecting and quantifying serum HO-1 level³³. Values were expressed as ng/mL. Additionally, serum iNOS level was evaluated by Cusabio Technology kit (USA) using quantitative sandwich enzyme immunoassay technique³⁴. Serum synthase levels were evaluated as IU/mL.

Assessment of serum level of inflammatory cytokines

The levels of proinflammatory cytokines, interleukin (IL-1 β), and neutrophil gelatinase-associated lipocalin (NGAL) were determined in serum samples using commercially available Cusabio Technology ELISA kits^{35,36}. Both levels were measured as pg/mL and ng/mL, respectively. Furthermore, Serum nuclear factor-kappa B (NF- κ B) activity was determined in serum using a commercially available sandwich ELISA kit obtained from My BioSource.com (Canada) and estimated as pg/mL³⁷.

Histopathological assessment of kidney tissue

Autopsy samples were rinsed with distilled water after being removed from a 10% formalin solution. Renal specimens were then dehydrated by exposing them to increased alcohol concentrations. Then, the dehydrated renal sections were fixed in xylene, embedded in paraffin, then sliced into 4 μ m-thick slices. The obtained tissue slices were deparaffinized and stained with hematoxylin and eosin for investigation with the light electronic microscope. A blinded histopathologist examined all sections for distinctive histopathological modifications³⁸. Histopathological lesions were scored as follows: normal appearance (-), mild (+), moderate (++) , and severe (+++) (Table I).

Investigation of renal iNOS, MAPK, and NF- κ B

Kidney segments from various groups were plated at 70°C overnight before being de-waxed in xylene. Endogenous peroxidase activity was restricted by culturing renal sections in a 3% H₂O₂

solution for 15 min then treated with 2% trypsin with buffer solution and washed with PBS. Renal sections were incubated in a solution of 3% H₂O₂ for 15 min to inhibit endogenous peroxidase activity. In these sections, primary antibodies against iNOS, p38 MAPK, and p65 NF-B were incubated overnight at 4°C. After being rinsed in PBS, all tubes were preserved in a secondary antibody. Afterward, hematoxylin is used to counterstain all segments and analyzed under a light microscope³⁹.

qRT-PCR investigation of renal NF- κ B, IKB, Nrf2, Keap1, and HO-1 mRNA transcription

Total RNA was isolated using a Qiagen RNeasy Mini Kit (Hilden, Germany), and qRT-PCR was used to assess the effect of carvacrol on the vancomycin-stimulated alteration of gene transcription profiles of NF- κ B, IKB, Nrf2, Keap1, and HO-1 in rat renal tissue, using β -actin as the standard gene⁴⁰ (Table II). The heated samples underwent denaturation for 15 min at 95°C and 1 min of annealing at 54-58 °C for 45 cycles. Melting analysis was performed starting at 60°C up to 90°C with a gradual increase in temperature by 0.5 °C every 10 min for nonspecific product screening. Finally, the relative mRNA expression of target genes was estimated by normalization to the control group and β -actin level⁴¹.

Detection of NF- κ B, IKB, MAPK, Nrf-2, and HO-1 protein levels in renal samples using Western blotting

After removing kidney tissue from -80°C and homogenizing it in a Radio-immunoprecipitation assay (RIPA) lysis buffer (Bio Basic Inc., Canada), BCA determined total protein concentrations.

Table I. Injury and lesion index for kidney histopathological features.

Pathological features	Lesion scores			
	Normal	Carvacrol (50mg/kg)	Vancomycin (200mg/kg)	Vancomycin + Carvacrol
Vacuoles formation	-	-	+++	++
Renal deterioration	-	-	+++	++
Cell shedding	-	-	+++	++
Cortical plugging	-	-	+++	+
Cells oozing	-	-	+++	+

Where (-) there is no alteration, (+) there is a slight alteration, (++) there is a considerable alteration, and (+++) there is a substantial alteration.

Table II. Primer sequence for mRNA expression qRT-PCR.

Target Gene	Sequence
NF-KB p65	F: 5-TCCCCAAGCCAGCACCCCAGC-3 R: 3-GGCCCCCAAGTCTTCATCAGC-5
IKB- α	F: 5-GACGAGGATTACGAGCAGAT-3 R: 3-CCTGGTAGGTTACTCTGTTG-5
Nrf2	F: 5-TTGTAGATGACCATGAGTCGC-3 R: 3-TGTCCTGCTGTATGCTGCTT-5
Keap1	F: 5-TGCCCTGTGGTCAAAGTG-3 R: 3-GGTCGGTTACCGTCCTGC-5
HO-1	F: 5-GTAATGCAGTGTGGCCCC-3 R: 3-ATGTCCAGGCATCTCCTTC-5
β -actin	F: 5-TGCTGTCCTGTATGCCTCT-3 R: 3-TTTGATGTACGCACGATT-5

The protein sample was isolated using sodium dodecyl sulphate polyacrylamide gel electrophoresis and then transferred to a nitrocellulose membrane. Subsequently, tissues were treated for 1h with a 5% buffered saline tween, and the cells were then incubated at 4°C overnight with primary antibodies against p65 NF- κ B, I κ B, MAPK, Nrf2, HO-1, and β -actin (1: 3000). At room temperature, HRP-conjugated secondary antibodies (1: 5000) were implemented to determine the primary antibodies, and the intensity of protein bands was assessed using a computerized densitometer⁴².

Docking estimation at the molecular level

The docking investigations and assessment of carvacrol binding affinities with HO-1, Keap1, NF- κ B, and p38MAPK were carried out using the Autodock vina 1.5.6 software⁴³. The crystal structures of HO-1 with its inhibitor (PDB ID: 3HOK), Keap1 with its inhibitor (PDB ID:4L7B), and NF- κ B (PDB ID: 1VKX), as well as p38MAPK with its inhibitor (PDB ID: 3ZS5), were retrieved from Protein Data Bank. Based on prior relevant studies, the interaction residues of the active site for each protein involved in docking experiments were discovered. The polar hydrogens were introduced to the crystalline structure after all the water molecules and ligands were eliminated, and the pdbqt templates were formed appropriately⁴⁴⁻⁴⁷. The lowest energy docking average energy docking was used to predict the binding affinities of carvacrol with the target protein. The best-scored conformation was analyzed and visualized using Chimera 1.12 software.

Statistical Analysis

All the data was graphed as mean \pm SD. The one-way analysis of variance was used to deter-

mine whether there was a significant difference in group means, along with the Tukey-Kramer test. The statistical package for social sciences (SPSS) computer program was used to stratify the statistical analysis and visualize findings (version 22 - IBM Corp., Armonk, NY, USA). The level of statistical significance was set at a p -value < 0.05.

Results

Carvacrol Treatment Ameliorated Kidney Function Tests in Vancomycin-Induced Nephrotoxicity

The effect of carvacrol on vancomycin-induced renal impairment is illustrated in (Table III). Vancomycin induced a significant elevation in renal bio-signs recognized by a substantial increase in serum creatinine and blood urea nitrogen (BUN) levels. This increase in renal parameters confirmed the induction of nephrotoxicity in the vancomycin group. However, the administration of carvacrol markedly prevented the vancomycin-induced increase in serum creatinine and BUN levels. Additionally, vancomycin-treated rats caused a significant elevation in serum cystatin C level, matching with the normal control group signaling lowering glomerular filtration rate. Interestingly, carvacrol significantly ameliorated serum cystatin C level elevation due to vancomycin-induced renal injury demonstrating crucial protection against protein catabolism and tubular dysfunction. Furthermore, rats receiving vancomycin caused a significant rising in serum KIM-1 levels compared to the normal control group indicating toxic kidney injury. Interestingly, carvacrol significantly ameliorated serum KIM-1 level el-

Table III. Carvacrol impact on serum level of renal performance indicators in vancomycin-injected rats.

Biomarker	Treatment regimen			
	Control	Carvacrol (50mg/kg)	Vancomycin (200mg/kg)	Vancomycin + Carvacrol
Creatinine (mg/dl)	0.58±0.016	0.58±0.030	2.55±0.067 ^a	1.13±0.049 ^{a,b}
BUN (mg/dl)	29.16±0.30	29.3±0.21	69.33±0.84 ^a	43.33±1.02 ^{a,b}
Cystatin C (ng/ml)	45.58±0.17	45.46±0.16	168.28±1.25 ^a	115.06±1.74 ^{a,b}
KIM-1 (ng/ml)	2.40±0.15	2.47±0.13	13.28±0.27 ^a	8.33±0.14 ^{a,b}

Each finding revealed the standard error of the mean of eight experimental rats (S.E.M). One-way analysis of variance (ANOVA) was applied for statistical analysis, accompanied by Tukey's post hoc comparison test. ^aAt $p < 0.05$, there was a significant difference between the normal control group. ^bAt $p < 0.05$, there was a significant difference vancomycin group.

evaluation due to vancomycin-agitated renal injury. All these results indicate the nephron-protective effect of carvacrol against kidney deterioration stimulated by vancomycin.

Carvacrol Treatment Significantly Reduced Oxidative Stress and Improved Antioxidant Enzymes Activity

In the current investigation, vancomycin injection resulted in a significant decrease in serum levels of GSH and HO-1 compared to the control group. On the contrary, a significant increase in MDA and iNOS levels in serum was observed in parallel with the normal control group. Conversely, co-treatment with carvacrol significantly restored glutathione and HO-1 to normal levels and significantly decreased the elevation of serum malondialdehyde and iNOS levels as matched to vancomycin-treated rats (Table IV).

In addition, vancomycin administration caused a remarkable decrease in HO-1 mRNA and protein expression compared with the normal control group. Compared to the vancomycin-treated group, the carvacrol treatment further upregulated HO-1 mRNA and protein expression (Figure 1 A-B). The observed alleviation in oxidative strain and refinement of the antioxidant defense technique could be accountable for the reno-protective outcomes of carvacrol against vancomycin-agitated renal deterioration.

Carvacrol Diminished Oxidative Overwork Via Coordination of Renal Keap1/Nrf2 Pathway of Vancomycin-Treated Rats

Evaluation of renal mRNA expression levels of keap1/Nrf2 and protein phosphorylation of Nrf2 revealed that vancomycin induced a considerable

Table IV. Carvacrol impact on GSH, HO-1, MDA, iNOS serum levels in vancomycin-injected rats.

Biomarker	Treatment regimen			
	Control	Carvacrol (50 mg/kg)	Vancomycin (200 mg/kg)	Vancomycin + Carvacrol
GSH (μmol/ml)	3.47±0.14	3.2±0.15	0.91±0.037 ^a	1.7±0.09 ^{a,b}
HO-1 (ng/ml)	7.7±0.27	7.8±0.29	1.31±0.0076 ^a	3.99±0.11 ^{a,b}
MDA (mol/ml)	11.7±0.17	11.5±0.01	29.7±0.2 ^a	17.5±0.05 ^{a,b}
iNOS (IU/ml)	4.18±0.07	4.15±0.09	24.71±1.49 ^a	12.13±0.47 ^{a,b}

Each finding revealed the standard error of the mean of eight experimental rats (S.E.M). One-way analysis of variance (ANOVA) was applied for statistical analysis, accompanied by Tukey's post-hoc comparison test. ^aAt $p < 0.05$, there was a significant difference between the normal control group. ^bAt $p < 0.05$, there was a significant difference vancomycin group.

reduction in Nrf2 mRNA and protein expression levels. Compared to the normal group, renal Keap1 mRNA expression levels increased dramatically. In contrast, co-treatment with carvacrol significantly increased Nrf2 mRNA and protein expression levels, even though Keap1 mRNA expression levels revealed a noticeable lowering as matched to the vancomycin-treated group (Figure 2 A-C), indicating the regulation of Keap1/Nrf2 pathway might be one of the emphasized techniques in protection against vancomycin-agitated nephrotoxicity.

Treatment with Carvacrol Mitigates Vancomycin-Induced Inflammatory Response

The current detections illustrated that vancomycin fundamentally elevated IL-1 β , NGAL,

NF- κ B in serum in the normal group. In contrast to the vancomycin-treated group, pretreatment with carvacrol revealed noticeable mitigation in serum levels of IL-1 β , NGAL, and NF- κ B (Figure 3 A-C). These findings substantiate carvacrol's anti-inflammatory potential, which might be responsible for its nephron protective impacts against vancomycin-induced renal deterioration.

Carvacrol Inhibits Inflammatory response via Influencing I κ B α /NF- κ B/MAPK Activity in Vancomycin-Treated Rats

In comparison to the normal control group, vancomycin administration significantly decreased I κ B mRNA and protein expression levels while significantly increasing p65 NF- κ B mRNA and protein expression levels and elevating p38 MAPK

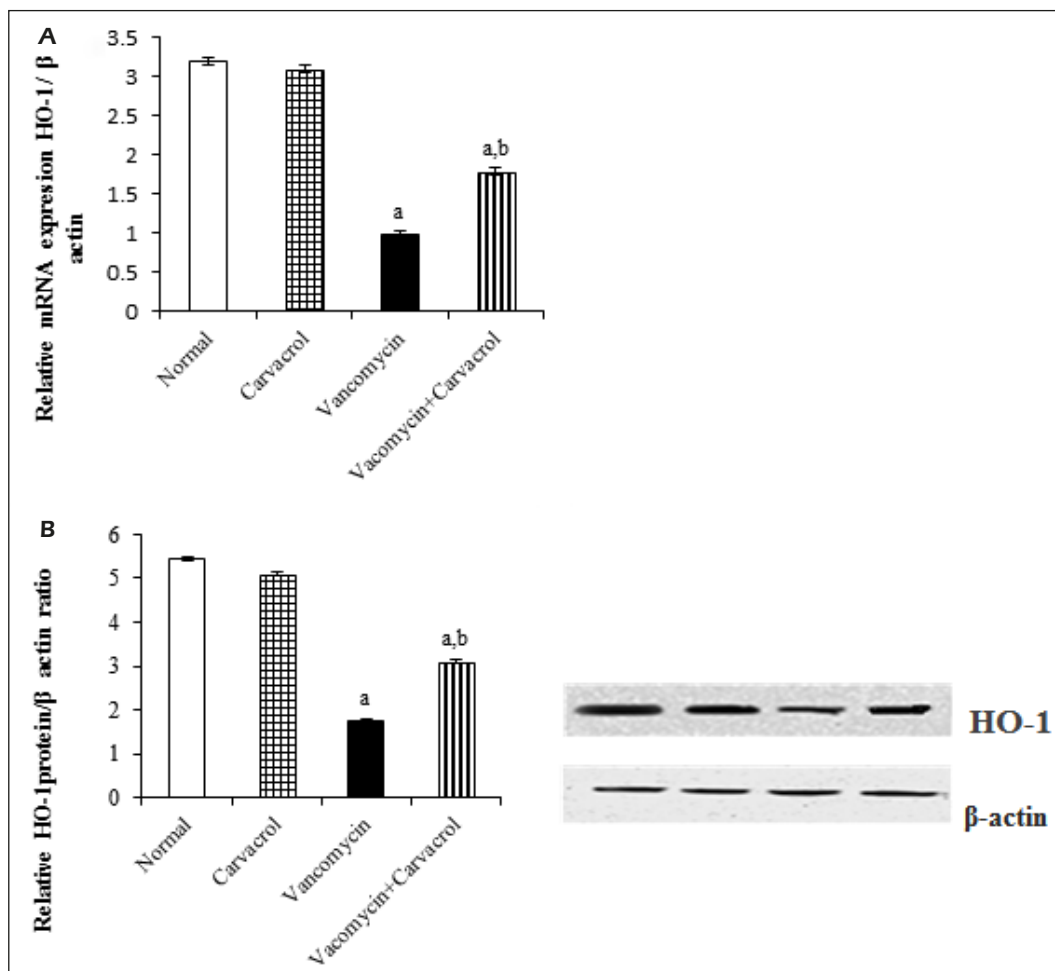


Figure 1. Impact of carvacrol on renal HO-1 mRNA (A) and protein expression in vancomycin-injected rats (B). Each finding revealed the standard error of the mean of eight experimental rats (S.E.M). In regard to β -actin, the proportion of mRNA and phosphorylated protein levels was recorded. One-way analysis of variance (ANOVA) was applied for statistical analysis, accompanied by Tukey's post-hoc comparison test. a: At $p < 0.05$, there was a significant difference from the normal control group. b: At $p < 0.05$, there was a significant difference between the vancomycin group.

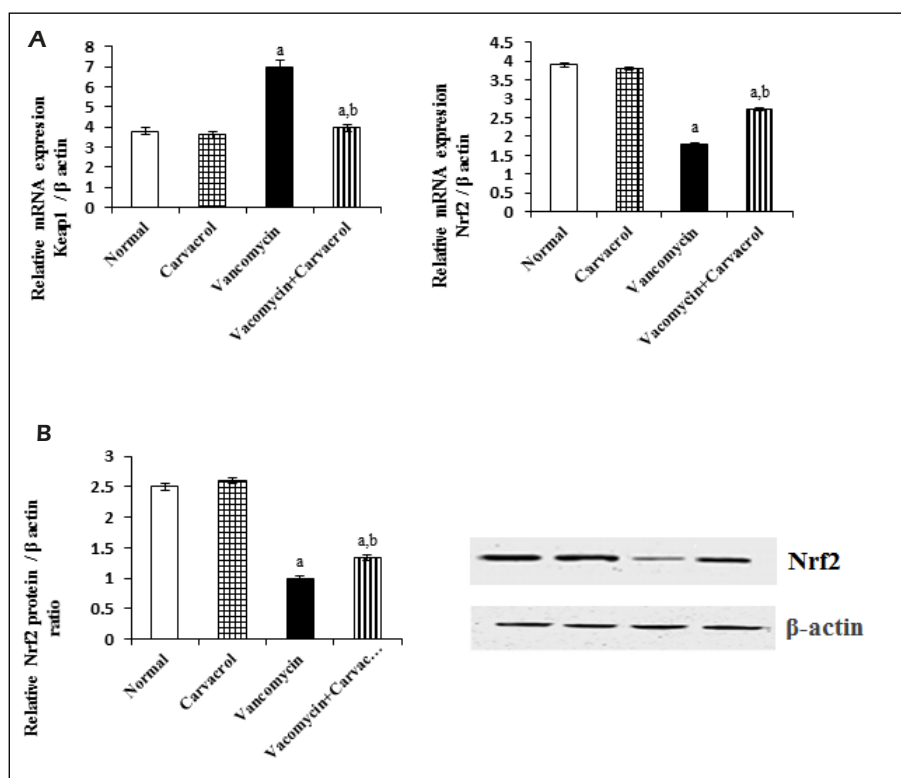


Figure 2. Impact of carvacrol on renal Keap-1 and Nrf2 mRNA (A) and protein expression levels in vancomycin-injected rats (B). Each finding revealed the standard error of the mean of eight experimental rats (S.E.M). In regard to β-actin, the proportion of mRNA and phosphorylated protein levels was recorded. One-way analysis of variance (ANOVA) was applied for statistical analysis, accompanied by Tukey's post-hoc comparison test. a: At $p < 0.05$, there was a significant difference between the normal control group. b: At $p < 0.05$, there was a significant difference vancomycin group.

protein phosphorylation. Compared to the vancomycin-treated group, these impacts were reversed by co-administration of carvacrol, where it up-regulated mRNA and protein expression levels of IKBα and downregulated the mRNA and protein expression levels of p65 NF-κB and reduced p38 MAPK protein phosphorylation (Figure 4 A-E).

Carvacrol Alleviates Vancomycin-Agitated Histopathological Abnormalities in the Kidney

The histopathological examination of kidney sections was performed to estimate vancomycin-agitated renal deterioration and the potential of carvacrol to safeguard renal tissues against this abrasion. The normal control and carvacrol-treated rats demonstrated no histopathological change and the normal histological structure of the glomeruli and tubules at the cortical and cortico-medullary portion, as depicted in (Figure 5 A-B).

In the interior layer of tubular epithelium in the cortical area of the kidneys of vancomycin-treated

rats, histopathological examination indicated gradual, often irreversible degradation and necrosis and the cortico-medullary segment in the medullary section of the tubular lining epithelium. There was also considerable degradation and erosions (Figure 5 C-D). These pathological changes in kidneys were alleviated by carvacrol, where the tubular lining epithelium at the cortex demonstrated slight degradation and erosions. The tubular lining epithelium had minimal tubular congestion in the cortico-medullary region, and the tubular lining epithelium had fewer deteriorating changes (Figure 5 E-F).

Impact of Carvacrol on Immunohistochemical Modulations in Kidney Tissues

Notably, kidney sections obtained from normal rats demonstrated no expression of iNOS, p38-MAPK, and p65-NF-κB immunostaining within the renal lining epithelium of proximal tubular cells (Figure 6 A-C). In contrast, immunohisto-

chemical examination of kidney sections from rats treated with vancomycin revealed significantly reduced the immunoreactivity of iNOS, MAPK, and NF- κ B in renal cells compared to the control group (Figure 6 D-F). Interestingly, rats pretreated with carvacrol showed significant amelioration in the vancomycin-induced overexpression of iNOS, MAPK, and NF- κ B in renal cells compared with the vancomycin-treated group (Figure 6 G-I).

Carvacrol Docking with HO-1, Keap1, NF-B, and MAPK at the Molecular Level

Carvacrol demonstrated promising binding affinities with HO-1, Keap1, NF- κ B, and MAPK with the binding energy of docking -6.61 ± 0.19 , -5.98 ± 0.30 , -5.84 ± 0.32 , and -7.31 ± 0.30 kcal/mol, respectively. Carvacrol demonstrated a well-fit-

ted structure in the small cleft between the prosthetic-heme group and the binding site of HO-1 through hydrophobic interaction with S142, V146, and L147 (Figure 7A). At the dimeric boundary of Keap1, carvacrol showed a variety of non-covalent engagement. It has a hydrogen bond with S363's side chain, and its aromatic ring has π - π interaction with Y334's aromatic ring (Figure 7 B). Carvacrol forms two hydrogen bonds with H364 and G365 in the active binding peptide of NF- κ B (Figure 7 C). Carvacrol demonstrated the highest binding affinity with p38MAPK compared to other target proteins. This promising binding affinity could be attributed to the hydrophobic interaction with the hydrophobic pocket of p38MAPK that include V38, K53, T106, and F169. In addition, it forms a hydrogen bond with T106 (Figure 7D).

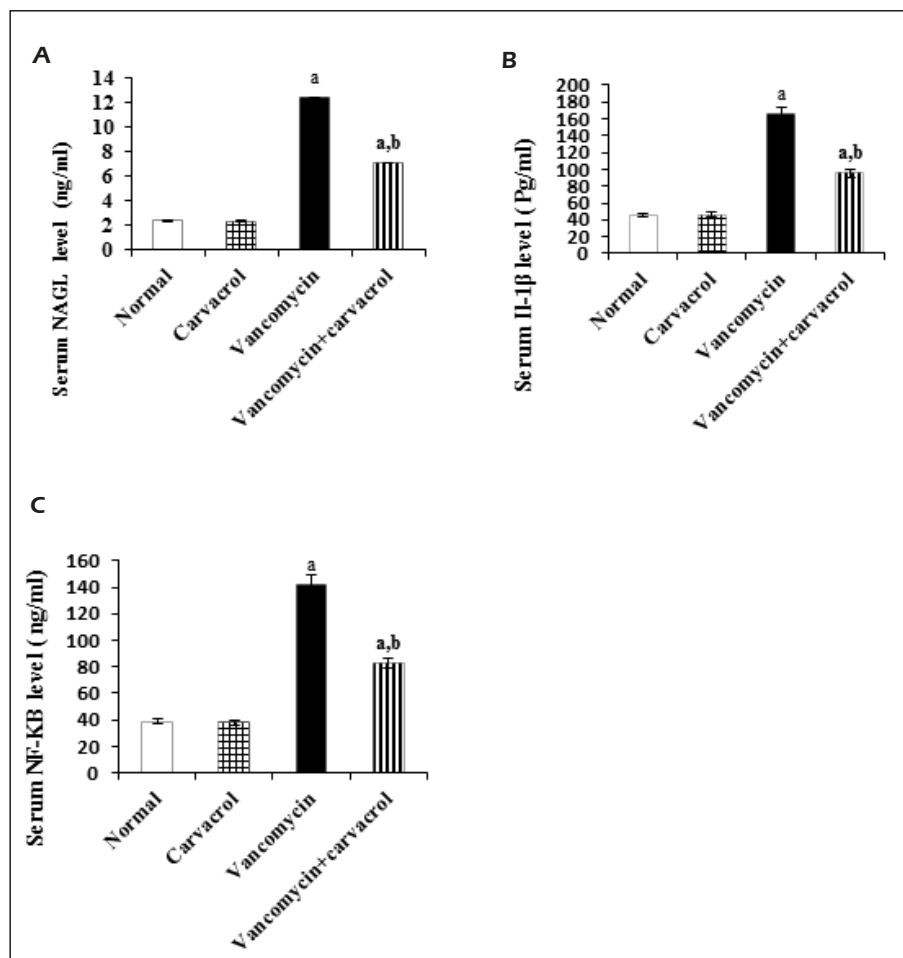


Figure 3. Carvacrol impact on serum levels of IL1 β , NGAL, NF- κ B in vancomycin-injected rats. (A-C) Each finding revealed the standard error of the mean of eight experimental rats (S.E.M). One-way analysis of variance (ANOVA) was applied for statistical analysis, accompanied by Tukey's post-hoc comparison test. a: at $p < 0.05$, there was a significant difference between the normal control group. b: at $p < 0.05$, there was a significant difference vancomycin group.

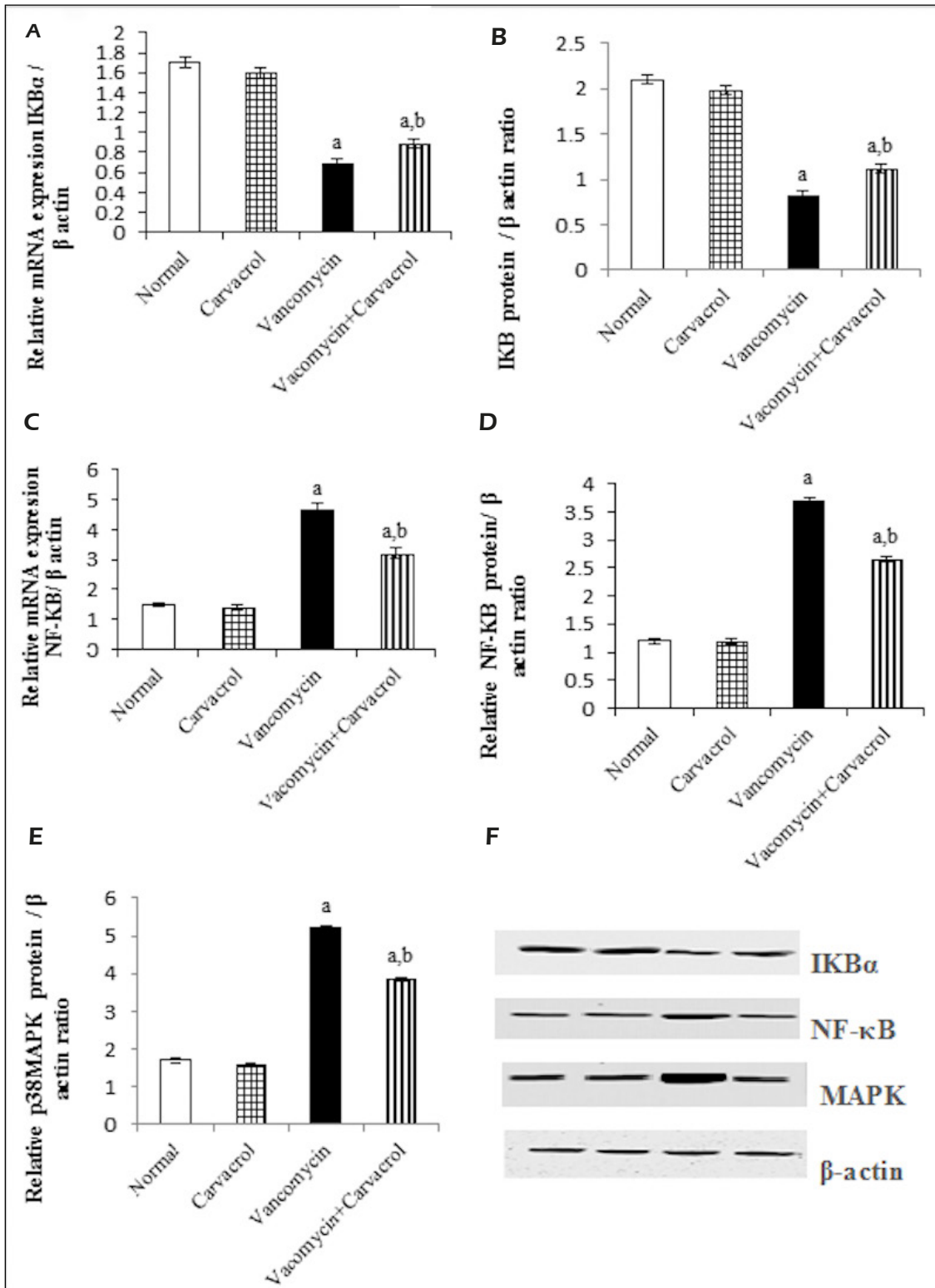


Figure 4. Impact of carvacrol on mRNA and protein expression levels of renal [IκBα]-NF-κB/ MAPK cascade in vancomycin-injected rats. (A-F) Each finding revealed the standard error of the mean of eight experimental rats (S.E.M). In regard to β-actin, the proportion of mRNA and phosphorylated protein levels was recorded. One-way analysis of variance (ANOVA) was applied for statistical analysis, accompanied by Tukey's post-hoc comparison test. a: at $p < 0.05$, there was a significant difference between the normal control group. b: at $p < 0.05$, there was a significant difference vancomycin group.

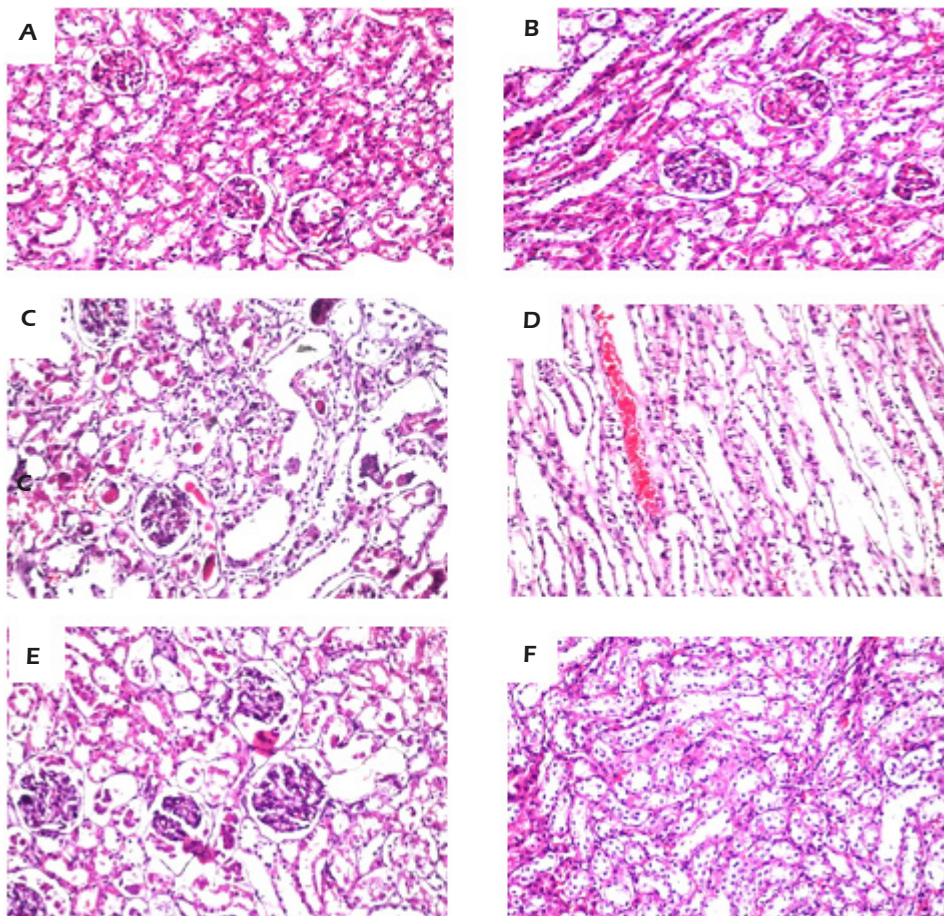


Figure 5. Impact of carvacrol on renal histopathological alterations. Photomicrographs of kidney tissues from rats of various groups stained with hematoxylin and eosin. Kidney sections of normal control (**A**) and carvacrol (**B**) groups showed no histopathological alterations with normal histological structure of the glomeruli and tubules at the cortical and cortico-medullary portion with magnification (x200). The vancomycin-injected rats (**C-D**) had irreversible deterioration and necrosis in the renal tubular epithelium in the cortical section, as well as distinct corrupted changes in the cortico-medullary epithelium, with degeneracy and erosions in the medullary fraction. Kidney sections from the group of vancomycin pretreated with carvacrol (**E-F**) displayed less degenerative changes in the renal histological picture as compared to vancomycin treated group with magnification (x400).

Discussion

Away from the conventional strategies in treating vancomycin renal injury, the current investigation investigates the carvacrol impact on suppressing oxidative load and inflammatory processes, as well as its relationship to the survival systems I κ B-p65 NF- κ B/p38 MAPK and Keap1-Nrf2/HO-1, in mitigating vancomycin-induced renal toxicity. The present study substantiated vancomycin-induced impairment in kidney function by substantial elevation in serum creatinine and urea levels. In the same regard, a previous study showed that vancomycin administration reduced creatinine and BUN levels⁴⁸. Additionally, our results revealed decreased glomerular filtration rate as indicated by

the increased expression of cystatin C in vancomycin exposed group⁴⁹. Cystatin C is a well-known proteinase inhibitor and was previously thought to be primarily responsible for buffering the extracellular inflammatory leukocytes and regulating proteolytic activity in various inflammatory pathways in the renal cell⁵⁰. In the current investigation, carvacrol played a critical role in protecting against protein catabolism and tubular dysfunction, as evidenced by the absence of vancomycin-induced increases in serum creatinine, BUN, and cystatin C levels. This effect could be attributed to carvacrol's antioxidant properties⁵¹.

On the contrary, kidney injury molecule-1 (Kim-1) is a phosphatidylserine transmembrane protein rarely found in healthy kidney tissue

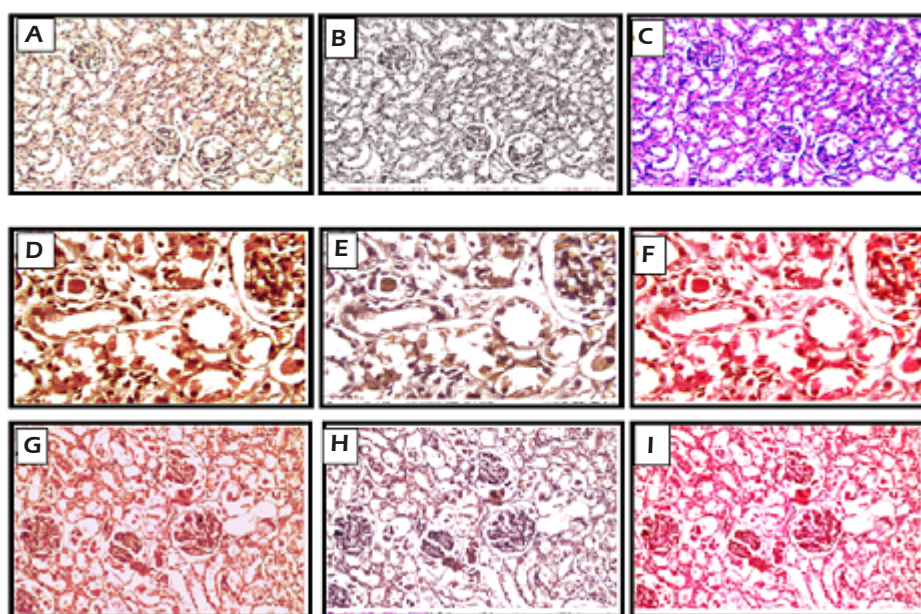


Figure 6. Influence of carvacrol on immunohistochemical alterations in kidney tissues. Immunohistochemical evaluation of the kidneys of control rats demonstrated negative expression of inducible nitric oxide synthase (iNOS), mitogen-activated protein kinase (p38-MAPK) and nuclear factor kappa B (p65-NF- κ B) immunostaining within the lining renal epithelium of proximal tubular cells (A-C), respectively with magnification (x200). On other hand, vancomycin administration, upon immunohistochemical examinations of kidneys, revealed significant increases in the immunoreactivity of iNOS, MAPK and NF- κ B in renal cells as compared to control group (D-F), respectively with magnification (x400). Interestingly, immunohistochemical evaluation of carvacrol-treated rats showed significant reductions in the vancomycin-induced overexpression of iNOS, MAPK, NF- κ B in renal proximal cells in comparison to vancomycin injected rats (G-I), respectively with magnification (x200).

but is elucidated at elevated concentrations in epithelial cells of the proximal tubule, especially in ischemic or toxic cases^{52,53}. It arranged the engulfment of apoptotic cells and oxidized molecules^{54,55}. In addition, KIM-1 overexpression can promote the migration and proliferation of renal tubular epithelial cells by activating the MAPK signaling pathway⁵⁶. In context, the current work demonstrated a substantial increase in Kim-1 serum levels in vancomycin-treated rats. This outcome was particularly evident in carvacrol-protected animals.

Many *in vivo* and *in vitro* studies revealed that vancomycin induced ROS generation, which is considered one of the essential mediators for its nephrotoxic activity^{57,58}. Meanwhile, these free radicals could cause lipid peroxidation as demonstrated by increased malondialdehyde (MDA) production and depletion of the antioxidant system are well known to cause protein denaturation, membrane lipid peroxidation, and cellular injury⁵⁹. In the current research, oxidative injury due to vancomycin was found to deplete protec-

tive cellular antioxidants such as serum reduced glutathione (GSH), heme oxygenase-1 (HO 1), and serum MDA^{60,61}. The combination of carvacrol and vancomycin significantly reduced the oxidative damage caused by the antibiotic, as evidenced by the recovery of serum GSH and HO-1 levels and the decrease of serum MDA levels. It is possible to attribute carvacrol's antioxidant effects at least to its free radical scavenging feature, which is due to the presence of the phenolic OH group linked to the aromatic ring in its structure. Furthermore, it serves as a hydrogen donor for the peroxy radicals formed during the lipid oxidation step, protecting the kidney from the adverse effects of ROS generation.

In addition, Heme oxygenase-1 is the only rate-limiting enzyme implicated in heme retrogression, converting heme into carbon monoxide, iron, and biliverdin⁶². The anti-oxidative, anti-inflammatory, anti-apoptosis, signaling, and immune controlling mechanisms of the previously metabolites validate HO1 to supply widespread tissue protection⁶³. In the current investigation,

carvacrol restored HO-1 activity besides the cellular thiol pool, demonstrating extensive protection against vancomycin-induced oxidative stress. Due to the presence of the phenolic OH group linked to the aromatic ring in its structure, the antioxidant effects of carvacrol could be attributed at least to its free radical scavenging feature. Furthermore, it serves as a hydrogen donor for the peroxy radicals formed during the lipid oxidation step, protecting the kidney from the detrimental effects of ROS generation⁶⁴.

Cells normally refuse to be exposed to potentially harmful oxidizing lesions; they attempt to protect themselves by orchestrating the intracellular antioxidant systems. One of these defenses is the Keap1-Nrf2/HO-1 pathway⁶⁵. Revitalizing Nrf2 and catalyzing the expression of HO-1 elucidated a sensitive marker of a cellular response versus oxidative strain. In situations accompanied by oxidative workover, the Keap1-Nrf2/HO-1 pathway is usually prompted, causing dissociation of Nrf2 from Keap1 and its migration to the nucleus stimulating the transcription of antioxidant genes. Here, the vancomycin-treated rats revealed a considerable suppression in both the protein and mRNA expression levels of Nrf2 and HO-1 with the exhaustion of the serum HO-1 level. Nevertheless, the mRNA expression level of Keap1 was significantly increased. The vancomycin-induced toxicity results in the enormous generation of ROS and RNS that overruns the physiological amplitude of the antioxidant

enzymes, such as HO-1. Consequently, these enzymes are depleted, and their efficiencies are attenuated. In the rats protected with carvacrol, a significant elevation in both the protein and mRNA expression levels of Nrf2/HO-1 and serum HO-1 level was observed with a significant increase in the mRNA expression level of Keap1. Therefore, the nephroprotective effect of carvacrol may be attributed to its ability to mitigate the vancomycin-induced activation Keap1-Nrf2/HO-1 signaling pathway.

The pathological procedure of vancomycin-agitated renal cell injury is associated with the release of several inflammatory cytokines and mediators, including IL-1 β , IL-6, TNF- α , iNOS, and NO⁶⁶. Interleukin-1 β (IL-1 β) is a proinflammatory cytokine linked to a variety of inflammatory diseases, as well as increased vascular permeability and hyperalgesia⁶⁷. Interestingly, the present investigation demonstrated that carvacrol has a conclusive mechanism to slow down the inflammatory process induced by vancomycin by lowering IL-1 β and NGAL serum levels. Neutrophil Gelatinase Associated Lipocalin is considered the essential protein responsible for a series of alterations in plasma protein levels during inflammatory prompting, agitated at most by the impacts of IL-1 β ⁶⁸. Furthermore, it has been reported that the nephroprotective effect of carvacrol treatment may be provided by attenuating the overproduction of IL-1 β and NO in macrophages cells, improving or preventing the destructive ef-

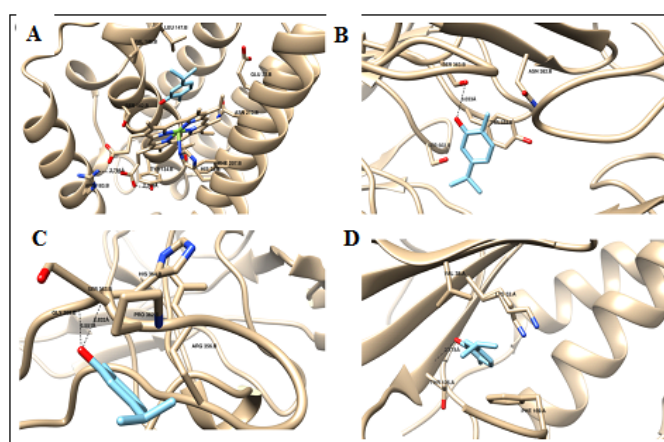


Figure 7. Carvacrol docking with HO-1, Keap1, NF- κ B, MAPK at molecular level. Carvacrol exhibited hydrophobic interaction with S142, V146 and L147 of HO-1 (A). Carvacrol forms a hydrogen bond with the side chain of S363 and π - π interaction with the aromatic ring of Y334 of Kelch-like ECH-associated protein 1 (Keap1) (B). Carvacrol forms a pair of hydrogen bonds with H364 and G365 of NF- κ B (C). Carvacrol exhibited hydrophobic interaction with the hydrophobic pocket of mitogen-activated protein kinase (p38MAPK) V38, K53, T106 and F169 and forms a hydrogen bond with T106 (D). Blocks reflect all the interaction residues of the identified proteins with carvacrol.

fects of lipopolysaccharide by inhibition of a cascade of the proinflammatory cytokine⁶⁹.

Nitric oxide is identified as a key regulator of physiological and pathological procedures of renal damage, and its role as an agitator of apoptosis in other organs has been stated before⁷⁰. Additionally, it was found that NO produced by iNOS has been detected in different sections of the renal tubules as well as in the glomerulus⁷¹. Vancomycin was found to initiate its renal apoptotic effect *via* NO, which reacts with superoxide anion and produces peroxynitrite radical, a more potent oxidant and cytotoxic agent implicated in lipid peroxidation of vancomycin-induced nephrotoxicity^{72,73}. It was also found that vancomycin administration increased the activities of iNOS in kidney tissues⁵⁹. Furthermore, NO acts as a neurotransmitter and vasodilation inducer, promoting an elevation of the macrophage's activity to reinforce the secretion of proinflammatory signaling molecules⁷⁴. The present data demonstrated that carvacrol considerably declined the mRNA expression level of iNOS. In addition, the current immunohistochemical study revealed that carvacrol eliminated the vancomycin-induced iNOS expression observed, supporting the assumption that carvacrol minimized NO generation by inhibiting the transcription of the iNOS genes explaining the anti-nitrosative effect of carvacrol.

Among all the intracellular signaling systems involved in regulating the levels of proinflammatory cytokines and inflammatory mediators, nuclear factor-kappa B (NF- κ B) is of particular interest. A series of inhibitory proteins known as nuclear factor of kappa light polypeptide inhibitors NF- κ B (IKBs) protect it physically in the cytoplasm^{75,76}. To further determine the anti-inflammatory activity of carvacrol, the NF- κ B p65 subunit and I κ B α in the NF- κ B signaling pathway were assessed. The current finding revealed that the protein phosphorylation and mRNA expression levels of I κ B α were lowered by vancomycin while NF- κ B protein and mRNA expression levels exceeded the normal group. Carvacrol supplementation restored these changes to their normal level, resulting in I κ B activation and NF- κ B inhibition. As a result, the current findings suggest that the protective effects of carvacrol on vancomycin-agitated rat renal injury may be linked to the suppression of NF- κ B initialization. Subsequently, the current outcomes illustrated that the protective impacts of carvacrol on vancomycin-agitated rat renal injury might be linked to the suppression of NF- κ B initialization.

To further clarify the restrained role of carvacrol on cytokine induction and signaling molecule generation, the recent study also confirmed its impact on the MAPK pathway, which plays a critical role in the inflammatory responses^{39,77}. The expression and initialization condition of the essential components of the p38 MAPK/NF- κ B axis were firmly established and positively connected to each other^{78,79}. These results demonstrated that phosphorylation of p38 MAPK was confirmed after vancomycin treatment. However, the phosphorylation and mRNA expression of p38 MAPK was significantly inhibited in carvacrol-treated groups. The previous findings indicated that carvacrol suppressed the initialization of proinflammatory signaling molecules by prohibiting the invigoration of NF- κ B and MAPK signaling pathways.

Vancomycin-treated rats had progressive, often irreversible deterioration and necrosis of the tubular lining epithelium in the cortical section, as well as degradation and erosions of the tubular lining membrane in the medullary fraction, according to the histopathological examination of kidney sections in the current study. These changes in vancomycin were equivalent to the alterations affirmed by Kandemir et al⁵⁹, who elucidated histological abrasions of rat kidneys after vancomycin treatment performed acute tubular necrosis emphasizes irreversible deterioration. Kidney sections from rats pretreated with carvacrol demonstrated less renal changes with mild degeneration in the tubular lining epithelium compared to the vancomycin group. This finding further supports the biochemical findings of the present investigation.

Otherwise, the use of a molecular docking technique to predict the binding ability of experimental drugs with their target proteins is prevalent in drug discovery⁸⁰. This approach can also be used to investigate the regulatory role of the drugs in different disease pathways. In the current study, this approach was utilized to investigate the potential binding of carvacrol with the crucial proteins that regulate the oxidative stress and inflammation pathways. Interestingly, carvacrol demonstrated promising binding affinities with the target proteins. The high affinity of carvacrol with the target proteins is due to the monoterpenoid phenol structure that allows it to form various non-covalent interactions through its polar phenolic-OH group and the aromatic ring. The docking findings strongly confirmed the modulatory impact of carvacrol in oxidative strain and inflammation cascades and its ther-

apeutic potential against vancomycin-induced nephrotoxicity.

Conclusions

The current research has revealed the protective effects of carvacrol versus vancomycin-agitated kidney injury. Carvacrol protected the rat kidney from the oxidative strain and inflammation stimulated by vancomycin by alleviating kidney deterioration. This effect could be attributed to the regulation and controlling of the following signaling cascades I κ B α /MAPK and Keap1/Nrf2, suggesting its role in the protective effect of carvacrol versus vancomycin-prompted kidney damage. Notably, carvacrol could be considered a reno-protective agent against vancomycin-induced nephrotoxicity. Further clinical studies are required to confirm our findings.

Conflict of Interest

The authors state that they have no recognized conflicting economic interests or personal connections that could have impacted the work.

Acknowledgments

Dr. Adel Bakeer Kholousy, Pathology Professor, Cairo University, Faculty of Veterinary Medicine, Egypt, kindly assisted the authors with the histological and immunohistochemical analyses.

Funding

This study was not supported by any governmental, corporate or not-for-profit funding sources.

Authors' Contributions

Marwa M. Khalaf, Samar M. Hassan, and Amira M. Abo-Youssef conceived and designed the experimental protocol. Samar M. Hassan conducted the experiments. Marwa M. Khalaf supervised the experimentation. Marwa M. Khalaf, Samar M. Hassan, and Amira M. Abo-Youssef performed statistical data analysis. Ahmed M. Sayed performed the molecular docking. Samar M. Hassan and Marwa M. Khalaf wrote the paper draft. Ahmed M. Sayed and Amira M. Abo-Youssef revised the manuscript. All authors contributed significantly to the research and have reviewed and confirmed the work for publishing.

All data were generated in-house, and no paper mill was used. All authors agree to be accountable for all aspects of work, ensuring integrity and accuracy.

Ethics Approval

All experiments and animal care procedures were carried out in accordance with the guidelines of the Ethics Committee for Animal Experimentation (Institutional Animal Care and Use Committee of Beni-Suef University, Faculty of Pharmacy (Reference Number: 020-121), which are based on the requirements proposed by the National Institutes of Health (NIH) Guide for Care and Use of Laboratory Animals.

References

- 1) Rybak MJ, Lomaestro BM, Rotschahfer JC, Mollering RC, Craig WA, Billeter M, Dalovisio JR, Levine DP. Vancomycin therapeutic guidelines: a summary of consensus recommendations from the infectious diseases Society of America, the American Society of Health-System Pharmacists and the Society of Infectious Diseases Pharmacists. *Clin Infect Dis* 2009; 49: 325-327.
- 2) Vandecasteele SJ, Boelaert JR, De Vriese AS. Staphylococcus aureus infections in hemodialysis: what a nephrologist should know. *Clin J Am Soc Nephrol* 2009; 4: 1388-1400.
- 3) Basarslan F, Yilmaz N, Ates S, Ozgur T, Tutanc M, Motor V, Arica V, Yilmaz C, Inci M, Buyukbas S. Protective effects of thymoquinone on vancomycin-induced nephrotoxicity in rats. *Exp Toxicol* 2012; 31: 726-733.
- 4) Nishino Y, Takemura S, Minamiyama Y, Hirohashi K, Tanaka H, Inoue M, Okada S, Kinoshita H. Inhibition of vancomycin-induced nephrotoxicity by targeting superoxide dismutase to renal proximal tubule cells in the rat. *Redox Rep* 2007; 7: 317-319.
- 5) Gharishvandi F, Kazerouni F, Ghanei E, Rahmipour A, Nasiri M. Comparative Assessment of Neutrophil Gelatinase-Associated Lipocalin (NGAL) and Cystatin C as early biomarkers for early detection of renal failure in patients with hypertension. *Iran Biomed J* 2015; 19: 76-81.
- 6) Tian L, Shao X, Xie Y, Wang Q, Che X, Zhang M, Xu W, Xu Y, Ni Z, Mou S. Kidney injury molecule-1 is elevated in nephropathy and mediates macrophage activation via the MAPK signaling pathway. *Cell Physiol Biochem* 2017; 41: 769-783.
- 7) Bayomy NA, Abdelaziz EZ, Said MA, Badawi MS, El-Bakary RH. Effect of pycnogenol and spirulina on vancomycin-induced renal cortical oxidative stress, apoptosis and autophagy in adult male albino rat. *Can J Physiol Pharmacol* 2016; 94: 838-848.
- 8) Davis CA, Nick HS, Agarwal A. Manganese superoxide dismutase attenuates cisplatin-induced renal injury: importance of superoxide. *Clin J Am Soc Nephrol* 2001; 12: 2683-2690.
- 9) Ahmida MH. Protective role of curcumin in nephrotoxic oxidative damage induced by vancomycin in rats. *Exp Toxicol Pathol* 2012; 64: 149-153.

- 10) Khaliq H, Jing W, Ke X, Ke-Li Y, Peng-peng S, Cui L, Wei-wei Q, Zhixin L, Hua-Zhen L, Hui S, Ju-Ming Z, Ke-Mei P. Boron affects the development of the kidney through modulation of apoptosis, antioxidant capacity, and Nrf2 Pathway in the African Ostrich Chicks. *Biol Trace Elem Res* 2018; 186: 226-237.
- 11) Clark, JS, Faisal A, Baliga R, Nagamine Y, Arany I. Cisplatin induces apoptosis through the ERK-p66shc pathway in renal proximal tubule cells. *Cancer Lett* 2010; 297: 165-170.
- 12) Oktem F, Arslan MK, Ozguner F, Candir O, Yilmaz HR, Ciris M, Uz E. In vivo evidences suggesting the role of oxidative stress in pathogenesis of vancomycin-induced nephrotoxicity: protection by erdosteine. *Toxicol* 2005; 15: 227-233. 13) Mergenhagen KA, Borton AR. Vancomycin nephrotoxicity: a review. *J Pharm Pract* 2014; 27: 545-553.
- 14) Lee JK, Choi SS, Won JS, Suh HW, The regulation of inducible nitric oxide synthase gene expression induced by lipopolysaccharide and tumor necrosis factor-alpha in C6 cells: Involvement of AP-1 and NF kappa B. *Life Sci* 2003; 73: 595-609. 15) Kramer HJ, Floege J. Differential activation of mitogen activated protein kinases in experimental proliferative glomerulonephritis. *J Am Soc Nephrol* 2000; 11: 232-240.
- 16) Ohashi R, Nakagawa T, Watanabe S, Kanellis J, Almiraz RG, Schreiner GF, Johnson RJ. Inhibition of p38 mitogen activated protein kinase augments progression of remnant kidney model by activating the ERK pathway. *Am J Pathol* 2004; 164: 477-485.
- 17) Yesil A, Gonen C, Senates E, Paker N, Gokden Y, Kochan K, Erdem ED, Gunduz F. Relationship Between Neutrophil Gelatinase-Associated Lipocalin (NGAL) Levels and Inflammatory Bowel Disease Type and Activity. *Dig Dis Sci* 2013; 58: 2587-2593.
- 18) Yanishlieva NV, Marinova EM, Gordon MH, Raneva VG. Antioxidant activity and mechanism of action of thymol and carvacrol in two lipid systems. *Food Chem* 1999; 64: 59-66.
- 19) Aeschbach R, Lölliger J, Scott BC, Murcia A, Butler C, Halliwell B, Aruoma OI, Antioxidant actions of thymol, carvacrol, 6-gingerol, zingerone and hydroxyl tyrosol. *Food Chem Toxicol* 1994; 32: 31-36.
- 20) Landa P, Kokoska L, Pribylova M, Vanek T, Marsik P. In vitro anti-inflammatory activity of carvacrol: inhibitory effect on COX-2 catalyzed prostaglandin E(2) biosynthesis. *Arch Pharm Res* 2009; 32: 75-78.
- 21) Lima MS, Quintans-Ju'nior LG, De Santana W, Kaneto CM, Botelho M, Soares P, Villarreal CF. Anti-inflammatory effects of carvacrol: Evidence for a key role of interleukin-10. *Eur J Pharma* 2013; 699: 112-117.
- 22) Shelef LA. Antimicrobial effects of spices, *J Food Safety* 1993; 6: 29-44.
- 23) Melo FH, Moura BA, De Sousa DP, De Vasconcelos SM, Macedo DS, Fonteles MM, Viana GS, De Sousa FC. Anxiolytic-like effect of carvacrol (5-isopropyl-2-methylphenol) in mice: involvement with GABAergic transmission. *Fundam Clin Pharmacol* 2010; 24: 437-443.
- 24) Aristatile B, Al-Numair SK, Veeramani C, Pugalendi KV. Effect of carvacrol on hepatic marker enzymes and antioxidant status in D-galactosamine induced hepatotoxicity in rats. *Fundam Clin Pharmacol* 2009; 23: 757-765.
- 25) Melo FH, Moura BA, De Sousa DP, De Vasconcelos SM, Macedo DS, Fonteles MM, Viana GS, De Sousa FC. Antidepressant-like effect of carvacrol (5-Isopropyl-2-methylphenol) in mice: involvement of dopaminergic system. *Fundam Clin Pharmacol* 2011; 25: 362-367.
- 26) Bozkurt M., Em S, Oktayoglu P, Turkcu G, Yuksel H, Sariyildiz MA, Caglayan, M, Batmaz I, Nas K, Bozkurt Y, Kuyumcu M. Carvacrol prevents methotrexate induced renal oxidative injury and renal damage in rats. *Clin Invest Med* 2014; 37: 19-25.
- 27) Fawcett JK, Scott JE. A rapid and precise method for the determination of urea. *J Clin Pathol* 1960; 13: 156-159.
- 28) Bartels H, Bohmer M, Heierli C. Serum creatinine determination without protein precipitation. *Clin Chim Acta* 1972; 37: 193-197.
- 29) Coll E, Botey A, Alvarez L, Poch E, Quinto L, Saurina A, Vera M, Piera C, Darnell A. Serum cystatin C as a new marker for noninvasive estimation of glomerular filtration rate and as a marker for early renal impairment. *Amr J Kid Dis* 2000; 36: 29-34.
- 30) Chaturvedi S, Farmer T, GF. Assay Validation for KIM-1: human urinary renal dysfunction biomarker. *Int J Biol Sci* 2009; 5: 128-134.
- 31) Look MP, Rockstroh JK, Rao GS, Kreuzer KA, Barton S, Lemoch H, Sudhop T, Hoch J, Stockinger K, Spengler U, Sauerbruch T. Serum selenium, plasma glutathione (GSH) and erythrocyte glutathione peroxidase (GSH-Px)-levels in asymptomatic versus symptomatic human immunodeficiency virus-1 (HIV-1)-infection. *Eur J Clin Nutr* 1997; 51: 266-272.
- 32) Draper HH, Squires EJ, Mahmoodi H, Wu J, Agarwal S, Hadley M. A comparative evaluation of thiobarbituric acid methods for the determination of malondialdehyde in biological materials. *Free Radic Biol Med* 1993; 4: 353-363.
- 33) Bauer M, Bauer I. Heme Oxygenase-1: Redox regulation and role in the hepatic response to oxidative stress. *Antioxid Redox Signal* 2002; 4: 749-758.
- 34) Combet S, Balligand J, Lameire N, Goffin E, Devuyst O. A specific method for measurement of nitric oxide synthase enzymatic activity in peritoneal biopsies. *Kidney Int* 2000; 57: 332-338.
- 35) Kwonga KYC, Jonesa CA, Cayabyab R, Lecart C, Khuua N, Rhandhawa I, Hanley JM, Ramanathan R, DeLemos RA, Minooc P. The Effects of IL-10 on proinflammatory cytokine expression (IL-1 β and IL-8) in hyaline membrane disease (HMD). *Clin Immunol Immunopathol* 1998; 88: 105-113.

- 36) Aghel A, Shrestha K, Mullens W, Borowski A, Tang WH. Serum neutrophil gelatinase-associated lipocalin (NGAL) in predicting worsening renal function in acute decompensated heart failure. *J Card Fail* 2010; 16: 49-54.
- 37) Logan RM, Stringer AM, Bowen JM, Gibson RJ, Sonis ST, Keefe DM. Serum levels of NF kappa B and proinflammatory cytokines following administration of mucotoxic drugs. *Cancer Biol Ther* 2008; 7: 1139-1145.
- 38) Bancroft JD, Stevens A, Turner DR. Fourth Ed. Churchill Livingstone. Theory and practice of histological techniques, 1996.
- 39) Ozbek E, Cekmen M, Ilbey YO, Simsek A, Polat EC, Somay A. Atorvastatin Prevents Gentamicin-Induced Renal Damage in Rats through the Inhibition of p38- MAPK and NF-κB Pathways. *Ren Fail* 2009; 31: 382-392.
- 40) Rashed L, Hashem R, Soliman H. Oxytocin inhibits NADPH oxidase and P38 MAPK in cisplatin-induced nephrotoxicity. *Biomed Pharmacother* 2011; 65: 474-480.
- 41) Livak KJ, Schmittgen TD. Analysis of relative gene expression data using real-time quantitative PCR and the 2- $\Delta\Delta$ CT method. *Methods* 2001; 25: 402-408.
- 42) Tomara A, Vasistha S, Khana SI, Malika S, Nagb TC, Aryaa DC, Bhatia J. Galangin ameliorates cisplatin induced nephrotoxicity in vivo by modulation of oxidative stress, apoptosis and inflammation through interplay of MAPK signaling cascade. *Phytomedicine* 2017; : 154-161.
- 43) Trott O, Olson AJ. Auto Dock Vina: improving the speed and accuracy of docking with a new scoring function, efficient optimization and multithreading. *J Comput Chem* 2010; 31: 455-461.
- 44) Chen FE, Huang DB, Chen YQ, Ghosh G. Crystal structure of p50/p65 heterodimer of transcription factor NF-κB bound to DNA. *Nature* 1998; 391: 410-413.
- 45) Rahman MN, Vlahakis JZ, Vukomanovic D, Szarek WA, Nakatsu K, Jia Z. X-ray Crystal Structure of Human Heme Oxygenase-1 with (2 R, 4 S)-2-[2-(4-Chlorophenyl) ethyl]-2-[(1 H-imidazol-1-yl) methyl]-4 [(5-trifluoromethylpyridin-2-yl) thio) methyl]-1, 3-dioxolane: A Novel, Inducible Binding Mode. *J med Chem* 2009; 52: 4946-4950.
- 46) Azevedo R, Vanzeeland M, Raaijmakers H, Kazemier B, de Vlieg J, Oubrie A. X-ray structure of p38α bound to TAK-715: comparison with three classic inhibitors. *Acta Crystallographica Section D: Biol Crystallogr* 2012; 68: 1041-1050.
- 47) Jnoff E, Albrecht C, Barker JJ, Barker O, Beaumont E, Bromidge S, Brookfield F, Brooks M, Bubert C, Ceska T, Corden V, Dawson G, Duclos S, Fryatt T, Genicot C, Jigorel E, Kwong J, Maghames R, Mushi I, Pike R, Sands ZA, Smith MA, Stimson CC, Courade JP. Binding mode and structure-activity relationships around direct inhibitors of the Nrf2-Keap1 complex. *Chem Med Chem* 2014; 9: 699-705.
- 48) Cetin H, Olgar S, Oktem F, Ciris M, Uz E, Aslan C, Ozguner F. Novel evidence suggesting an antioxidant property for erythropoietin on vancomycin induced nephrotoxicity in a rat model. *Clin Exp Pharmacol Physiol* 2007; 34: 1181-1185.
- 49) Larsson A, Malm J, Grubb A, Hansson LO. Calculation of glomerular filtration rate expressed in mL/min from plasma cystatin C values in mg/L. *Sci J Clin Lab Invest* 2004; 64: 25-30.
- 50) Ohlsson S, Irena CA, Krantz L, Ohlsson K, Segelmark M, Wieslander J. Novel distribution of the secretory leucocyte proteinase inhibitor in kidney. *Mediat Inflamm* 2001; 10: 347-350.
- 51) Trabace L, Zotti M, Morgese MG, Tucci P, Colaianna M, Schiavone S, Avato P, Cuomo V. Estrous cycle affects the neurochemical and neurobehavioral profile of carvacrol-treated female rats. *Toxicol Appl Pharm* 2011; 255: 169-175.
- 52) Han WK, Bailly V, Abichandani R, Thadhani R, Bonventre JV. Kidney injury molecule-1(KIM-1): a novel biomarker for human renal proximal tubule injury. *Kidney Int* 2002; 62: 237-244.
- 53) Zhou Y, Vaidya VS, Brown RP, Zhang J, Rosenzweig BA, Thompson KL, Miller TJ, Bonventre JV, Goering PL. Comparison of kidney injury molecule-1 and other nephrotoxicity biomarkers in urine and kidney following acute exposure to gentamicin, mercury and chromium. *Toxicol Sci* 2008; 101: 159-170.
- 54) Ichimura T, Asseldonk EJ, Humphreys BD, Gunaratnam L, Duffield JS, Bonventre JV. Kidney injury molecule-1 is a phosphatidylserine receptor that confers a phagocytic phenotype on epithelial cells. *J Clin Invest* 2008; 118: 1657-1668.
- 55) Nojiri T, Hosoda H, Kimura T, Tokudome T, Miura K, Takabatake H, Miyazato M, Okumura M, Kangawa K. Protective effects of ghrelin on cisplatin-induced nephrotoxicity in mice. *Peptides* 2016; 82: 85-91.
- 56) Yang L, Brooks CR, Xiao S, Sabbisetti V, Yeung MY, Hsiao LL, Ichimura T, Kuchroo V, Bonventre JV. KIM-1-mediated phagocytosis reduces acute injury to the kidney. *J Clin Invest* 2015; 125: 1620-1636.
- 57) Elyasi S, Khalili H, Dashti-Khavidaki S, Mohammadpour A. Vancomycin-induced nephrotoxicity: mechanism, incidence, risk factors and special populations. A literature review. *Eur J Clin Pharmacol* 2012; 68, 1243-1255.
- 58) Ima DS, Shina HJ, Yangb KJ, Jungb SY, Songc HY, Hwangd HS, Gile HW. Cilastatin attenuates vancomycin-induced nephrotoxicity via P-glycoprotein. *Toxicol Lett* 2017; 277: 9-17.
- 59) Kandemir FM, Yildirim S, Kucukler S, Caglayan C, Mahamadu A, Dortbudak M.B. Therapeutic efficacy of zingerone against vancomycin-induced oxidative stress, inflammation, apoptosis and aquaporin 1 permeability in rat kidney. *Biomed Pharmacother* 2018; 105: 981- 991.
- 60) King D, Smith M. Proliferative responses observed following vancomycin treatment in renal proximal tubule epithelial cells. *Toxicol In Vitro* 2004; 18: 797-803.

- 61) Jarmi T, Agarwal A. Heme oxygenase and renal disease. *Curr Hypertens Rep* 2009; 11: 56-62.
- 62) Li Q, Guo Y, Ou Q, Cui C, Wu WJ, Tan W, Zhu X, Lanceta LB, Sanganalmath SK, Dawn B, Shinmura K, Rokosh GD, Wang S, Bolli R. Gene transfer of inducible nitric oxide synthase affords cardio-protection by upregulating heme oxygenase-1 via a nuclear factor-kappa B-dependent pathway. *Circulation* 2009; 120: 1222-1230.
- 63) Xin G, Du J, Wang YT, Liang TT. Effect of oxidative stress on heme oxygenase 1 expression in patients with gestational diabetes mellitus. *Exp Ther Med* 2013; 7: 478-482.
- 64) Ezz-Eldin Y, Aboseif AA, Khalaf MM. Potential anti-inflammatory and immunomodulatory effects of carvacrol against ovalbumin-induced asthma in rats. *Life Sci* 2020; 242:117222.
- 65) Sahin K, Tuzcu M, Gencoglu H, Dogukan D, Timurkan M, Sahin N, Aslan A, Kucuk O. Epigallocatechin-3-gallate activates Nrf2/HO-1 signaling pathway in cisplatin-induced nephrotoxicity in rats. *Life Sci* 2010; 87: 240-245.
- 66) Gilmore TD. Introduction to NF- κ B: players, pathways, perspectives. *Oncogene*. 2006; 25: 6680-6684.
- 67) Shen J, Xu S, Zhou H, Liu H, Jiang W, Hao J, Hu Z. IL-1 β induces apoptosis and autophagy via mitochondria pathway in human degenerative nucleus pulposus cells. *Sci Rep* 2017; 7: 41067.
- 68) Cowland JB, Sørensen OE, Sehested M, Borregaard N. Neutrophil Gelatinase-Associated Lipocalin Is Upregulated in Human Epithelial Cells by IL-1 β , but Not by TNF- α . *J Immunol* 2003; 171, 6630-6639.
- 69) Filiopoulos V, Biblaki D, Vlassopoulos D. Neutrophil gelatinase-associated lipocalin (NGAL): A promising biomarker of contrast-induced nephropathy after computed tomography. *Ren Fail* 2014; 36: 979-986.
- 70) Goligorsky MS, Brodsky SV, Noiri E. Nitric oxide in acute renal failure: NOS versus NOS. *Kid Int* 2002; 61: 855-861.
- 71) Vodovotz Y, Kim PKM, Bagci EZ, Ermentrout BG, Chow CC, Bahar I, Billiar TR. Inflammatory Modulation of Hepatocyte Apoptosis by Nitric Oxide: In Vivo, In Vitro, and In Silico Studies. *Curr Mol Med* 2004; 4: 753-762.
- 72) Ischiropoulos H, Zhu L, Beckman JS. Peroxynitrite formation from macrophage-derived nitric oxide. *Arch Biochem Biophys* 1992; 298: 446-451.
- 73) Christo JS, Rodrigues AM, Mouro MG, Cenedeze MA, Simões MDJ, Schor N, Higa EMS. Nitric oxide (NO) is associated with gentamicin (GENTA) nephrotoxicity and the renal function recovery after suspension of GENTA treatment in rats. *Nitric Oxide* 2011; 24: 77-83.
- 74) Chong DLW, Sriskandan S. Proinflammatory mechanisms in sepsis. *Contrib Microbiol* 2011, 17: 86-107.
- 75) Perkins ND. Integrating cell-signalling pathways with NF- κ B and IKK function. *Nat Rev Mol Cell Biol* 2007; 8: 49-62.
- 76) Sahu BD, Kalvala AK, Koneru M, Kumar JM, Kuncha M, Rachamalla SS, Sistla R. Ameliorative Effect of Fisetin on Cisplatin-Induced Nephrotoxicity in Rats via Modulation of NF- κ B Activation and Antioxidant Defence. *PLoS ONE* 2014; 9: e105070.
- 77) Ramesh G, Reeves WB. p38 MAP kinase inhibition ameliorates cisplatin nephrotoxicity in mice. *Am J Physiol Renal* 2005; 289: 166-174.
- 78) Papachristou DJ, Papadakou E, Basdra EK, Baltopoulos P, Panagiotopoulos E, Papavassiliou AG. Involvement of the p38 MAPK-NF- κ B Signal Transduction Pathway and COX-2 in the Pathobiology of Meniscus Degeneration in Humans. *Mol Med* 2008; 14: 160-166.
- 79) Fann DY, Lim YA, Cheng YL, Lok KZ, Chunduri P, Baik SH, Drummond GR, Dheen ST, Sobey CG, Jo DG, Chen CL, Arumugam TV. Evidence that NF-kappa B and MAPK signaling promotes NLRP inflammasome activation in neurons following ischemic stroke. *Mol Neurobiol* 2017; 55: 1082-1096.
- 80) Meng XY, Zhang HX, Mezei M, Cui M. Molecular docking: a powerful approach for structure-based drug discovery. *Curr Comput-Aided Drug Des* 2011; 7: 146-157.