

Effect of ellagic acid on damage caused by hepatic ischemia reperfusion in rats

C. DURGUN¹, F. AŞIR²

¹Division of General Surgery, Memorial Hospital, Diyarbakır, Turkey

²Department of Histology and Embryology, Faculty of Medicine, Dicle University, Diyarbakır, Turkey

Abstract. – OBJECTIVE: Ischemia (I) causes lack of oxygen delivery to the tissues, leading to hypoxia and cellular damage. Reperfusion (R) is the re-blooded of the tissue; however, it may cause more tissue damage than ischemia alone in some cases. During IR, number of free radicals and metabolic by-products increases. To prevent this, cellular antioxidant system is activated but it may not be enough to restore the cellular activities. The aim of this study was to investigate the potential protective effect of Ellagic Acid on damage caused by hepatic IR in rats.

MATERIALS AND METHODS: Thirty rats were divided into three groups: (1) Sham group – no drug administration but only midline laparotomy was performed in the abdomen; (2) Ischemia-Reperfusion (IR) group – ischemia was applied for 1 hour by sealing the portal vein and hepatic artery, then vessels were reperfused for 6 hours; (3) IR+Ellagic Acid (EA) group – after IR, 10 mg/kg of EA was given intraperitoneally to the rats once a day for 28 days. Oxidative stress markers were analyzed by blood collection. Hepatic tissues were processed for histological and immunohistochemical analysis.

RESULTS: MDA level and MPO activity were increased and GSH content was decreased after IR group was compared to sham group. After EA treatment, these values were improved in IR+EA group. IR caused hepatocyte degeneration, sinusoidal dilatation, leukocyte infiltration and disintegrity of hepatic tissue. EA administration improved histopathology after IR. IR injury increased TNF- α and Caspase-9 expression in hepatocytes and vascular endothelial cells in IR group; however, both decreased in EA-received group.

CONCLUSIONS: Ellagic Acid may reduce oxidative stress level and prevent induction of inflammation and cell death against hepatic IR.

Key Words:

Ischemia-Reperfusion, Ellagic acid, TNF- α , Caspase-9.

Introduction

Cells undergo hypoxia and nutrient deficiency during ischemia (I), causing disruption of cellular homeostasis. Reperfusion (R) is the restoration of the blood flow to ischemic cells. Reperfusion itself may give more tissue damage than ischemia alone. This is called IR injury. During IR, depletion of oxygen and nutrients occurs, and metabolic by-products are accumulated¹. Hepatic vascular exclusion and total vascular exclusion are methods to prevent excessive blood during liver surgery². Animal experimentation to explain hepatic IR mechanism would be beneficial for clinical patients with prolonged IR injury or liver transplantation. Animal IR model can reveal phenomenon lying in IR injury at molecular and cellular level³.

Ellagic acid (C₁₄H₆O₈, EA) is a phenolic compound that can be obtained from the leaves, fruits and seeds of plants such as *Myrciaria cauliflora*, *Juglans regia*, *Terminalia chebula*, *Sanguisorba officinalis*, *Punica granatum*⁴. EA is formed as a result of hydrolysis of ellagitannins, which are formed as secondary metabolites in plants. EA is known with its anti-inflammatory and antioxidant properties⁵. Ellagic acid inhibits hydrogen peroxide-induced toxicity. Although hydrogen peroxide does not react specifically with most of the molecules of biological importance, it is a precursor that plays a role in the formation of more reactive oxidants, such as the hydroxyl radicals. Therefore, it is thought that ellagic acid may reduce cellular degeneration triggered by free radicals⁶. Studies⁷ have shown that plant extracts containing EA have a proliferation-suppressive effect for many different cancer cells. Other studies⁸ have shown that ellagic acid provides neuroprotection by reducing oxidative damage in diabetic rats.

Tumor necrosis factor- α (TNF- α) is a cytokine secreted by many immune cells. TNF- α is involved in various cellular events such as inflammation, proliferation, and apoptosis. TNF- α has long been associated with hepatic IR injury and play key role in the response to the injury. It is secreted from hepatic macrophages, namely Kupffer cells, and its level readily increases after IR^{8,9}. Caspase-9 is an important initiator of apoptosis activated by mitochondria-mediated signaling pathway; it has been shown to be effective as an antiapoptotic agent in animal models of cerebral ischemia and spinal cord injury¹⁰.

In this study, the effects of EA on rat liver ischemia reperfusion injury were examined histopathologically, immunohistochemically and biochemically.

Materials and Methods

All animal experimentation with ethical approval was done according to Local Ethical Committee of Animal Experiments of Dicle University, Turkey (record number: 2022/38). Male Wistar albino rats (n=30), 3 to 4 months old, weighing 180 to 240 g were used. Experimental animals had unlimited access to water and food, and they were kept under control in an environment of 12 hours daytime/12 hours dark, 8:00 am to 8:00 pm, at 23±2°C. Thirty animals were assigned to three groups (10 rats per group).

1. Sham group: no drug administration. Midline laparotomy was performed in the abdomen and then it was sealed up again.
2. Ischemia-Reperfusion (IR) group: before surgical procedures, animals were anesthetized by intramuscular injection of 80 mg/kg ketamine hydrochloride (Ketalar®, Pfizer, Istanbul, Turkey) and 20 mg/kg xylazine (Rompun®, Bayer, Istanbul Turkey). In the midline of abdomen, 4 cm of incision were opened to observe hepatoduodenal ligament. Hepatic artery and vein were clamped with Bulldog clam for 60 min (1 hour) ischemia. Then, the suture was opened, and hepatic reperfusion was performed for 6 hours. After these procedures, the abdominal midline was closed by suturing with skin and fascia.
3. IR+Ellagic Acid group: after IR, 10 mg/kg Ellagic acid (catalog no: E2250, Merck, Darmstadt, Germany) was administered to the rats by intraperitoneal route once a day for 28 days.

Biochemical Analyses

Blood samples were analyzed for Malondialdehyde (MDA), Glutathione (GSH) and Myeloperoxidase (MPO). Samples were kept in centrifugation tubes and centrifuged for 5 minutes at 1,550 g. Supernatant was discarded to determine level of MDA, GSH and MPO. MDA levels (nmol/g) were measured according to method of Draper and Hadley¹¹. To measure GSH activity (U/g), protocol of Paglia and Valentine was carried out¹². MPO level (U/g) was detected according to protocol of Hillegas et al¹³.

Histopathological Analysis

Liver tissues were excised and stored in 10% formalin for tissue fixation. Tissues were passed through ascending alcohol series, washed in xylene and embedded in paraffin wax. Sections were cut from liver tissues and stained with Hematoxylin and Eosin dye. Scoring was calculated for each group by examining ten different areas by two different histologist experts. Parameters were assigned to scoring system where 0=no expression/pathology, 1 = mild expression/pathology, 2 = moderate expression/pathology, 3 = intense expression/pathology, and 4 = very intense expression/pathology^{14,15}.

Immunohistochemical Analysis

Tissues were fixed in 10% formalin solution and processed for histological tissue processing. Sections were deparaffinized in xylene and passed through descending alcohol series. Epitopes were unrevealed by boiling section in microwave oven in citrate buffer solution (pH 6.0) for 15 minutes at 700 W. Sections were washed in phosphate buffered saline (PBS) for 5 minutes and soaked with 3% hydrogen peroxide solution for 7 minutes to prevent endogenous peroxidase. Samples were blocked with blocking solution (catalog no. TA-015UB, ThermoFischer, Waltham, Massachusetts, US) for 8 minutes. Primary antibodies TNF- α , (catalog no: ab220210, Abcam, Cambridge, UK) and Caspase-9 (catalog no: ab202068, Abcam, Cambridge, UK) was dropped onto slides and incubated overnight at +4°C. Sections were first washed in PBS, then treated with secondary antibody (TP-015-BN, ThermoFischer, Waltham, Massachusetts, US) for 20 min. After PBS washing for 3x5 min, streptavidin-peroxidase solution (TS-015-HR, ThermoFischer, Waltham, Massachusetts, USA) was used for 20 min. To visualize expression, DAB (TA-001-HCX, ThermoFischer, Waltham,

Massachusetts, USA) was used as chromogen. Sections were counterstained with hematoxylin and mounted with mounting media and examined with Zeiss Imager A2 light microscope (Carl Zeiss, Jena, Germany)¹⁶⁻²⁰.

Statistical Analysis

Biochemical and histological scoring were evaluated by the IBM SPSS 25.0 software (IBM, Armonk, New York, USA). Shapiro-Wilk test was used for data distribution analysis. Nonparametric Kruskal-Wallis' test (multiple comparison) and Mann-Whitney U (binary comparison) tests were used. $p < 0.05$ was accepted as significant level.

Results

Statistical analysis of biochemical and histochemical parameters are shown in Table I.

MDA and MPO levels and histological scores of hepatocyte degeneration, inflammation, vascular dilatation and congestion, TNF- α and Caspase-9 expression were significantly higher in IR group than sham group. GSH content was the significantly lower in the IR group compared to sham group. Compared to IR group, after EA treatment, MDA and MPO levels were statistically decreased in IR+EA group. Similar statistical decrease was also recorded in hepatocyte degeneration, inflammation, vascular dilatation and congestion, TNF- α and Caspase-9 expression in IR+EA group. GSH content was statistically increased in IR+EA groups compared to IR group.

Histopathological Examination

Hematoxylin Eosin staining and Caspase-9 and TNF- α immune staining of liver sections by groups are shown in Figure 1.

Table I. Biochemical and histological parameters of sham, IR and IR+EA groups.

Parameter	Groups	N	Median (Min-Max)	Mean Rank	p-value
MDA (nmol/g)	Sham	10	35.89 (23.78-57.50)	12.60	$p < 0.001^*$ $p = 0.001^{**}$
	IR	10	58.825 (45.29-68.64)	34.10	
	IR+EA	10	41.63 (30.87-49.32)	17.90	
GSH (U/g)	Sham	10	1.535 (1.13-1.78)	31.05	$p < 0.001^*$ $p = 0.001^{**}$
	IR	10	0.515 (0.24-0.96)	6.00	
	IR+EA	10	1.3 (0.67-1.57)	20.65	
MPO (U/g)	Sham	10	3.82 (3.27-4.37)	6.30	$p < 0.001^*$ $p = 0.001^{**}$
	IR	10	8.975 (7.06-9.85)	35.05	
	IR+EA	10	5.54 (4.13-7.06)	19.70	
Hepatocyte degeneration	Sham	10	0 (0.00-1.00)	5.80	$p < 0.001^*$ $p = 0.004^{**}$
	IR	10	4 (3.00-4.00)	33.00	
	IR+EA	10	2.5 (1.00-4.00)	22.10	
Inflammation	Sham	10	0 (0.00-1.00)	5.70	$p < 0.001^*$ $p = 0.044^{**}$
	IR	10	4 (3.00-4.00)	30.75	
	IR+EA	10	3 (1.00-4.00)	23.80	
Vascular dilatation and congestion	Sham	10	0 (0.00-1.00)	5.65	$p < 0.001^*$ $p = 0.008^{**}$
	IR	10	3.50 (3.00-4.00)	29.00	
	IR+EA	10	3.50 (2.00-4.00)	28.10	
TNF- α expression	Sham	10	0.50 (0.00-1.00)	5.50	$p < 0.001^*$ $p = 0.047^{**}$
	IR	10	4 (3.00-4.00)	26.95	
	IR+EA	10	4.00 (2.00-4.00)	25.05	
Caspase-9 expression	Sham	10	0 (0.00-1.00)	5.50	$p < 0.001^*$ $p < 0.006^{**}$
	IR	10	4 (3.00-4.00)	32.10	
	IR+EA	10	3.00 (2.00-4.00)	22.20	

*Sham vs. IR; **IR vs. IR+EA.

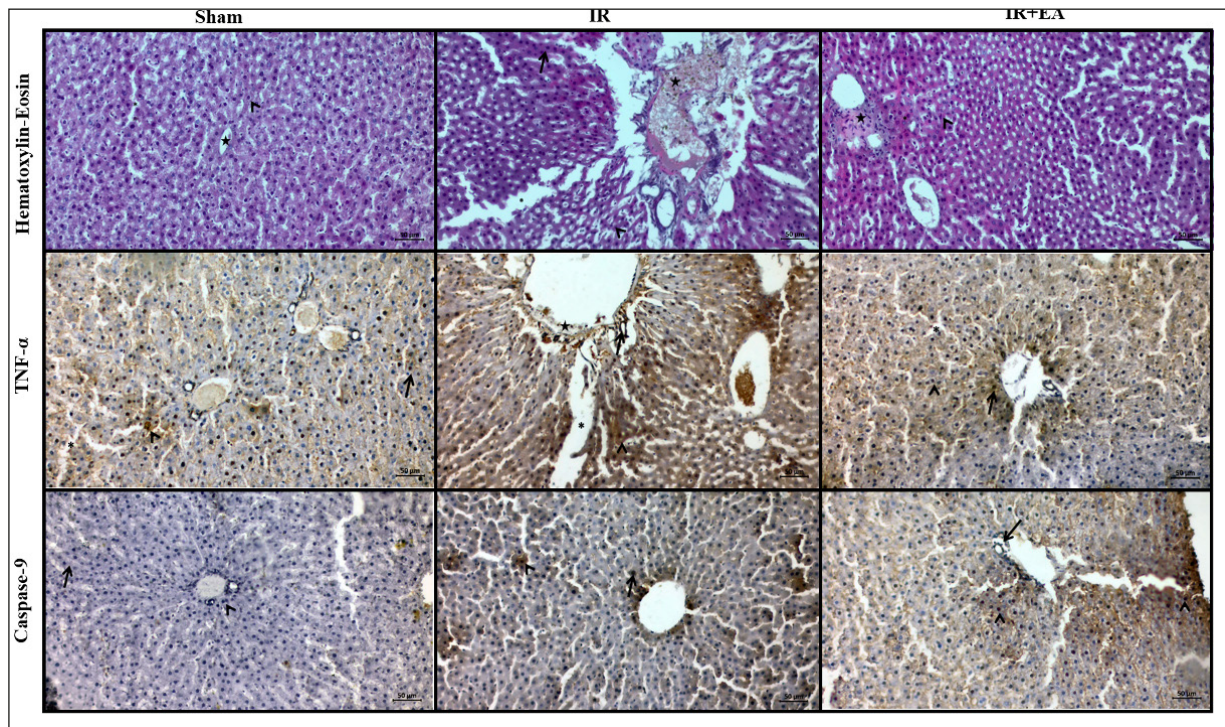


Figure 1. Hematoxylin Eosin staining. Sham group: Normal appearances of hepatocytes (*arrowhead*) around the vena centralis (*star*) and the sinusoidal vessels (*asterisk*); IR group: Degenerated and pyknotic hepatocytes, dilatated sinusoidal vessels (*asterisk*), ruptures of blood vessels in the periportal and portal area and leukocyte infiltration (*asterisk*); IR+Ellagic acid group: Dilatation and cell infiltration (*asterisk*) were observed in the vena centralis. Edema (*asterisk*) and hepatocytes vacuolization and hypertrophy (*arrowhead*) were observed. It was observed that ellagic acid provided moderate protection compared to the ischemia-reperfusion group. TNF- α immunostaining. Sham group: Positive TNF- α expression in some hepatocytes (*arrowhead*) and macrophage cells (*arrow*); IR group: Positive TNF- α reaction in hepatocytes (*arrowhead*), portal area (*star*), inflammatory cells (*asterisk*); IR+Ellagic acid group: Positive TNF- α expression in inflammatory cells (*arrow*) but negative in hepatocytes (*arrowhead*) and sinusoidal vessels (*asterisk*). Caspase-9 immunostaining Sham group: Negative Caspase-9 expression (*arrowhead*) in hepatocytes; IR group: Positive expression in nuclei and cytoplasm of liver cells (*arrowhead*) and vascular endothelial cells (*arrow*); IR+ellagic acid group. Positive Caspase-9 reaction in inflammatory cells (*arrowhead*), hepatocyte cells (*arrow*) and in the sinusoidal vessels (*asterisk*). Scale Bar: 50 μ m, Magnification: 20X.

Discussion

Ischemia-reperfusion (I/R) injury causes imbalance in antioxidant and oxidant molecules level. Malondialdehyde (MDA) level reflects the lipid peroxidation which signals the level of free radical. An increased level of MDA induces cellular scavenging mechanism to prevent further tissue damage caused by reactive oxygen species²¹. One of the cellular antioxidant mechanisms is glutathione peroxidase (GSH). GSH plays a role in protecting the cells against oxidative damage. GSH content is shown to decrease in hepatic ischemia reperfusion injury. This depletion leads to increased lipid

peroxidation and MDA level. Myeloperoxidase (MPO) is a proinflammatory enzyme and an indicator of neutrophils existence. High MPO activity shows elevated level of neutrophils and inflammation^{22,23}. In our study, MDA and MPO levels were significantly increased compared to sham group after IR injury in liver ($p < 0.001$). GSH content in IR group decreased after injury compared to sham group ($p < 0.001$). After EA treatment, MDA and MPO levels in IR+EA group significantly decreased compared to IR ($p < 0.001$). GSH content was also elevated in IR+EA group compared to IR group, and this increase was statistically significant ($p < 0.001$) (Table I).

We observed that ellagic acid (EA) administration reduced MDA level by scavenging free radicals, causing reduction in lipid peroxidation. After IR injury, EA treatment restored the MDA and MPO level to that in sham group. EA acted as a free radical scavenger to reduce lipid peroxidation, thereby increasing GSH content and eliminating reactive oxygen products. Administration of ellagic acid improved biochemical changes and reduced oxidative damage against IR (Table I).

Hepatic ischemia causes hypoxia in hepatic cells, leading to depletion of ATP synthesis. These events result in cell damage with mitochondrial swelling, degenerated sinusoidal endothelial and hepatic macrophages, Kupffer cells. Once macrophages are induced, together with elevated free radicals-initiated expression of proinflammatory molecules *via* neutrophil mediated injury. All these processes lead to inflammation cascade induction²⁴. In the cases of severe hepatic injury, excessive loss of hepatocytes impairs the parenchymal proliferation, inducing hepatic progenitor cells. After hepatic injury, expansion of hepatic progenitor cells indicates depletion in hepatocyte number. Although vacuolization and vascular congestion in hepatocellular damage is reversible, cell death (apoptosis or necrosis) is irreversible²⁵. In our study, statistical analysis showed that histological scores of hepatocyte degeneration, inflammation, vascular dilatation and congestion were increased after IR injury; however, EA treatment improved the scores ($p < 0.001$, Table I). In the histopathological analysis, sham group showed normal liver histology with no pathology. In IR group, degeneration and pyknosis in hepatocyte cells, dilatation of sinusoidal vessels, ruptures of blood vessels in the periportal and portal area and leukocyte infiltration, degeneration of vascular endothelium and hyperplasia of bile duct structures were developed. After EA treatment, in IR+EA group, vascular dilatation and cell infiltration were observed in the vena centralis. Edema and hepatocytes vacuolization and hypertrophy were observed. It was observed that ellagic acid provided moderate protection compared to the ischemia-reperfusion group (Figure 1, Hematoxylin Eosin staining).

Ischemia reperfusion injury in liver may be experienced with many clinical complications, such as liver bleeding and shock, surgical resection and transplantation. Hepatic IR induces many signal pathways with many cell types. Tumor necrosis factor- α (TNF- α) is an inflammatory mediator involving in hepatic IR. Its level readily increases after IR and interacts with many cells

through receptor-mediated signal transduction pathways²⁶. TNF- α is a vital molecule involved in cellular events such as inflammation, proliferation and apoptosis. During hepatic IR injury, expression of TNF- α was shown to change as an inflammatory response. Hepatic macrophages are predominantly responsible for expression of TNF- α , but other hepatic cells can also express it²⁷. In our study, statistical analysis showed histological score of TNF- α were increased after IR injury however EA treatment improved the scores ($p < 0.001$, Table I). TNF- α immunostaining of the liver section of the sham group showed generally negative TNF- α reaction in hepatocytes and portal areas. IR increased TNF- α reaction in hepatocytes, inflammatory cells, and sinusoidal vessels in IR group. In IR+EA group, TNF- α activity was positive in inflammatory cells but decreased in hepatocytes and sinusoidal area. EA treatment reduced TNF- α expression to a level close to the sham group (Figure 1, TNF- α immunostaining).

Caspase-9 is an apoptosis marker and a member of Caspase family. It is expressed in many cell types and involved in Caspase activation: it binds to other apoptotic molecules and form the apoptosome complex, then Caspase-9 is activated. In the IR injury, the apoptosis is induced, therefore expression of Caspase-9 is increased²⁸. Tsai et al²⁹ studied apoptosis and expression of Caspase-9 in myocardial IR. They found that IR caused death of cardiomyocytes by increasing rate of apoptosis, which led to expression of cleaved Caspase-9. In a similar study conducted by Liu³⁰, Caspase-9 expression was significantly increased in ischemic group compared to sham group with increased apoptotic index in cardiomyocytes of ischemic group. In our study, statistical analysis showed histological score of Caspase-9 expression were increased after IR injury however EA treatment improved the scores ($p < 0.001$, Table I). In the Caspase-9 immune-stained of liver tissue, the expression was mostly negative in sham group. In IR group, Caspase-9 expression was increased after IR injury in hepatocytes and vascular endothelial cells. In IR+EA group, Caspase-9 reaction was positive in inflammatory cells, hepatocytes and sinusoidal area in the periportal and portal area. It was observed that EA treatment reduced the expression of Caspase-9 (Figure I, Caspase-9 immunostaining).

As a result, our findings showed that ellagic acid protected the integrity and structure of hepatic tissue by providing its antioxidant properties against hepatic IR.

Limitations

As a limitation in our study, we can affirm that a quantitative method would have been better to support the immunohistochemical study.

Conclusions

Ellagic acid reduces oxidative stress by increasing the antioxidant capacity of the liver as a result of increased oxidative stress after IR injury and may be an alternative treatment for preventing inflammation and cell damage after liver injury by affecting the cell degeneration signaling pathway.

Conflict of Interest

The Authors declare that they have no conflict of interests.

Funding

This study was not supported by any institute, governmental and non-governmental or any funding agency.

Authors' Contribution

Conceptualization: CD, FA; Methodology: FA; Validation: FA; Formal analysis: CD, FA; Investigation: CD, FA; Resources: FA; Data Curation: CD, FA; Writing - Original Draft: CD, FA; Writing - Review & Editing: FA; Visualization: FA; Supervision: CD, FA; Project administration: CD, FA.

Ethics Approval

Dicle University Animal Experimentation Ethics Committee approved this animal study (record number: 2022/38).

ORCID ID

C. Dođru: 0000-0002-5797-7926; F. Aşır: 0000-0002-6384-9146.

References

- 1) Huguet C, Gavelli A, Bona S. Hepatic resection with ischemia of the liver exceeding one hour. *J Am Coll Surg* 1994; 178: 454-458.
- 2) Lemasters JJ, Thurman RG. Reperfusion injury after liver preservation for transplantation. *Annu Rev Pharmacol Toxicol* 1997; 37: 327-338.
- 3) Konishi T, Lentsch AB. Hepatic Ischemia/Reperfusion: Mechanisms of Tissue Injury, Repair, and Regeneration. *Gene Expr* 2017; 17: 277-287.
- 4) Lee J, Kim YS, Lee J, Heo SC, Lee KL, Choi SW, Kim Y. Walnut Phenolic Extract and Its Bioactive Compounds Suppress Colon Cancer Cell Growth by Regulating Colon Cancer Stemness. *Nutrients* 2016; 8.
- 5) Ambigaipalan P, de Camargo AC, Shahidi F. Phenolic Compounds of Pomegranate Byproducts (Outer Skin, Mesocarp, Divider Membrane) and Their Antioxidant Activities. *J Agric Food Chem* 2016; 64: 6584-6604.
- 6) Saleem A, Husheem M, Härkönen P, Pihlaja K. Inhibition of cancer cell growth by crude extract and the phenolics of *Terminalia chebula* retz. fruit. *J Ethnopharmacol* 2002; 81: 327-336.
- 7) Uzar E, Alp H, Cevik MU, Fırat U, Evliyaoglu O, Tufek A, Altun Y. Ellagic acid attenuates oxidative stress on brain and sciatic nerve and improves histopathology of brain in streptozotocin-induced diabetic rats. *Neurol Sci* 2012; 33: 567-574.
- 8) Yang L, Inokuchi S, Roh YS, Song J, Looma R, Park EJ, Seki E. Transforming growth factor- β signaling in hepatocytes promotes hepatic fibrosis and carcinogenesis in mice with hepatocyte-specific deletion of TAK1. *Gastroenterology* 2013; 144: 1042-1054.e1044.
- 9) Inokuchi S, Aoyama T, Miura K, Osterreicher CH, Kodama Y, Miyai K, Akira S, Brenner DA, Seki E. Disruption of TAK1 in hepatocytes causes hepatic injury, inflammation, fibrosis, and carcinogenesis. *Proc Natl Acad Sci U S A* 2010; 107: 844-849.
- 10) Zheng TS, Flavell RA. Divinations and surprises: genetic analysis of caspase function in mice. *Exp Cell Res* 2000; 256: 67-73.
- 11) Draper HH, Hadley M. Malondialdehyde determination as index of lipid peroxidation. *Methods Enzymol* 1990; 186: 421-431.
- 12) Paglia DE, Valentine WN. Studies on the quantitative and qualitative characterization of erythrocyte glutathione peroxidase. *J Lab Clin Med* 1967; 70: 158-169.
- 13) Hillegass LM, Griswold DE, Brickson B, Albrightson-Winslow C. Assessment of myeloperoxidase activity in whole rat kidney. *J Pharmacol Methods* 1990; 24: 285-295.
- 14) Tasin C, Ermis I, Deveci E. Endothelin-1 and APAF-1 Expression in the Umbilical Cord of Placenta Previa Cases. *Anal Quant Cytopathol Histopathol* 2021; 43: 439-445.
- 15) Aşır F, Nergiz Y, Pala A. Vitamin E protected the mouse adrenal gland against immobilization stress. *Pol J Vet Sci* 2022; 25: 447-454.
- 16) Ermis I. Losartan Protects Ovarian Tissue Against Ischemia-Reperfusion An Immunohistochemical Study. *Anal Quant Cytopathol Histopathol* 2021; 43: 345-352.
- 17) Özgökçe Ç, Öcal A, Ermiş IS. Expression of NF- κ B and VEGF in normal placenta and placenta previa patients. *Advances in clinical and experimental medicine: official organ Wroclaw Medical University* 2022.

- 18) Ermis IS, Deveci E. Investigation of the Biochemical, Histopathological, and Immunohistochemical Effects of Honokiol on the Changes in the Chorioid Plexus After Traumatic Brain Injury in Rats. *Analytical and Quantitative Cytopathology and Histopathology* 2021; 43: 417-425.
- 19) Yükselmis Ö, Ermis IS. Effect of Melatonin on Peripheral Nerve Damage Resulting from Tibial Defect in Rats. *International Journal of Morphology* 2022; 40: 1035-1042.
- 20) Ozgokce C, Ocal A, Ermis IS, Deveci E. The Effect of Folic Acid on Bone and Bone Marrow Development of Deltamethrin Toxicity Treated During Pregnancy in Newborn Pup Rats. *Fresenius Environmental Bulletin* 2022; 31, 7604-7614.
- 21) Becker LB. New concepts in reactive oxygen species and cardiovascular reperfusion physiology. *Cardiovasc Res* 2004; 61: 461-470.
- 22) Sehirli O, Ozel Y, Dulundu E, Topaloglu U, Er-can F, Sener G. Grape seed extract treatment reduces hepatic ischemia-reperfusion injury in rats. *Phytother Res* 2008; 22: 43-48.
- 23) Sagara G, Ogikubo O, Takeyama H, Tada T, Suzuki N, Okamoto H, Otsuka T. Comparison of effects of ischemia period in rat limb ischemia/reperfusion injury. *Nagoya Med J* 2009; 50: 83-91.
- 24) Katoonizadeh A, Nevens F, Verslype C, Pirenne J, Roskams T. Liver regeneration in acute severe liver impairment: a clinicopathological correlation study. *Liver Int* 2006; 26: 1225-1233.
- 25) Miller MA, Zachary JF. Mechanisms and Morphology of Cellular Injury, Adaptation, and Death. *Pathologic Basis of Veterinary Disease* 2017: 2-43.e19.
- 26) Atalay S, Soylu B, Aykaç A, Öğünç AV, Çetinel Ş, Özkan N, Erzik C, Şehirli A. Protective effects of St. John's wort in the hepatic ischemia/reperfusion injury in rats. *Turk J Surg* 2018; 34: 198-204.
- 27) Shuh M, Bohorquez H, Loss GE, Jr., Cohen AJ. Tumor Necrosis Factor- α : Life and Death of Hepatocytes During Liver Ischemia/Reperfusion Injury. *Ochsner J* 2013; 13: 119-130.
- 28) Avrutsky MI, Troy CM. Caspase-9: A Multimodal Therapeutic Target With Diverse Cellular Expression in Human Disease. *Front Pharmacol* 2021; 12: 701301.
- 29) Tsai CF, Su HH, Chen KM, Liao JM, Yao YT, Chen YH, Wang M, Chu YC, Wang YH, Huang SS. Paeonol Protects Against Myocardial Ischemia/Reperfusion-Induced Injury by Mediating Apoptosis and Autophagy Crosstalk. *Front Pharmacol* 2020; 11: 586498.
- 30) Liu D. Effects of procyanidin on cardiomyocyte apoptosis after myocardial ischemia reperfusion in rats. *BMC Cardiovasc Disord* 2018; 18: 35.