

# Iatrogenic or fracture-related nerve injuries in supracondylar humerus fracture: is treatment necessary for nerve injury?

S. GUNER, N. GUVEN, S. KARADAS<sup>1</sup>, M.F. CEYLAN,  
U. TURKTAS, M.A. GOKALP, A. GOZEN

Department of Trauma and Orthopedic Surgery, Yuzuncu Yil University Medical School Hospital, Van, Turkey

<sup>1</sup>Department of Emergency Medicine, Yuzuncu Yil University Medical School Hospital, Van, Turkey

**Abstract. – BACKGROUND:** Supracondylar humerus fractures are very common types of elbow fractures in children between the ages of three and ten years. Totally displaced supracondylar humerus fractures can be associated with neurovascular injuries, and treatment can be complicated by iatrogenic neurovascular injury, compartment syndrome, malunion, and elbow stiffness

**AIM:** The aim of this study was to describe the clinical outcome of nerve injuries associated with supracondylar humerus fractures in children observed over a period of seven years.

**PATIENTS AND METHODS:** Children with displaced supracondylar humerus fracture who were treated with closed reduction and percutaneous cross K-wire fixation were reviewed retrospectively at the Medical School Hospital of Yuzuncu Yil University from May 2004 to October 2012.

**RESULTS:** There were 91 patients available for follow-up. Nerve injury was observed in 11 (12.1%) of 91 patients with supracondylar humerus fractures. In 10 (90.1%) of these 11 cases, nerve functions recovered completely (excellent outcome) and in one (9.9%) case partial recovery was seen (good outcome).

**CONCLUSIONS:** Iatrogenic or fracture-related nerve injury in a supracondylar humerus fracture is a benign condition which may be resolved spontaneously and observation appears to be a good and valuable method for treatment of this complication.

*Key Words:*

Nerve injury, Supracondylar humerus fracture, Treatment, Iatrogenic, Observation.

## Introduction

Supracondylar humerus fractures (SHF) are very common types of elbow fractures in children between the ages of three and ten years<sup>1,2</sup>. Totally displaced SHF can be associated with neurovascular injuries, and treatment may be

complicated by iatrogenic neurovascular injury, compartment syndrome, malunion, and elbow stiffness<sup>2,3</sup>. While iatrogenic nerve injury most frequently affects the ulnar nerve<sup>4</sup>, the radial and median nerves are frequently damaged by the fracture fragments<sup>5-7</sup> (Figure 1). Iatrogenic injury of the ulnar nerve has been observed in up to 20% of the cases treated with crossed K-wire<sup>8</sup>. In addition, radial pinning for SHF may cause injury in the radial and median nerve<sup>9-11</sup>.

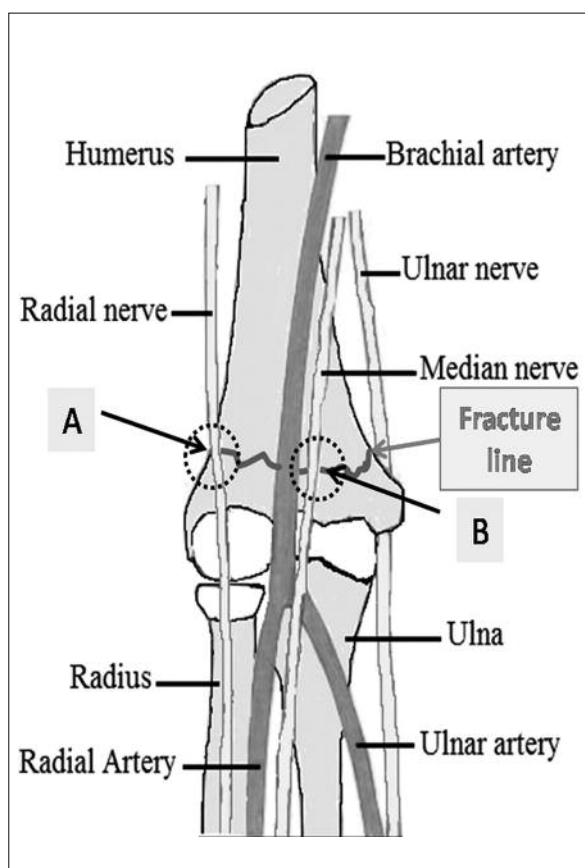
We analyzed the result and compared the rates of injuries of the ulnar, radial, and median nerves in a series of displaced SHF in children. The aim of this study was to describe the clinical outcome of nerve injuries associated with SHF in children seen over a period of seven years.

## Patients and Methods

We received approval of the Institutional Ethics Board for the study. Children with displaced SHF (Garthland type III) who were treated with closed reduction and percutaneous cross K-wire fixation were reviewed retrospectively at Medical School Hospital of Yuzuncu Yil University from May 2004 to October 2012. Gartland classification<sup>12</sup> is shown in Table I.

Name, age, gender, time of injury, date of presentation, cause of injury (simple fall or fall from height), and any history of previous surgery were recorded for all patients in the study. The inclusion criteria of the study were children with SHF of 2-12 years age and displaced SHF (Gartland type III). The exclusion criteria were undisplaced SHF and open fracture.

After closed reduction maneuver was applied, crossed K-wires were inserted percutaneously. The K-wires were bent outside the skin or cut



**Figure 1.** The radial and median nerves are frequently damaged by the fracture site (A and B).

**Table I.** The Gartland classification.

| Type | Displacement                        |
|------|-------------------------------------|
| I    | Undisplaced                         |
| II   | Displaced (posterior cortex intact) |
| III  | Totally displaced                   |

**Table II.** Classification of nerve injury according to Brich at al (MTP: Muscle power test, ST: Sensation test).

| Grade     | Nerve function   | Comments  |
|-----------|--|---|
| Excellent | MPT: normal (grade 5)<br>ST: Normal  | Normal  |
| Good      | MPT: Grade 4<br>ST: Minimal alteration   | Essentially normal  |
| Fair      | MPT: Grade 3<br>ST: Decreased texture recognition and two-point discrimination | Skin atrophy, brittle nails and possible growth disturbance |
| Poor      | MPT: Grade 2 or 1<br>ST: Pain  | As above  |

under the level of the skin. Exploration of the injured nerve was not performed. A long arm cast was applied after operation. Implant removal was performed together with cast removal when callus formation was seen in fracture sites where K-wires had been bent outside the skin. In children who had the K-wires cut below the level of the skin, implants were removed on a day-surgery basis 3 months later.

### **Surgical Technique**

Under general anesthesia in a supine position on the operating table, the closed reduction maneuver was implemented under fluoroscopic guide. With the elbow in hyperflexion position, a K-wire was inserted from the lateral condyle of distal humerus across the lateral cortex engaging the medial cortex. After the ulnar nerve was palpated the elbow was extended to a position of less than 90 degrees. The medial K-wire was then located to the beginning of the medial epicondyle to engage the lateral cortex again in a hyperflexed elbow position.

### **Neurologic Evaluation**

Preoperative and postoperative neurologic examinations of all patients were performed and recorded for ulnar, median and radial nerves. The operation findings and details of the surgical process were recorded.

### **Follow-up**

Post-operative follow-up was performed at four weeks, two months, three months and subsequently every month until full recovery. In addition, electromyography (EMG) evaluation of motor unit was performed at 3 and 6 months after the surgery. The clinical results at the last follow-up were assessed according to the criteria of Birch, Bonney and Wynn Parry<sup>13</sup> and graded as excellent, good, fair or poor (Table II).

**Table III.** Details of patients with nerve injury.

| Case | Age | Gender | Nerve injury     | Etiology         | Recovery time | Outcome (according to Brich at al) |
|------|-----|--------|------------------|------------------|---------------|------------------------------------|
| 1    | 9   | Male   | Ulnar            | Iatrogenic       | 4 months      | Excellent                          |
| 2    | 7   | Female | Ulnar and radial | Fracture-related | 12 months     | Excellent                          |
| 3    | 3   | Male   | Ulnar            | Fracture-related | 8 months      | Excellent                          |
| 4    | 2   | Female | Ulnar            | Fracture-related | 5 months      | Good                               |
| 5    | 8   | Male   | Ulnar            | Iatrogenic       | 6 months      | Excellent                          |
| 6    | 12  | Male   | Ulnar and radial | Fracture-related | 11 months     | Excellent                          |
| 7    | 11  | Male   | Radial           | Fracture-related | 3 months      | Excellent                          |
| 8    | 4   | Female | Ulnar            | Fracture-related | 6 months      | Excellent                          |
| 9    | 10  | Male   | Median           | Fracture-related | 5 months      | Excellent                          |
| 10   | 7   | Male   | Ulnar            | Iatrogenic       | 8 months      | Excellent                          |
| 11   | 8   | Male   | Ulnar            | Fracture-related | 6 months      | Excellent                          |

**Results**

There were 91 patients available for follow-up. Nerve injury was observed in 11 (12.1%) of 91 patients with SHF. In patients with nerve injury, the mean recovery time was 6.7 months (range 3-12 months). The mean age of the 11 patients (3 female, 8 male) was 7.4 years (range 2-12). Concomitant injuries included one ipsilateral distal radius fracture and one ipsilateral bicondylar fracture of humerus. A closed reduction maneuver was successful in all of the patients. K-wires were removed at the 4<sup>th</sup> week in three cases, the 5<sup>th</sup> week in two case and the 6<sup>th</sup> week in five cases. Final EMG studies showed complete recovery in ten cases.

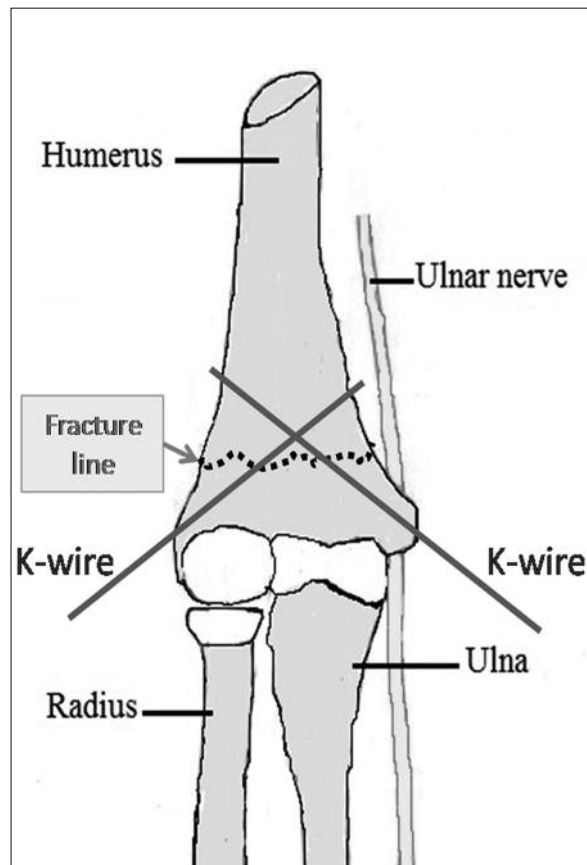
Iatrogenic nerve complication was seen in three patients (3.3%), and noted as two ulnar and one radial nerve injuries. Fracture-related nerve injuries were seen in eight (8.8%) patients (six ulnar, three radial and one median-two patients had both ulnar and radial nerves injury) (Table III). We did not observe any deep infections after surgical treatment. Early removal of implant (in cases of irritation of the nerve) and early exploration were not applied.

In 10 (90.1%) of 11 cases, nerve functions completely recovered (excellent outcome) and in one (9.9%) case partial recovery was seen (good outcome) according to the criteria of Birch (Table III).

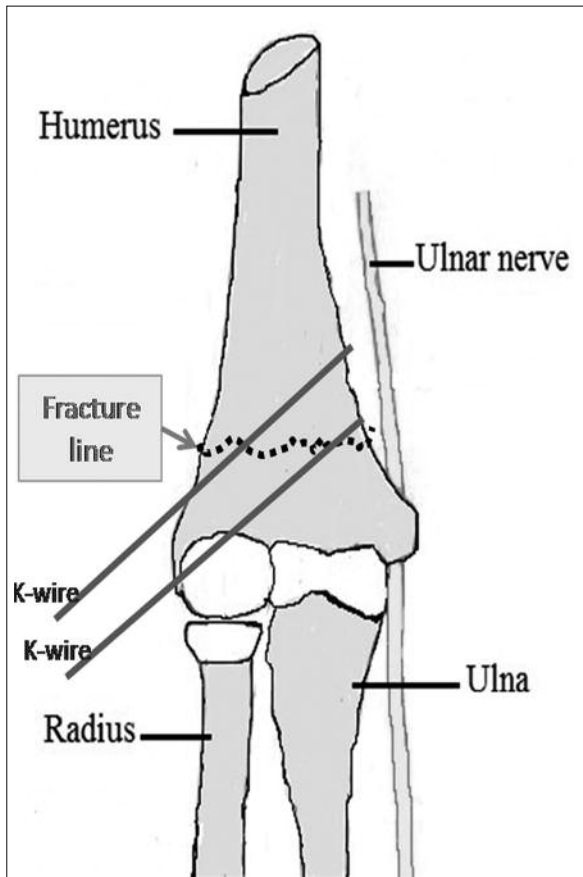
**Discussion**

There have been many variations of suggested pinning techniques for treatment of SHF. Cross-pins (Figure 2), lateral pins (Figure 3) and cross-

pins (Figure 4) are used in the treatment of SHF. Swenson<sup>14</sup>, Flynn et al<sup>15</sup>, and Nacht et al<sup>16</sup> recommend using cross-two pins, which are placed through the medial and lateral epicondyles. Biomechanically, fixation provided by the two lateral K-wire is less safe in comparison to the cross-pins. Fixation of fracture fragment by two lateral



**Figure 2.** Fixation of fracture fragment by cross-two pins, which are placed through the medial and lateral epicondyles.



**Figure 3.** Fixation of fracture fragment by two lateral K-wire.

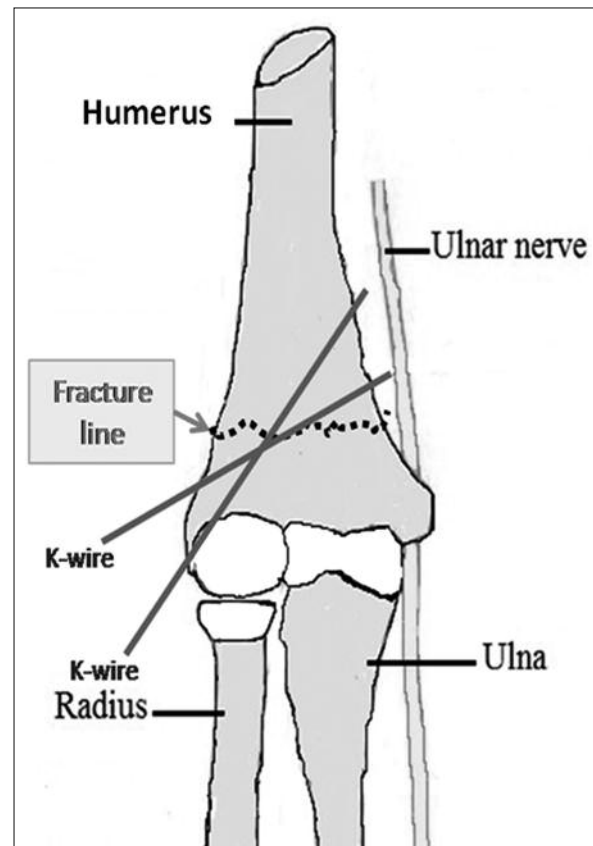
K-wire may allow rotation of the fracture fragment. It has been discussed that insertion of two lateral cross-pins will provide a biomechanically stable fixation along with avoiding the risk of ulnar nerve injury<sup>9,17</sup>.

Nerve injuries after SHF may occur primarily because of tenting or entrapment of the nerve on the sharp proximal humeral part. Iatrogenic injuries may occur either during closed manipulation or percutaneous pinning of the fracture fragments or rarely during open procedures<sup>8,18,19</sup>. Wilkins et al reported the frequency of neurologic complication after percutaneous pinning from 2 to 3%<sup>20</sup>. Flynn et al<sup>15</sup>, in a series of 72 cases, had only one (1.4%) postoperative ulnar nerve palsy which recovered spontaneously in six weeks<sup>15</sup>. Royce et al<sup>21</sup> had three (2%) cases of postoperative ulnar nerve injury occurred with a medial pin<sup>21</sup>. Our incidence of iatrogenic ulnar nerve injury after percutaneous pinning of the SHF was 3.3% and this ratio compatible with the literature.

There are several controversies about treatment options for nerve injury after percutaneous pinning. Observation, medial K-wire removal, medial K-wire reposition, exploration + medial K-wire reposition, exploration + reposition + cubital retinacular release were recommended by different authors<sup>8,15,18</sup>. We did not attempt any surgical intervention and only observed patients who had suffered nerve injury. In our study, full recovery at 3-12 months (mean 6.7 months) was observed in nine cases and partial recovery was seen at five months in two cases. It appears that the recovery period varies according to the sensory or motor deficit of the nerve and the degree of nerve damage.

### Conclusions

Iatrogenic or fracture-related nerve injuries in SHF are a benign condition which may be resolved spontaneously and observation appears to be a good and valuable method for the treatment of this complication.



**Figure 4.** Fixation of fracture fragment by cross two lateral K-wire.

**Statement of Interest**

The Authors declare that no financial arrangement with any product or rival product featured in the article, sources of funding, institutional affiliations, and any possible financial or personal conflicts of interest.

**References**

- 1) HANLON CR, ESTES WL. Fractures in childhood, a statistical analysis. *Am J Surg* 1954; 87: 312-323.
- 2) BATTAGILA TC, ARMSTRONG DG, SCHWEND RM. Factors affecting forearm compartment pressures in children with supracondylar fractures of the humerus. *J Pediatr Orthop* 2002; 22: 431-439.
- 3) ROCKWOOD CA, WILKINS KE, BEATY JH. Fractures in children, vol 3. Lippincott-Raven, Philadelphia, 1996.
- 4) SKAGGS DL, HALE JM, BASSETT J, KAMINSKY C, KAY RM, TOLO VT. Operative treatment of supracondylar fractures of the humerus in children. The consequences of pin placement. *J Bone Joint Surg Am* 2001; 83: 735-740.
- 5) DORMANS JP, SOUILLANTE R, SHARF H. Acute neurovascular complications with supracondylar humerus fractures in children. *J Hand Surg Am* 1995; 20: 1-4.
- 6) CRAMER KE, GREEN NE, DEVITO DP. Incidence of anterior interosseous nerve palsy in supracondylar humerus fractures in children. *J Pediatr Orthop* 1993; 13: 502-505.
- 7) BROWN IC, ZINAR DM. Traumatic and iatrogenic neurological complications after supracondylar humerus fractures in children. *J Pediatr Orthop* 1995; 15: 440-443.
- 8) LYONS JP, ASHLEY E, HOFFER MM. Ulnar nerve palsies after percutaneous cross-pinning of supracondylar fractures in children's elbows. *J Pediatr Orthop* 1998; 18: 43-45.
- 9) BRAUER CA, LEE BM, BAE DS, WATERS PM, KOCHER MS. A systematic review of medial and lateral entry pinning versus lateral entry pinning for supracondylar fractures of the humerus. *J Pediatr Orthop* 2007; 27: 181-186.
- 10) KOCHER MS, KASSER JR, WATERS PM, BAE D, SNYDER BD, HRESKO MT, HEDEQUIST D, KARLIN L, KIM YJ, MURRAY MM, MILLIS MB, EMANS JB, DICHTEL L, MATHENEY T, LEE BM. Lateral entry compared with medial and lateral entry pin fixation for completely displaced supracondylar humeral fractures in children. A randomized clinical trial. *J Bone Joint Surg Am* 2007; 89: 706-712.
- 11) OMID R, CHOI PD, SKAGGS DL. Supracondylar humeral fractures in children. *J Bone Joint Surg Am* 2008; 90: 1121-1132.
- 12) GARTLAND JJ. Management of supracondylar fractures of the humerus in children. *Surg Gynecol Obstet* 1959; 109: 145-154.
- 13) BIRCH R, BONNEY G, WYNN PARRY CB. Surgical disorders of the peripheral nerves Edinburgh: Churchill Livingstone, 1998; pp. 235-244.
- 14) SWENSON AL. Treatment of supracondylar fractures of the humerus by Kirschner wire trans-fixation. *J Bone Joint Surg Am* 1948; 30: 993-997.
- 15) FLYNN JC, MATTHEWS JG, BENOIT RL. Blind pinning of displaced supracondylar fractures of the humerus in children. *J Bone Joint Surg* 1974; 56: 263-272.
- 16) NACHT JL, EKER ML, CHUG SM, LOTKE PA, DAS M. Supracondylar fracture of the humerus in children treated by closed reduction and percutaneous pinning. *Clin Orthop Relat Res* 1983; 177: 203-209.
- 17) OTSUKA NY, KASSER JR. Supracondylar Fractures of the Humerus in Children. *J Am Acad Orthop Surg* 1997; 5: 19-26.
- 18) BROWN IC, ZINAR DM. Traumatic and iatrogenic neurological complications after supracondylar humerus fractures in children. *J Pediatr Orthop* 1995; 15: 440-443.
- 19) GOSENS T, BONGERS KJ. Neurovascular complications and functional outcome in displaced supracondylar fractures of the humerus in children. *Injury* 2003; 34: 267-273.
- 20) WILKINS KE, BEATY JH, CHAMBERS HG, TONIOLO RM. Fractures and dislocations of the elbow region. In: Rockwood CA Jr, Wilkins KE, Beaty JH. Ed. Fractures in Children. Philadelphia: Lippincott-Raven, 1996; pp. 653-904.
- 21) ROYCE RO, DUTKOWSKY JP, KASSER JR, RAND FR. Neurologic complications after K-wire fixation of supracondylar humerus fractures in children. *J Pediatr Orthop* 1991; 11: 191-194.