

# Trigeminal and facial schwannoma: a case load and review of the literature

P. GENNARO, E. NASTRO SINISCALCHI, G. GABRIELE, P. CASCONI

Department of Maxillofacial Surgery, School of Medicine, Sapienza University of Rome, Rome, Italy

**Abstract.** – Schwannoma or neurilemmoma are benign tumours originating from Schwann cells of the nerve sheath. They can arise from any peripheral, cranial, or autonomic nerve. The treatment of extracranial head and neck schwannomas is surgical and the approach depends on the location and extent of the tumor and the nerve involved. The Authors report the case load of surgical managements of three different extracranial nerve schwannomas involved facial and trigeminal nerves, and a review of the literature.

*Key Words:*

Schwannoma, Neurilemmoma, Trigeminal, Facial, Maxillofacial, Surgery.

## Introduction

Schwannoma or neurilemmoma are benign tumours originating from Schwann cells of the nerve sheath. Approximately 25-40% of all schwannomas are seen in the soft tissues of the head and neck, often originate from the acoustic nerve<sup>1,2</sup>. They can arise from any peripheral, cranial, or autonomic nerve. These tumors can simulate any primary and metastatic disease in the head and neck. The treatment of extracranial head and neck schwannomas is surgical and the approach depends on the location and extent of the tumor and the nerve involved<sup>3</sup>.

We report one case of intraparotid facial nerve schwannoma and two cases of extracranial trigeminal schwannoma involving the first and the second branch of V<sup>th</sup> cranial nerve.

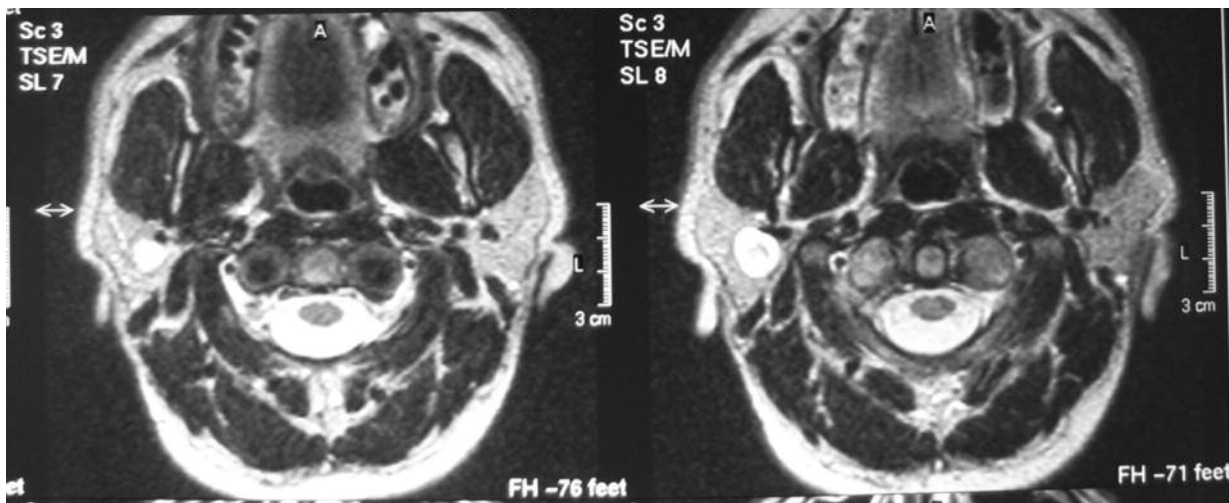
### **Case I: Intraparotid Facial Nerve Schwannoma**

A 48-year-old male presented with a 5-year history of pain in his right parotid region without any sign of swelling of the parotid gland, or weakness of the facial nerve. The patient had been previously visited by a ENT clinician who made an Ecography which did not report any pathological sign. A magnetic resonance imaging

(MRI) was then performed. The imaging revealed the presence of a mass suggesting an intraparotid neoplasm (Figure 1). Preoperative fine-needle aspiration biopsy was performed, but did not allow a clear diagnosis. The patient was taken to the operating theatre for parotidectomy with facial nerve preservation. After the skin flap was elevated, the mass itself was detected. It appeared closely related to the main trunk of the facial nerve (Figure 2). A biopsy of nonstimulating portion of the nerve, by the use of a nerve stimulator, was performed. Istological diagnosis of schwannoma was confirmed. Since the patient had normal facial nerve function, conservative management was followed, and the deep portion of the mass was maintained. Postoperatively the patient developed a low grade facial nerve dysfunction (House-Brackmann grade II) which decreased three months later and the lack of pain of the parotid region. The immunohistochemical exam of the mass confirmed the diagnosis of schwannoma. A MRI was performed one month later and one year later. Both the exams showed the presence of a mass along the deep portion of the parotid gland, smaller than previous, with no vascularization (Figure 3). Clinical and radiological follow up is still performing.

### **Case II: Intraorbital Trigeminal Nerve Schwannoma**

A 28-year-old female presented with a 1-year history of a right diplopia with a retrobulbar pain. Sonographically a retrobulbar mass was detected. The ophthalmologist confirmed the presence of diplopia and pain most associated with the upper side movements. The MRI showed an intracanal retrobulbar mass which dislocated the rectus inferior and rectus medialis muscles (Figure 4). The patient was taken to the operating theatre for the enucleation of the mass. A trans-conjunctival incision of the right lower eyelid followed by a lateral osteotomy of the orbit was performed. The mass was then detected and removed preserving the optic nerve, which had



**Figure 1.** Case 1: MRI reveal the presence of an intraparotid mass.

been dislocated by the neoplasm (Figure 5). The histopathological pattern confirmed the diagnosis of schwannoma.

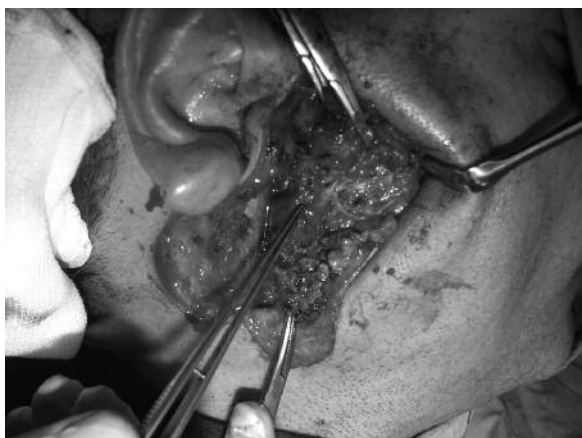The patient reported the regression of both diplopia and pain with an acceptable aesthetic outcome. The post-operative MRI showed no anomalies (Figure 6).

**Case III: Mandibular Schwannoma**

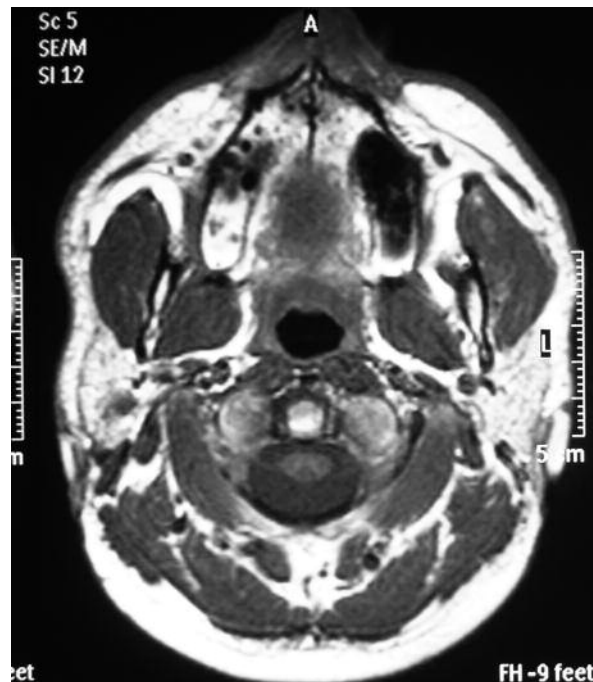A 34-year-old female presented with a radiologically diagnosis of mandibular cyst. The X ray showed an osteolytic area involving the left body and part of the left ramus of the mandible (Figure 7). An open biopsy was then performed and the histological features suggested the presence of a schwannoma. The CT scan confirmed the presence of an intrabony lesion of the left body of the mandible and the ramus (Figure 8). The MRI

showed a mass arising from the infratemporal and pterigoid space, involving the mandible from the Spix foramen to the entire left body in its inner part (Figure 9).

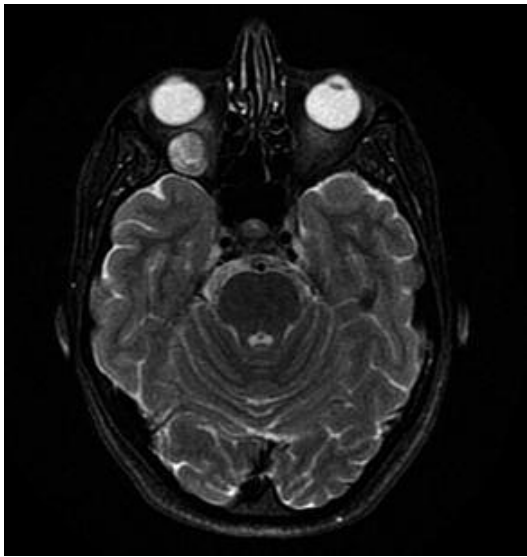
The patient was taken to the operating room and operated with a combined maxillofacial-neurosurgical approach. A preauricular incision extended to the submandibular area was performed. A split osteotomy of the angle of the mandible was made, following the preplating of the angle.



**Figure 2.** Case 1: the schwannoma is noticeable near the main trunk of the facial nerve.



**Figure 3.** Case 1: post-operative MRI show the complete asportation of the tumor.



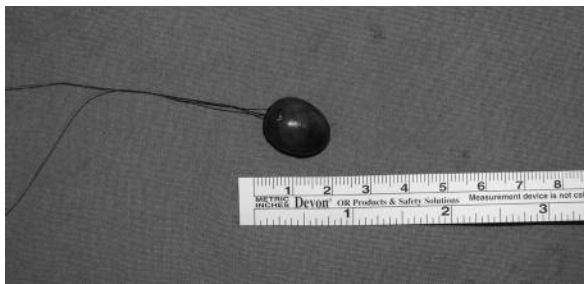
**Figure 4.** Case 2: MRI showing an intraconal retrobulbar mass.

A temporo-zygomatic door was then performed in order to detect the mass. This approach widely exposed the anterior wall of the tumor (Figure 10). The neoplasm was then excised with the principal root of the third branch of the trigeminal nerve (V3) from the oval foramen to the internal mandibular bone.

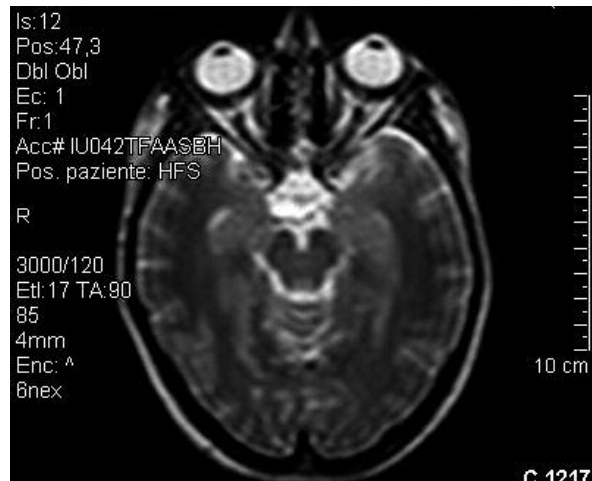
The post-operative MRI did not show any evidence of disease (Figure 11). The MRI 2 years later was negative and the patient showed a good aesthetic and functional outcome.

### Discussion

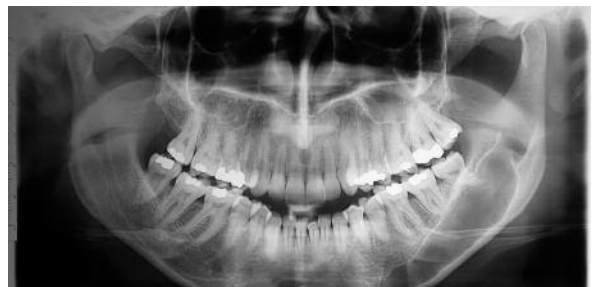A schwannoma or neurilemmoma is a benign, slow growing, tumour originating from Schwann cells. Approximately 25-40% of all schwannomas are seen in the soft tissues of the head and neck, of-



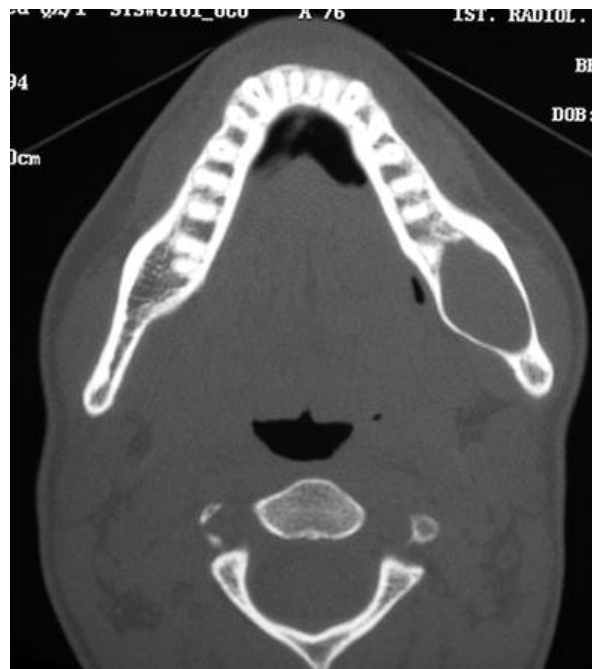**Figure 5.** Case 2: The infraorbital mass asported. Histopathological pattern confirmed the diagnosis of schwannoma.



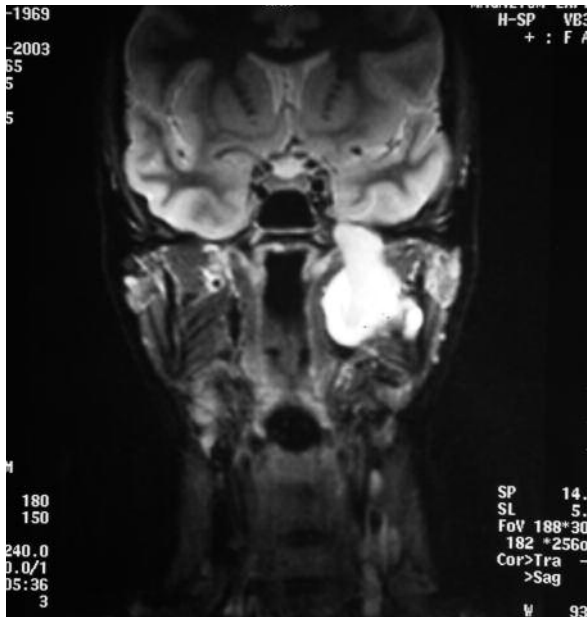
**Figure 6.** Case 2: Post-operative MRI showing the complete removal of the neoplasm.



**Figure 7.** Case 3: RX-OPT scan revealing an osteolytic area involving the left body and part of the left ramus of the mandible.



**Figure 8.** Case 3: Ct scan confirming the presence of an intrabony lesion of the left body of the mandible and the ramus.

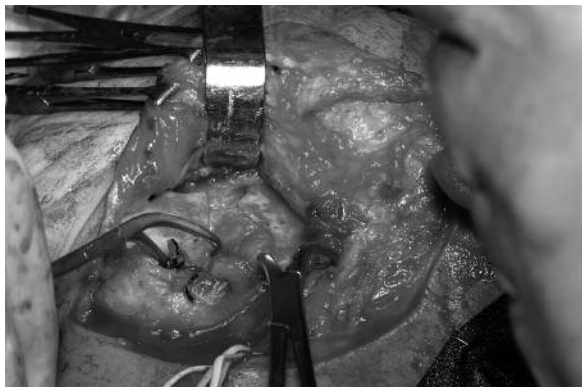


**Figure 9.** Case 3: MRI showing the mass arising from the infratemporal and pterigoid space, involving the mandible from the Spix foramen to the entire left body in its inner part.

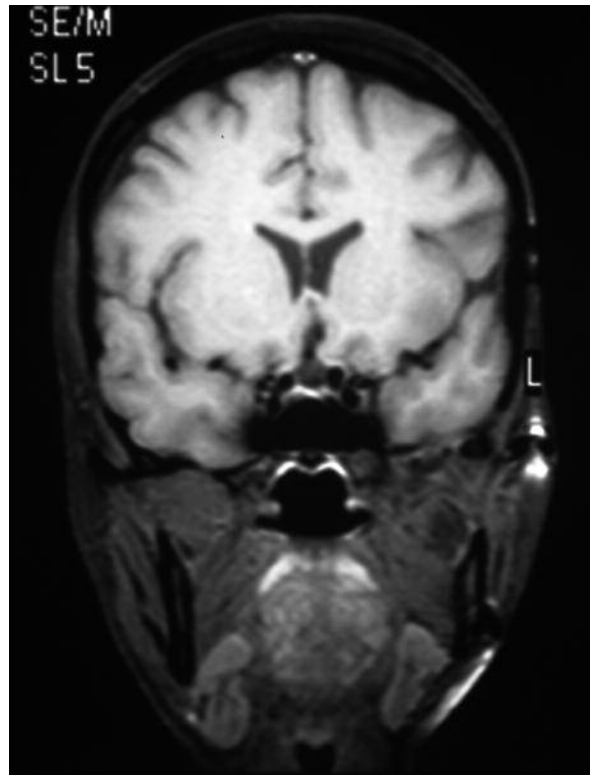
ten originate from the acoustic nerve<sup>2</sup>. They can arise from any peripheral, cranial, or autonomic nerve. Of the 12 cranial nerves, only the olfactory and optic nerves do not develop schwannomas since they lack Schwann cells in their sheaths<sup>4,5</sup>.

The treatment of extracranial head and neck schwannomas is surgical and the approach depends on the location and extent of the tumor and the nerve involved (art head e neck).

Facial nerve schwannoma (FNS) is a rare event. It can occur at any point along its course from the cerebello-pontine angle to its peripheral branches in the face<sup>6,7</sup>. Schwannoma most commonly affect



**Figure 10.** Case 3: The neoplasm was excided with the principal root of the third branch of the trigeminal nerve from the oval foramen to the internal mandibular bone.



**Figure 11.** Case 3: Post-operative MRI showing no more evidence of disease.

the intracranial course of the facial nerve<sup>8,9</sup>. Primary intraparotid facial nerve tumours are a rare entity (Qin craniomaxillo). Its typical presentation is a slow growing, painless mass mimicking a pleomorphic adenoma. It may present with pain or facial palsy. The rate of facial nerve palsy in intraparotid FNS is about 20-27%<sup>10,11</sup>.

Preoperative diagnosis of FNS is important but rarely achieved. Sonography, computed tomography (CT) and Magnetic Resonance (MRI) are not sufficient to make the diagnosis. Fine needle aspiration (FNA) is not able as well in making the pre-operative diagnosis. The definitive diagnosis of FNS in the parotid is made by histological examination of the resected specimen or an intraoperative biopsy. If a malignant schwannoma is diagnosed, a radical excision should be made<sup>8</sup>.

Once the diagnosis of intraparotid FNS has been made, definitive management depends on several factors. Many Authors focus their attention on the several factors, like extent and biological behavior of the tumor, preoperative facial nerve function according to the House-Brackmann grade, and location in relation to the intraparotid facial nerve main trunk<sup>6,8,12</sup>.

This clinical case has been conservatively managed according to the literature. Good preoperative facial nerve function and close relationship between the mass and the nerve, suggested us to perform only a superficial enucleation of the mass and a clinically and radiographically follow up. The radical excision of the tumor, in fact, could have been impaired facial function.

The patient is still following, as suggested by literature, clinically as well as radiographically with MRI and does not present any sign of facial impairment.

Extracranial fifth cranial nerve schwannomas are a rare entity as well. They may arise from the trigeminal nerve root, Gasserian ganglion, or one of the three peripheral branches of the trigeminal nerve<sup>13,14</sup>. While the treatment of facial schwannoma depends on several factors mainly related to the extension and the impairment of mimic function, treatment of the trigeminal tumor is surgical. The approach depends mainly on the extension of the mass according to the needs of exposure and complete enucleation of the mass. A combined maxillofacial-neurosurgical approach is often needed.

Preoperative diagnosis of schwannoma is always difficult. That's why, for facial tumor, the surgeons have often to convert intraoperatively the intervention. One of the major characteristic of intraparotid facial nerve schwannoma is the difficulty, during a normal procedure of dissection of the parotid gland, to detect the facial nerve and its main trunk which is often dislocated by the mass. As a consequence, when the mass is so closely related to the facial nerve main trunk, and its anatomical relationship is not clear, a diagnosis of intraparotid facial nerve (IFN) schwannoma has to be suspected. In this case, an intraoperative biopsy must be done and the decision of how to manage the mass with the gland itself depend on the presence of the nature of the lesion, preoperative presence of pain and eventually FN palsy. Since the preoperative exams are not enough in such cases to determine the correct diagnosis, patients should be informed before the operation about the possibility of converting the treatment and enucleate only the superficial mass, leaving the deep portion inside, in order to preserve the facial nerve function.

Any decision must to be kept according to the needs of resolution of pain, and swelling but, above all of preservation of facial nerve function.

Conversely, the needs of functional preservation of trigeminal nerve are less important in such surgery, and patients are always informed about this event.

For these reason, we think that the superficial parotidectomy has to be preferred in these cases. With this procedures, in fact, the detection of facial nerve is the first step in order to avoid neural lesions. Other techniques, such as partial resection, should be avoided because of the possibility of cause neural damages.

## References

- 1) LUKSIC I, MULLER D, VIRAG M, MANOJLOVIC S, OSTOVIC KT. Schwannoma of the tongue in a child. *J Craniomaxillofac Surg* 2011; 39: 441-444.
- 2) ENOZ M, SOUGLU Y, ILHAN R. Lingual schwannoma. *J Cancer Res Ther* 2006; 2: 76-78.
- 3) KARKAS AA, SCHMERBER SA, BETTEGA GW, REYT EP, RIGHINI CA. Osteoplastic maxillotomy approach for infraorbital nerve schwannoma, a case report. *Head Neck* 2008; 30: 401-404.
- 4) HAMZA A, FAGAN JJ, WEISSMAN JL, MYERS EN. Neurilemmomas of the parapharyngeal space. *Arch Otolaryngol Head Neck Surg* 1997; 123: 622-626.
- 5) LEU YS, CHANG KC. Extracranial head and neck schwannomas: a review of 8 years experience. *Acta Otolaryngol* 2002; 122: 435-437.
- 6) MEHTA RP, DESCHLER DG. Intraoperative diagnosis of facial nerve schwannoma at parotidectomy. *Am J Otolaryngol* 2008; 29: 126-129.
- 7) ONCELL S, ONAL K, ERMETE M. Schwannoma (neurilemmoma) of the facial nerve presenting as a parotid mass. *J Laryngol Otol* 2002; 116: 642-643.
- 8) FYRMPAS G, KONSTANTINIDIS I, HATZIBOUGIAS D, VITAL V, CONSTANTINIDIS J. Intraparotid facial nerve schwannoma: management options. *Eur Arch Otorhinolaryngol* 2008; 265: 699-703.
- 9) ELAHI MM, AUDET N, ROCHON L, BLACK MJ. Intraparotid facial nerve schwannoma. *J Otolaryngol* 1995; 24: 364-367.
- 10) BRETLAU P, MELCHORS H, KROGDAHL A. Intraparotid neurilemmoma. *Acta Otolaryngol* 1983; 95: 382-384.
- 11) JAEHNE M, USSMULLER J. Clinical aspects and therapy of extratemporal facial neurinoma. *HNO* 2001; 49: 264-269.
- 12) ALICANDRI-CIUFELLI M, MARCHIONI D, MATTIOLI F, TRANI M, PRESUTTI L. Critical literature review on the management of intraparotid facial nerve schwannoma and proposed decision-making algorithm. *Eur Arch Otorhinolaryngol* 2009; 266: 475-479.
- 13) SAMII M, MIGLIORI MM, TATAGIBA M, BABU R. Surgical treatment of trigeminal schwannoma. *J Neurosurg* 1995; 82: 711-718.
- 14) SERVADEI F, ROMANO A, FERRI A, MAGRI AS, SESENA E. Giant trigeminal schwannoma with parapharyngeal extension: report of a case. *J Craniomaxillofac Surg* 2012; 40: e15-18.