

# Should fat graft be recommended in tendon scar treatment? Considerations on three cases (two feet and a severe burned hand)

M.R. COLONNA, M.C. SCARCELLA, F.do STAGNO D'ALCONTRES, G. DELIA, F. LUPO

Department of Clinical and Experimental Medical and Surgical Specialties and Odontostomatology, Section of Stomatology and Plastic Surgery, University of Messina, Italy

**Abstract. – OBJECTIVES:** Lipostructure has been reported as a successful ancillary tool for surgery in tenolysis procedures, but to date no reports of its capability to resolve tendon adherence without further surgery have been reported. The aim of this study is to highlight the role of lipografting in the treatment of tendon and joint adhesences.

**PATIENTS AND METHODS:** In our experience, we started treating important tendon adhesences together with nerve entrapment on the dorsal aspect of the foot in two cases and in a severe burned hand.

**RESULTS:** We achieved good results both in terms of function and sensory recovery. A twenty four month follow up showed good maintenance of the ROM. We also reported gaining of almost 30-40 degrees of a flexion contracure in the second finger of a burned hand, minimizing further surgery for scar contracure and tenoarthrolysis, with a stable follow up.

**CONCLUSIONS:** We suggest that prior to refer to surgery scars involving tendons as well as joints should be considered for lipografting.

*Key Words:*

Tendon, Adhesences, Tenolysis, Lipografting.

## Introduction

Adherence of tendons is a common complication of tendon surgery, and becomes an important problem when skin and deep tissue, as well as bone, are involved. Tenolysis is required to remove scar and free tendons to their original ROM, but this surgery is affected by a moderate/high level of incidence of relapse<sup>1</sup>. Among the methods the surgeon can apply to reduce further scarring, steroid injections and anti-adherence materials<sup>2</sup> have been attempted: steroids having proven poorly effective, whilst antiadherent materials, even if effective in the literature as

well as in the corresponding author's direct experience<sup>3</sup>, remain too expensive. Another interesting approach is represented by bringing adipofascial gliding flaps, such as omentum<sup>4</sup> or perforator flaps<sup>5</sup>.

Damgaard and Siemssen<sup>1</sup> reported a case where recurrent adherence of extensor foot tendons was treated successfully with tenolysis supplemented by autologous fat transplant.

In this study we applied successfully lipografting to two cases of dorsal foot compartment adhesences and one case of hand burn scar (the volar surface of radial long fingers), without need for further surgery; we suggest that this regenerative approach could be considered as a first choice of treatment for tendon adhesences

## Materials and Methods

Three cases (two feet and one hand) complex scars with tendon adhesences were treated with lipografting.

From 500 to 600 ml of a solution containing 50 ml of 2% lidocaine and 1 ml of 1:1000 epinephrine per litre of saline was injected into the subcutaneous fat of trochanteric regions. Manual liposuction was then performed using a 12-gauge (2.7 mm), 12-hole (12 mm), 25 cm-long cannula connected to a syringe pulling a steady 300 mmHg vacuum suction. To separate the graft from the serum and tumescent solution, the collected lipoaspirate was put to settle on a side table in the first two cases or centrifugated and decanted to separate the liquid parts in the third case.

The fat cells were transferred into a closed system to the injection syringe. Small amounts of cells were injected throughout the scar and over as well as below the retracted tendons.

### Case 1

A 59 yr old patient had suffered from a traction engine injury of his right lower limb. He was treated also with Hyperbaric Oxygen and a ugly scar developed on his dorsal forefoot together with hypoanesthesia and extensor tendons adherence.

We stated to treat both scar and tendon adherence as well as nerve scar entrapment starting with a lipostructure (Figures 1 to 4).

### Case 2

After a car accident, a 21 yr old girl suffering from degloving and open fractures of the first three tibial rays of her left foot dorsum, was debrided and covered with <sup>TM</sup>Integra, the fractures having been synthesized with K wires.

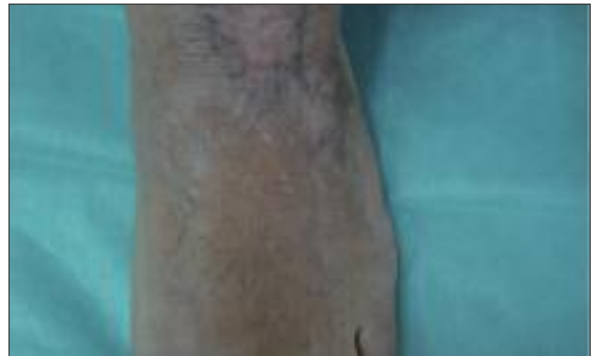The dermal scaffold was then grafted with a STSG.

One year later, a ugly pigmented and retracted scar involving the underlying tendons and bones, was treated with lipografting in three sessions and immediately after with LASER (Erbium-Yag) sessions to reduce hyperpigmentation with a renewal of dermal component (Figure 5-9). In both cases, we did not use limb exanguination.

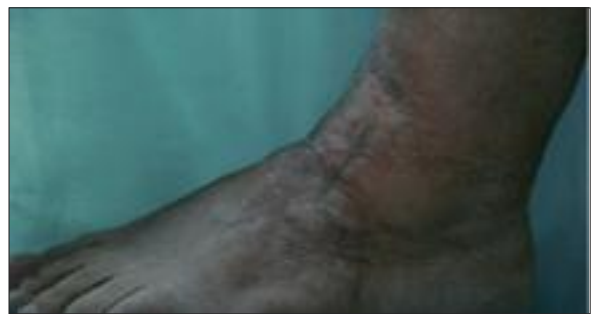### Case 3

A 28 yr old man had suffered from a flamethrower assault and developed retracting scars involving the whole body and particularly his face and hands. He had been treated with distal segments amputation of his right thumb and all the long fingers but the right index, which showed a PIP and DIP ROM less than 5 degrees. A marked hypoesthesia of the index pulp was registered, too.

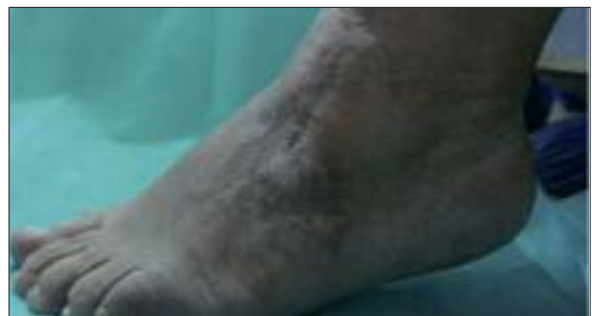We decided to start with lipostructure to release burn scar contractures involving the face, and to include this finger in our previous experience gained on the lower limb.



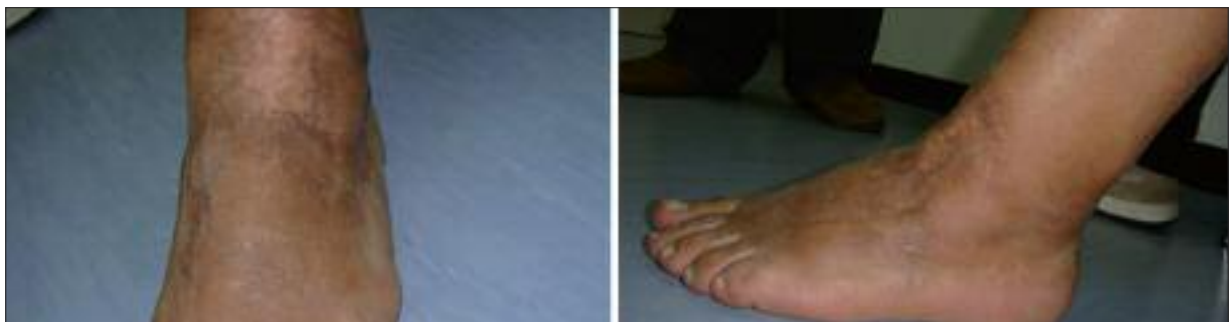**Figure 1.** Our first two case: a painful retracting scar of the proximal forefoot from a farm accident.



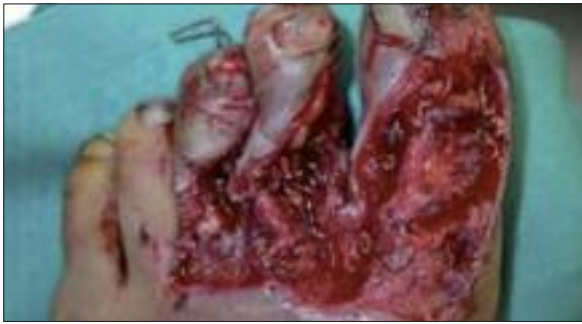**Figure 2.** Tendon adhesions and scars of the dorsal aspect. The patient also complained of paresthesia in the territory distal to the scar.



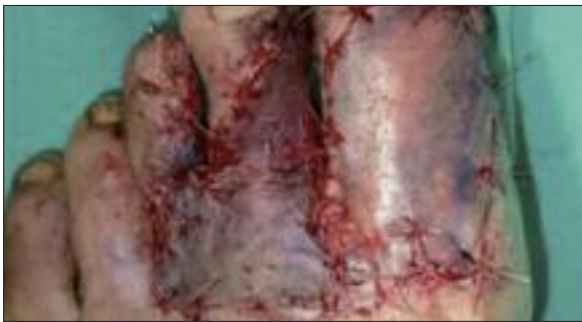**Figure 3.** ROM limitation.



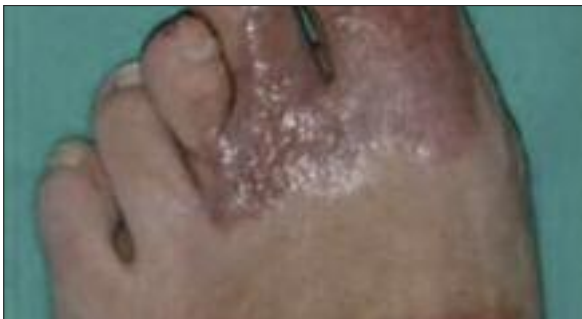**Figure 4.** Two months after simple one step lipografting. A complete scar release together with important nervous recovery has been gained.



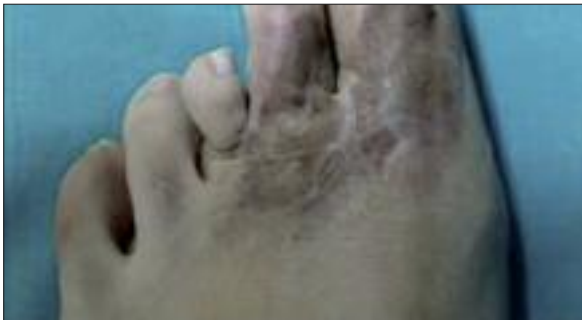**Figure 5.** Our second case: a 23 yr old girl suffering from three rays scalping and multiple exposed bone fractures.



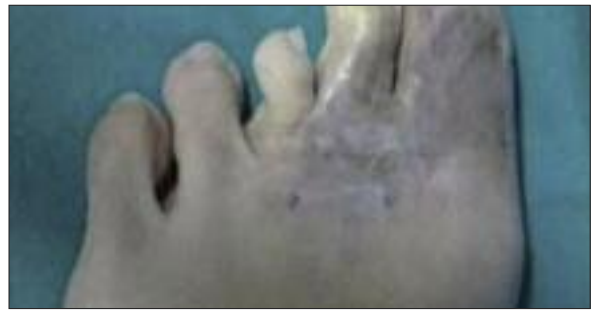**Figure 6.** Result after bone reduction, covering with dermal regeneration template and STSGs.



**Figure 7.** Scarring: Ugly retracting hyperpigmented scars are shown involving underlying tendon . After 1<sup>st</sup> lipografting.



**Figure 8.** After 2<sup>nd</sup> lipografting.



**Figure 9.** After 3<sup>rd</sup> lipografting and ND/YAG LASER treatment.

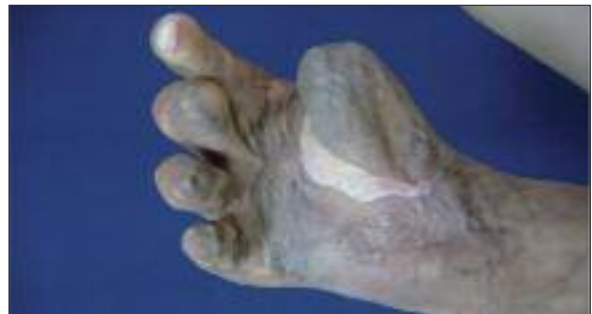Following Hovius et al<sup>6</sup> indication, limb exanguination with a tourniquet was achieved, and from proximal to distal, multiple scar puncture wounds were made with a fine needle-like, sharp-tipped, bevelled piercing instrument as described by the author's<sup>6</sup>, keeping the digit extended as far as possible, taking care only to release scar and not to touch neurovascular bundles. After the first session, scar dissection was easier to perform.

Finally, 10 ml lipografting was performed through a LipoStructure Cannula, Mini, Style III, 3 cm, the graft having been treated as described above.

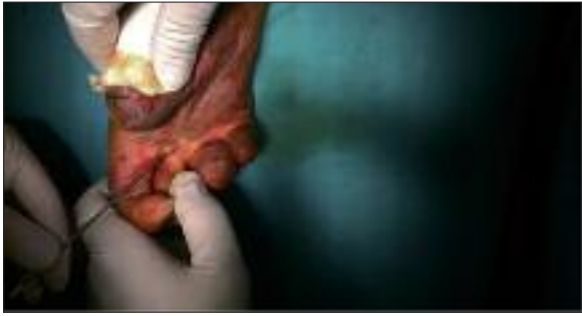The lipoaspirate graft was injected into the space previously created by the dissector. Some injected cells are expected to escape through the needle release sites. Three sessions over a six months period were performed (Figures 10 to 20).

## Results

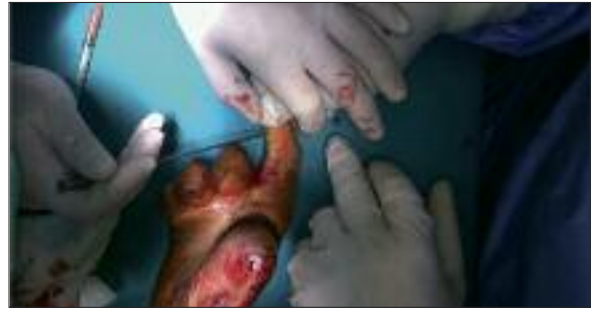In the first case, healing was uneventful and one month after surgery, activity-related pain and discomfort were markedly reduced.



**Figure 10.** A burned hand treated with lipografting. A 28 yr young man had suffered from burn aggression; we treated scars and tendon adhesions of his right hand 2<sup>nd</sup> and 3<sup>rd</sup> (amputation stump) ray volar aspect. Right hand before treatment.



**Figure 11.** Whilst dissecting scars, ever protect neurovascular bundles remembering Hovius: many (how many!) microtreatments weaken chords and scar.



**Figure 12.** Perform and follow scar release completely from proximal to distal.

After two months a customized protocol of mobilization including passive and active ROM as well as skin stretching massages, was performed.

A nine months follow-up showed good results, with relief of pain and contraction and recovery of a normal walking. Sensitivity also looked better at M2PDT

As well as to date no recurrence of scar nor tendon adherence have been registered, nor further treatment was to be proposed and a twenty eight month follow up shows good results (Figure 4).

In the second case, two years later, a soft scar with correction of both retraction and skin pigmentation, has been obtained (Figure 9).

In the burned hand, both the treated rays showed promising results just one month after the first lipografting session, with a significant softening in both MP and IP joints. The patient was submitted to a complete joint rehabilitation protocol and further lipografting sessions were scheduled and performed.

A sensory recovery was also registered between the second and the third session (the interval was above three months) at the M2PDT, which revealed stable in the following time.

Forty five days after the last session, 40 degrees of ROM had been gained, and rehabilitation was restarted to last about two months (Figure 21). Results look stable without retraction loss at a sixty days follow up.

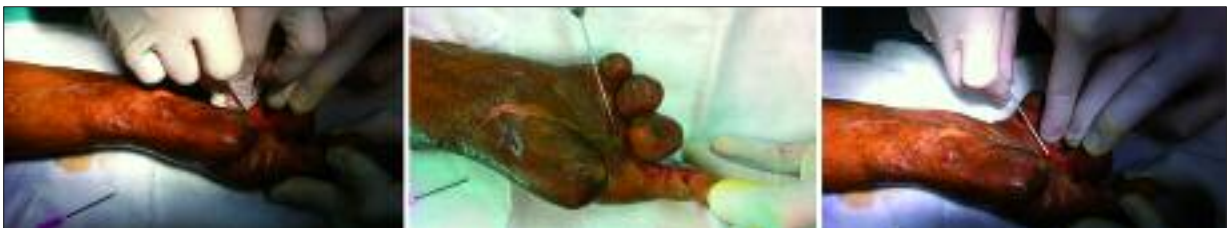A minor anterior tenoarthrolysis (TATA) procedure together with skin resurfacing has been scheduled.

## Discussion

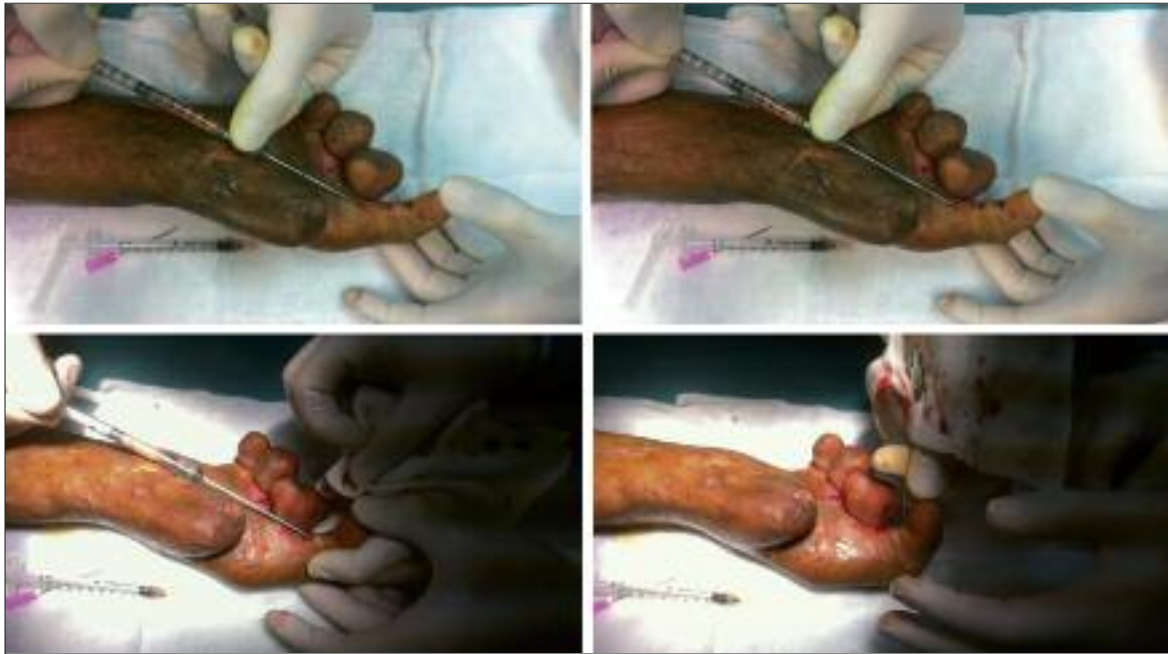Adherences involving skin, tendons and bone, as produced by high energy or crush or



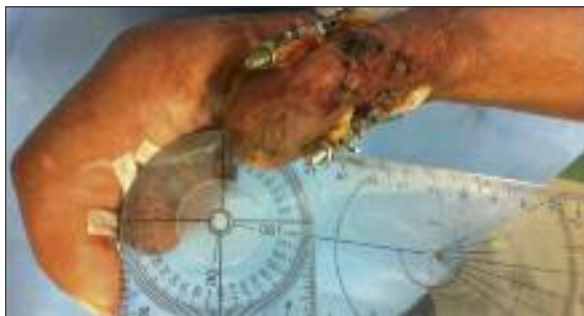**Figure 13.** Before 3<sup>rd</sup> treatment. 2<sup>nd</sup> finger MP and IP ROM.



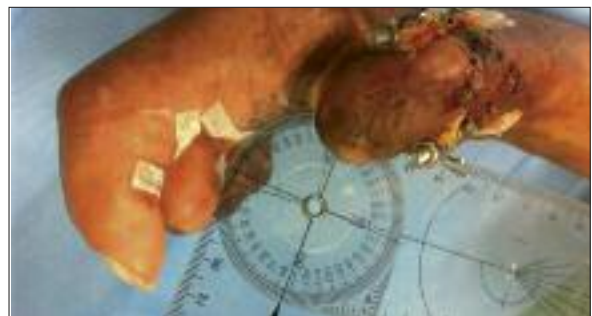**Figure 14.** Scar dissection is easier in the third session.



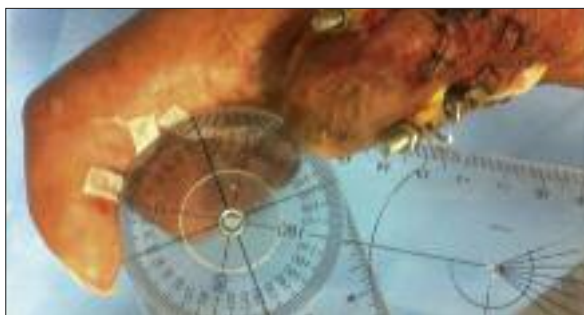**Figure 15.** Injecting fat from proximal to distal.



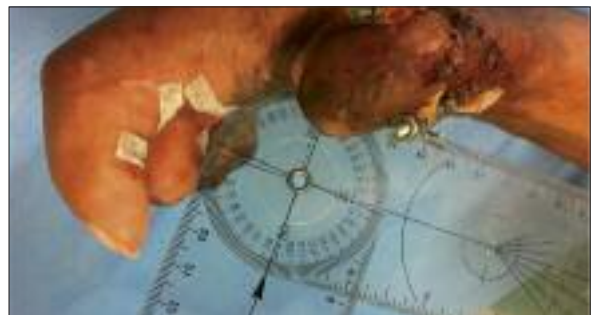**Figure 16.** After the 3<sup>rd</sup> lipografting session. Ten days after 2<sup>nd</sup> finger MP gains 10°.



**Figure 18.** Ten days after 3<sup>rd</sup> finger remnant MP gains 10°.




**Figure 17.** Ten days after 2<sup>nd</sup> finger PIP gains more than 25°.



**Figure 19.** Ten days after 3<sup>rd</sup> finger remnant PIP gains 6°.

even burns, are well known as an important surgical challenge, and in particular both hand and foot tendon compartments must be considered at high risk of developing retractile scars in-

volving tendons and deep structures. Scarring, especially after high energy traumas, involves all these layers together, creating a unique fibrous retraction as well as tenolysis to date re-



**Figure 20.** One month after 2<sup>nd</sup> finger remnant MP gains 30°.

tains a high incidence of relapse and surgery itself produces further scar<sup>1</sup>. Traditional methods of treatment lack the possibility of regeneration, which has been introduced into scar release surgery by lipografting; this method has revealed effective in scar release and precursors and stem cells contained in structured adipose and stromal grafting have been showed as promoters of tissue regeneration<sup>7</sup>.

Among different potential donor sites, trochanteric fat has been demonstrated to be the richest in stromal derived precursors<sup>8</sup>.

Our results show that lipografting promotes regeneration also in tendon scars, and we propose



**Figure 21.** One month after 2<sup>nd</sup> finger remnant PIP gains 40°, the third finger showing no significant gain modification in the last twenty days. Of course, complete skin scar discarding is needed. Meanwhile, to be stated whether a major issue has to be devoted to tendon and joints. Whatever the approach, we believe that an important both MP and PIP ROM has been gained, reducing the need for major dissections, and reducing further scarring.

that structured adipose grafts could be suggested to the patient as a useful tool even in preparation of a surgical tenolysis.

Tendon adherence revealed tenacious and three lipostructure sessions were performed, but it is to be noted that in the first case, one session was effective. We used Hovius technique as we believe it enhances safety, through tourniquet to deflate neurovascular bundle and reduce risk of needle damage and especially in tunnel dissection and adherence rupture<sup>6</sup>. The other advantage is that you can perform it and begin a customized program of rehabilitation to recover skin elasticity together with detaching from the tendon and ROM exercise to loosen stiff joints, that is demonstrated in our cases on the extensor compartment of the foot and on the digital flexor structures in the hand treated.

Concerning with nerve entrapment resolution, our data support other reports<sup>9</sup> that fat grafting produces a better perineural tissue and starts up paracrine messages for nerve repair, contrasting formation of neuromas.

Whatever even about endoarticular fat injection as a further proposal to complete this kind of approach, we suggest that these simple steps could be regarded as a first regenerative surgery tool to ameliorate retractions of the forefoot as well as of the hand.

Thus a less invasive approach could forward, but also avoid further surgery, which in a patient's as well as (or rather better) in a surgeon's mind could mean avoiding further scarring and lessening redo surgery together with poor outcome.

As a final message, we propose that even before to attempt a tenolysis, fat grafting as a less invasive method of treatment should be considered.

#### Conflict of Interest

The Authors declare that there are no conflicts of interest.

#### References

- 1) DAMGAARD OE, SIEMSEN PA. Lipografted tenolysis. *J Plast Reconstr Aesthet Surg* 2010; 63: 637-638.
- 2) RICCIO M, BATTISTON B, PAJARDI G, CORRADI M, PASARETTI U, ATZEI A, ALTISSIMI M, VAIENTI L, CATALANO F, DEL BENE M, FASOLO P, CERUSO M, LUCHETTI R, LANDI

- A; STUDY GROUP ON TENDON ADHESION OF ITALIAN SOCIETY OF HAND SURGERY. Efficiency of Hyaloglide in the prevention of the recurrence of adhesions after tenolysis of flexor tendons in zone II: a randomized, controlled, multicentre clinical trial. *J Hand Surg Eur Vol* 2010; 35: 130-138.
- 3) COLONNA MR, RISITANO G. The effect of hyaluronate as a gliding antiadherent material on extensor tendon injuries of the dorsal compartment of the hand. Report of a 35 cases as a pilot study at the Messina University Hospital, unpublished data, 2008.
  - 4) UEDA K, HARASHIMA T, HARADA T, OBA S, NAGASAKA S. Omentum as gliding material after extensive forearm tenolysis. *Br J Plast Sur* 1993; 46: 590-593.
  - 5) IGNATIADIS IA, MAVROGENIS AF, AVRAM AM, GEORGESCU AV, PEREZ ML, GEROSTATHOPOULOS NE, SOUCACOS PN. Treatment of complex hand trauma using the distal ulnar and radial artery perforator-based flaps. *Injury* 2008; 39(Suppl 3): S116-124.
  - 6) HOVIUS SE, KAN HJ, SMIT X, SELLES RW, CARDOSO E, KHOURI RK. Extensive percutaneous aponeurotomy and lipografting: a new treatment for Dupuytren disease. *Plast Reconstr Surg* 2011; 128: 221-228.
  - 7) KLINGER M, CAVIGGIOLI F, FORCELLINI D, VILLANI F. Scars: a review of emerging and currently available therapies. *Plast Reconstr Surg* 2009; 124: 330.
  - 8) PANETTIERE P, ACCORSI D, MARCHETTI L, MINICOZZI AM, ORSINI G, BERNARDI P, BENATI D, CONTI G, AND SBARBATI A. The trochanteric fat pad. *Eur J Histochem* 2011; 55: e16.
  - 9) VAIENTI L, MERLE M, BATTISTON B, VILLANI F, GAZZOLA R. Perineural fat grafting in the treatment of painful end-neuromas of the upper limb: a pilot study. *J Hand Surg Eur Vol* 2013; 38: 36-42.