

# Use of balloon catheter dilation and steroid-eluting stent in light and severe rhinosinusitis of frontal sinus: a multicenter retrospective randomized study

A. MINNI<sup>1</sup>, A. DRAGONETTI<sup>2</sup>, A. SCIUTO<sup>1</sup>, D. ROSATI<sup>1</sup>, C. CAVALIERE<sup>1</sup>,  
M. RALLI<sup>1</sup>, D. AZIMONTI<sup>3</sup>, A. FRANZETTI<sup>3</sup>, M. DE VINCENTIIS<sup>1</sup>

<sup>1</sup>Department of Sensory Organs, "Sapienza University", Azienda Policlinico Umberto I, Rome, Italy

<sup>2</sup>Azienda Ospedaliera Niguarda Ca' Grande, Milan, Italy

<sup>3</sup>E. Bassini Hospital, Cinisello Balsamo, Milan, Italy

**Abstract.** – **OBJECTIVE:** Frontal sinus surgery has an increased rate of re-stenosis, if compared to other sinuses. It depends mainly on recurrent inflammation and abnormal scarring at the frontal recess and its reduction represents one of the keys to therapeutic success. Balloon catheter dilation (BCD) and implantable sinus stents/spacers represent strategies to improve sinus ventilation respecting the integrity of mucosa and reducing abnormal post-surgical scarring. The purpose of this study was to evaluate the effectiveness, safety and correct indication about the use of BCD and a non-absorbable stent (Relieva Stratus™ MicroFlow spacer) in the management of chronic rhinosinusitis (CRS) of the frontal sinus.

**PATIENTS AND METHODS:** In this multicentric retrospective study we included a population of 76 frontal sinuses with non-polypoid CRS. 41 frontal sinuses were treated with BCD alone and 35 frontal sinuses with BCD + Spacer. We analyzed both radiological (Lund-McKay CT scoring modified by Zinreich) and symptomatological results (SNOT-20 questionnaire) before surgery and after 12 months, dividing our population in two main groups: group "L" (light/mild frontal CRS) and group "S" (moderate/severe frontal CRS).

**RESULTS:** Our results confirm a good safety and effectiveness of BCD in the management of frontal CRS and show a good safety but a not significant effectiveness of Relieva Stratus™ MicroFlow spacer when added to BCD in the management of light and severe frontal chronic rhinosinusitis.

**CONCLUSIONS:** BCD is an acclaimed option in the management of frontal CRS and in the near future, utilization of stents/spacers could become a new and effective weapon in the management of rhinosinusitis, both like an adjunct to standard therapies, and in patient popula-

tions where the use of systemic drugs is contraindicated.

*Key Words:*

Chronic Rhinosinusitis, Sinusitis, Frontal sinus, Endoscopic sinus surgery, Balloon catheter dilation, Spacer, Stent.

## Introduction

Chronic rhinosinusitis (CRS) is a condition of chronic inflammation of the mucosal lining of the nasal cavity and paranasal sinuses<sup>1</sup>. Multiple factors have been implicated in the development of CRS, including environmental (bacteria, biofilms, fungi and allergens described as factors that lead to inflammation of the mucosa of nose and paranasal cavities) and host factors (such as immunodeficiency and eicosanoid dysregulation that contribute to refractory infections or inflammation) and both have a significant impact on the severity of CRS<sup>2-4</sup>.

Infectious factors (bacterial, including biofilm, viral and fungal) indeed coexist with allergic and inflammatory factors (affecting the mucosa and the underlying bone) and mucociliary clearance deficiency<sup>5,6</sup>. Endoscopic Sinus Surgery (ESS) is widespread in treating CRS<sup>7</sup> and several studies have shown that it is an effective and safe treatment for patients with CRS when drug therapy has failed<sup>8,9</sup>. The main goal of ESS is to restore the ventilation of the diseased paranasal sinuses creating an open and accessible cavity, which has been demonstrated to optimize sinonasal penetration of topical medical therapy<sup>10</sup>. However, ESS for the frontal sinus has been shown to have a lower success rate compared to other sinuses<sup>11,12</sup> and it depends both

on perioperative (i.e. extension of frontal sinusotomy) and postoperative (medical management of the frontal recess) conditions<sup>13</sup>. Reasons for failure of ESS in frontal sinus include persistent or recurrent inflammation and abnormal scarring at the frontal recess, leading to restenosis and occlusion of the frontal sinusotomy, leading to a high long-term revision rates (10% to 20% of patients), independently of the approach<sup>13-18</sup>. So, CRS of the frontal sinus is a challenging, constantly evolving and extremely controversial condition and the success of surgery is, in part, dependent on optimization of the postoperative wound-healing process<sup>19,20</sup>. An important goal in the early postoperative period is to minimize mucosal inflammation and promote normal ciliary function in order to reduce the risk of complications such as synechiae formation and infection. To minimize postoperative mucosal inflammation, most experts would recommend high volume saline irrigations and early topical corticosteroid therapy<sup>21,22</sup>; however, the early postoperative formation of sinonasal crusting, retained secretions, and mucosal edema significantly alter the adequate delivery of topical corticosteroid therapy immediately following ESS. Simultaneously, in last years, implantable sinus stents/spacers have been progressively used following ESS to maintain patency of the sinuses and deliver local steroids and there has been a recent interest in use of steroid-impregnated spacers for its potential anti-inflammatory properties during the postoperative period<sup>23-27</sup>. Absorbable or non-absorbable sinus stents allow a sustained, localized, controlled release of medication (corticosteroids or saline solution) and can be used in conjunction to ESS or Balloon Catheter Dilation (BCD) to enable better sinus drainage and wound healing. These drug-eluting devices release drug-loads slowly and continuously to affected areas in the sinuses or nasal cavities for a prolonged period of time. The purpose of this study was to evaluate the effectiveness, safety and correct indication about use of BCD and a non-absorbable stent (Relieva Stratus™ MicroFlow spacer) in treatment of CRS of the frontal sinus, trying to evaluate the role that these devices could play in the management of pathology of frontal recess.

## Patients and Methods

### Patients

We realized a multicentric (Policlinico Umberto I, Rome; Bassini Hospital, Milan; Niguarda Hospital, Milan) retrospective study to assess

the validity and safety of BCD *vs.* BCD with utilization of MicroFlow Spacer in symptomatological CRS of the frontal sinus. The Ethics Committee approval was granted by our Hospital (Policlinico Umberto I, Rome, Italy). We investigated a population of 54 adult patients (31 men and 23 women; overall 76 frontal sinuses studied) with non-polypoid CRS (according to the criteria defined by the European Position Paper on Rhinosinusitis and nasal Polyps Group 2012). 33 patients had been treated with BCD alone for a total of 41 frontal sinuses treated (B group) and 31 patients had been treated with BCD + Spacer for a total of 35 frontal sinuses treated (S group). The patients had been subjected to surgery in the 3 different facilities between 2010 and 2016 for BCD and between 2010 and 2013 for BCD + Spacer. At the time of surgery, patients were aged between 19 and 58 years (mean age = 46 years). By medical records we obtained medical history data, otorhinolaryngologic examination, the preoperative and postoperative SNOT-20 subjective symptomatological test<sup>28</sup>, the preoperative and postoperative endoscopic examination of nasal cavity and preoperative and postoperative Computed Tomography (CT) in axial, coronal and sagittal planes of paranasal sinuses. The degree of every frontal sinus involvement at CT was evaluated using the Lund-MacKay score system modified by Zinreich<sup>29</sup> (Table I). For a better evaluation of the disease, in our study we decided to analyze both radiological (modified Lund-McKay CT scoring) and symptomatological results (SNOT-20 questionnaire) because, although CT scoring are objective metrics<sup>30</sup>, often they do not correlate well with rhinologic symptoms<sup>31</sup>. By protocol, all patients had been subjected to standard medical therapy (antibiotics, corticosteroids and nasal irrigations with saline solution) for at least two months, in accordance with EPOS guidelines, and had not shown improved evaluation criteria. At the end of this period of therapy, they had been thus referred to surgery. Exclusion criteria had been: pregnancy, revision surgery, CRS with nasal polyps, cystic fibrosis, paranasal sinus tumors, allergy to non steroidal anti-inflammatory drugs, coagulopathy, use of anticoagulants, osteoneogenesis or Paget's disease, a previous glaucoma diagnosis, uncontrolled hypertension, diabetes mellitus, history of facial trauma with distorted sinus anatomy. Informed consent had been obtained prior to surgery from designated staff. Studying pre-operative TC and a SNOT-20

questionnaire of every patient, we divided our population in two main groups using the modified Lund-MacKay score system:

- group “L” (light) included all patients with a light/mild involvement of the frontal sinus (appreciated with a lower score (1-2) of Zinreich classification) (25 patients/43 pathological frontal sinuses);
- group “S” (severe) included all patients with a moderate/severe involvement of the frontal sinus (appreciated with an higher score (3-4-5) of Zinreich classification) (29 patients/33 pathological frontal sinuses). Patients of the “L” group were further divided creating two subgroups:
  - LB, in which frontal sinus dilatation with BCD had been performed (composed of 24 frontal sinuses);
  - LS, in which frontal sinus dilation with BCD and positioning of MicroFlow Spacer had been performed (composed of 19 frontal sinuses).

The same division was realized for patients of the “S” group, creating the subgroups:

- SB, in which frontal sinus dilatation with BCD had been performed (composed of 17 frontal sinuses);
- SS, in which frontal sinus dilation with BCD and positioning of MicroFlow Spacer had been performed (composed of 16 frontal sinuses).

There was homogeneity in primary outcome measures (SNOT-20 and Lund-Mackay) between the groups. During every procedure, executed under general anesthesia, ESS had been performed for each individual case according to the surgical need of the patient. So, septoplasty and/or partial middle turbinectomy had been performed to increase access to the frontal sinus outflow. All patients had been treated with a 5x16 mm Relieva\* sinus catheter (Acclarent), inflated at 10-14 atmosphere for 10 s. At discretion of the surgeon, serial balloon dilations had been performed if needed to ensure that the frontal sinus outflow tract was completely dilated in its entire length. A 30° and 45° endoscope had been then used to inspect the frontal recess and confirm successful dilation. After this procedure, patients of the S group had been also treated with positioning of Relieva Stratus™ MicroFlow spacer (filled with the steroid triamcinolone acetonide 40 mg/ml), removed about 4 weeks after in the office setting. In both groups, standard postoperative therapy was administered, which comprised antibiotics, nasal

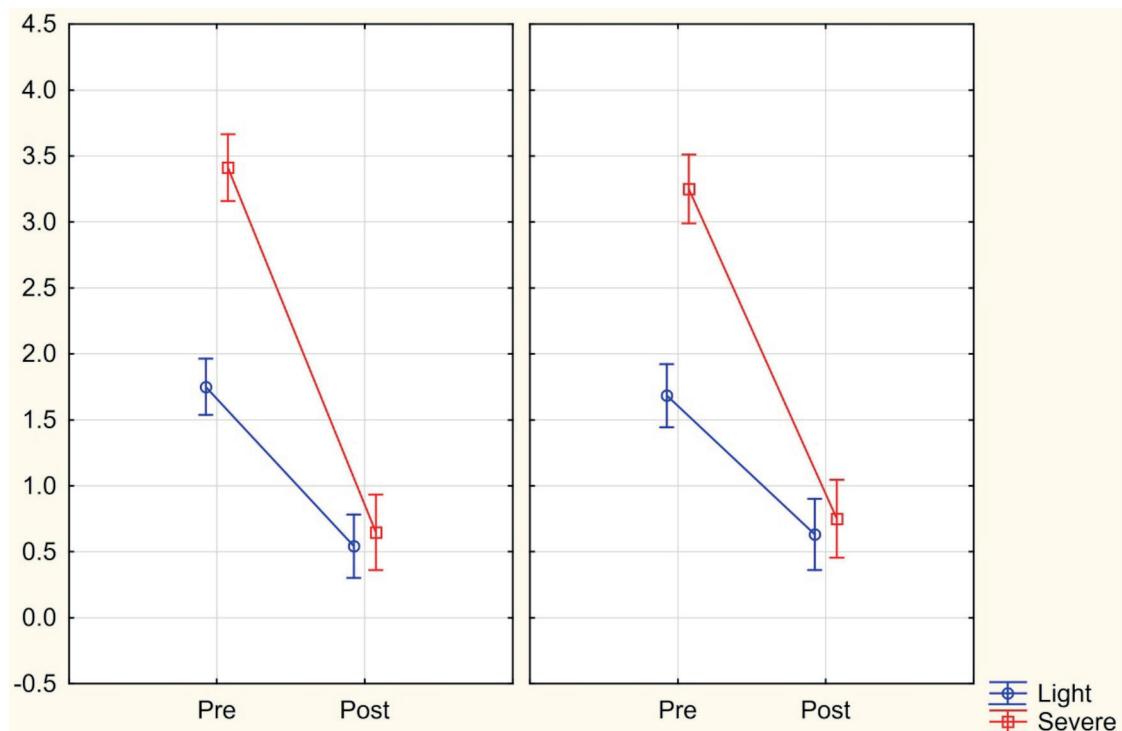
irrigations and topical steroids for 1 month. Standardized post-surgical management consisted of nasal endoscopy and aspiration for removal of secretions and scabs after one week, two weeks, one month, 3 months, 6 and 12 months following surgery, using direct visualization with a 30° and 70° endoscope to confirm patency of the frontal sinus ostia. A 2-mm outer diameter curved suction was also passed into the frontal sinus ostia to confirm patency. If there was edema, the 2-mm-diameter suction was not pushed through the edema but the patency of the frontal sinus ostium was measured. If edema was fully obstructing the ostium, this was recorded as not patent. The permeability of frontal recess was defined as a dichotomous variable (yes/no) before surgery and 12 months after surgery. The goal of the procedure was the complete resolution of frontal sinus disease shown on CT scan after one year follow-up and a considerable improvement of symptoms evaluated with SNOT-20 test. The follow-up had been rationally planned at one year from surgery because some researches<sup>32</sup> have shown that a restenosis of the frontal sinus occurs usually within 12 months, and effectively, after that time, the frontal sinus achieves a good re-epithelization, with a very low risk of new stenosis and thus a quite certain probability of permanent results. Twelve months after surgery, nasal symptoms were reassessed with SNOT-20 questionnaire and a new tomographic scan was performed to evaluate the degree of disease according to the CT Lund-Mackay stage system modified by Zinreich, specifically applied to the frontal sinus<sup>29</sup>.

### **Statistical Analysis**

Statistical analysis was realized with Statistica 10 (Satsoft). Statistical analysis was performed with ANOVA for repeated measures by comparing baseline and post-treatment values in the two groups of patients. The post-hoc test was done with the Newman-Keuls test;  $p$ -value < 0.05 was considered statistically significant. The interaction between treatments and time was evaluated to compare the effectiveness of the two treatments in the groups.

### **Results**

Group LB comprised 24 frontal sinuses treated with BCD and presented a preoperative mean SNOT-20 of 62.86 and a mean Lund-MacKay frontal sinus CT preoperative grading modified accord-



**Figure 1.** CT score between Balloon Catheter Dilation and MicroFlow Spacer; vertical bars denote 0.95 confidence intervals.

ing to Zinreich of 1.76. Group LS comprised 19 frontal sinuses treated with BCD + Spacer and presented a preoperative mean SNOT-20 of 64.21; the mean Lund-MacKay frontal sinus CT preoperative grading modified according to Zinreich was 1.69. The statistical comparison between the two groups did not show significant differences in terms of SNOT-20 ( $p=0.711$ ) or radiological grading ( $p=0.713$ ). Group SB comprised 17 frontal sinuses treated with BCD and presented a preoperative mean SNOT-20 of 68.25 and a mean Lund-MacKay frontal sinus CT preoperative grading modified according to Zinreich of 3.42. Group SS comprised 16 frontal sinuses treated with BCD + Spacer and presented a preoperative mean SNOT-20 of 69.16; the mean Lund-MacKay frontal sinus CT preoperative grading modified according to Zinreich was 3.27. Even here the statistical comparison between the two groups did not show significant differences in terms of SNOT-20 ( $p=0.79$ ) or radiological grading ( $p=0.37$ ).

Postoperative data at 12 months showed these results:

- in subgroup LB (BCD in light sinusitis) the mean SNOT-20 decreased from 62.86 to 22.65 while the mean Lund-Mackay CT score in frontal sinuses decreased from 1.76 to 0.53. No patients were lost at the 12-month follow-up and 22 frontal sinuses out of 24 seemed patent at one-year endoscopic evaluation (91.7%).
- in subgroup LS (BCD + Spacer in light sinusitis) the mean SNOT-20 decreased from 64.21 to 24.11 while the mean Lund-Mackay CT score in frontal sinuses decreased from 1.69 to 0.61. No patients were lost at the 12-month follow-up and 17 frontal sinuses out of 19 seemed patent at one-year endoscopic evaluation (89.5%).
- in subgroup SB (BCD in severe sinusitis) the mean SNOT-20 decreased from 68.25 to 23.86 while the mean Lund-Mackay CT score in frontal sinuses decreased from 3.42 to 0.67. No patients were lost as the 12-month follow-up and 15 frontal sinuses out of 17 seemed patent at one-year endoscopic evaluation (88.2%).
- in subgroup SS (BCD + Spacer in severe sinusitis) the mean SNOT-20 decreased from 69.16 to 25.02 while the mean Lund-Mackay CT score in frontal sinuses decreased from 3.27 to 0.73. No patients were lost as the 12-month follow-up and 14 frontal sinuses out of 16 seemed patent at one-year



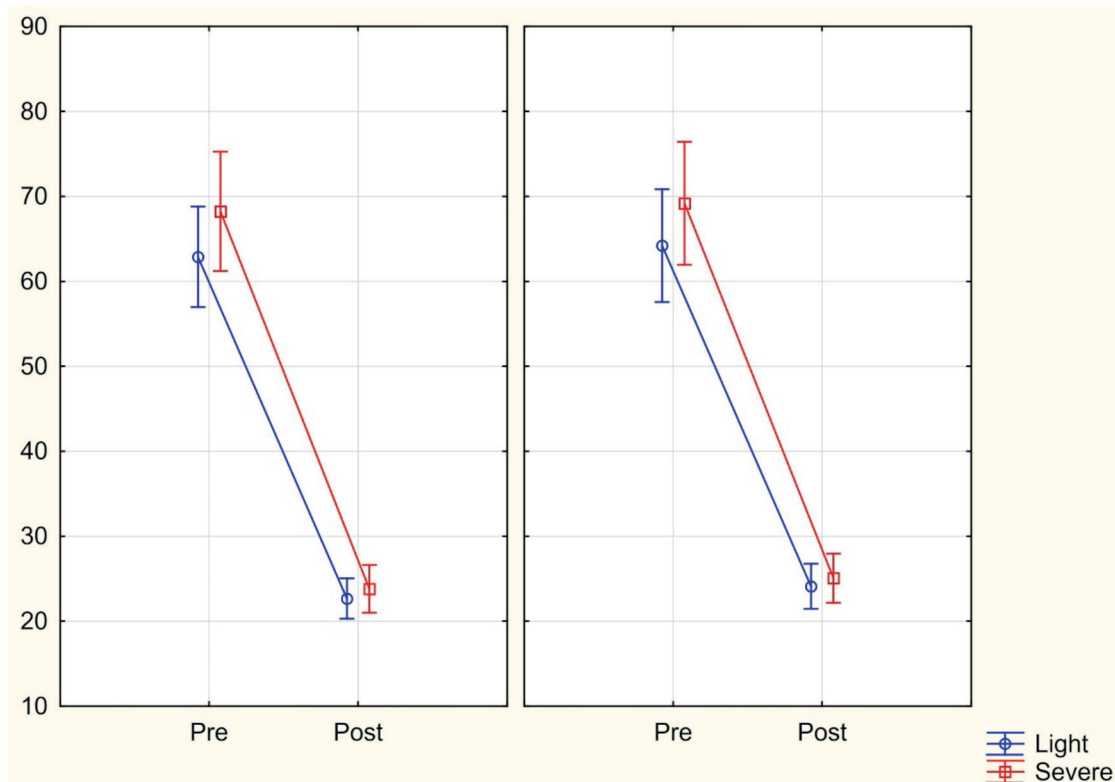
endoscopic evaluation (87.5%). The preoperative and postoperative score of Lund-Mackay CT score in LB and SB groups demonstrated a significant reduction ( $p=0.00012$  and  $p=0.00015$ ), the same happened for LS and SS groups ( $p=0.00012$  and  $p=0.00015$ ) (Figure 1). Comparison between the two techniques was not significant both in light sinusitis ( $p=0.624$ ) and in severe sinusitis ( $p=0.574$ ). Comparing preoperative and postoperative SNOT-20 score in patients treated with BCD in both light and severe sinusitis (LB - SB), we found that there was a significant reduction ( $p=0.00012$  and  $p=0.00015$ ). We found the same result in patients treated with BCD + Spacer (LS - SS) ( $p=0.00012$  and  $p=0.00012$ ) (Figure 2). The comparison between the two techniques for light sinusitis (LB vs. LS) was not significant ( $p=0.750$ ). The same resulted between the two techniques in patients with severe sinusitis (SB vs. SS) ( $p=0.792$ ). No major complications were observed in either group, although minor epistaxis was reported occasionally. The cases of frontal recess obstructed following

treatment with BCD or BCD + Spacer were subjected to revision surgery. None of our patients developed complications as a result of the BCD procedure or Spacer positioning procedure including orbital or skull base dehiscence and mucocele formation.

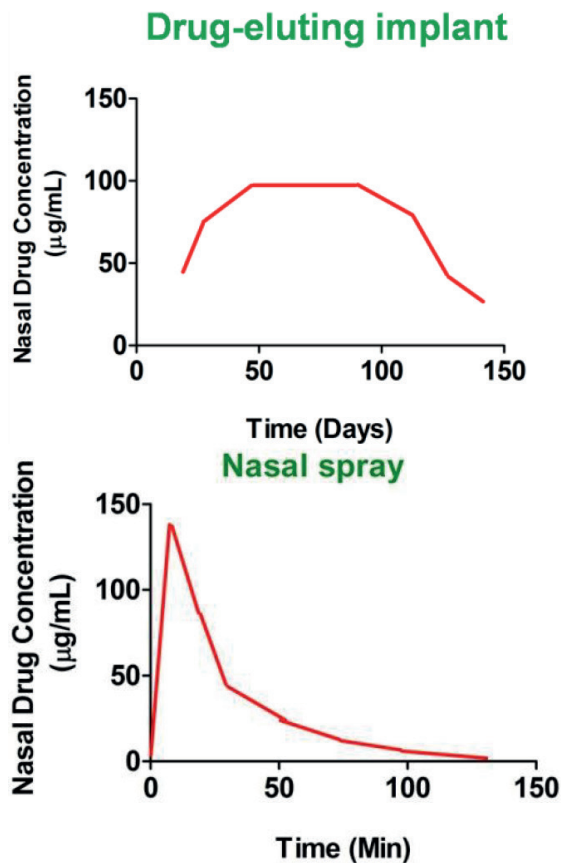
## Discussion

Failures in frontal CRS surgery are more frequent than in other sinuses CRS surgery and they can often be prevented with a correct and focused post-surgical therapeutic management. Mucosal and bony tissue reactivity play a pivotal role in exacerbating CRS<sup>33,34</sup>; therefore, for the long-term reduction of mucosal inflammation, it represents one of the keys for obtaining a therapeutic success.

In 2005, the United States Food and Drug Administration (FDA) approved BCD for diagnostic and therapeutic approaches to the paranasal sinuses. BCD consists of a high-pressure compression of the sinus mucosa with a balloon that creates microfractures in the bone surrounding the *sinus ostium* and his outflow tract to improve sinus drain-



**Figure 2.** SNOT-20 comparison between Balloon Catheter Dilation and MicroFlow Spacer; vertical bars denote 0.95 confidence intervals.



**Figure 3.** Comparison of the plots of nasal drug concentration versus time, obtained after administration of nasal sprays and drug-eluting implants. Nasal sprays show rapid clearance of the drug from the nasal mucosa as compared to locally acting implants.

age and ventilation, respecting the integrity of mucosa. It represents a minimally invasive procedure that aims to restore physiological sinus drainage preventing abnormal scarring associated with mucosal stripping<sup>35,36</sup>. BCD can be performed alone or in conjunction with traditional ESS. Currently, there are four companies with FDA-cleared balloon dilation systems: Acclarent\* (Menlo Park, CA, USA), Entellus Medical\* (Plymouth, Minnesota, USA), Ventera\* (Reston, VA, USA), and Medtronic\* (Dublin, Ireland). The rationale behind the use of BCD in frontal sinus involves the ability of this technique to microfracturing and remodeling the bone in frontal recess, preserving the integrity of surrounding mucosa. In this way, the combination of this improved bony and mucosal patency, could be sufficient to restore the sinus continued physiological drainage and ventilation. In addition, even in case of surgical failure the frontal sinus remains available to further surgical interven-

tion (re-dilation or advanced endoscopic traditional surgery). A recent important review<sup>37</sup> on the use of balloon procedure in rhinosinusitis suggests a benefit in certain circumstances for BCD of the frontal sinus when applied as either a stand-alone or hybrid procedure. The same research concludes that findings are not sufficient to reach consensus in relation to the outcomes of BCD in different severity levels of CRS as graded by CT, and other studies with appropriate controls (comprehensive pre-operative assessments, including CT scan severity) are needed to establish the different outcomes that this technique can achieve in light and severe rhinosinusitis. In a previous trial, we compared the safety and efficacy of BCD with traditional ESS demonstrating the substantial similarity between these two techniques that must be alternative weapons of this kind of surgery [38]; we divided the population affected in two groups, one with light/mild frontal CRS and the other with moderate/severe frontal CRS (basing on radiological findings at Lund-MacKay modified by Zinreich score). Our data showed a better improvement at SNOT-20 questionnaire in patients with severe rhinosinusitis that underwent BCD compared to traditional ESS. The standard treatment of CRS is local and systemic drug therapy and there is increasing evidence of the favorable effect of topically administered glucocorticoid therapy on inflammatory character of CRS. The topical administration of steroids is safe and may have only minor side effects, such as mucosal irritation, crusting and minor nose bleedings. The main problem in drug delivery to the affected paranasal sinus mucosa is the complexity of the sinus anatomy, especially in the frontal recess<sup>39,40</sup>. Topical steroids are widely used postoperatively as they can facilitate early mucosalization and reduce edema, granulation tissue formation and fibrin deposition<sup>20</sup>. However, many investigations<sup>41-44</sup> have reported that topical nasal steroid sprays do not reach adequately the frontal recess and hence are quite effective in post-surgical management of patients with frontal sinusitis; so, the challenge of topical steroid therapy remains adequate drug delivery and patient compliance. On the other hand, oral steroids, although effective in treating the inflammatory response, have shown a higher rate of systemic risks for the patient and, therefore, are prescribed with caution<sup>45,46</sup>. The differences of local distribution of drug between nasal drug-eluting implants and standard nasal sprays are summarized in Figure 3<sup>24</sup>. As observed, little quantity of drug are detected within a few hours using nasal sprays, while drug-eluting nasal im-

**Table I.** Zinreich Staging System (Modification of Lund-Mackay).

Zinreich staging system.	
Zinreich Staging System (Modification of Lund-Mackay) Scores Each Sinus 0-5, OMC 0-2 0 = 0%, 1 = 1-25%, 2 = 26-50%, 3 = 51-75%, 4 = 76-99%, 5 =100%	
Right	Left
Maxillary	Maxillary
Anterior ethmoid	Anterior ethmoid
Posterior ethmoid	Posterior ethmoid
Sphenoid	Sphenoid
Frontal	Frontal
Osteomeatal complex	Osteomeatal complex
Total (maximum = 54)	

plants ensure a continuous and prolonged drug release to the affected mucosa for CRS treatment. Another important problem is that preventing post-operative complications is not only an important quality-of-care outcome for patients, but it also reduces potentially wasted economic resources used by the interventions required to solve the complications<sup>47,48</sup>. For this reason, policy makers and third party players well recognize the importance of prevention of complications and avoidance of revision surgery; so, they place value on interventions that achieve this endpoint. Therefore, it is important to identify management strategies aimed to reduce the total duration of systemic corticosteroid therapies and to improve the delivery of topical steroids in frontal sinus. At this regard, the use of steroid-eluting stent or spacers may represent a novel strategy to reach this goal. In last years, a variety of devices have been tested in the paranasal sinuses after endoscopic sinus surgery with varying success; these include packing materials, injectable space-filling gels or structured stents. Sinus stents may be composed of non-absorbable alloplastic materials (i.e. silicone, plastic) that must be removed in the office setting after a variable period of time or absorbable biomaterials (i.e. bovine gelatin, poly(lactic-co-glycolic acid)), that degrade spontaneously and gradually in a controlled time following surgery. Sinus stents are also defined “spacers” because they maintain separation between critical areas of healing to prevent edema, scar formation and restenosis. Incorporation of a drug such as corticosteroids, antibiotics or anti-neoplastic agents into these nasal devices is the primary and most interesting focus of developing drug-eluting nasal implants<sup>49</sup>. Drug-eluting sinus implants can be used very effectively after sinus

surgery because of their ability to maintain sinus patency by providing controlled, constant drug release over a variable period of time to the surrounding sinus mucosa<sup>50</sup>. Examples of clinically approved implants include Propel™ implant, Relieva Stratus™ MicroFlow spacer and the Sinu-Foam™ spacer. Due to its position as an emerging technology, the role of steroid-eluting stents in the management of surgical CRS patients has yet to be fully assessed; data reported in literature show significant variability in the outcomes of these implants designed and aimed to maintain sinus patency and drug releasing to the affected sinus mucosa<sup>51</sup>. An assessment<sup>52</sup> by the National Institute for Health and Care Excellence (NICE, 2016) concludes: “Current evidence on the safety of corticosteroid-eluting bioabsorbable stent or spacer insertion during endoscopic sinus surgery to treat chronic rhinosinusitis raises no major safety concerns...NICE encourages further research on corticosteroid-eluting bioabsorbable stent or spacer insertion during endoscopic sinus surgery and, specifically, controlled studies designed for between-patient (rather than within-patient) comparisons. Outcomes should include symptom scores, quality of life and the need for retreatment in the long-term. All complications should be reported”. In a Cochrane review published in 2015, Huang et al<sup>23</sup> evaluated the safety and effectiveness of steroid-eluting sinus stents placement in CRS patients after ESS, but they concluded that there was currently no evidence to demonstrate the benefits of steroid-eluting sinus stents when compared to non-steroid-eluting sinus stents, nasal packing or no treatment. Similarly, there was no evidence to show that one steroid-eluting sinus stent was superior to another. In another trial using an intra-pa-

tient control design, Smith et al<sup>53</sup> evaluated the safety and effectiveness of a steroid-eluting implant in improving surgical outcomes when placed in the frontal sinus following ESS in patients with CRS; the authors demonstrated the effectiveness of steroid-eluting implants in improving outcomes of frontal sinus surgery. The Relieva Stratus™ MicroFlow spacer from Acclarent\* (Menlo Park, CA, USA) is a temporarily implanted drug-eluting stent designed to provide slow release of steroids into frontal or ethmoid sinuses over a 2-4 week period with the intention of maintaining sinus ostial patency. It was introduced in 2009 as a minimally invasive surgical tool to treat chronic ethmoidal and frontal sinusitis. In the United States, the FDA approved the spacer loaded only with sterile saline, while in Europe, the device received a CE Mark approval for the use of triamcinolone acetonide (40 mg/ml), asserting that the mechanism of action would have been topical, so no significant systemic effects would have been expected. The implantation of this device is quick, simple and safe to perform and the complication rate ought to be very low basing on previous literature<sup>54, 55</sup> even if one orbital complication has been reported in the literature. The device was then easily removed in the office setting. Catalano et al<sup>57</sup> tried to evaluate the safety and short-term outcomes of this device in ethmoid sinus and they concluded that this spacer appeared safe and effective in treating chronic ethmoid sinus disease within the defined follow-up period of 6 months. Taulu et al<sup>58</sup> compared the optical Image-Guided Surgery (IGS)-assisted insertion of the device with fluoroscopic insertion and concluded that, from a technical perspective, IGS-guided insertion was a faster, safer and more exact procedure that guaranteed the optimal positioning and effectiveness of the implant. Businco et al<sup>59</sup> evaluated the safety and effectiveness of this device in the management of allergic CRS in comparison with the traditional endoscopic ethmoidectomy and concluded that in their experience, the use of this spacer was effective in treatment of allergic patients with ethmoidal CRS when conventional medical treatment had failed, or when wishing to avoid the traditional ESS. Anyway, in May 2013, Acclarent voluntarily discontinued all sales of the Stratus device and withdrew all approved FDA clearances, making the devices no longer available for sale in the United States.

The major disadvantage of Relieva Stratus™ MicroFlow spacer was its duration of use (14-28 days). Probably, this was not sufficient to treat chronic inflammation of CRS, which lasts for

more than 12 weeks<sup>7</sup> and thus a relapse of infection/inflammation can ensue. This statement is coherent and can probably explain our results, in which it is showed a not statistically significant difference at one year-control between treatment with BCD and treatment with BCD + spacer in the frontal sinus, both in patients with light/mild frontal CRS ( $p>0.05$ ) and in patients with moderate/severe frontal CRS ( $p>0.05$ ), studied with Lund-Mackay modified by Zinreich score. The same not statistically significant difference was observed comparing the results of SNOT-20 questionnaire at one year-control between treatment with BCD and treatment with BCD + spacer in the frontal sinus, both in patients with light/mild frontal CRS ( $p>0.05$ ), and in patients with moderate/severe frontal CRS ( $p>0.05$ ). Anyway, not significant adverse events were encountered in our study.

## Conclusions

Our findings confirm the good safety and effectiveness of BCD in the management of light and severe frontal CRS and show a good safety but not significant effectiveness of Relieva Stratus™ MicroFlow spacer when added to BCD in the management of light and severe frontal CRS. Nevertheless, in this trial we evaluated the safety and efficacy of a kind of nasal stent, but additional studies are needed to demonstrate the safety and efficacy of every kind of implant. We suggest a further development of devices releasing drugs, probably improved in time of permanence and re-absorption in the affected site and perhaps with the possibility to distribute several drugs in synergic association. These devices could become another option in the management of rhino-sinusitis, both like an alternative to standard therapies, and in patient populations where the use of systemic drugs can be contraindicated, like patients with immunodeficiency, diabetes mellitus, uncontrolled hypertension, serious osteoporosis or other conditions in which the surgeon wants to avoid the oral steroids administration to the patient. Moreover, evaluating the cost-effectiveness of the steroid-eluting implants compared to other interventions for managing complications (i.e. surgery revision) should be the focus of future economic evaluations.

## Conflict of Interest

The Authors declare that they have no conflict of interest.



## References

- 1) ROSENFELD RM, PICCIRILLO JF, CHANDRASEKHAR SS, BROOK I, ASHOK KUMAR K, KRAMPER M, ORLANDI RR, PALMER JN, PATEL ZM, PETERS A, WALSH SA, CORRIGAN MD. Clinical practice guideline (update): adult sinusitis. *Otolaryngol Head Neck Surg* 2015; 152: S1-S39.
- 2) KENNEDY DW. Pathogenesis of chronic rhinosinusitis. *Ann Otol Rhinol Laryngol Supplement* 2004; 193: 6-9.
- 3) TAN BK, SCHLEIMER RP, KERN RC. Perspectives on the etiology of chronic rhinosinusitis. *Curr Opin Otolaryngol Head Neck Surg* 2010; 18: 21-26.
- 4) CAVALIERE C, ROSATI D, MESSINEO D, MASIERI S. ENT tests for assessing the allergic patient. *J Biol Regul Homeost Agents* 2018; 32: 29-35.
- 5) ZACHAREK MA, KROUSE JH. The role of allergy in chronic rhinosinusitis. *Curr Opin Otolaryngol Head Neck Surg* 2003; 11: 196-200.
- 6) CHENG KJ, BAO YY, ZHOU SH. The role of hypoxia inducible factor in nasal inflammations. *Eur Rev Med Pharmacol Sci* 2016; 20: 5067-5076.
- 7) FOKKENS WJ, LUND VJ, MULLOL J, BACHERT C, ALOBID I, BAROODY F, COHEN N, CERVIN A, DOUGLAS R, GEVAERT P, GEORGALAS C, GOOSSENS H, HARVEY R, HELLINGS P, HOPKINS C, JONES N, JOOS G, KALOGJERA L, KERN B, KOWALSKI M, PRICE D, RIECHELMANN H, SCHLOSSER R, SENIOR B, THOMAS M, TOSKALA E, VOEGELS R, WANG DE Y, WORMALD PJ. EPOS 2012: European position paper on rhinosinusitis and nasal polyps 2012. A summary for otorhinolaryngologists. *Rhinology*; 2012; 50: 1-12.
- 8) HOPKINS C, BROWNE JP, SLACK R, LUND V, TOPHAM J, REEVES B, COPLEY L, BROWN P, VAN DER MEULEN J. The national comparative audit of surgery for nasal polyposis and chronic rhinosinusitis. *Clin Otolaryngol* 2006; 31: 390-398.
- 9) RAGAB SM, LUND VJ, SCADDING G. Evaluation of the medical and surgical treatment of chronic rhinosinusitis: a prospective, randomised, controlled trial. *Laryngoscope* 2004; 114: 923-930.
- 10) HARVEY RJ, GODDARD JC, WISE SK, SCHLOSSER RJ. Effects of endoscopic sinus surgery and delivery device on cadaver sinus irrigation. *Otolaryngol Head Neck Surg* 2008; 139: 137-142.
- 11) HOSEMANN W, KUHNEL T, HELD P, WAGNER W, FELDERHOFF A. Endonasal frontal sinusotomy in surgical management of chronic sinusitis: a critical evaluation. *Am J Rhinol* 1997; 11: 1-9.
- 12) VALDES CJ, BOGADO M, SAMAHA M. Causes of failure in endoscopic frontal sinus surgery in chronic rhinosinusitis patients. *Int Forum Allergy Rhinol* 2014; 4: 502-506.
- 13) CHANDRA RK, PALMER JN, TANGSUJARITTHAM T, KENNEDY DW. Factors associated with failure of frontal sinusotomy in the early follow-up period. *Otolaryngol Head Neck Surg* 2004; 131: 514-518.
- 14) RAMADAN HH. Surgical causes of failure in endoscopic sinus surgery. *Laryngoscope* 1999; 109: 27-29.
- 15) CHAN Y, MELROY CT, KUHN CA, KUHN FL, DANIEL WT, KUHN FA. Long-term frontal sinus patency after endoscopic frontal sinusotomy. *Laryngoscope* 2009; 119: 1229-1232.
- 16) ANDERSON P, SINDWANI R. Safety and efficacy of the endoscopic modified Lothrop procedure: a systematic review and meta-analysis. *Laryngoscope* 2009; 119: 1828-1833.
- 17) KUTLUHAN A, BOZDEMIR K, ÇETIN H, YALÇINER G, SALVIZ M, SARI N, DEĞER HM, BILGEN AS. Endoscopic balloon dilation sinuplasty including ethmoidal air cells in chronic rhinosinusitis. *Ann Otol Rhinol Laryngol* 2009; 118: 881-886.
- 18) TOMAZIC PV, STAMMBERGER H, KOELE W, GERSTENBERGER C. Ethmoid roof CSF-leak following frontal sinus balloon sinuplasty. *Rhinology* 2010; 48: 247-250.
- 19) HOSEMANN W, SCHINDLER E, WIEGREBE E, GOPFERICH A. Innovative frontal sinus stent acting as a local drug-releasing system. *Eur Arch Otorhinolaryngol* 2003; 260: 131-134.
- 20) HOSEMANN W, WIGAND ME, GODE U, LANGER F, DUNKER I. Normal wound healing of the paranasal sinuses: clinical and experimental investigations. *Eur Arch Otorhinolaryngol* 1991; 248: 390-394.
- 21) RUDMIK L, SOLER ZM, ORLANDI RR, STEWART MG, BHATTACHARYYA N, KENNEDY DW, SMITH TL. Early post-operative care following endoscopic sinus surgery: an evidence-based review with recommendations. *Int Forum Allergy Rhinol* 2011; 1: 417-430.
- 22) BEULE A, SCHARF C, BIEBLER KE, GÖPPERICH A, STEINMEIER E, WOLF E, HOSEMANN W, KAFTAN H. Effects of topically applied dexamethasone on mucosal wound healing using a drug-releasing stent. *Laryngoscope* 2008; 118: 2073-2077.
- 23) HUANG Z, HWANG P, SUN Y, ZHOU B. Steroid-eluting sinus stents for improving symptoms in chronic rhinosinusitis patients undergoing functional endoscopic sinus surgery. *Cochrane Database Syst Rev* 2015; (6): CD010436.
- 24) PARIKH A, ANAND U, UGWU MC, FERIDOONI T, MASSOUD E, AGU RU. Drug-eluting nasal implants: formulation, characterization, clinical applications and challenges. *Pharmaceutics* 2014; 6: 249-267.
- 25) ZHAO X, GREWAL A, BRIEL M, LEE JM. A systematic review of nonabsorbable, absorbable, and steroid-impregnated spacers following endoscopic sinus surgery. *Int Forum Allergy Rhinol* 2013; 3: 896-904.
- 26) DAUTREMONT JF, MECHOR B, RUDMIK L. The role of immediate postoperative systemic corticosteroids when utilizing a steroid-eluting spacer following sinus surgery. *Otolaryngol Head Neck Surg* 2014; 150: 689-695.
- 27) RUDMIK L, MACE J, MECHOR B. Effect of a dexamethasone Sinu-Foam™ middle meatal spacer on endoscopic sinus surgery outcomes: a randomized, double-blind, placebo-controlled trial. *Int Forum Allergy Rhinol* 2012; 2: 248-251.
- 28) PICCIRILLO JF, MERRITT MG JR, RICHARDS ML. Psychometric and clinimetric validity of the 20-Item Sino-Nasal Outcome Test (SNOT-20). *Otolaryngol Head Neck Surg* 2002; 126: 41-47.
- 29) LIKNESS MM, PALLANCH JF, SHERRIS DA, KITA H, MASHTARE TL JR, PONIKAU JU. Computed tomography scans as an objective measure of disease severity in chronic rhinosinusitis. *Otolaryngol Head Neck Surg* 2014; 150: 305-311.

- 30) MINNI A, MESSINEO D, ATTANASIO G, PIANURA E, D'AMBROSIO F. 3D cone beam (CBCT) in evaluation of frontal recess: findings in youth population. *Eur Rev Med Pharmacol Sci* 2012; 16: 912-918.
- 31) GREGURIĆ T, TRKULJA V, BAUDOIN T, GRGIĆ MV, ŠMIGOVEC I, KALOGJERA L. Association between computed tomography findings and clinical symptoms in chronic rhinosinusitis with and without nasal polyps. *Eur Arch Otorhinolaryngol* 2017; 274: 2165-2173.
- 32) TRAN KN, BEULE AG, SINGAL D, WORMALD PJ. Frontal ostium restenosis after the endoscopic modified Lothrop procedure. *Laryngoscope* 2007; 117: 1457-1462.
- 33) TIMPERLEY D, SCHLOSSER RJ, HARVEY RJ. Chronic rhinosinusitis: an education and treatment model. *Otolaryngol Head Neck Surg* 2010; 143: S3-8.
- 34) MASIERI S, CAVALIERE C, BEGVARFAJ E, ROSATI D, MINNI A. Effects of omalizumab therapy on allergic rhinitis: a pilot study. *Eur Rev Med Pharmacol Sci* 2016; 20: 5249-5255.
- 35) LEVINE H, RABAGO D. Balloon sinuplasty: a minimally invasive option for patients with chronic rhinosinusitis. *Postgrad Med* 2011; 123: 112-118.
- 36) LEVY JM, MARINO MJ, MCCOUL ED. Paranasal sinus balloon catheter dilation for treatment of chronic rhinosinusitis: a systematic review and meta-analysis. *Otolaryngol Head Neck Surg* 2016; 154: 33-40.
- 37) PICCIRILLO JF, PAYNE SC, ROSENFELD RM, BAROODY FM, BATRA PS, DELGAUDIO JM, EDELSTEIN DR, LANE AP, LUONG AU, MANES RP, MCCOUL ED, PLATT MP, REH DD, CORRIGAN MD. Clinical consensus statement: balloon dilation of the sinuses. *Otolaryngol Head Neck Surg* 2018; 158: 203-214.
- 38) MINNI A, DRAGONETTI A, SCIUTO A, CAVALIERE C, ROSATI D, AZIMONTI D, FRANZETTI A. Use of balloon catheter dilation vs. traditional endoscopic sinus surgery in management of light and severe chronic rhinosinusitis of the frontal sinus: a multicenter prospective randomized study. *Eur Rev Med Pharmacol Sci* 2018; 22: 285-293.
- 39) LUND VJ, BLACK JH, SZABO LZ, SCHREWELIUS C, AKERLUND A. Efficacy and tolerability of budesonide aqueous nasal spray in chronic rhinosinusitis patients. *Rhinology* 2004; 42: 57-62.
- 40) SMALL CB, HERNANDEZ J, REYES A, SCHENKEL E, DAMIANO A, STRYSZAK P, STAUDINGER H, DANZIG M. Efficacy and safety of mometasone furoate nasal spray in nasal polyposis. *J Allergy Clin Immunol* 2005; 116: 1275-1281.
- 41) HONG SD, JANG JY, KIM JH, JANG SY, KIM HY, DHONG HJ, CHUNG SK. The effect of anatomically directed topical steroid drops on frontal recess patency after endoscopic sinus surgery: a prospective randomized single blind study. *Am J Rhinol Allergy* 2012; 26: 209-212.
- 42) AGGARWAL R, CARDOZO A, HOMER J. The assessment of topical nasal drug distribution. *Clin Otolaryngol Allied Sci* 2004; 29: 201-205.
- 43) KAYARKAR R, CLIPTON N, WOOLFORD T. An evaluation of the best head position for instillation of steroid nose drops. *Clin Otolaryngol* 2002; 27: 18-21.
- 44) DURAND M, LE GUELLEC S, POURCHEZ J, DUBOIS F, AUBERT G, CHANTREL G, VECCELIO L, HUPIN C, DE GERSEM R, REYCHLER G, PITANCE L, DIOT P, JAMAR F. Sonic aerosol therapy to target maxillary sinuses. *Eur Ann Otorhinolaryngol Head Neck Dis* 2012; 129: 244-250.
- 45) COPE D, BOVA R. Steroids in otolaryngology. *Laryngoscope* 2008; 118: 1556-1560.
- 46) POETKER DM, REH DD. A comprehensive review of the adverse effects of systemic corticosteroids. *Otolaryngol Clin North Am* 2010; 43: 753-768.
- 47) MANSON SC, BROWN RE, CERULLI A, VIDAURRE CF. The cumulative burden of oral corticosteroid side effects and the economic implications of steroid use. *Respir Med* 2009; 103: 975-994.
- 48) RUDMIK L, SMITH TL. Economic evaluation of a steroid-eluting sinus implant following endoscopic sinus surgery for chronic rhinosinusitis. *Otolaryngol Head Neck Surg* 2014; 151: 359-366.
- 49) BEDNARSKI KA, KUHN FA. Stents and drug-eluting stents. *Otolaryngol Clin N Am* 2009; 42: 857-866.
- 50) MURR AH, SMITH TL, HWANG PH, BHATTACHARYYA N, LANIER BJ, STAMBAUGH JW, MUGGLIN AS. Safety and efficacy of a novel bioabsorbable, steroid-eluting sinus stent. *Int. Forum Allergy Rhinol* 2011; 1; 23-32.
- 51) CLINICAL POLICY BULLETIN: DEVICES FOR POST-OPERATIVE USE FOLLOWING ENDOSCOPIC SINUS SURGERY. Available online: [http://www.aetna.com/cpb/medical/data/800\\_899/0840.html](http://www.aetna.com/cpb/medical/data/800_899/0840.html) (accessed on 09 February 2018)
- 52) <https://www.nice.org.uk/guidance/ippg551>
- 53) SMITH TL, SINGH A, LUONG A, OW RA, SHOTTS SD, SAUTTER NB, HAN JK, STAMBAUGH J, RAMAN. A randomized controlled trial of a bioabsorbable steroid-releasing implant in the frontal sinus opening. *Laryngoscope* 2016; 126: 2659-2664.
- 54) MELROY CT, KUHN FA. Safety of ethmoid sinus drug-eluting catheter insertion. *Ann Otol Rhinol Laryngol* 2009; 118: 708-713.
- 55) MINNI A, DRAGONETTI A, GERA R, BARBARO M, MAGLIULO G, FILIPO R. Endoscopic management of recurrent epistaxis: the experience of two metropolitan hospitals in Italy. *Acta Otolaryngol* 2010; 130: 1048-1052.
- 56) SJOGREN PP, PARKER NP, BOYER HC. Retained drug-eluting stents and recalcitrant chronic rhinosinusitis: a case report. *Allergy Rhinol (Providence)* 2013; 4: e45-e48.
- 57) CATALANO PJ, THONG M, WEISS R, RIMASH T. The microflow spacer: a drug-eluting stent for the ethmoid sinus. *Indian J Otolaryngol Head Neck Surg* 2011; 63: 279-284.
- 58) TAULU R, NUMMINEN J, BIZAKI A, RAUTIAINEN M. Image-guided, navigation-assisted Relieva Stratus MicroFlow Spacer insertion into the ethmoid sinus. *Eur Arch Otorhinolaryngol* 2015; 272: 2335-2340.
- 59) BUSINCO LD, MATTEI A, LAURINO S, ANGELONE AM, LAURIELLO M, CRESCENZI D, ALESSIA DM, RADICI M, BUSINCO AD. Steroid-eluting ethmoidal stent versus antero-posterior ethmoidectomy: comparison of efficacy and safety in allergic patients. *Otolaryngol Pol* 2016; 70: 6-12