

# Onset of ulcerative colitis after thyrotoxicosis: a case report and review of the literature

L. LATERZA<sup>1</sup>, A.C. PISCAGLIA<sup>1,2</sup>, S. LECCE<sup>3</sup>, A. GASBARRINI<sup>1</sup>, M.L. STEFANELLI<sup>1,2</sup>

<sup>1</sup>Department of Internal Medicine, Gastroenterology and Liver Disease, Catholic University of the Sacred Heart of Rome, Rome, Italy

<sup>2</sup>Endoscopy and Gastroenterology Unit, State Hospital, San Marino, Republic of San Marino

<sup>3</sup>Institute of Pathology, "Infermi" Hospital, Rimini, Italy

**Abstract. – OBJECTIVE:** Ulcerative colitis is a chronic disease that could be triggered by acute stressful events, such as gastrointestinal infections or emotional stress.

**PATIENTS AND METHODS:** we reported the case of the onset of an ulcerative colitis after a thyrotoxicosis crisis and reviewed the literature about the relationships between thyroid dysfunctions and ulcerative colitis.

**RESULTS:** A 38-year-old woman was diagnosed with ulcerative colitis after her third thyrotoxicosis crisis, two years after the diagnosis of Graves' disease. In this case, thyrotoxicosis acted as a trigger for ulcerative colitis onset.

**CONCLUSIONS:** Hyperthyroidism could be a trigger able to elicit ulcerative colitis in susceptible patients.

*Key Words:*

Digestive tract, Thyroid, Ulcerative colitis.

## Abbreviations

UC = Ulcerative colitis; TSH = thyroid-stimulating hormone; FT4 = free thyroxine; BMI = body mass index; NSAIDs = nonsteroidal anti-inflammatory drugs.

## Introduction

Ulcerative colitis (UC) is a chronic inflammatory disease with a multifactorial pathogenesis. Stressful events such as smoking cessation or gastrointestinal infections could be associated with the onset of the disease<sup>1</sup>. We reported the case of a woman who developed UC after a thyrotoxicosis crisis.

## Case Report

In 2012, a 36-year-old woman was diagnosed with Graves' disease, presenting with occasional

palpitations, weight loss, anxiety and heat intolerance, confirmed by laboratory tests showing suppressed thyroid stimulating hormone (TSH), increased free thyroxine (FT4) and presence of anti-TSH receptor, anti-thyroglobulin and anti-thyroperoxidase antibodies (Figure 1). She started metimazole 10 mg BID with good response, thus she gradually reduced the dosage until discontinuation in August 2013. In October 2013, due to hyperthyroidism recurrence, she underwent a second cycle of metimazole 10 mg for six months, with good response. In October 2014, she started complaining about non-bloody diarrhoea; laboratory findings showed recurrence of hyperthyroidism, that was treated with metimazole 15 mg, with rapid and satisfactory control of thyroid function, but without improvement of the diarrhoea. She was then treated with rifaximin, probiotics and dietary restriction (no lactose-containing food, no vegetables), without improvement of symptoms. Thus, in November 2014 she was referred to our Primary Care Gastroenterology Center in San Marino. She complained of non-bloody diarrhoea (3-4 bowel movements per day) and colic pain in the lower abdomen improving after defecation, nocturnal awakening for pain and diarrhoea, weight loss (about 4 kg in one month and a half; at the time of the visit BMI was 18,3 kg/m<sup>2</sup>). She had never experienced similar symptoms before. She did not assumed drugs other than metimazole, including NSAIDs.

The patient was an ex-smoker (she had smoked 3-4 cigarettes/day for 4 years, 20 years before), she did not drink coffee, occasionally drank alcohol, had not allergies, but reported a lactose intolerance. In the past, she had suffered from dyspepsia, thus she had undergone upper endoscopy in 2006, showing hiatal hernia, chronic gastritis with antral microerosions and duo-

denitis in the absence of *Helicobacter pylori* infection. She never underwent surgery. Family history was negative for IBD, celiac disease and other gastrointestinal diseases. Her mother suffered from hyperthyroidism.

Physical examination showed diffuse abdominal tenderness that was particularly severe in left iliac fossa. No palpable masses were detected. Temperature was 36.8°C, BP 110/75 mmHg and pulse 80 bpm.

Laboratory findings showed no anaemia and normal WBC, PCR and ESR, but faecal calprotectin was >300 mcg/g (range of detection 30-300 mcg/g) and there were neutrophils in faeces. Faecal parasitic and cultural exams were negative. *Clostridium difficile* toxin was negative. Anti-transglutaminase IgA antibodies were negative (total IgA were normal).

Thus, she underwent ileo-colonoscopy showing disappearance of haustral folds in every colonic segment; colonic mucosa, from rectum to caecum, showed loss of vascular pattern, granularity, erythema, mild friability and erosions. Inflammation was continuous and more severe in rectum and sigmoid colon, where signs of cobblestone were present. Ileal mucosa was normal. These endoscopic features were consistent with UC, that was confirmed by histological exam, showing chronic and acute inflammatory infiltrate, crypt abscesses, crypt architectural irregularity, erosions, and mucin depletion.

So the patient was finally diagnosed with UC E3 following Montreal Classification<sup>2</sup>, Mayo<sup>3</sup> endoscopic subscore 2, with mild clinical activity following Truelove and Witts<sup>4</sup>. The patient started therapy with oral 5-ASA 3.2 g/day and combined topical mesalamine following ECCO recommendations for extensive non-severe UC<sup>5</sup> and she achieved clinical remission and normalization of faecal calprotectin.

## Discussion

We described the case of a patient who developed UC after a thyrotoxicosis crisis in Graves' disease. We reviewed the literature to find other similar cases and the possible relationship between UC and dysthyroidism, using the following research string on Pubmed: "ulcerative colitis AND (thyroid OR Graves OR Basedow OR hyperthyroidism)". No time or language limits were used. The last literature review was performed on April 9, 2015.

The effects of thyroid hormones on gastrointestinal function have been well established. In particular, their effects on gastrointestinal motility have been considered the most important cause of gastrointestinal symptoms<sup>6</sup>. The onset of hyperthyroidism could be characterized by altered bowel habits, persistent abdominal pain, vomiting and unexplained weight loss, even in the absence of other typical symptoms of hyperthyroidism (apathetic hyperthyroidism)<sup>7</sup>. Up to 25% of patients with hyperthyroidism could show diarrhoea, due to reduced small bowel transit time and to hypersecretory state within the intestinal mucosa<sup>6</sup>. Usually, these manifestations improve with the restoration of euthyroidism. For these reasons, in our patient, diarrhoea was not extensively investigated on its onset, because it was considered related to the recurrence of hyperthyroidism. The persistence of symptoms in spite of normalization of thyroid hormones after therapy with metimazole required further investigations and revealed the onset of UC. The relationship between hyperthyroidism and UC has been anecdotally reported in the literature. In fact many case reports have been published since 1970s, supporting the hypothesis of a common pathogenesis<sup>8-16</sup>.

The diagnosis of hyperthyroidism could precede, follow or be simultaneous to the one of UC.

The oldest population studies demonstrated that patients with UC have a 2- to 4-fold increase in the prevalence of thyroid disease<sup>17,18</sup> and that free thyroxine could be increased nearly 50% in IBD<sup>19</sup>. A large evaluation of the association between thyroid dysfunction and UC was conducted by Järnerot et al<sup>20</sup> in 1975; the authors investigated the prevalence of thyroid enlargement and hyperthyroidism in a cohort of 300 UC patients and 600 controls. A history of thyrotoxicosis was present in 3.7 percent of the UC patients vs. 0.8 percent of controls (*p* greater than 0.01). In more than half of these patients hyperthyroidism preceded the diagnosis of UC by years. However, the increased prevalence of hyperthyroidism in UC has been questioned by a more recent study by Casella et al<sup>21</sup>, who evaluated the prevalence of thyroid dysfunction in an Italian cohort of 162 UC patients followed for 4 years, compared with 5000 control subjects. Among UC cases, only 1 patient showed hyperthyroidism and 3 had hypothyroidism. Thus, the prevalence of dysthyroidism was significantly lower than in control population (2.5 vs. 7.4%, respectively).

A common autoimmune basis has been advocated to explain the coexistence of UC and dysthyroidism. In fact, the presence of autoantibodies against tropomyosins expressed in colonic and jejunal epithelial cells and intestinal smooth muscle in UC patients supported a possible autoimmune pathogenesis of UC and a probable cross-reactivity with other cells<sup>22-24</sup>. Other possible mechanisms are a Th1/Th2 response imbalance<sup>9,25</sup>, the possible increased prevalence of iodine deficiency in UC patients<sup>26</sup> and the sharing of certain single-nucleotide polymorphisms (SNPs) in the chromosome 4q27 region containing the *IL2* and *IL21* genes<sup>27</sup>.

Although thyroid diseases are not considered extraintestinal manifestations of UC, there are some evidences that dysthyroidism may exacerbate UC symptoms or modify the response to therapy<sup>6,18,28</sup>.

### Conclusions

To our knowledge, the case presented here is the first in which a third thyrotoxicosis crisis in Graves' disease acted as a trigger of UC, in a patient with no previous history of inflammatory bowel diseases or diarrhoea or other related symptoms.

### Conflict of Interest

The Authors declare that they have no conflict of interests.

### References

- 1) ANANTHAKRISHNAN AN. Epidemiology and risk factors for IBD. *Nat Rev Gastroenterol Hepatol* 2015; 12: 205-217.
- 2) SILVERBERG MS, SATSANGI J, AHMAD T, ARNOTT ID, BERNSTEIN CN, BRANT SR, CAPRILLI R, COLOMBEL JF, GASCHE C, GEBOES K, JEWELL DP, KARBAN A, LOFTUS EV, JR., PENAS AS, RIDDELL RH, SACHAR DB, SCHREIBER S, STEINHART AH, TARGAN SR, VERMEIRE S, WARREN BF. Toward an integrated clinical, molecular and serological classification of inflammatory bowel disease: report of a Working Party of the 2005 Montreal World Congress of Gastroenterology. *Can J Gastroenterol* 2005; 19 Suppl A: 5A-36A.
- 3) SCHROEDER KW, TREMAINE WJ, ILSTRUP DM. Coated oral 5-aminosalicylic acid therapy for mildly to moderately active ulcerative colitis. A randomized study. *N Engl J Med* 1987; 317: 1625-1629.
- 4) TRUETOVE SC, WITTS LJ. Cortisone in ulcerative colitis; final report on a therapeutic trial. *Br Med J* 1955; 2: 1041-1048.
- 5) DIGNASS A, LINDSAY JO, STURM A, WINDSOR A, COLOMBEL JF, ALLEZ M, D'HAENS G, D'HOORE A, MANTZARIS G, NOVACEK G, ORESLAND T, REINISCH W, SANS M, STANGE E, VERMEIRE S, TRAVIS S, VAN ASSCHE G. Second European evidence-based consensus on the diagnosis and management of ulcerative colitis part 2: Current management. *J Crohns Colitis* 2012; 6: 991-1030.
- 6) DAHER R, YAZBECK T, JAOUDE JB, ABOUDD B. Consequences of dysthyroidism on the digestive tract and viscera. *World J Gastroenterol* 2009; 15: 2834-2838.
- 7) KIM D RJ. Gastrointestinal manifestations of systemic diseases. *Gastrointestinal and liver disease: Pathophysiology/ diagnosis/management*. Philadelphia: Saunders; 2002.

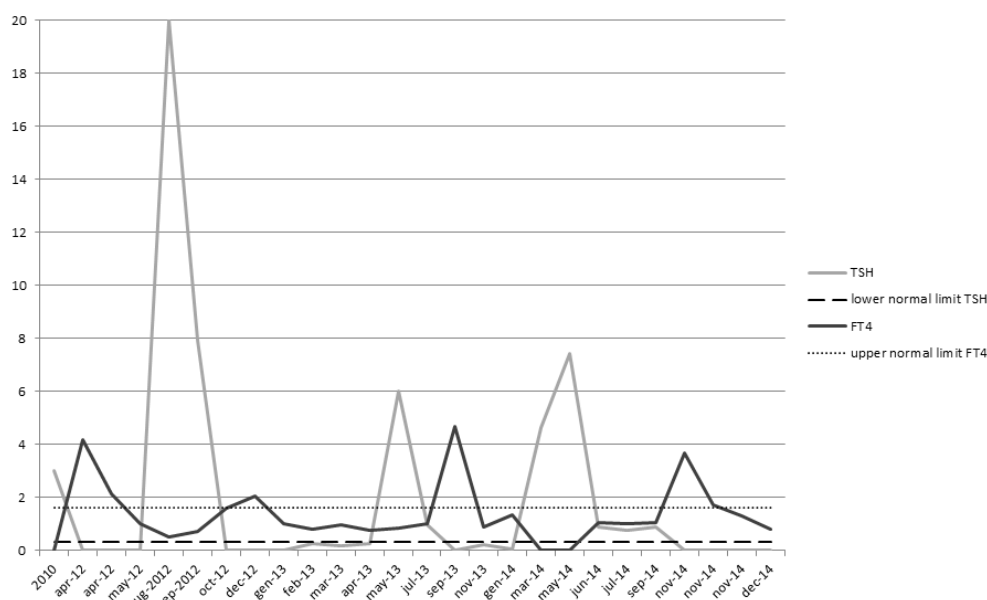


Figure 1. The graphic shows the value of TSH and FT4 since the diagnosis of Graves' disease to the diagnosis of ulcerative colitis.

- 8) TRIANTAFILLIDIS JK, CHERAKAKIS P, ZERVAKAKIS A, THEODOROU M. Coexistence of hyperthyroidism and ulcerative colitis: Report of 4 cases and a review of the literature. *Ital J Gastroenterol* 1992; 24: 494-497.
- 9) BONAPACE ES, SRINIVASAN R. Simultaneous occurrence of inflammatory bowel disease and thyroid disease. *Am J Gastroenterol* 2001; 96: 1925-1926.
- 10) KU E, ANANTHAPANYASUT W, CAMPESE VM. IgA nephropathy in a patient with ulcerative colitis, Graves' disease and positive myeloperoxidase ANCA. *Clin Nephrol* 2012; 77: 146-150.
- 11) MODEBE O. Autoimmune thyroid disease with ulcerative colitis. *Postgrad Med J* 1986; 62: 475-476.
- 12) NISHIMURA M, YAMAMOTO T, IJIMA H, MORIWAKI Y, TAKAHASHI S, HADA T. Basedow's disease and chronic ulcerative colitis: A case report and review of the Japanese literature. *Intern Med* 2001; 40: 44-47.
- 13) PAI S, MEHTA R, RAO G. Thyrotoxicosis co-existing with ulcerative colitis. *Indian J Gastroenterol* 2005; 24: 263-264.
- 14) PERETIANU D, DUMITRESCU C, LOTREANU V. Association of hyperthyroidism and ulcerative colitis. Report of two cases. *Med Interne* 1990; 28: 41-45.
- 15) IYER SK, KARLSTADT RG. Hyperthyroidism and ulcerative colitis: Report of two cases and a review of the literature. *J Natl Med Assoc* 1980; 72: 127-131.
- 16) CLUBB JS, BLACK PJ, WALLACE DC. An association of thyroid disease, ulcerative colitis and diabetes mellitus. Report of three cases in young women. *Australas Ann Med* 1970; 19: 159-164.
- 17) POWELL JR, SHAPIRO HA, CARBONE JV. Therapeutic problems of ulcerative colitis with hyperthyroidism. *Am J Gastroenterol* 1968; 50: 116-124.
- 18) SNOOK JA, DE SILVA HJ, JEWELL DP. The association of autoimmune disorders with inflammatory bowel disease. *Q J Med* 1989; 72: 835-840.
- 19) BIANCHI GP, MARCHESINI G, GUELI C, ZOLI M. Thyroid involvement in patients with active inflammatory bowel diseases. *Ital J Gastroenterol* 1995; 27: 291-295.
- 20) JARNEROT G, AZAD KHAN AK, TRUELOVE SC. The thyroid in ulcerative colitis and Crohn's disease. II. Thyroid enlargement and hyperthyroidism in ulcerative colitis. *Acta Med Scand* 1975; 197: 83-87.
- 21) CASELLA G, DE MARCO E, ANTONELLI E, DAPERNO M, BALDINI V, SIGNORINI S, SANNELLA F, MORELLI A, VILANACCI V, BASSOTTI G. The prevalence of hyper- and hypothyroidism in patients with ulcerative colitis. *J Crohns Colitis* 2008; 2: 327-330.
- 22) GENG X, BIANCONE L, DAI HH, LIN JJ, YOSHIZAKI N, DASGUPTA A, PALLONE F, DAS KM. Tropomyosin isoforms in intestinal mucosa: Production of autoantibodies to tropomyosin isoforms in ulcerative colitis. *Gastroenterology* 1998; 114: 912-922.
- 23) TANIGUCHI M, GENG X, GLAZIER KD, DASGUPTA A, LIN JJ, DAS KM. Cellular immune response against tropomyosin isoform 5 in ulcerative colitis. *Clin Immunol* 2001; 101: 289-295.
- 24) MIRZA ZK, SASTRI B, LIN JJ, AMENTA PS, DAS KM. Autoimmunity against human tropomyosin isoforms in ulcerative colitis: Localization of specific human tropomyosin isoforms in the intestine and extraintestinal organs. *Inflamm Bowel Dis* 2006; 12: 1036-1043.
- 25) ROURA-MIR C, CATALFAMO M, SOSPEDRA M, ALCALDE L, PUJOL-BORRELL R, JARAQUEMADA D. Single-cell analysis of intrathyroidal lymphocytes shows differential cytokine expression in Hashimoto's and Graves' disease. *Eur J Immunol* 1997; 27: 3290-3302.
- 26) JARNEROT G. The thyroid in ulcerative colitis and crohn's disease. I. Thyroid radioiodide uptake and urinary iodine excretion. *Acta Med Scand* 1975; 197: 77-81.
- 27) GLAS J, STALLHOFER J, RIPKE S, WETZKE M, PFENNIG S, KLEIN W, EPPLEN JT, GRIGA T, SCHIEMANN U, LACHER M, KOLETZKO S, FOLWACZNY M, LOHSE P, GOKE B, OCHSENKUHN T, MULLER-MYHSOK B, BRAND S. Novel genetic risk markers for ulcerative colitis in the IL2/IL21 region are in epistasis with IL23R and suggest a common genetic background for ulcerative colitis and celiac disease. *Am J Gastroenterol* 2009; 104: 1737-1744.
- 28) TRIANTAFILLIDIS JK, MANOUSSAKIS CA, TSAFARAS C, KOUTSORIZOF A. Coexistence of thyrotoxicosis and exacerbation of ulcerative colitis. *Am J Gastroenterol* 1990; 85: 908-910.