

Aortic vulnerability to COVID-19: is the microvasculature of vasa vasorum a key factor? A case report and a review of the literature

G. FAA^{1,2}, C. GEROSA¹, D. FANNI¹, D. BARCELLONA³, G. CERRONE¹, G. ORRÙ⁴, A. SCANO⁴, F. MARONGIU³, J.S. SURI⁵, R. DEMONTIS⁶, M. NIOI⁶, E. D'ALOJA⁶, G. LA NASA⁷, L. SABA⁸

¹Division of Pathology, Department of Medical Sciences and Public Health, AOU of Cagliari, University of Cagliari, Cagliari, Italy

²Department of Biology, College of Science and Technology, Temple University, Philadelphia, PA, USA

³Internal Medicine, Department of Medical Sciences and Public Health, AOU of Cagliari, University of Cagliari, Cagliari, Italy

⁴Section of Microbiology, Department of Surgical Sciences, AOU of Cagliari, University of Cagliari, Cagliari, Italy

⁵Stroke Monitoring and Diagnostic Division, AtheroPoint™, Roseville, CA, USA.

⁶Legal Medicine, Department of Medical Sciences and Public Health, AOU of Cagliari, University of Cagliari, Cagliari, Italy

⁷Hematology, Department of Medical Sciences and Public Health, Businco Hospital ARNAS Brotzu, University of Cagliari, Cagliari, Italy

⁸Division of Radiology, Department of Medical Sciences and Public Health, AOU of Cagliari, University of Cagliari, Cagliari, Italy

Abstract. – Arterial thromboembolic complications reported in patients with COVID-19 infection suggested that SARS-CoV-2 can trigger atherosclerotic plaque vulnerability. While endothelial cells in healthy subjects protect against thrombus formation, after injury they show prothrombotic activity. In addition, it has been hypothesized that “cytokine storm” might stimulate the production of neo-platelets triggering an abnormal “immunothrombosis” responsible for the hypercoagulable state induced in COVID-19 patients. The aim of this study is to report a case of severe COVID-19 infection characterized by the occurrence of microthrombosis in the vasa vasorum of the aorta.

A 67-year-old male patient, in good health status and without comorbidities, who underwent a severe COVID-19 infection with fatal outcome, showed scattered aortic atherosclerotic plaques, characterized by multiple occlusive micro-thromboses in the vasa vasorum, spread out lymphocytic infiltrates and foci of endotheliitis and endothelial detachment.

This case report confirms the previously described thrombotic involvement of vasa vasorum in COVID-19. The occurrence of the synchronous damage involving both the lumen surface (endothelial dysfunction, endotheliitis and endothelial detachment) and the adventitia (inflamma-

tion and occlusive thrombosis of vasa vasorum) could be the key points related to the fatal outcome of the SARS-CoV-2 patients. In our opinion, vasa vasorum thrombosis may thus initiate an atherogenic process that could be characterized by a much more rapid development.

Key Words:

Endotheliitis, COVID-19, SARS-CoV2, Thromboembolic complications, Atherosclerotic plaque.

Introduction

Arterial thromboembolic complications represent a common finding in COVID-19 infected patients¹ who show a disproportionately higher incidence of myocardial infarction and cerebral ischemic stroke²⁻⁵. Collectively, these data⁶ suggest that SARS-CoV-2 could be able to trigger atherosclerotic plaque vulnerability. In spite of our better knowledge on the multiple molecular pathways triggered by COVID-19⁷, the linkage between SARS-CoV-2 and the development of a pro-thrombotic phenotype has not been clarified yet.

All the actions of the hemostatic system are aimed to maintain people distant from both Scylla (bleeding) and Charybdis (thrombosis)⁸. In healthy subjects, the hemostatic system is able to stop bleeding events by both platelets and the coagulation cascade activation. Moreover, the hemostatic system rules a delicate balance between avoiding fibrin formation and deposition within the normal blood vessels. Indeed, fibrinolysis represents a defensive mechanism, being able to remove fibrin from the endothelial cells. Fibrinolysis is in turn well balanced by a fine control of its inducers and inhibitors⁹. Finally, endothelial cells can produce substances, such as nitric oxide, prostacyclin and an ADP deactivation molecule, which maintain platelets distant from their layer thus avoiding their aggregation with consequent involvement in the thrombotic process¹⁰. Basically, endothelial cells in healthy subjects protect the host from thrombus formation, and they become strongly prothrombotic if a direct injury occurs.

Multiple bits of evidence^{11,12} show that, in subjects affected by SARS-CoV-2, endothelium is under attack: lymphocytic endotheliitis and circulating endothelial cells, a typical marker of endothelial injury¹³, have been reported following severe COVID-19 infection. Recently, it has been hypothesized that “cytokine storm” caused by SARS-CoV-2 might stimulate megakaryoblasts to produce neo-platelets, triggering an abnormal “immunothrombosis” responsible for the hypercoagulative state typical of COVID-19 infection¹⁴.

Case Report

Here we report a case of a 67-year-old male patient, in good health status and without co-

morbidities, who underwent a severe COVID-19 infection, with fatal exitus for respiratory failure. Further clinical information is not publicly available because of the sensitive nature of the data; request to access that material from qualified researchers trained in human subject confidentiality protocols may be sent to D'Aloja at Cagliari University through the corresponding author. At autopsy, aorta showed the presence of scattered atherosclerotic plaques. Histology revealed the presence of multiple occlusive micro-thromboses in the vasa vasorum of the aortic wall (Figures 1 and 2). Moreover, lymphocytic infiltrates were observed around the wall of the aortic vasa vasorum (Figure 3). The study of the aortic endothelium in the correspondence of vasa vasorum microthrombi showed foci of endotheliitis (Figure 4) and endothelial detachment (Figures 2, 3 and 4).

Discussion

Our data confirm previous findings on the thrombotic involvement of vasa vasorum in COVID-19 patients¹⁴ and suggest that aortic vasa vasorum thrombosis could represent a key factor which might link the severe forms of SARS-CoV-2 with the transformation of a stable plaque into an unstable lesion⁶, with thromboembolic consequences.

All these data taken together support the hypothesis that the influence of SARS-CoV-2 on large vessels such as aorta is more complex than previously thought. The occurrence of virus attack on key targets may be hypothesized:

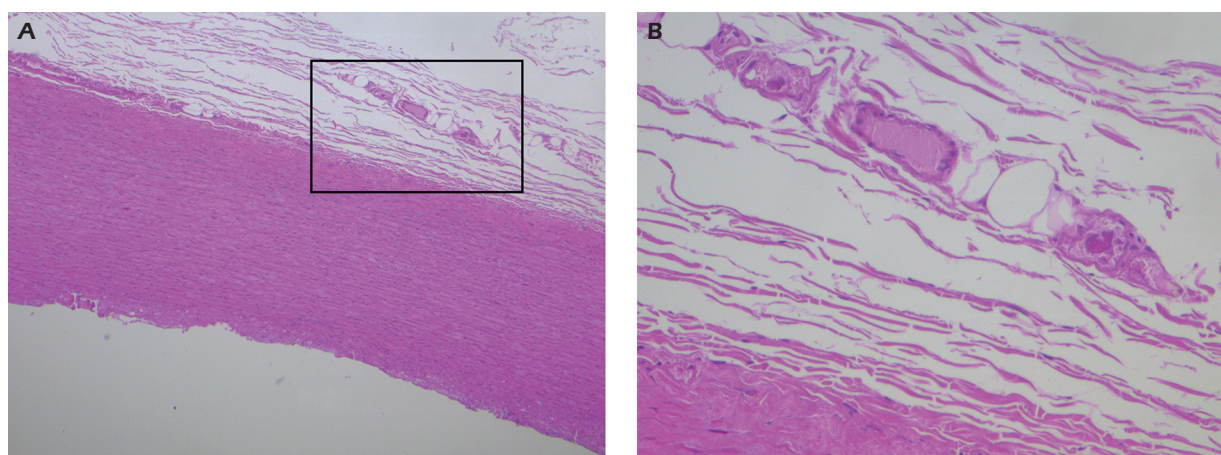


Figure 1. Full thickness of aortic wall at low power view (A original magnification 50×) showing occlusive micro-thromboses in the vasa vasorum at high power field (B original magnification 200×).

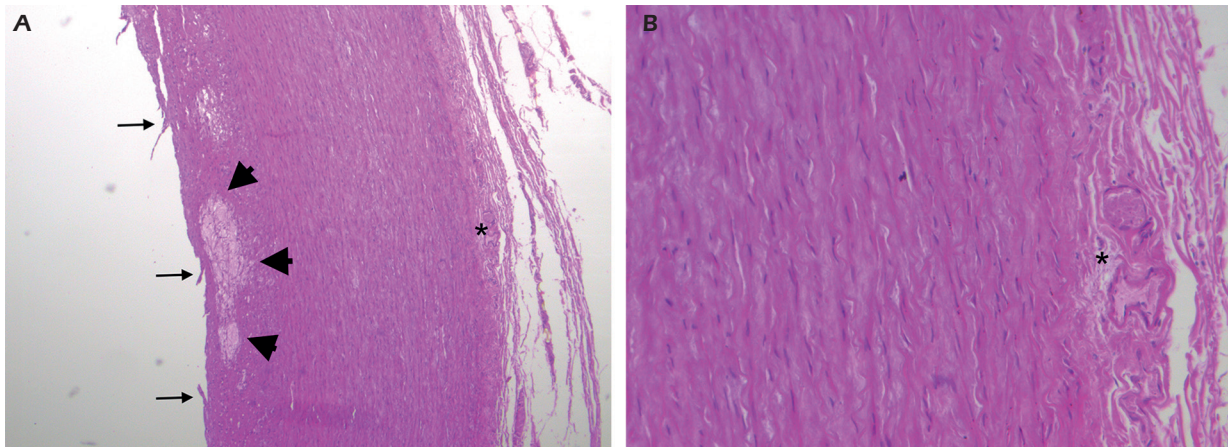


Figure 2. Full thickness of aortic wall at low power view showing endothelial detachment (*arrows*), plaque (*arrowheads*) occlusive micro-thromboses in the vasa vasorum (*) (A original magnification 50×); micro-thromboses of the vasa vasorum at high power field (B original magnification 200×).

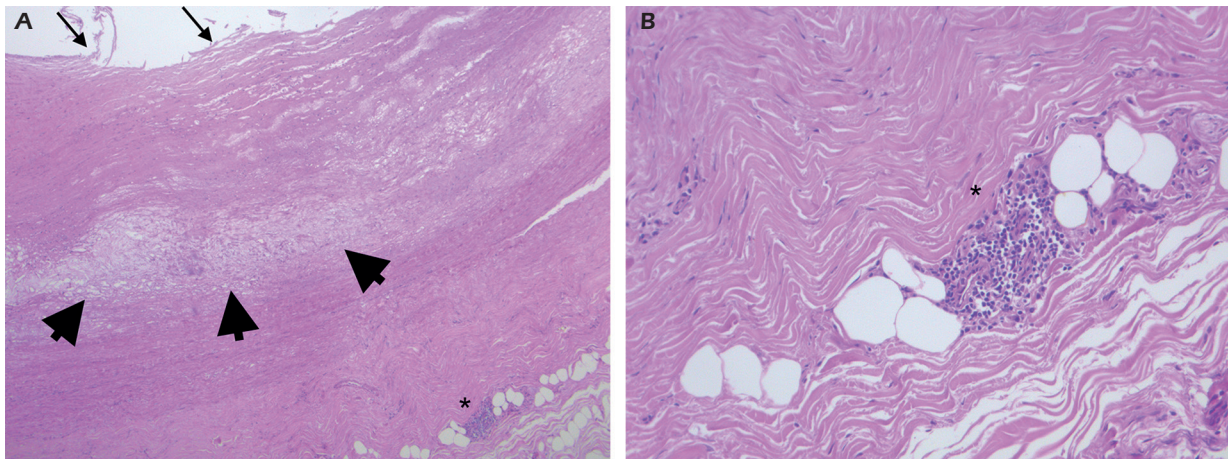


Figure 3. Aortic wall showing endothelial detachment (*arrows*), plaque (*arrowheads*) and lymphocytic infiltrates around vasa vasorum (A original magnification 50×); high power view of the lymphocytic infiltrates detected around vasa vasorum (B original magnification 200×).

at the lumen surface, COVID-19 might cause endothelial dysfunction, endotheliitis and endothelial detachment. However, in the adventitia, vasa vasorum are filled, with inflammation and occlusive thrombosis. This phenomenon may be responsible of the decrease of blood and nutrients that supply the arterial wall thus favoring all the pathological features described above. This statement is supported by an old experimental observation which demonstrated that the occlusion of vasa vasorum leads to the development of vascular lesions¹⁵. In SARS-CoV-2 patients, vasa vasorum thrombosis may initiate an atherogenic process¹⁶ that could be much more rapid in development.

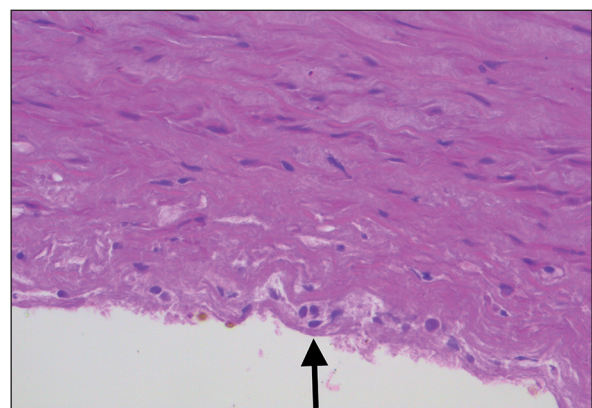


Figure 4. Foci of endotheliitis (*arrow*) in the aortic endothelium seen in correspondence of vasa vasorum micro-thrombi (original magnification 400×).

Conclusions

The thrombosis of the vasa vasorum should be taken into account in the pathophysiology of the COVID-19 infection as a crucial target of the virus in terms of arterial damage progression. The severe effects of COVID-19 infection in the vascular system could therefore be explained by a progressive multi-level injury, so suggesting that a unique therapeutical target might not be enough to control the effect of these virus attacks. A role of anti-platelet agents along with anticoagulation could be a further anti-thrombotic strategy but new well-planned trials are needed to confirm or not our hypothesis.

Conflict of Interest

The Authors declare that they have no conflict of interests.

References

- 1) Indes JE, Koleilat I, Hatch AN, Choinski K, Jones DB, Aldailami H, Billett H, Denesopolis JM, Lipsitz E. Early experience with arterial thromboembolic complications in patients with COVID-19. *J Vasc Surg* 2021; 73: 381-389.e1.
- 2) Helms J, Kremer S, Merdji H, Clere-Jehl R, Schenck M, Kummerlen C, Collange O, Boulay C, Fafi-Kremer S, Ohana M, Anheim M, Meziani F. Neurologic Features in Severe SARS-CoV-2 Infection. *N Engl J Med* 2020; 382: 2268-2270.
- 3) Shi S, Qin M, Shen B, Cai Y, Liu T, Yang F, Gong W, Liu X, Liang J, Zhao Q, Huang H, Yang B, Huang C. Association of Cardiac Injury With Mortality in Hospitalized Patients With COVID-19 in Wuhan, China. *JAMA Cardiol* 2020; 5: 802.
- 4) Guo T, Fan Y, Chen M, Wu X, Zhang L, He T, Wang H, Wan J, Wang X, Lu Z. Cardiovascular Implications of Fatal Outcomes of Patients With Coronavirus Disease 2019 (COVID-19). *JAMA Cardiol* 2020; 5: 811.
- 5) Mahammedi A, Saba L, Vagal A, Leali M, Rossi A, Gaskill M, Sengupta S, Zhang B, Carriero A, Bachir S, Crivelli P, Paschè A, Premi E, Padovani A, Gasparotti R. Imaging of Neurologic Disease in Hospitalized Patients with COVID-19: An Italian Multicenter Retrospective Observational Study. *Radiology* 2020; 297: E270-E273.
- 6) Saba L, Gerosa C, Wintermark M, Hedin U, Fanni D, Suri JS, Balestrieri A, Faa G. Can COVID19 trigger the plaque vulnerability-a Kounis syndrome warning for 'asymptomatic subjects'. *Cardiovasc Diagn Ther* 2020; 10: 1352-1355.
- 7) Saba L, Gerosa C, Fanni D, Marongiu F, La Nasa G, Caocci G, Barcellona D, Balestrieri A, Coghe F, Orru G, Coni P, Piras M, Ledda F, Suri JS, Ronchi A, D'Andrea F, Cau R, Castagnola M, Faa G. Molecular pathways triggered by COVID-19 in different organs: ACE2 receptor-expressing cells under attack? A review. *Eur Rev Med Pharmacol Sci* 2020; 24: 12609-12622.
- 8) Barcellona D, Marongiu F. The hemostatic system. 1st Part. *J Pediatr Neonatal Individ Med* 2020; 9: e090106.
- 9) Kwaan H, Lisman T, Medcalf RL. Fibrinolysis: Biochemistry, Clinical Aspects, and Therapeutic Potential. *Semin Thromb Hemost* 2017; 43: 113-114.
- 10) van der Meijden PEJ, Heemskerk JWM. Platelet biology and functions: new concepts and clinical perspectives. *Nat Rev Cardiol* 2019; 16: 166-179.
- 11) Varga Z, Flammer AJ, Steiger P, Haberecker M, Andermatt R, Zinkernagel AS, Mehra MR, Schuepbach RA, Ruschitzka F, Moch H. Endothelial cell infection and endotheliitis in COVID-19. *Lancet Lond Engl* 2020; 395: 1417-1418.
- 12) McGonagle D, Bridgewood C, Ramanan AV, Meaney JFM, Watad A. COVID-19 vasculitis and novel vasculitis mimics. *Lancet Rheumatol* 2021; 3: e224-33.
- 13) Guervilly C, Burtsey S, Sabatier F, Cauchois R, Lano G, Abdili E, Daviet F, Arnaud L, Brunet P, Hraiech S, Jourde-Chiche N, Koubi M, Lacroix R, Pietri L, Berda Y, Robert T, Degioanni C, Velièr M, Papazian L, Kaplanski G, Dignat-George F. Circulating Endothelial Cells as a Marker of Endothelial Injury in Severe COVID -19. *J Infect Dis* 2020; 222: 1789-1793.
- 14) Roncati L, Manenti A, Manco G, Farinetti A, Mattioli A. The COVID-19 Arterial Thromboembolic Complications: From Inflammation to Immunothrombosis Through Antiphospholipid Autoantibodies. *Ann Vasc Surg* 2021; 72: 216-217.
- 15) Nakata Y, Shionoya S. Vascular lesions due to obstruction of the vasa vasorum. *Nature* 1966; 212: 1258-1259.
- 16) Boyle EC, Sedding DG, Haverich A. Targeting vasa vasorum dysfunction to prevent atherosclerosis. *Vascul Pharmacol* 2017; 96-98: 5-10.