

# Closed incision Negative Pressure Therapy (ciNPT): does depression affect underlying tissues?

D. GUI, A. CASAROLI, A. BORRELLO, S. MAGALINI

Department of Emergency and Trauma Surgery, Policlinico Gemelli, Catholic University of Sacred Heart, Rome, Italy

**Abstract. – OBJECTIVE:** Closed incision Negative Pressure Therapy (ciNPT) has become a widespread practice in recent years. Described benefits concern the rate of wound infection, based on the assumption that negative pressure spreads inside the wound removing collections and edema. The study aims to clarify this technical point, on which experimental scientific evidence is lacking in literature.

**MATERIALS AND METHODS:** In the experimental animal (newly sacrificed pig), the pressure was measured for hours at the bottom of three surgical abdominal wounds sutured by planes and dressed in negative pressure therapy commercial sets.

**RESULTS:** The depression applied to the surface of the sutured wounds (ciNPT) is not transmitted to the underlying tissues. The blue dye deposited in the deep layer of the wounds didn't surface as an effect of ciNPT.

**CONCLUSIONS:** The possible benefits deriving from the application of negative pressure on sutured wounds must depend on a different mechanism from the diffusion of depression in the wound planes and in the underlying tissues.

*Key Words:*

ciNPT, Depression, Wound.

## Introduction

The use of Negative Pressure (NP) for open wounds (NP Wound Therapy – NPWT) from trauma or infections has spread over the last twenty years. It realizes an effective drainage of secretions through the foam (or gauze) covering the wound and connected to a device that regulates and maintains the depression.

Recently, NPWT use has been extended to surgical wounds closed with sutures and re-named “closed incision Negative Pressure Therapy” (ciNPT). ciNPT is applied directly in the operating room and maintained for a week or more<sup>1</sup>. ciNPT has become popular favored by the spread of dis-

posable commercial devices which are small and low cost. If the dressing stays clean, it will be removed at complete wound healing. An advantage is a reduction in the costs of conventional wound care (personnel and dressing changes).

Healing of the closed surgical wound is conditioned by a multiplicity of biological factors, causing for example the appearance of edema or collections with consequent risk of infection and the final scar aspect which can be hypertrophic and flawed<sup>1</sup>.

The use of ciNPT was initially privileged in larger surgical wounds or when conventional dressings were more difficult or painful. The success of this therapy was dictated, later, by the aim of preventing complications of an exudative and infectious nature, for example in all cases in which obesity represents a risk factor for the onset of infections or in the reconstruction of the abdominal wall<sup>2</sup>. Furthermore, the use of ciNPT has been favorably received in the field of plastic surgery, as in the case of the breast (including oncology), to obtain a more aesthetic wound.

The ciNPT benefits has not been proven without doubt in the series reported in literature<sup>1,3-5</sup>, even if a generally positive conviction has taken root in the medical and nursing fields. This belief is based on the certainty that the depression applied to the surface is transferred, directly or indirectly, inside the wound and in the layers below the skin, realizing its property of removing secretions and collections, preventing suppuration<sup>6</sup>. A similar belief in the diffusion of depression within the underlying tissues would justify the increase in microcirculation<sup>7</sup> and the greater softness of the final scar.

In the literature, however, very little is described on the biomechanical effects associated with the application of NP therapy both on the surface of the closed surgical wound and in correspondence to the underlying tissues<sup>4</sup>. With this study, we wanted to investigate in a biological model the effective spread of depression in the

wound planes and surrounding tissues, in the event that a ciNPT is applied to the surface of a surgical wound closed by stitches.

## Materials and Methods

The study described in this manuscript was approved by the Local Animal Ethics Committee of the Catholic University of Sacred Heart (Rome, Italy). For the experiment, a pig weighing about 30 kg, just sacrificed in compliance with the institution's guidelines, was used in the Experimental Lab of the Catholic University of the Sacred Heart (Rome, Italy). A dead animal was chosen to perform the experiment because, eliminating the coagulation component of the blood above and inside the wound, a more favorable condition for the spread of depression in the wound planes was created. Abdominal pig skin was disinfected and purged of bristles and cut with a surgical scalpel. Three incisions (10 cm long) were performed: one medial incision spanning the umbilicus deepened to the fascial plane, sparing the fascia itself; two in the iliac fossa, both on the right and the left, deepened into the muscle plane. A spiral surgical drain (silicon drain, 10 FR round, hubless; Ethicon, NJ, USA) was positioned on the bottom of the wounds (average distance in depth from skin 1.5 cm), above the fascia or muscles, and its terminal end was pulled out of the skin at 15 cm from the wound margins. The subcutaneous tissue was sutured with stitches

(Vicryl 3/0, 1 cm apart) and the skin was closed with Proximate clips (Ethicon, NJ, USA) (Figure 1) as in use in abdominal surgery.

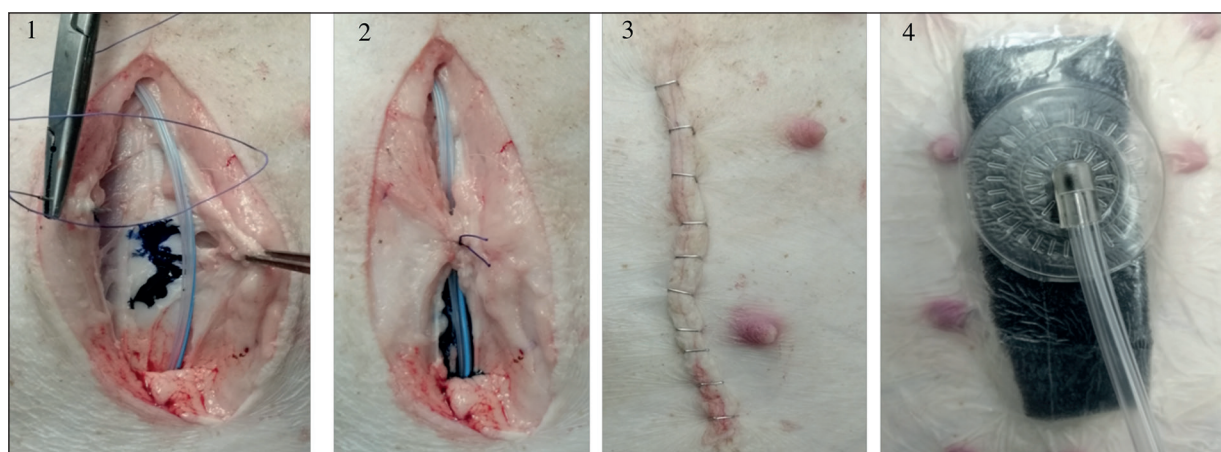
Finally, ciNPT was applied over the wound, with a conventional commercial NPWT kit with a polyurethane sponge (Hospotica, Rome, Italy).

The wounds were put under depression with commercial standard NPWT devices (MINI-VAC, Hospotica, Rome, Italy) for 3 hours, realizing a ciNPT. The depression levels were set in the order of those used in the clinic by commercial ciNPT devices: continuous -80 mmHg for the first hour, continuous -125 mmHg for the second hour, oscillating between -120/-70 mmHg, period of 120 seconds, for the third hour. The depression values inside the wound dressing and through the drain (inside the wound planes) were simultaneously measured and recorded with independent digital pressure gauges (VAC-Test SIGMA Engineering s.r.l., Rome, Italy).

Before suturing the subcutaneous layer, methylene blue dye (0.5 ml) was deposited over the fascia/muscles. At the end of the entire study, the dressing was disassembled to check for dye on the surface (skin) and inside the depth of the wounds over the subcutaneous layer.

## Results

At all levels of depression exerted in the wound dressing (ciNPT), the pressure recorded at the deep planes (over the fascia/muscles) did not change from the baseline, showing that the ex-



**Figure 1.** Common steps for the three wounds. **1,** Bottom of the wound with 0.5 ml of blue dye dropped on it, and silicone drain in position (1.5 cm in depth from the skin). Forceps and suture are on the two sides of the subcutaneous layer. **2,** Subcutaneous layer sutured over the drain with sutures inserted at 1 cm distance. **3,** Skin sutured with Proximate clips. **4,** Black sponge and pad dressing before the application of depression.

ternal depression imposed in the dressing of the closed surgical wound is not transmitted inside the wound itself (Figure 2).

### Blue Test

Similarly, the ciNPT simulation did not aspirate the dye solution (methylene blue) deposited at the level of the deep plane of the wound itself. At the opening of the wounds, the dye was shown to remain under the subcutaneous layer in all 3 wounds (Figure 3).

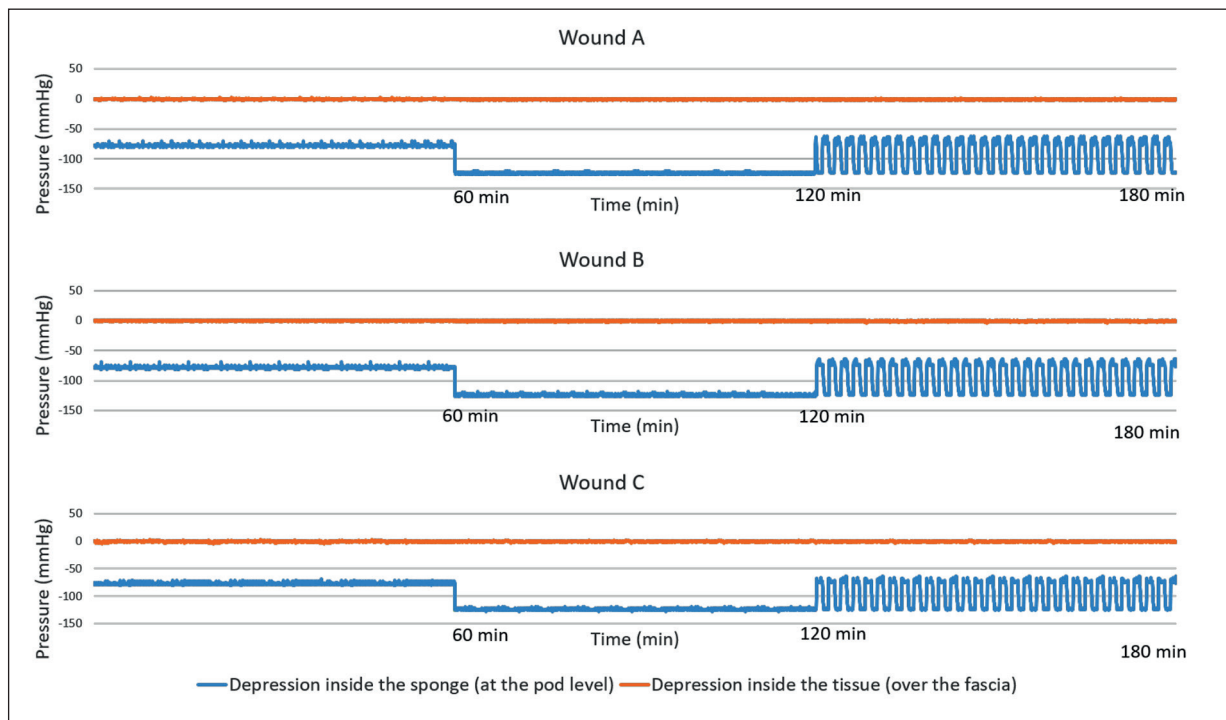
## Discussion

This experimental animal study demonstrates that, applying the vacuum dressing to a closed (sutured) surgical incision (ciNPT), the depression is not transmitted into the deep planes of the wound, even at the highest levels of depression used in clinic, in continuous or intermittent setting. Using a dead animal, the experimental model avoided the blood clotting on the suture line that could contribute to make it impervious to the spread of depression. The simple suturing of wound's edges, by dealing with soft biological

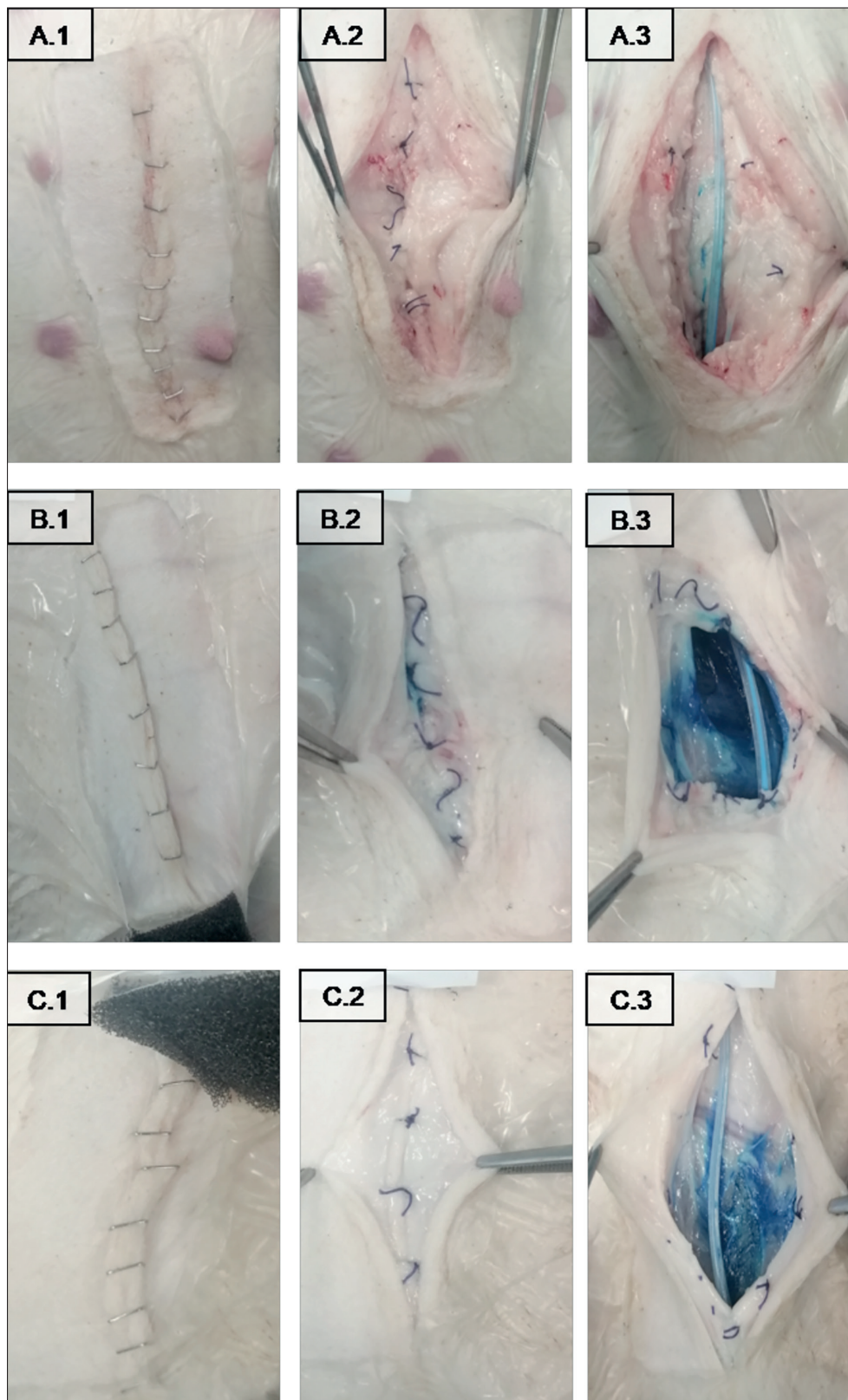
tissues that adapt to each other, creates a state of "tightness" for the passage of air and fluids. The colored solution introduced into the suprafascial plane mimics a serous collection, that is at the root of pus formation and wound infection. The fact that the solution was not aspirated by the ciNPT further confirms the lack of transmission of negative pressure in depth, in presence of a surgically sutured wound.

These results contradict the frequent assertion that ciNPT applied to closed surgical wounds is able to drain the serous or infected collections that form in depth, thereby acting as a tool for prevention of wound infection. If the depression applied on the surface does not reach the sites where the collections form, it is not possible to attribute to ciNPT a prophylactic action on wound infection through this mechanism of action.

Actually, other experimental work, conducted on parts of the abdominal wall obtained from corpses or dead animals, has produced similar results. In this case, the edges of the wound were not sutured together but simply joined or superimposed, unlike what happens in surgical wounds. The depression measured in depth was few mbar, and thus completely negligible<sup>8</sup>.



**Figure 2.** Pressure measured at the bottom of three closed wounds A, B, and C (orange) and inside the wound dressing (blue) during three consecutive tests of one hour each. During the first hour the imposed negative pressure on the device was -75 mmHg; -125 mmHg in the second hour; oscillating between -120/-70 mmHg, with a period of 120 sec, in the third hour.



**Figure 3.** Cutaneous, subcutaneous layers and bottom of wounds after three hours of applied depression. (A.1, B.1, C.1) The three closed incision skins after dressing removal. (A.2, B.2, C.2) Subcutaneous layers after Proximate clip removal. (A.3, B.3, C.3) Wound's bottoms after opening of the subcutaneous layer. The dye is confined under the subcutaneous layer.

Otherwise, studies have declared a benefit of the ciNPT in terms of prophylaxis of wound infection and serous fluid collections. Series often have gaps in sample homogeneity, randomization, statistics. However, a recent meta-analysis concluded positively for the infection prevention effect<sup>9</sup>. Therefore, this feature must find a different reason not depending on the transmission of depression into the wound depth<sup>5</sup>.

An advantage in the application ciNPT to this class of wounds may lie in the creation of an isolated environment, free from contamination and protected from any external infections, perhaps favored by frequent dressings of the conventional care. An effect of depression has also been reported in approaching the edges of the wound following the reduction of the transverse dimensions of the sponge, which drags the skin fixed with the adhesive film. It should be noted that this effect of bringing the edges of the wound closer together further militates against the possibility that the depression, creeping between the edges themselves, can be transmitted in depth.

The possibility that depression favors the micro vascular blood flow<sup>3</sup>, considered a cause of good and rapid recovery, must also be excluded for the same reasons already mentioned. Other mechanisms are not to be excluded, such as: stable wound temperature, better guaranteed by the ciNPT occlusive dressing; vascular reflex phenomena that will have to be investigated in future studies; or the demonstrated hypoxic conditions inside the dressing under depression that could reduce the bacterial growth<sup>10</sup>.

The present study was performed on the dead pig model. Limitations are the restricted time of measurements, that did not last for days, and the impossibility to evaluate possible effects of movement and blood flow on subcutaneous pressure.

## Conclusions

This study, for the first time, verifies the effective depression inside the wound tissues during ciNPT, concluding that the attribution of the anti-infective and anti-oedema effect cannot be explained by the exercise of depression on subcutaneous tissues, because this is not measurable in the aforementioned circumstances of closed surgical wounds.

## Conflict of Interest

The Authors declare that they have no conflict of interests.

## Acknowledgements

The authors are grateful to Experimental Lab of the Catholic University of the Sacred Heart in Rome for support.

## References

- 1) Scalise A, Calamita R, Tartaglione C, Pierangeli M, Bolletta E, Gioacchini M, Gesuita R, Di Benedetto G. Improving woundhealing and preventing surgical site complications of closed surgical incisions: a possible role of incisional negative pressure wound therapy. A systematic review of the literature. *Int Wound J* 2016; 13: 1260-1281.
- 2) Tran BNN, Johnson AR, Shen C, Lee BT, Lee ES. Closed-incision negative-pressure therapy efficacy in abdominal wall reconstruction in high-risk patients: a meta-analysis. *J Surg Res* 2019; 241: 63-71.
- 3) Frazee R, Manning A, Abernathy S, Isbell C, Isbell T, Kurek S, Regner J, Smith R, Papaconstantinou H. Open vs closed negative pressure wound therapy for contaminated and dirty surgical wounds: a prospective randomized comparison. *J Am Coll Surg* 2018; 226: 507-512.
- 4) Hussan SH, Limthongkul B, Humphreys T. The biomechanical properties of the skin. *Dermatol Surg* 2013; 39: 193-203.
- 5) Swanson EW, Cheng HT, Susarla SM, Lough DM, Kumar AR. Does negative pressure wound therapy applied to closed incisions following ventral hernia repair prevent wound complications and hernia recurrence? A systematic review and meta-analysis. *Plast Surg* 2016; 24: 113-118.
- 6) Animesh A. Management of closed incisions using negative-pressure wound therapy in orthopedic surgery. *Plast Reconstr Surg* 2019; 143: 21-26.
- 7) Biermann N, Geissler EK, Brix E, Schiltz D, Muehle C, Prantl L, Taeger CD. Pressure distribution and flow characteristics during negative pressure wound therapy. *J Tissue Viability* 2020; 29: 32-36.
- 8) Jansen-Winkel B, Niebisch S, Scheuermann U, Gockel I, Mehdorn M. Biomechanical effects of incisional negative wound pressure dressing: an ex vivo model using human and porcine abdominal walls. *Biomed Res Int* 2018; 2018: 7058461.
- 9) Normann G, Goh EL, Dumville JC, Shi C, Liu Z, Chiverton L, Stankiewicz M, Reid A. Negative pressure wound therapy for surgical wounds healing by primary closure. *Cochrane Database Syst Rev* 2019; 3: CD009261.
- 10) Biermann N, Geissler EK, Brix E, Schiltz D, Prantl L, Kehrer A, Taeger CD. Oxygen levels during negative pressure wound therapy. *J Tissue Viability* 2019; 28: 223-226.