

Endoscopic laser diverticulotomy in Zenker's diverticulum: experiences with basal wound sealing using a collagen-fibrin patch

M. KOCH¹, V. THIMSEN¹, M. TRAXDORF¹, J. ZENK², H. IRO¹, E. TREUTLEIN^{1,2}, K. MANTSOPOULOS¹

¹Department of Otorhinolaryngology, Head and Neck Surgery, Friedrich Alexander University of Erlangen–Nuremberg, Erlangen, Germany

²Department of Otorhinolaryngology, Head and Neck Surgery, University of Augsburg, Augsburg, Germany

E. Treutlein and K. Mantsopoulos are equal contributors

Abstract. – **OBJECTIVE:** Very few reports investigated techniques of closure of the basal wound area to reduce severe complications like mediastinitis after endoscopic laser diverticulotomy. In this study, we report our experiences after routine use of a collagen-fibrin sealant patch for basal wound covering after laser diverticulotomy in consideration of postoperative complications and recurrence rates.

PATIENTS AND METHODS: This retrospective study was conducted in a tertiary referral center and university hospital. Endoscopic laser diverticulotomies performed in our hospital between January 2006 and July 2018 were included. After complete transection of the laser septum of the diverticulum, we placed a collagen-fibrin patch onto the basal wound area to cover the opening to the mediastinum. Patient records were evaluated to assess the occurrence of perioperative complications, and the data were compared with those reported in the literature.

RESULTS: A total of 127 endoscopic laser diverticulotomies were performed in 109 patients (71 men, 38 women) suffering from Zenker's diverticulum. Morbidity rate was 0%, in particular no mediastinitis was observed. Mediastinal emphysema was observed in two patients (1.6%), and temporary or persistent recurrent nerve palsy in one patient (0.8%) each. The mean follow-up period was 71.6±5.16 months. Recurrent symptomatic diverticulum was observed in 19.3% of the patients.

CONCLUSIONS: These findings suggest that use of a collagen-fibrin sealant patch in endoscopic laser diverticulotomy may contribute to the safety of endoscopic controlled laser diverticulotomy without comprising the success rates.

Key Words:

Zenker's diverticulum, Treatment, CO₂ laser, Endoscopic, Minimally invasive, Complications.

Introduction

Various surgical techniques are nowadays used to treat Zenker's diverticulum (ZD) including transcervical approaches¹ as well as rigid or flexible endoscopic techniques². Minimally invasive, endoscopically guided techniques were favored more and more in the recent years in order to reduce frequency and severity of complications, morbidity and mortality. In particular in the older patients affected by ZD, methods using rigid endoscopes including endoscopic stapler diverticulotomy (ESD)³⁻⁹, and endoscopic CO₂ laser diverticulotomy (ELD) are now well-established^{7,10-14}. For transection of the septum also variable techniques using flexible endoscopes (FED)¹⁵⁻¹⁷ have been published including stapler techniques, laser techniques and various other modifications. Outcomes after transcervical approaches and rigid endoscopic procedures using ESD^{4,18}, ELD¹⁹⁻²¹ or using ESD and ELD²²⁻²⁴ were published. A literature review²⁵ compared the outcomes of transcervical approaches and endoscopic approaches using rigid devices. In the comprehensive review published by Verdonck and Morton²⁶ results after endoscopic procedures using a rigid or flexible endoscopes were compared. As a summary, endoscopic procedures were reported to be associated with significant shorter operating times, shorter hospital stays, lower rates of complications and postoperative morbidity but higher recurrence rates. Verdonck and Morton²⁶ reported an overall recurrence rate of around 20% for rigid endoscopic procedures, in comparison with 4-5% for transcervical surgery.

In comprehensive literature reviews analyzing results after FED, rates of postoperative bleeding were 2.95 and 6.6% and rates of perforation 3.4 and 5.3%. Recurrences were reported to be 11.3 and 13.7%, respectively. Hospital stays were short, but in a substantial part of the patients more than one, sometimes up to three procedures were necessary to achieve clinical success^{15,16}.

Although minimally invasive transoral endoscopically controlled diverticulotomy is preferred today, the surgeon always faces a conflict. It is between complete transection of the septum down to the fundus of the diverticulum to avoid recurrences or leaving an adequate tissue barrier at the bottom of the diverticulum, at the border with the mediastinum, to avoid complications. Bacterial mediastinitis is a major cause of perioperative morbidity and is the main cause of the perioperative mortality. Up to 1% were reported in the literature for transcervical and endoscopic techniques after use of rigid devices^{6,9,14,19,22,23,26,27} and 3 to over 5% when flexible endoscopes were used^{15,16}.

Efforts have been made to improve the safety of the procedures and avoid complications. In ESD, the basal defect is closed using two rows of clips; this offers the advantage of primary wound closure but is associated with incomplete exposure at the bottom of the pouch and a risk of a residual septum^{6,8,9,18}. This has been reported to have a favorable effect on complications, but not necessarily on recurrence rates³⁻⁹.

By contrast, ELD provides excellent visualization of the tissue layers, allowing maximum transection of the septum down to the fundus of the diverticulum and avoiding inappropriate opening of the mediastinum. Primary wound closure is desirable but has not been reported to be a routine part of this procedure. This may at least partly explain the higher rates of mediastinitis (1.0-1.5%) and postoperative bleeding (0.5-2.0%) reported in the literature^{7,10-14,26}.

To overcome this, attempts to achieve primary wound closure after ELD have been described^{11,12,28}. Sommer et al¹¹ compared primary wound closure using fibrin glue with closure using sutures in combination with fibrin glue. Anagiotos et al¹² compared cases without manipulation with those after wound closure using sutures and fibrin glue. Positive effects on complication rates and recurrence rates after additional suturing had been reported in both of these publications.

In FED closure of the basal wound area was described using the stapler technique²⁹ and endo-

scopic closure by clipping after submucosal tunneling (Z-POEM)³⁰⁻⁴¹.

The intention in this retrospective analysis was to examine the effects of a sealant patch consisting of collagen matrix covered with fibrinogen and thrombin on one side (TachoSil[®], Takeda, Berlin, Germany), which was used to cover the basal wound area after ELD, on the perioperative and postoperative course.

Patients and Methods

This retrospective study was carried out at the Department of Otorhinolaryngology, Head and Neck Surgery in the University of Erlangen-Nuremberg, Germany. The approval for the study was obtained from the Local Institutional Review Board of Friedrich Alexander University of Erlangen-Nuremberg. Informed consent was obtained from all study participants. Patients being treated for ZD using ELD between January 2006 and July 2018 were included. The investigation focused on the possible impact on postoperative complications after attaching a sealing patch to the basal tissue. The patients' medical records were analyzed for age and sex, type and duration of preoperative symptoms, size of the diverticulum, length of the operation, intraoperative complications (e.g., invasion of the mediastinum), postoperative complications (bleeding, increase of C-reactive protein, white blood cell count, fever, thoracic pain, pneumo-mediastinum, paralysis of vocal cord), length of hospital stay, and recurrences. The size of the diverticulum was calculated using video fluoroscopy for assessment of the radiologic stage according to the Brombart classification^{42,43}.

ELD was carried out with microscopic control using a carbon dioxide laser after insertion of a Weerda distending diverticuloscope. After placement of a nasogastric feeding tube, the septum and the bottom of the diverticulum pouch were exposed. A moist pad was used to protect the mucosa of the esophagus and pharynx from accidental laser injury. With microscopic viewing, the diverticular septum was cut down along the midline until the adventitia covering the mediastinal adipose tissue was exposed. A TachoSil[®] fibrin sealant patch was placed on the adventitia layer for wound sealing at the end of each procedure. This additional measure took about 3-5 minutes (Figures 1-4).

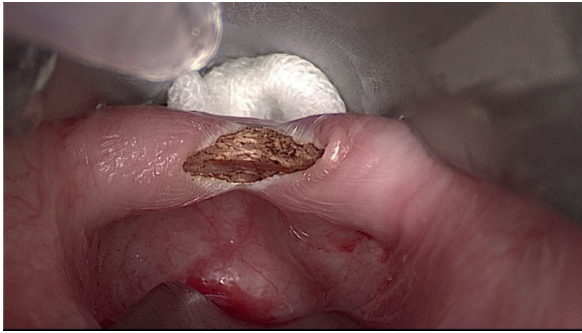


Figure 1. View to the exposed septum after the start of the CO₂ laser diverticulotomy in the midline.

The postoperative regimen usually included a hospital stay of 7 days and feeding through the nasogastric tube. Intravenous antibiotic treatment was started preoperatively and continued for 7 days postoperatively (2 g ampicillin/1 g sulbactam 3×/d or clindamycin 600 mg 3×/d). Symptoms, such as pain or dyspnea, were monitored daily. Vital parameters, body temperature and inflammation parameters were recorded. Further examinations, such as medical imaging, were performed in case of atypical symptoms or a rise in body temperature. Video fluoroscopy was performed 5-6 days after surgery. In case of unremarkable findings oral nutrition was started the same day. After discharge a follow-up visit was scheduled usually 2-3 months after surgery.

The follow-up was conducted by phone interviews in January 2020. A total of 109 patients were asked about any symptoms, in particular disturbed swallowing or dysphagia, regurgitation, and whether any further medical treatment was necessary. If the patients had died or were unable to take part in the phone interview for reasons

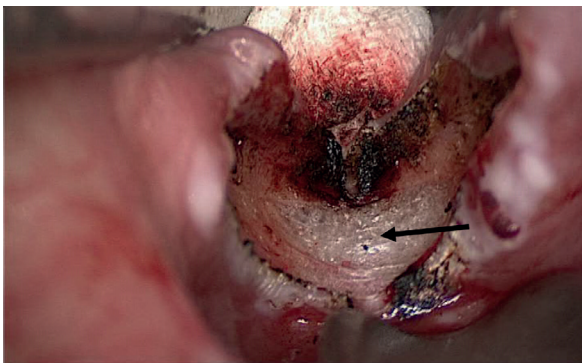


Figure 2. Situation after transection of the septum down to most basal parts of the fundus of the diverticulum, until the basal adventitial layer (black arrow) becomes visible.

such as severe illness or dementia, an attempt was made to obtain information from family members or from the physicians treating the patient.

Statistical Analysis

The software program IBM SPSS Statistics for Windows, version 24, was used (IBM Corporation, Armonk, NY, USA). All data are given as means ± SEM, range, and median. Bivariate correlations were calculated using the Pearson correlation coefficient. Differences between groups were calculated using the Mann-Whitney *U* test, and differences between categorical variables using the chi-squared test. The significance level was $p \leq 0.05$.

Results

127 ELDs were performed in 109 patients (71 men, 38 women). The Brombart radiologic stages were stage 1 in two patients (1.6%), stage 2 in 11 (8.7%), stage 3 in 48 (37.8%), and stage 4 in 51 patients (40.1%). It was not possible to determine the initial Brombart stage retrospectively in 15 patients (11.8%) because video fluoroscopy records from external radiology departments were not available and the Brombart stage was not stated in the radiology report (Figure 5).

In 28 patients (22%), the procedure was performed as a revision operation after failure of earlier treatments consisting of ESD in four patients, argon plasma coagulation in three, prior ELD in 20, and transcervical pouch resection in one.

The patients' mean age at the time of surgery was 68.1±8.87 years (median 70, range 50-90). The mean duration of preoperative symptoms was 21.8±2.79 months (median 12, range 1-180). The mean operating time was 51.8±2.10 minutes (me-




Figure 3. The collagen-fibrin sealing patch before and after (inset) its preparation for basal wound sealing.

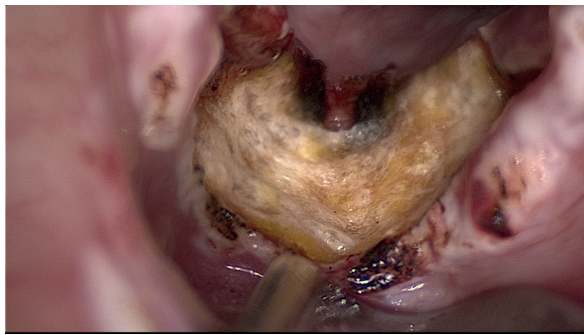


Figure 4. Situation after positioning the collagen-fibrin sealing patch onto the basal tissue layer.

dian 47.5, range 22-145). The mean hospital stay was 8.5 ± 0.15 days (median 9, range 5-15).

Major postoperative complications were noted in 3.2% of the patients and recurrences in 19.3% (21/109, Table I). There were no cases of mediastinitis. Mediastinal emphysema accompanied by a possible rise in leukocytes, without an increase in body temperature, occurred in 1.6% of the procedures (2/127, Table I). There were no cases of postoperative bleeding from the pouch area, but one patient had bleeding due to laceration of the mucosa in the vallecula region, presumably caused either by traumatic intubation or by the diverticuloscope. The mortality rate was 0%. Minor complications were observed in 6.4% of the patients and are listed in Table I.

During the follow-up, clinical examinations have to be carried out when the patients present-

Table I. Major complications (including recurrences) and minor complications after endoscopic laser diverticulotomy in 109 patients.

	n	%
Major complications and recurrences (n = 127)		
Emphysema	2	1.6
Recurrent nerve palsy		
Temporary	1	0.8
Persistent	1	0.8
Bleeding	0	–
Fistula	0	–
Mediastinitis	0	–
Recurrence	22	19.3
Minor complications (n = 127)		
Tooth damage	2	1.6
Lip damage	2	1.6
Drug rash	1	0.8
Dysgeusia (temporary)	1	0.8
Sensory tongue disturbance (temporary)	1	0.8

ed to the outpatient service. Radiologic examinations have to be conducted only in case of symptoms. However, due to the patients' advanced age and/or for other reasons, 89 patients were not able to present personally and seven patients had died before the follow-up investigation could be done. The medium to long-term follow-up was consequently mainly performed via phone interviews with the surviving patients. 79 patients (72.47%) were interviewed only. The mean follow-up period was 71.6 ± 5.16 months (median 72, range 3-173; 95% CI 61.34-81.85). In patients with recurrent

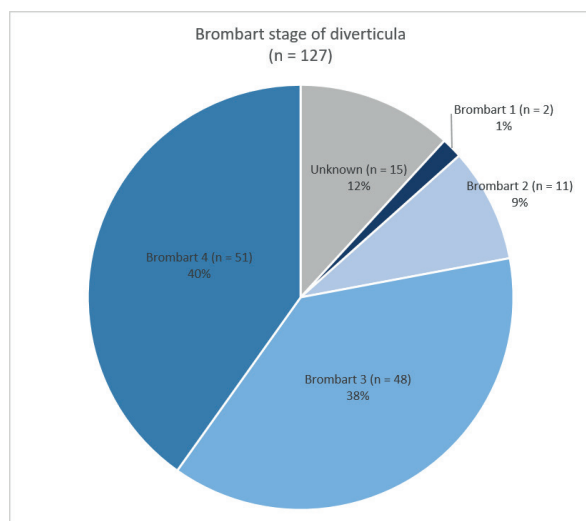


Figure 5. Diverticulum sizes relative to Brombart stages in the 127 diverticula.

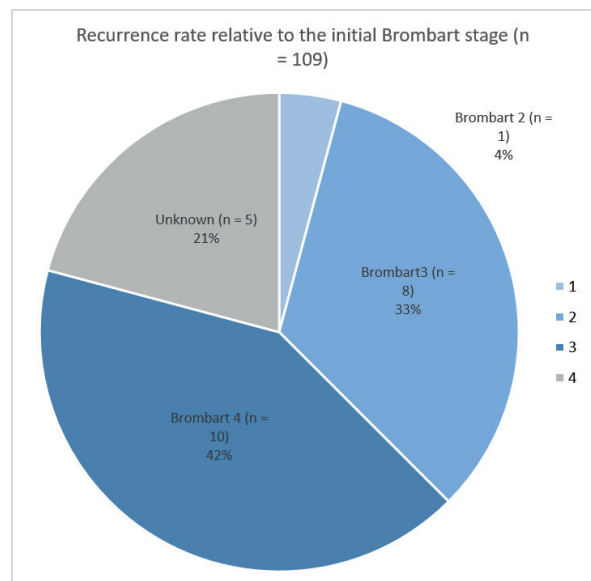


Figure 6. Recurrence rates relative to Brombart stages in the 109 patients.

diverticula, the average time between ELD and recurrent symptoms was 20.6 ± 6.04 months (median 12, range 4-94; 95% CI 7.23-32.87).

Symptomatic clinical recurrences developed in 19.3% of the patients (21/109) and after 18.9% of the surgical procedures (24/127, Table I). A small residual pouch was visible on video fluoroscopy after surgery, but without any accompanying symptoms, in a further 4.7% (six patients). Most of the recurrences (83.3%; 20/24 procedures) occurred in the first 24 months after surgery. The initial Brombart stage was not known for five of the recurrent diverticula (Figure 6). More detailed analysis was carried out in patients with known Brombart stages. This revealed that neither of the two patients with Brombart stage 1 and only one patient with stage 2 (9.1% of all those with Brombart 2) developed recurrences (4% of all recurrences). Most recurrences developed in higher stages: in eight patients with Brombart 3 diverticula (16.6% of all those with Brombart 3; 33% of all recurrences) and in 10 patients with Brombart stage 4 (19.6% of all those with Brombart 4; 42% of all recurrences). There were no significant differences in the recurrence rates between the Brombart groups.

Discussion

The results obtained in this series after 127 ELDs in 109 patients indicate that additional wound sealing can contribute to the safety of the procedure. There were no cases of postoperative bleeding from the pouch area, no fistulas, and no mediastinitis, and the mortality rate was 0%. The major complications after ELD reported in a comprehensive literature review²⁶ – mediastinitis at a rate of 1.2%, emphysema 3%, hematoma/bleeding 0.2%, and morbidity 0.4% – were not noted.

Endoscopic techniques are now favored in the majority of patients presenting with ZD. This is supported by the high level of patient acceptance of the procedures, shorter operating times and low postoperative morbidity^{4,15,16,18-26}.

An issue that is still unresolved is whether and how to protect the basal area that is created after transection of the septum and which separates the mediastinum from the endoluminal space. The various techniques for endoscopic controlled diverticulotomy have to be considered here.

In comparison with ELD, ESD or FED with use of stapler device has the advantage of providing primary wound closure. Immediate closure

of the mucosal barrier can keep the complication rates and morbidity low. Because of its simplicity and low-risk profile, this technique is endorsed by some authors as the first-line therapy, especially for elderly patients^{3-6,9,23}. The stapler is a relatively expensive, single-use device. It does not always allow a complete transection of the mucosa under direct visual control and may leave a residual septum with the need for a second stapler procedure. Higher rates of repeated procedures have been described in some reports. In addition, the stapler brackets remain in the tissue as foreign bodies, with potential problems during revision surgery^{8,26,29}.

Several techniques for primary wound closure after ELD have been described, in one use of fibrin glue¹¹ and in two suture techniques^{12,28} were described. Sommer et al¹¹ investigated the effectiveness of primary wound closure using fibrin glue in one group and closure using sutures and additional fibrin glue in a second group. They reported better results in relation to mediastinitis, increased body temperature, and need for revision surgery in the group with suture closure. Anagiotos et al¹² described similar effects in a comparison between a closed-wound group and an open-wound group after ELD. Following wound closure using sutures and fibrin glue, they observed lower rates of fever (7.4% vs. 11.4%), fistula (3.7% vs. 5.7%), and mediastinitis (0.0% vs. 2.9%). Despite these good results, this modification did not become a routine procedure. The main reason for this, as also mentioned by the authors, appears to be that suturing the residual walls after transecting the septum in this region is a somewhat risky, time-consuming process, leading to disproportionate increases in the duration and cost of the procedure.

In contrast to other wound closure techniques that have been described, positioning a sealing patch at the base after complete transection of the diverticulum is easily feasible, can be performed with microscopic guidance, and takes only 3-5 minutes. After the complete mucosal wall has been cut down, the patch not only serves as a sealant but also enhances the generation of granulation tissue from beneath. In the present authors' experience, it provides excellent wound closure, is fast and easy to perform, and results in minimal rates of complications, morbidity, and mortality. Compared to any clip fixed to a basal incision there is also no risk for dislocation into the mediastinum.

Size or one radiologic parameter used for its estimation, the Brombart stage, may have in-

fluence on which technique can be applied to treat the ZD^{20,42,43} and also on the recurrence rates^{4,10,20,25,26,44}. In very small diverticula (radiologic stage Brombart 1) more often show inadequate protection and therefore not amenable to endoscopic controlled therapy due to a greater risk of morbidity and higher recurrence rates. Therefore, such diverticula are treated predominantly by a transcervical approach with good success^{1,20,26}. In particular a complete myotomy necessary to achieve long-term success cannot be performed in these stages at least in one surgical step. Earlier opening of the mediastinal space must be expected. If an endoscopic procedure is performed, use of a sealing patch in this situation in particular may enable the surgeon to continue with the procedure to the maximum extent and to cover the adventitia adequately. Bigger sized diverticula (radiologic Brombart 2-4), which show a better protection with a longer septum, suggest a clear indication for endoscopic controlled therapy. In any stage, sealing of the basal tissue layer next to the fundus of the diverticulum appears to help reduce the morbidity, with little effort (Figures 3-4). In general, even if the adventitia has been damaged and the mediastinum has been opened accidentally in a small area, a sealing technique may prevent the need for conversion to open surgery. This can be advantageous for ELD, ESD and also FED techniques. For all of these higher rates of adverse reaction, in particular perforation (3 to over 5%) were reported^{15,16,45}.

ELD provides excellent exposure and allows complete cutting down of the septum under microscopic control as far as the bottom, until the adventitia can be seen - resulting in maximum transection of the musculature - at least to the level of the adventitia. Due to the flimsy layer of adventitial tissue left above the mediastinum, which becomes broader the deeper the transection extends to the fundus, these techniques involve a distinct risk of perforation and mediastinitis. After ELD in the present study, a sealant patch proved to be useful for eliminating exactly this risk without compromising the surgical success rates. Even if the mediastinum is opened, a sealing procedure can bridge the uncovered area and open surgery can be avoided. This is underscored by the low complication rates in our study, particularly 0% rates of fistula and mediastinitis.

Additional sealing was performed in all diverticula of all stages with no significant influence on the recurrence rates. Most of the diverticula (78.0%) were classified as Brombart stage 3 or 4,

and also most of the recurrences were observed in these cases (Table I, Figures 5, 6). In direct comparison, Brombart stage 3 diverticula (48/127; 37.8%) were associated with a lower recurrence rate of 16.6% than stage 4 diverticula (51/127; 40.2%), with a recurrence rate of 19.6%. The difference was not significant. The clinical and radiological verified recurrence rate in the present group was 19.3% – comparable with the rates reported in the literature^{15,16,26,45}.

Conclusions

This study suggests that routine use of a fibrin sealant patch in endoscopic laser diverticulotomy allows maximum removal of the diverticular septum without increasing the risk of morbidity and mortality. It can increase the safety and effectiveness of endoscopic treatment for Zenker's diverticulum. The sealing material did not have a negative impact on the recurrence rates, which were equivalent to or even lower than those reported in the literature. Sealing of the basal wound layer compensates the disadvantages of ELD compared to ESD and has the potential to contribute to the safety and effectivity of this surgical procedure.

Conflict of Interest

The Authors declare that they have no conflict of interests.

Informed consent

Informed consent was obtained from all individual participants included in the study.

ORCID ID

Michael Koch: <https://orcid.org/0000-0001-7838-6490>.

References

- 1) Mantsopoulos K, Psychogios G, Kunzel J, Zenk J, Iro H, Koch M. Evaluation of the different transcervical approaches for Zenker diverticulum. *Otolaryngol Head Neck Surg* 2012; 146: 725-729.
- 2) Hussain T, Maurer JT, Lang S, Stuck BA. [Pathophysiology, diagnosis and treatment of Zenker's diverticulum]. *HNO* 2017; 65: 167-176.
- 3) Narne S, Cutrone C, Bonavina L, Chella B, Peracchia A. Endoscopic diverticulotomy for the treatment of Zenker's diverticulum: results in 102 patients with staple-assisted endoscopy. *Ann Otol Rhinol Laryngol* 1999; 108: 810-815.

- 4) Wirth D, Kern B, Guenin MO, Montali I, Peterli R, Ackermann C, von Flue M. Outcome and quality of life after open surgery versus endoscopic stapler-assisted esophagodiverticulostomy for Zenker's diverticulum. *Dis Esophagus* 2006; 19: 294-298.
- 5) Verhaegen VJ, Feuth T, van den Hoogen FJ, Mares HA, Takes RP. Endoscopic carbon dioxide laser diverticulostomy versus endoscopic staple-assisted diverticulostomy to treat Zenker's diverticulum. *Head Neck* 2011; 33: 154-159.
- 6) Wilken R, Whited C, Scher RL. Endoscopic staple diverticulostomy for Zenker's diverticulum: review of experience in 337 cases. *Ann Otol Rhinol Laryngol* 2015; 124: 21-29.
- 7) Barton MD, Detwiller KY, Palmer AD, Schindler JS. The safety and efficacy of endoscopic Zenker's diverticulotomy: a cohort study. *Laryngoscope* 2016; 126: 2705-2710.
- 8) Shah RN, Slaughter KA, Fedore LW, Huang BY, Deal AM, Buckmire RA. Does residual wall size or technique matter in the treatment of Zenker's diverticulum? *Laryngoscope* 2016; 126: 2475-2479.
- 9) Mazza M, Bergamini AN, Parise P, Cossu A, Adamenko O, Elmore U, Rosati R. Treatment of Zenker's diverticulum with Endoscopic Stapled Esophago-diverticulostomy (ESD): analysis of long-term outcome. *Surg Laparosc Endosc Percutan Tech* 2017; 27: 445-448.
- 10) Zbaren P, Schar P, Tschopp L, Becker M, Hausler R. Surgical treatment of Zenker's diverticulum: transcuteaneous diverticulectomy versus microendoscopic myotomy of the cricopharyngeal muscle with CO2 laser. *Otolaryngol Head Neck Surg* 1999; 121: 482-487.
- 11) Sommer KD, Ahrens KH, Reichenbach M, Weerda H. [Comparison of 2 endoscopic surgery techniques for reliable therapy of Zenker diverticulum]. *Laryngorhinootologie* 2001; 80: 470-477.
- 12) Anagiotos A, Feyka M, Gostian AO, Lichtenstein T, Henning TD, Guntinas-Lichius O, Hüttenbrink KB, Preuss SF. Endoscopic laser-assisted diverticulotomy without versus with wound closure in the treatment of Zenker's diverticulum. *Eur Arch Otorhinolaryngol* 2014; 271: 765-770.
- 13) Anagiotos A, Feyka M, Eslick GD, Lichtenstein T, Henning TD, Guntinas-Lichius O, Hüttenbrink KB, Preuss SF. Long-term symptom control after endoscopic laser-assisted diverticulotomy of Zenker's diverticulum. *Auris Nasus Larynx* 2014; 41: 568-571.
- 14) Hoffmann M, Fazel A, Mews KG, Ambrosch P. 32 years of experience with CO2 -LASER-assisted treatment for Zenker's Diverticulum - an update of 227 patients treated in Kiel. *Clin Otolaryngol* 2017; 42: 592-596.
- 15) Ishaq S, Hassan C, Antonello A, Tanner K, Bellisario C, Battaglia G, Anderloni A, Correale L, Sharma P, Baron TH, Repici A. Flexible endoscopic treatment for Zenker's diverticulum: a systematic review and meta-analysis. *Gastrointest Endosc* 2016; 83: 1076-1089.e5.
- 16) Jain D, Sharma A, Shah M, Patel U, Thosani N, Singhal S. Efficacy and safety of flexible endoscopic management of Zenker's diverticulum. *J Clin Gastroenterol* 2018; 52: 369-385.
- 17) Ishaq S, Sultan H, Siau K, Kuwai T, Mulder CJ, Neumann H. New and emerging techniques for endoscopic treatment of Zenker's diverticulum: state-of-the-art review. *Dig Endosc* 2018; 30: 449-460.
- 18) Bonavina L, Bona D, Abraham M, Saino G, Abate E. Long-term results of endosurgical and open surgical approach for Zenker diverticulum. *World J Gastroenterol* 2007; 13: 2586-2589.
- 19) Chang CW, Burkey BB, Netterville JL, Courey MS, Garrett CG, Bayles SW. Carbon dioxide laser endoscopic diverticulotomy versus open diverticulectomy for Zenker's diverticulum. *Laryngoscope* 2004; 114: 519-527.
- 20) Koch M, Mantsopoulos K, Velegarakis S, Iro H, Zenk J. Endoscopic laser-assisted diverticulotomy versus open surgical approach in the treatment of Zenker's diverticulum. *Laryngoscope* 2011; 121: 2090-2094.
- 21) Nitschke P, Kemper M, König P, Zahnert T, Weitz J, Reissfelder C, Distler M. Interdisciplinary comparison of endoscopic laser-assisted diverticulotomy vs. transcervical myotomy as a treatment for Zenker's diverticulum. *J Gastrointest Surg* 2020; 24: 1955-1961.
- 22) Leibowitz JM, Fundakowski CE, Abouyared M, Rivera A, Rudman J, Lo KM, Weed D, Civantos F. Surgical techniques for zenker's diverticulum: a comparative analysis. *Otolaryngol Head Neck Surg* 2014; 151: 52-58.
- 23) Visser LJ, Hardillo JA, Monserez DA, Wieringa MH, Baatenburg de Jong RJ. Zenker's diverticulum: Rotterdam experience. *Eur Arch Otorhinolaryngol* 2016; 273: 2755-2763.
- 24) Howell RJ, Giliberto JP, Harmon J, Masch J, Khosla S, Postma GN, Meinzen-Derr J. Open versus endoscopic surgery of Zenker's diverticula: a systematic review and meta-analysis. *Dysphagia* 2019; 34: 930-938.
- 25) Albers DV, Kondo A, Bernardo WM, Sakai P, Moura RN, Silva GL, Ide E, Tomishige T, de Moura EG. Endoscopic versus surgical approach in the treatment of Zenker's diverticulum: systematic review and meta-analysis. *Endosc Int Open* 2016; 4: E678-E686.
- 26) Verdonck J, Morton RP. Systematic review on treatment of Zenker's diverticulum. *Eur Arch Otorhinolaryngol* 2015; 272: 3095-3107.
- 27) Gutschow CA, Hamoir M, Rombaux P, Otte JB, Goncette L, Collard JM. Management of pharyngoesophageal (Zenker's) diverticulum: which technique? *Ann Thorac Surg* 2002; 74: 1677-1682.
- 28) Minovi CM, Minovi A, Dost P. Suture of the mucosa after the endoscopic LASER mucomyotomy of Zenker's diverticulum. *Eur Arch Otorhinolaryngol* 2015; 272: 2947-2952.
- 29) Wilmsen J, Baumbach R, Stüker D, Weingart V, Nesper F, Gölder SK, Pfundstein C, Nötzel EC, Rösch T, Faiss S. New flexible endoscopic controlled stapler technique for the treatment of Zenker's diverticulum: a case series. *World J Gastroenterol* 2017; 23: 3084-3091.
- 30) Li QL, Chen WF, Zhang XC, Cai MY, Zhang YQ, Hu JW, He MJ, Yao LQ, Zhou PH, Xu MD. Submucosal tunneling endoscopic septum division: a novel technique for treating Zenker's diverticulum. *Gastroenterology* 2016; 151: 1071-1074.

- 31) Hernandez Mondragon OV, Solorzano Pineda MO, Blancas Valencia JM. Zenker's diverticulum: Submucosal tunneling endoscopic septum division (Z-POEM). *Dig Endosc* 2018; 30: 124.
- 32) Li LY, Yang YT, Qu CM, Liang SW, Zhong CQ, Wang XY, Chen Y, Spandorfer RM, Christofaro S, Cai Q. Endoscopic needle-knife treatment for symptomatic esophageal Zenker's diverticulum: A meta-analysis and systematic review. *J Dig Dis* 2018; 19: 204-214.
- 33) Delis K, Robotis J, Sachitzi E, Mastronikola E. Submucosal tunneling endoscopic septum division of a Zenker's diverticulum. *Ann Gastroenterol* 2018; 31: 634.
- 34) Brewer Gutierrez OI, Moran R, Yang J, Sanaei O, Kalloo AN, Kumbhari V, Khashab MA. Successful single-session cricopharyngeal and Zenker's diverticulum peroral endoscopic myotomy. *Endoscopy* 2018; 50: E220-E221.
- 35) Brewer Gutierrez OI, Ichkhanian Y, Spadaccini M, Vosoughi K, Repici A, Khashab MA. Zenker's diverticulum per-oral endoscopic myotomy techniques: changing paradigms. *Gastroenterology* 2019; 156: 2134-2135.
- 36) Krutsri C, Phalanusitthepha C, Hiranyathep P, Sumritpradit P, Leelakusolvong S, Methasate A, Singhatas P, Janbavonkij T. Successful advanced third-space endoscopic surgery by per-oral endoscopic myotomy (Z-POEM) for Zenker's diverticulum: a case report and review of literature. *Int J Surg Case Rep* 2020; 74: 186-191.
- 37) Repici A, Spadaccini M, Belletrutti PJ, Galtieri PA, Fugazza A, Anderloni A, Carrara S, Di Leo M, Pellegatta G, Cappello A, Castoro C, Ichkhanian Y, Khashab MA, Maselli R. Peroral endoscopic septotomy for short-septum Zenker's diverticulum. *Endoscopy* 2020; 52: 563-568.
- 38) Shen B, Jiang H, Li Z, Wang Z, Song H, Ding X. Zenker's diverticulum treated with submucosal tunneling endoscopic septum division surgery: two case reports. *Medicine (Baltimore)* 2020; 99: e18659.
- 39) Yang J, Novak S, Ujiki M, Hernández Ó, Desai P, Benias P, Lee D, Chang K, Briau B, Barret M, Kumta N, Zeng X, Hu B, Delis K, Khashab MA. An international study on the use of peroral endoscopic myotomy in the management of Zenker's diverticulum. *Gastrointest Endosc* 2020; 91: 163-168.
- 40) Mittal C, Diehl DL, Draganov PV, Jamil LH, Khalid A, Khara HS, Khullar V, Law R, Lo SK, Mathew A, Mirakhor E, Sedarat A, Sharma N, Sharzei S, Tavakkoli A, Thaker A, Thosani N, Yang D, Zelt C, Wagh MS. Practice patterns, techniques, and outcomes of flexible endoscopic myotomy for Zenker's diverticulum: a retrospective multicenter study. *Endoscopy* 2020; 53: 346-353.
- 41) Klingler MJ, Landreneau JP, Strong AT, Barajas-Gamboa JS, Tat C, Tu C, Fathalizadeh A, Kroh M, Rodriguez J, Sanaka MR, Ponsky J. Endoscopic mucosal incision and muscle interruption (MIMI) for the treatment of Zenker's diverticulum. *Surg Endosc* 2020; 35: 3896-3904.
- 42) Brombart M. [Zenker's pharyngo-esophageal diverticulum; pathogenic considerations on radiological studies on 26 cases (23 cases in initial stage)]. *J Belge Radiol* 1953; 36: 166-197.
- 43) Mantsopoulos K, Psychogios G, Karatzanis A, Künzel J, Lell M, Zenk J, Koch M. Clinical relevance and prognostic value of radiographic findings in Zenker's diverticulum. *Eur Arch Otorhinolaryngol* 2014; 271: 583-588.
- 44) Tabola R, Lewandowski A, Cirocchi R, Augoff K, Kozminska U, Strzelec B, Grabowski K. Zenker diverticulum: Experience in surgical treatment of large diverticula. *Medicine (Baltimore)* 2018; 97: e0557.
- 45) Crawley B, Dehom S, Tamares S, Marghalani A, Ongkasuwan J, Reder L, Ivey C, Amin M, Fritz M, Pitman M, Tulunay-Ugur O, Weissbrod P. Adverse events after rigid and flexible endoscopic repair of Zenker's diverticula: a systematic review and meta-analysis. *Otolaryngol Head Neck Surg* 2019; 161: 388-400.