

# Expression level and clinical significance of IL-2, IL-6 and TGF- $\beta$ in elderly patients with goiter and hyperthyroidism

L.-F. LV<sup>1</sup>, H.-Y. JIA<sup>1</sup>, H.-F. ZHANG<sup>1</sup>, Y.-X. HU<sup>2</sup>

<sup>1</sup>Department of Endocrinology, People's Hospital of Zhengzhou University, Henan Provincial People's Hospital, Zhengzhou, Henan, China

<sup>2</sup>Department of Gastrointestinal Surgery, Zhengzhou Central Hospital Affiliated to Zhengzhou University, Zhengzhou Central Hospital, Zhengzhou, Henan, China

**Abstract.** – **OBJECTIVE:** To investigate the level of expression and the clinical significance of IL-2 (interleukin-2), IL-6 (interleukin-6) and TGF- $\beta$  (transforming growth factor- $\beta$ ) in elderly patients with goiter and hyperthyroidism.

**PATIENTS AND METHODS:** Gender, age, course of disease, BMI (Body Mass Index), serum FT3 (Free triiodothyronine-3), FT4 (Free triiodothyronine-4), TT3 (Total triiodothyronine-3), TT4 (Total triiodothyronine-4), TSH (Thyroid Stimulating Hormone) and clinical manifestations on admission and other general clinical data and laboratory examination results were collected and statistically analyzed as case group in 128 elderly patients with goiter and hyperthyroidism. Additional 128 over 60-year-old patients with hyperthyroidism were selected as control group. The thyroid tissue of these patients and the control group were examined by fine needle aspiration biopsy. The expressions of IL-2, IL-6, TGF- $\beta$  of the thyroid tissue in all patients were detected by immunohistochemistry, qRT-PCR (Real-time Quantitative Polymerase Chain Reaction) and Western blot method respectively, and the statistical analysis was carried out.  $p < 0.05$  indicated that the difference had statistical significance.

**RESULTS:** Compared with the control group, the expressions of IL-2, IL-6 and TGF- $\beta$  in the group of patients were significantly higher ( $p < 0.05$ ). The significantly higher expression of IL-2, IL-6, and TGF- $\beta$  was mainly concentrated in the thyroid follicular cells of patients with hyperthyroidism and thyroid enlargement ( $p < 0.05$ ). In the patients with goiter, hyperthyroidism, and symptoms of exophthalmos, the level of expression of IL-6 was significantly higher than that of patients without exophthalmos ( $p < 0.05$ ). In the patients with goiter, hyperthyroidism and symptoms of exophthalmos, and the patients with goiter, hyperthyroidism without symptoms of exophthalmos, IL-2 and TGF- $\beta$  expression level were not different ( $p > 0.05$ ).

**CONCLUSIONS:** The expression levels of IL-2, IL-6, and TGF- $\beta$  were significantly increased in the patients with senile goiter and hyperthyroidism, but in the senile patients with goiter, hyperthyroidism and exophthalmos symptoms, IL-6 levels were significantly higher than those without exophthalmos. The use of IL-2, IL-6, and TGF- $\beta$  is of great significance in the diagnosis of goiter with hyperthyroidism, especially for elderly patients with atypical clinical symptoms of hyperthyroidism.

*Key Words:*

IL-2, IL-6, TGF- $\beta$ , Thyroid enlargement, Hyperthyroidism.

## Introduction

Clinically, enlargements of the thyroid gland are usually classified into two types; one is simple goiter while the other is reduced goiter with hyperthyroidism or thyroid dysfunction. Among them, patients with goiter and hyperthyroidism are common<sup>1,2</sup>. The thyroid function of the patients with simple goiter is normal<sup>3</sup>. Compensatory goiter is mainly due to expression deficiency of goiter material or related metabolic enzyme gene caused by the defects of iodine<sup>4-6</sup>, without evident symptoms of hyperthyroidism or thyroid dysfunction. In patients with goiter and hyperthyroidism, also to the general performance of simple goiter, there is thyroid associated with synthesis and release of thyroid hormones in peripheral circulation, so in order to promote the body's metabolism of hyperthyroidism accompanied by sympathetic nerve excitement symptoms,

patients had clinical manifestations of heart palpitations, sweating, increased eating, increased stool frequency but the body weight decreased<sup>7</sup>. Most of the patients were often accompanied with proptosis, eyelid edema, and decreased visual acuity, but there are studies reported that in the elderly patients with goiter and hyperthyroidism, there is usually no clinical manifestation, and even in the laboratory examination of the thyroid function, there is no significant difference. This makes it difficult to diagnose simple goiter and goiter with hyperthyroidism, and it is not conducive to the treatment of the patients<sup>8-10</sup>. Dong et al<sup>11</sup> believe that Graves' disease is usually an autoimmune idiopathic disease. At the time of onset, the patient is often accompanied by varying degrees of inflammatory cytokines, including IL-2, IL-6, and TGF- $\beta$  and increased inflammatory mediators, thereby stimulating to produce a large number of lymphocytes and lymphocytes release. In the role of these inflammatory cytokines and mediators, a lot of thyroid harmful immune globulin-TSI (Thyroid Stimulating Immunoglobulin) is produced. This substance can destroy the structure of thyroid follicles and make a lot of thyroid hormone stored in thyroid follicular released into the peripheral tissues, making the patient appearing in a toxic reaction<sup>12</sup>. Based on these data, we designed and implemented the current study, to provide a theoretical basis for the differential diagnosis of elderly patients with atypical thyroid enlargement and hyperthyroidism.

## Patients and Methods

### Patients

The current work is a prospective study conducted from August 2014 to December 2015. We collected over 60-year-old patients with thyroid enlargement and neck pain. The age, time of onset, clinical manifestation, laboratory examination, imaging examination and other general clinical data were collected and sorted out. According to the clinical manifestations and imaging examination, combined with the pathological examination, 128 patients with goiter and hyperthyroidism were diagnosed and 128 patients with goiter without hyperthyroidism were randomly selected as control group. This study was approved by the Ethics Committee of The People's Hospital of Zhengzhou University. Signed written informed consents were obtained from all participants before the study.

### Inclusion Criteria of Case Group<sup>6</sup>

1. Patients were diagnosed as thyroid enlargement and hyperthyroidism by imaging, pathology, physical examination, and laboratory examination;
2. Age of patients > 60.

### Exclusion Criteria of Case Group<sup>7</sup>

1. Malignant tumors of the thyroid gland or other systems;
2. Patients cannot be clearly diagnosed by imaging, pathology, physical examination and laboratory examination;
3. Cognitive impairment or mental illness;
4. Some of the reasons for failure to obtain a patient's sample;
5. Patients or family members cannot cooperate with the inspectors;
6. Some of the reasons lead to the withdrawal of the researchers;
7. Patients give up treatment.

### Reagents

Taq Master Mix (SinoBio, Indiana, PA, USA), agarose (Biowest, Nuaille, France), sterile double distilled water, anti-phosphorylation TGF- $\beta$ 1 (p-TGF- $\beta$ 1) (1:1.000; Cell Signaling Technology, Danvers, MA, USA),  $\beta$ -actin antibody (1:5.000; Invitrogen, Carlsbad, CA, USA), phosphorylation TGF- $\beta$ 1 (p-TGF- $\beta$ 1 antibody 1:1.000; Cell Signaling Technology, Danvers, MA, USA). 0.9% stroke-physiological saline solution (Otsuka Pharmaceutical, Tokushima, Japan), Trizol (Invitrogen, Carlsbad, CA, USA).

### Instruments

PCR amplification instrument Bio-Rad (Hercules, CA, USA), gel imaging instrument Bio-Rad (Hercules, CA, USA), electrophoresis apparatus (Beijing 61 Instrument Factory, Beijing, China), centrifuge (Eppendorf, Hamburg, Germany), micropipette (Eppendorf, Hamburg, Germany), Haier ice machine, Western blot electrophoresis apparatus trophoresis (Heidelberg, Germany), -80°C refrigerator (Thermo, Waltham, MA, USA), 10 ml syringe, 5 ml syringe (Hanaco, Tianjin, China), experimental animal surgical instruments (Beijing Medical Equipment Factory, Beijing, China), NanoDrop2000 photometric analyzer (Thermo, Waltham, MA, USA), EP tube (Eppendorf, Hamburg, Germany), Water bath (Beijing Medical Equipment Factory, Beijing, China), pathological section machine (Leica, Wetzlar, Germany).

### **Research Method**

Fine needle aspiration biopsy of the thyroid gland<sup>8</sup>: this experiment has been agreed by the Experimental Animal Ethics of the University.

1. Determine the puncture position, near the puncture position use the iodophor and medical alcohol for disinfection;
2. Use 10% lidocaine hydrochloride on puncture site for local infiltration anesthesia, after the onset of anesthesia, carry out puncture sampling, pay attention to the anesthetic process, and do not hurt the throat back nerve;
3. Puncture needle can be used for pathological puncture, after a puncture, carefully pull out the puncture needle. What was got was the lesion site of thyroid tissue.

Thyroid hormone test<sup>9</sup>: thyroid hormone levels were detected in patients with thyroid hormone withdrawal for 1 day, and in the next morning 4-6 ml peripheral blood sample of patients was extracted. FT4, TT3, TT4, TSH, FT3 were detected by Abbott Automatic Biochemical Analyzer (Abbott Park, IL, USA).

### **Diagnostic Criteria**

1. The normal reference value of total three iodine thyroid gland (TT3): 0.45-1.37 ng/ml;
2. Normal reference value of total thyroid hormone (TT4): 4.5-12 ug/dl;
3. Free triiodothyronine (FT3) 1.45-3.48 pg/ml;
4. Free thyroid hormone (FT4) 0.71-1.85 ng /dl;
5. Normal reference value of thyroid stimulating hormone (TSH): 0.49-4.67 mIU/L.

Diagnosis of thyroid ophthalmopathy<sup>10</sup>: there is a bilateral or unilateral eye, eyelid congestion and edema, and swelling of the orbital tissue. The upper eyelid or lower eyelid retraction and upper eyelid falling slowly were called "lag signs", with increase or decrease of blink. With the aid of ultrasound and MRI, CT and other imaging method, the diagnosis of hyperthyroid exophthalmos was taken.

The qRT-PCR method was used to detect IL-2, IL-6 and TGF- $\beta$  in the thyroid tissue transcription level in the case group and the control group<sup>12,13</sup>. One part of the tissue samples that was got in the first step was used to extract the RNA in the tissue by Trizol (Invitrogen, Carlsbad, CA, USA) method. After the extraction, NanoDrop2000 photometric analyzer (Thermo, Waltham, MA, USA) was used to measure the concentration, 260/280.

Western blot method was used to detect the level of IL-2, IL-6 and TGF- $\beta$  in the thyroid tissue of the two groups of patients<sup>14</sup>: part of pathological thyroid tissue of patients was taken, after grinding in liquid nitrogen. Preliminary purification was taken by acetone tissue. The tissue was placed in the ice lysis solution to prevent the degradation of the tissue protein. The concentration of the sample protein (50  $\mu$ g) was determined by Bio-Rad Kit (Hercules, CA, USA). 10% sodium dodecyl sulphate-polyacrylamide gel electrophoresis (SDS-PAGE) was isolated and added into the polyvinylidene fluoride, polyvinylidene difluoride (PVDF) film. The incubation with the first antibody was undertaken at 4°C refrigerator. Immune reactivity test: on the first day after the overnight incubation, visualization enhanced chemiluminescence (VEC) method and the second antibody were used to detect. The first antibody was anti-IL-2, anti-IL-6, and anti-TGF- $\beta$  (1:500; Biolegend, San Diego, CA, USA), and anti- $\beta$ -actin (1:5000; Invitrogen, Carlsbad, CA, USA). Strip signal quantification analysis was taken by ImagePro+6.0 imaging software (Media Cybernetics, Silver Springs, MD, USA).

### **Immunohistochemistry**

Before immunohistochemical staining, the paraffin section of rat brain was first produced. This production mainly included fixation, dehydration, transparency, tissue embedding, slice, patch, baking sheet and so on. Then, the paraffin section was made, and the immunohistochemical staining was carried out according to a previous report<sup>5</sup>. In detail, after heat-induced epitope retrieval with 10 mM citrate buffer (pH 6.0) by microwave oven for 15 min, the sections were pretreated with 3% H<sub>2</sub>O<sub>2</sub> in phosphate buffered saline (PBS) for 15 min and blocking with 5% goat serum at room temperature. Sections were incubated with rabbit anti-TGF- $\beta$  antibody (dilution: 1:200; Abcam, Cambridge, MA, USA; Catlog#: ab66043) overnight at 4°C. After the primary antibody reaction, an immunohistochemical staining kit (Dako, Santa Clara, CA, USA) was used. The sections were washed and stained with 3,3'-diaminobenzidine (DAB) and then counterstained with hematoxylin.

### **Statistical Analysis**

Statistical analysis was performed by SPSS19.0 (Version X; IBM, Armonk, NY, USA). Variance analysis (ANOVA) test and  $X^2$ -test were used to analyze the normal distribution data. Fisher exact

**Table I.** General clinical diagnostic indexes of two groups (U/L).

	Age (years old)	Course of disease (year)	BMI (kg/m <sup>2</sup> )	TT3 (ng/ml)	TT4 (ug/dl)	FT3 (ng/dl)	FT4 (ng/dl)	TSH (mIU/L)
Case group	65.3 $\pm$ 5.5	1.33 $\pm$ 0.44	18.8 $\pm$ 1.2	2.41 $\pm$ 0.75	25.2 $\pm$ 7.86	16.7 $\pm$ 6.88	6.68 $\pm$ 5.37	6.81 $\pm$ 4.37
Control group	62.8 $\pm$ 4.7	1.27 $\pm$ 0.89	19.27 $\pm$ 0.87	1.68 $\pm$ 2.54	10.2 $\pm$ 3.92	8.83 $\pm$ 2.68	1.58 $\pm$ 2.24	3.28 $\pm$ 2.34
<i>t</i> -value	0.98	1.22	0.87	6.59	9.83	2.39	4.38	7.38
<i>p</i> -value	> 0.05	> 0.05	> 0.05	< 0.05	< 0.05	< 0.05	< 0.05	< 0.05

probability method was used for the data of the four cases that did not satisfy the condition. The comparison of skewed distribution data was tested by paired *t* or  $\chi^2$ . *p* < 0.05 indicated that the difference had statistical significance.

## Results

### Comparison of General Clinical Data of Both Groups of Patients

The general clinical indexes and clinical manifestations of the patients were collected and statistically analyzed. Compared with the control group, TT3, TT3, FT3, FT4, TSH in the case group of patients were significantly higher (*p* < 0.05) (Table I).

### Levels of Transcription of IL-2, IL-6, and TGF- $\beta$ in Thyroid Tissue of Both Groups of Patients

We used qRT-PCR to detect and count the levels of IL-2, IL-6, and TGF- $\beta$  in thyroid pathology in both groups of patients, and the results were shown in Figure 1A-B. We found that, compared with the control group, IL-2, IL-6, and TGF- $\beta$  in the case group of patients were significantly higher (*p* < 0.05).

### Expression Level of IL-2, IL-6, and TGF- $\beta$ in Thyroid Tissues of Two Groups of Patients

The levels of expression of IL-2, IL-6, and TGF- $\beta$  were detected and statistically analyzed in thyroid pathology of both groups of patients by Western blot method, and the results were shown in Figure 2. We found that, compared with the control group, the levels of expression of IL-2, IL-6, and TGF- $\beta$  were significantly higher in the case group (*p* < 0.05).

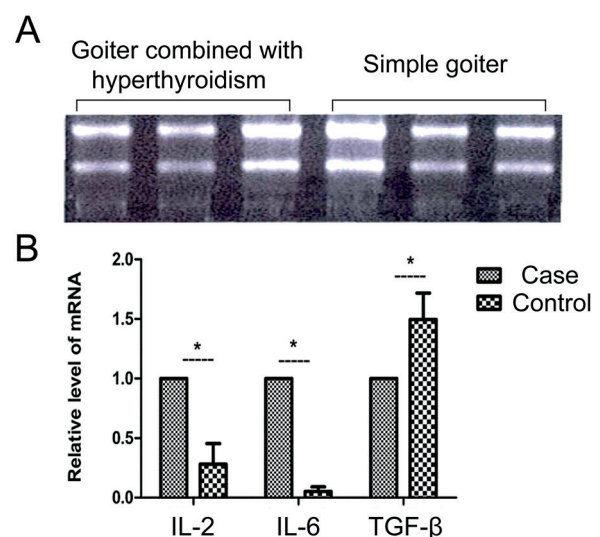
### Immunohistochemical Detection Results

We performed immunohistochemical staining on the pathological tissues in the group of pa-

tients and found that the high expression of IL-2, IL-6, and TGF- $\beta$  was mainly concentrated in the thyroid follicular cells of patients with hyperthyroidism and thyroid enlargement as shown in Figure 3 A-B.

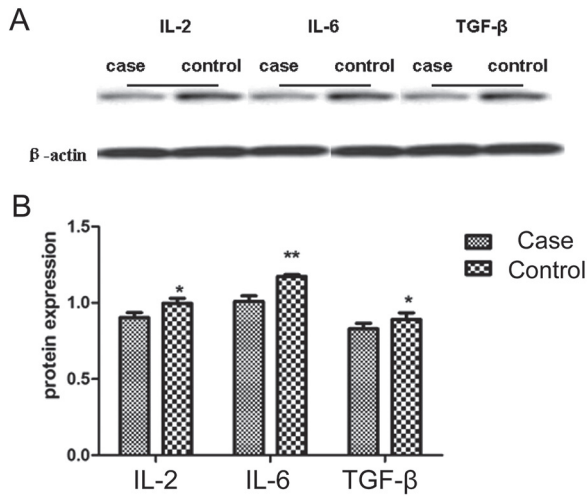
### Effect of Exophthalmos on the Expression level of IL-2, IL-6, and TGF- $\beta$ in Patients with Hyperthyroidism

Patients in the case group according to diagnostic criteria of hyperthyroid exophthalmos were divided into exophthalmos group and non-exophthalmos group, among which 55 patients in exophthalmos group, and 73 patients in non-exophthalmos patients. The level of IL-6 in patients of exophthalmos group was significantly higher than the control group (*p* < 0.05) (Figure 4). The levels of expression of IL-2 and TGF- $\beta$  had no difference (*p* > 0.05). Serum levels



**Figure 1.** **A**, The results of total RNA 1.5% agarose gel electrophoresis 1, 2, 3: thyroid enlargement associated with hyperthyroidism; 4, 5, 6: thyroid tissue in patients with simple goiter. **B**, Statistics of IL-2, IL-6, TGF- $\beta$  mRNA levels in thyroid tissue of two groups of patients. \*Showed that the difference was statistically significant, *p* < 0.05.





**Figure 2.** Expression levels of IL-2, IL-6, and TGF- $\beta$  in thyroid tissue of two groups of patients were detected, it was found that compared with the control group, the IL-2, IL-6 and TGF- $\beta$  expression levels were significantly higher in the case group, and the differences were statistically significant ( $p < 0.05$ ). **A**, Western blot scanning film result display. **B**, Western blot statistical histogram. \* $p < 0.05$ ; \*\* $p < 0.01$ .

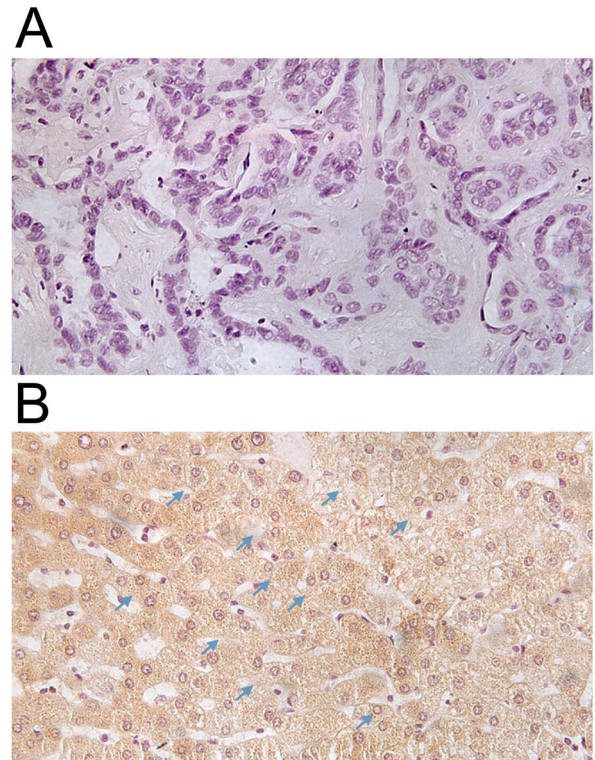
of TT3, TT3, FT3, FT4, TSH in patients with non-exophthalmos and simple goiter patients, compared with those of patients with exophthalmos were found significantly lower. However, the levels of these markers in patients with exophthalmos or not, were significantly higher than those of simple goiter patients (Table II).

## Discussion

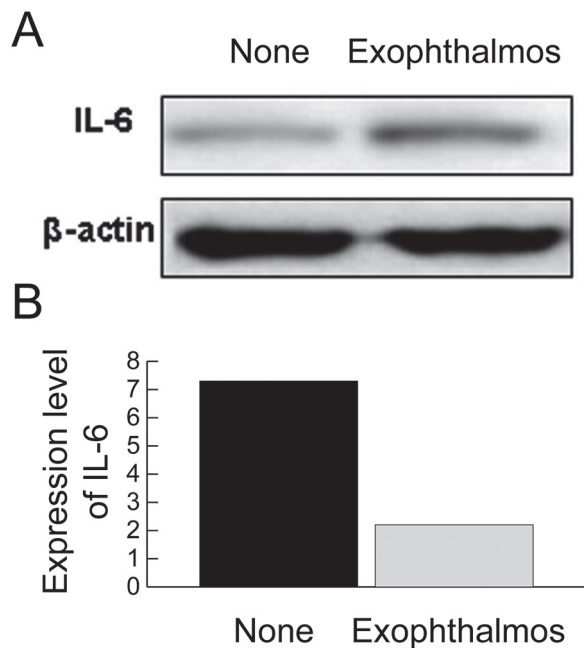
The etiology of goiter with hyperthyroidism is complex, mainly including diffuse toxic goiter (Graves' disease), subacute thyroiditis, painless thyroiditis, postpartum thyroiditis, Hashimoto's thyroiditis, hyperthyroidism induced by levothyroxine sodium and iodine, and hyperthyroidism induced by blood hCG and the thyroid of pituitary TSH tumor and so on. The study showed that the most common clinical hyperthyroidism was caused by Graves disease<sup>1,2</sup>. Graves disease is an autoimmune disease of the thyroid, and often the cause is that the effect of some factors promotes lymphocytes of patients to produce a lot of immunoglobulin-TSI (Thyroid Stimulating Immunoglobulin) that stimulates the thyroid. On the clinical usually thyroid stimulating hormone receptor antibody TRAb (Thyrotrophin Receptor Antibody) can be determined<sup>3-5</sup>.

According to Eisenstein et al<sup>14</sup>, T2 can enhance blood glucose, urine protein, extracellular matrix expansion and TGF- $\beta$ 1 expression by inhibiting the expression and activation of SIRT1 (Sirtuin) protein<sup>15</sup>. TGF- $\beta$ 1 can prompt type IV collagen expression, leads to an increase in collagen deposition that is also an important regulating factor causing exophthalmos of hyperthyroidism patients. In normal conditions, T3 can form T2 by deiodination, the biological function of T2 and T3 is similar, but they cannot cause hyperthyroidism in the body. In patients with hyperthyroidism, the content of T2 was significantly higher than that of patients without hyperthyroidism<sup>16</sup>. Therefore, Ngo et al<sup>17</sup> also believe to the important relationship between T2 content in serum of patients with hyperthyroidism and exophthalmos.

In our work, the expression level of IL-2 in patients with hyperthyroidism and thyroid enlargement was significantly higher than that in patients with simple goiter ( $p < 0.05$ ). IL-2 is an inflammatory cytokine secreted by Th cells,



**Figure 3.** HE staining and immunohistochemical staining in patients with hyperthyroidism and thyroid enlargement. **A**, HE staining in patients with hyperthyroidism and thyroid enlargement (X10). **B**, Immunohistochemical staining in patients with hyperthyroidism and thyroid enlargement (X10). Blue arrow indicated that the expression of TGF- $\beta$  was mainly in the nucleus of the thyroid gland.



**Figure 4.** **A**, Western blot was used to detect thyroid tissue IL-6 expression levels in patients with exophthalmos and without exophthalmos. **A**, The expression of patients without exophthalmos was significantly higher than that of patients with exophthalmos. **B**, The difference was statistically significant ( $p < 0.05$ ). \* $p < 0.05$ .

and it is known that elevated levels of IL-2 can often prompt some autoimmune diseases, such as rheumatoid arthritis and Takayasu arteritis. Current IL-2 and IL-10 polymorphism can be used as biomarkers for the evaluation of Graves disease in patients with hyperthyroidism. Also, TGF- $\beta$ , which is secreted by fibroblasts, also plays an important role in autoimmune diseases. In the immune system, the function of TGF- $\beta$  is mainly to induce the differentiation of induced Treg cells (regulatory T cells). iTreg cells have been previously reported to play a role in systemic lupus erythematosus, SLE (Systemic Lupus Erythematosus), type 1 diabetes and other autoimmune diseases. It is known that the main

mechanism refers as playing a pathogenic role through the regulation of interleukin cytokines, but the specific mechanism is not clear<sup>17</sup>. We also found that in patients with exophthalmos, the expression level of IL-6 was significantly higher than hyperthyroidism patients with senile thyroid goiter without ophthalmopathy ( $p < 0.05$ ). This is consistent with the previous reports. Kumar et al<sup>18</sup> reported that in the peripheral circulation of patients with Graves ophthalmopathy, autoantibodies of thyrotropin receptor, TSHR, and proinflammatory cytokine IL-6 were significantly increased in serum and ocular tissues. These autoantibodies can also increase IL-6 expression and secretion in fat cells and fibroblast, and can through activation of Akt and NF- $\kappa$ B signaling pathway regulate fibroblast proliferation and differentiation, which directly affects the patient's disease and prognosis. Therefore, we suggest that the detection of the level of IL-2, IL-6, and TGF- $\beta$  in patients with goiter and hyperthyroidism can be used in early diagnose of patients with atypical thyroid enlargement and hyperthyroidism whose symptoms are not typical.

There are some limitations in our study; we used the method of empty needle puncture for pathological tissue collection and pathological diagnosis of patients with thyroid enlargement, and take histological localization of IL-2, IL-6, and TGF- $\beta$  by immunohistochemistry staining. In some patients with thyroid enlargement, the empty needle puncture method easily punctures follicle cells, resulting in the release of thyroxine. Although the peripheral blood test can detect the inflammatory factor in white blood cells, the detection efficiency of this method is low. The detection concentration of inflammatory factors in peripheral blood is far lower than that *in situ* tissue, and the detection rate is poor. At present, there is a lack of noninvasive methods for the examination of tissue inflammatory factors. This also greatly limits the scope of the application of this study.

**Table II.** General clinical diagnostic indexes of two groups (U/L)

	Age (years old)	Course of disease (year)	BMI (kg/m <sup>2</sup> )	TT3 (ng/ml)	TT4 (ug/dl)	FT3 (ng/dl)	FT4 (ng/dl)	TSH (mIU/L)
Exophthalmos	61.3 ± 3.5	1.23 ± 0.34	19.8 ± 1.4	2.81 ± 0.45	28.2 ± 3.86	19.6 ± 3.48	8.38 ± 4.27	7.84 ± 2.67
No exophthalmos	62.4 ±	1.47 ± 0.46	17.2 ± 0.69	2.07 ± 0.98	20.3 ± 2.78	11.3 ± 2.23	5.38 ± 2.38	4.42 ± 1.28
Control group	62.8 ± 4.7	1.27 ± 0.89	19.27 ± 0.87	1.68 ± 2.54	10.2 ± 3.92	8.83 ± 2.68	1.58 ± 2.24	3.28 ± 2.34
F-value	0.38	0.22	0.97	2.19	8.82	9.33	4.27	6.49
p-value	> 0.05	> 0.05	> 0.05	< 0.05	< 0.05	< 0.05	< 0.05	< 0.05

## Conclusions

We suggest that the detection of the level of IL-2, IL-6, and TGF- $\beta$  in elderly patients with goiter and hyperthyroidism, can be used in early diagnose of patients with atypical thyroid enlargement and hyperthyroidism, whose symptoms are not typical.

## Conflict of Interest

The Authors declare that they have no conflict of interests.

## References

- 1) COOPER DS, DOHERTY GM, HAUGEN BR, KLOOS RT, LEE SL, MANDEL SJ, MAZZAFERRI EL, MCLIVER B, PACINI F, SCHLUMBERGER M, SHERMAN SI, STEWARD DL, TUTTLE RM. Revised American Thyroid Association management guidelines for patients with thyroid nodules and differentiated thyroid cancer. *Thyroid* 2009; 19: 1167-1214.
- 2) LUTON D, ALBERTI C, VUILLARD E, DUCARME G, OURY JF, GUIBOURDENCHE J. Iodine deficiency in northern Paris area: impact on fetal thyroid mensuration. *PLoS One* 2011; 6: e14707.
- 3) ZOU S, WU F, GUO C, SONG J, HUANG C, ZHU Z, YU H, GUO Y, LU X, RUAN Y. Iodine nutrition and the prevalence of thyroid disease after salt iodization: a cross-sectional survey in Shanghai, a coastal area in China. *PLoS One* 2012; 7: e40718.
- 4) CHEN Z, XU W, HUANG Y, JIN X, DENG J, ZHU S, LIU H, ZHANG S, YU Y. Associations of noniodized salt and thyroid nodule among the chinese population: a large cross-sectional study. *Am J Clin Nutr* 2013; 98: 684-692.
- 5) ZIMMERMANN MB, BOELAERT K. Iodine deficiency and thyroid disorders. *Lancet Diabetes Endocrinol* 2015; 3: 286-295.
- 6) VOLZKE H, LUDEMANN J, ROBINSON DM, SPIEKER KW, SCHWAHN C, KRAMER A, JOHN U, MENG W. The prevalence of undiagnosed thyroid disorders in a previously iodine-deficient area. *Thyroid* 2003; 13: 803-810.
- 7) SINGH ON, MARAKA S, ESPINOSA DYA, BRITO JP, CASTRO MR, MORRIS JC, MONTORI VM. Prognosis of patients with benign thyroid nodules: a population-based study. *Endocrine* 2016; 54: 148-155.
- 8) WANG JJ, ZHOU JJ, YUAN XL, LI CY, SHENG H, SU B, SHENG CJ, OU S, LI H. Hyperthyroidism caused by acquired immune deficiency syndrome. *Eur Rev Med Pharmacol Sci* 2014; 18: 875-879.
- 9) GRUBECK-LOEBENSTEIN B, VIERHAPPER H, BRATUSCH-MARRAIN P, NOWOTNY P, WALDHAUSL W. [Diagnosis and therapy of patients with simple goiter within the scope of a thyroid gland ambulatory care service]. *Schweiz Med Wochenschr* 1984; 114: 654-659.
- 10) HU ZJ, HE JF, LI KJ, CHEN J, XIE XR. Decreased microRNA-146a in CD4+T cells promote ocular inflammation in thyroid-associated ophthalmopathy by targeting NUMB. *Eur Rev Med Pharmacol Sci* 2017; 21:1803-1809.
- 11) DONG YH, FU DG. Autoimmune thyroid disease. Mechanism, genetics and current knowledge. *Eur Rev Med Pharmacol Sci* 2014; 18: 3611-3618.
- 12) LIAO D, LIU YQ, XIONG LY, ZHANG L. Renoprotective effect of atorvastatin on STZdiabetic rats through inhibiting inflammatory factors expression in diabetic rat. *Eur Rev Med Pharmacol Sci* 2016 20: 1888-1893.
- 13) MIYARA M, GOROCHOV G, EHRENSTEIN M, MUSSET L, SAKAGUCHI S, AMOURA Z. Human FoxP3+ regulatory T cells in systemic autoimmune diseases. *Autoimmun Rev* 2011; 10: 744-755.
- 14) EISENSTEIN Z, ENGELSMAN E, WEISS M, KALECHMAN Y, SREDDI B. Modulation of the IL-2 production defect in vitro in Graves' disease. *Clin Exp Immunol* 1994; 96: 323-328.
- 15) GILLESPIE EF, RAYCHAUDHURI N, PAPAGEORGIOU KI, ATKINS SJ, LU Y, CHARARA LK, MESTER T, SMITH TJ, DOUGLAS RS. Interleukin-6 production in CD40-engaged fibrocytes in thyroid-associated ophthalmopathy: involvement of Akt and NF-kappaB. *Invest Ophthalmol Vis Sci* 2012; 53: 7746-7753.
- 16) LIANG C, DU W, DONG Q, LIU X, LI W, WANG Y, GAO G. Expression levels and genetic polymorphisms of interleukin-2 and interleukin-10 as biomarkers of Graves' disease. *Exp Ther Med* 2015; 9: 925-930.
- 17) NGO ST, STEYN FJ, MCCOMBE PA. Gender differences in autoimmune disease. *Front Neuroendocrinol* 2014; 35: 347-369.
- 18) KUMAR S, SCHIEFER R, COENEN MJ, BAHN RS. A stimulatory thyrotropin receptor antibody (M22) and thyrotropin increase interleukin-6 expression and secretion in Graves' orbital preadipocyte fibroblasts. *Thyroid* 2010; 20: 59-65.