

Microabrasion plus resin infiltration in masking white spot lesions

A.B. ALREBDI, Y. ALYAHYA

Department of Conservative Dental Sciences, College of Dentistry, Qassim University, Qassim, Saudi Arabia

Abstract. – OBJECTIVE: Enamel opacities or white spot lesion is a result of enamel demineralization due to cariogenic activity or fluorosis, or enamel hypo-plastic/hypo-mineralized, which are an esthetic concern. A recent evidence base of dentistry has been focused on the Minimal Invasive Dental (MID) approach for treating such lesions. The aim of the study is to evaluate the esthetic improvement of white spots lesion using microabrasion and resin infiltration in upper permanent incisors, immediately and up to six months follow-up.

CASE DESCRIPTION: For the present case with enamel opacities, the minimal invasive therapy resin infiltration was chosen, preceded by microabrasion technique, to improve the teeth aesthetic appearance of the affected teeth.

An excellent improvement in 11 and 21 teeth esthetic. However, we still found good outcome in the enamel surfaces after six months follow-up, which became hard to detect, except in the near inspection. The patient was delighted with the well-defined enhancement in his esthetics smile and was mentioned no postoperative sensitivity immediately or in the recall evaluation.

CONCLUSIONS: The resin infiltration showed significant teeth esthetic improvement immediately and good follow-up outcome for six months, preceded by microabrasion. More high-quality and long-term clinical studies are needed to verify durability and factors that may affect treatment quality.

Key Words:

Minimal invasive therapy, White spots lesions, Resin infiltration, Microabrasion, Enamel opacity.

Introduction

Enamel opacities or white spot lesion (WSL) is a result of enamel demineralization due to cariogenic activity or fluorosis due to excessive fluoride exposure, or enamel hypoplastic/hypo-mineralized due to impairment of enamel development and formation before the eruption of teeth^{1,2}. Spreading of light through the subsurface miner-

al loss as a consequence of air and saliva presence in contrast to the surrounding natural enamel can cause a whitish and chalky appearance³.

Numerous individuals looking for dental esthetic treatment are concerned with tooth appearance. Shade is one of the foremost visually imperative aspects remarkably while they are smiling. Several preventive procedures have been utilized to maintain a strategic distance from the demineralization or stop and reverse the progression if that occurs. Natural and additional remineralization agents such as fluoride topically or systematic, casein phosphor peptide amorphous calcium phosphate (CPP-ACP), can arrest the progression and remineralize the lesions but cannot completely be masking the WSL^{4,5}.

Direct restoration or indirect restoration such as veneer could be an option of treatment. This procedure needs an invasive treatment that removes more of the tooth structure, in addition to the longer chair clinical treatment. A recent evidence base of dentistry has been focused on the Minimal Invasive Dental (MID) approach. The fundamental philosophy of this concept was shifting from a predominantly reparative approach to maximal conservation of natural dental structures^{6,7}.

Bleaching, microabrasion, and resin infiltration are common modes of MID; they are alternative therapy with less aggressive and novel solutions in certain clinical cases.

Resin infiltration is a low viscosity material that is primarily composed of triethylene glycol dimethacrylate (TEGDMA), which has consequently infiltrated the microporous of the inner and outer enamel surface. Sealing the micro porosities by resin will reduce the scattering of lights and slow or arrest the progression of the lesion, making it more resistant to bacterial acid attack. Other benefits of using this treatment method include partially or completely esthetic masking the enamel opacities alongside high maintenance of the dental health substance⁸⁻¹⁰.

Microabrasion is a micro-abrasive technique that was demonstrated in the 1970s through the use of 18% hydrochloric acid, hydrogen peroxide, and ether¹¹. Using 35% phosphoric acid instead of hydrochloric acid in 1989, which was thought to be beneficial because it is often used in clinical treatment for other procedures¹². The focal function of enamel microabrasion is the mechanical removal of opaque discoloration or irregular texture caused by teeth demineralization, fluorosis, and enamel hypoplasia. The elimination of the highly porous enamel surface is limited between 25-200 nm, through swabbing a mixture containing acid and an abrasive burs using a low-speed handpiece¹³.

Hence, this study aimed to discuss the contemporary procedures of the minimally invasive therapy and to evaluate the esthetic improvement of white spots lesion using microabrasion and resin infiltration in upper permanent incisors, immediately and up to six months follow up.

A Clinical Case

Diagnosis, Examination, and Treatment Procedure

A 35-year-old male patient presented at the Dental Clinic of Qassim University, Saudi Arabia. He was displeased with the presence of white spots in his smile on the upper anterior teeth since he was young. The patient stated that in the last couple of years, he visited several dental clinics to treat his complaint, and all of them suggested either composite restoration or ceramic veneer. He refused these types of treatment because he did not want to expose his teeth to an aggressive approach, especially since these options could not be a permanent solution. After that, the patient said he was pleased when he heard that the dental clinics of the University provide a less invasive and cosmetic treatment that can mask these lesions in a short-visited time.

The patient was systemically healthy, and the complete health of hard/soft intraoral tissue, the radiographic examination also disclosed normal supporting tissues. The clinical examination revealed WSL on teeth 11 and 21, which were diagnosed as enamel hypoplasia. Informed consent was obtained from the patient, and the treatment plan was chosen to be teeth polishing, microabrasion, and resin infiltration, followed by diet and oral hygiene instructions.

Microabrasion

Teeth and lesions were cleaned using prophylaxis paste. Teeth lesions were micro braided using both 37% phosphoric acid as an abrasive agent and pumice stone. Two sessions contained multiple ap-

plications of phosphoric acid; they were performed in each lesion, circling movements of 15 s using a low-speed handpiece and a rubber cup bur. Two sessions were mandatory to get a predictable outcome by removing almost a superficial of 5-10% of enamel, noted that micro-eroded enamel generally depends on the severity and depth of the lesions. At the end of each session, the teeth were polished with superfine soflex disc and Diamond R polishing paste to enhance any roughness on the surface.

Resin Infiltration

After the microabrasion session, the resin infiltrates procedure (Icon, DMG) (Figure 1) was applied according to the manufacturer's guidelines, including multiple steps. After proper isolation, the first step is to etch by 15% hydrochloric acid for two minutes above the WSL only. Then, the etched zone was washed for 30 s with exuberant water and instantly dried. Reapplications of Icon-etch were needed due to the extension of opacity lesions. The next step was applying an agent composed of 99% ethanol to dry any water that could be held within the microporosity of the surface, allowing it to rest for 30 s. After these phases, the chalky appearance was seen altered, which had less visibility than previously.

Then, the low-viscosity resin was carefully applied to the affected teeth and was permitted to fill microporosities for 3 min. The repeated application was done for 1 min as well, then removed any excess from the surface before 40 s of light curing. Finally, the roughened enamel surface was polished with a high-luster polishing paste, using goat-hair brushes and polishing disc.

Results

Regarding the clinical case (Figure 2A), it shows WSL in the central incisor's preoperative photograph. An immediately postoperative photograph (Figure 2B) using microabrasion and resin infiltration indicated an excellent improvement in 11 and 21 teeth esthetic. However, good outcome in the enamel surfaces after six months follow-up (Figure 2C) became hard to detect, except in the near inspection. High smile photographs before the treatment and in the recall visit six months later are showed in Figure 3A and 3B. Even though there was no total resolve of the WSL, the patient was delighted with the well-defined enhancement in his esthetics smile and was mentioned no postoperative sensitivity immediately or in the recall evaluation




Figure 1. Showing Resin infiltration (Icon, DMG:15% hydrochloric acid & 99% ethanol & Resin).

Discussion

At the end of the 20th century, the studies of dentistry have experienced a dramatic transform toward noninvasive or minimally invasive management. Prevention and proper diagnosis centering on the disease causes not only the consequences of the disease, but these are also the most prominent properties of this approach. The

evidence showed that if the disease causes are not addressed appropriately, the teeth restorative will bomb entering into a repetitive restorative sequence. MID has become the first treatment choice, using the least invasive surgical approach, making it favorably acceptable to the patients due to numerous advantages^{6,7}.

Optical phenomena can be explained by the clinical appearance of enamel opacities on the

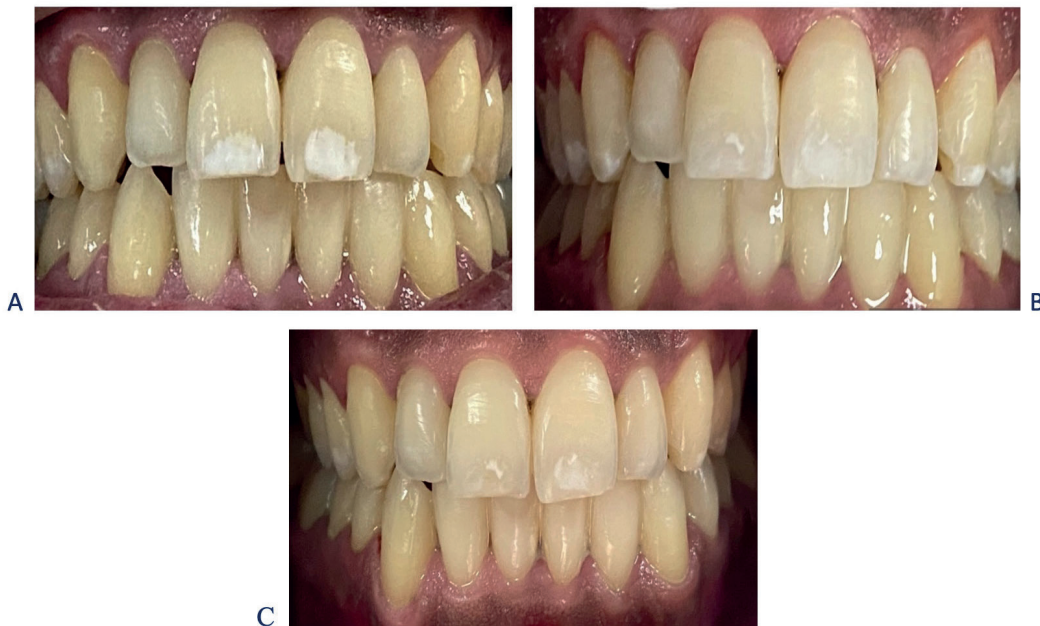

Figure 2. A, Preoperative photograph WSL in 11 and 21 teeth. B, Immediately postoperative photograph, after Microabrasion and Resin infiltration. C, Six months follow up after treatment.

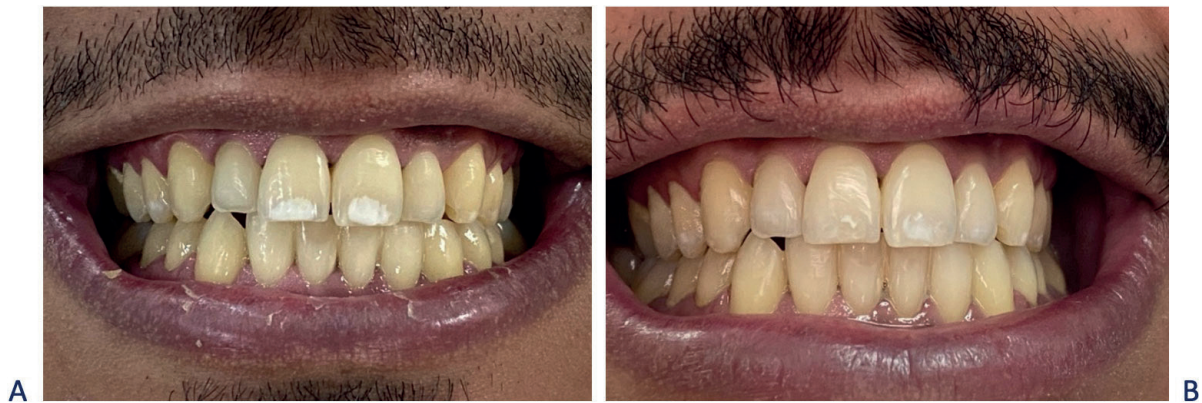

Figure 3. A, Smile before treatment. B, Smile after six months of treatment.

teeth. The refractive index (RI) of the sound enamel is 1.62, whereas the RI of the porous enamel is 1.33 when it is filled with watery medium and 1.0 when filled by air. More porous enamel increased crystalline spaces caused major variance in RI induces changes in the external scattering, resulting in the formation of white patches¹⁴.

In the present clinical case, the patient was needed two sessions of microabrasion, allowed to reduce the enamel opacity, restricted to 5-10 % of the enamel superficial layer. This procedure variations the optical appearances of the affected enamel and made it lustrous and shiny nearly to natural enamel. Resin infiltration was followed microabrasion to penetrate the deepest subsurface micro porosities and esthetically mask the central chalky appearance.

However, the patient was delighted and satisfied with the immediately brilliant result. Six months later in the follow-up, still the improvement was good and acceptable even if it was not identical to the previous outcome. The patient mentioned his shortcomings some weeks before the recall period in terms of the oral hygiene instructions.

According to the evidence, enamel micro-abrasion is practical and reliable for creating teeth visual appeal improvements. Clinical studies have considered it a safe and minimum operative intervention method subsequent to long-term and constant esthetic outcomes. Furthermore, clinical studies¹³⁻¹⁵ indicated that microabrasion with phosphoric acid showed defiant to bacterial colonization on the enamel surface. When dealing with fluorosis, it is essential to consider the extent of enamel stains or defects because microabrasion is more effective in the superficial enamel. The

latest study¹⁵ exhibited that two minutes of micro-abrasive management decreases around 10% of the enamel thickness.

It can have predicted the extension of the lesion through passing the light cure, indicating the darker shade if the lesions go deeper. The microabrasion technique produces contrast enhancement because the mineralized tissue in the enamel surface is condensed within the organic area, and the top shell of prism-rich enamel is modified with compaction with no prism layer. Reflection of the light will be inverse; enamel appeared glossy color and smooth texture^{15,16}.

In an attempt to optimize the final esthetic output, the microabrasion strategy may be integrated with certain other therapeutic interventions when absolutely required^{15,16}. Remineralizing agents, such as those used in daily oral hygiene or those that require clinical application by a dentist, have a limited effect on these abnormalities and have a slower duration, which is often highly reliant on the patients' commitment¹⁷.

The purpose of resin infiltration is to completely block subsurface microporosities while also generating a surface boundary within the body of the lesion rather than on the surface. Also, instead of removing initial caries, the resin infiltration concept aims to arrest it and inhibit the routes for acids to demineralize enamel. As a result of the lesser variation between both the refractive indices of the resin-infiltrated and intact enamel, less light is scattered, allowing the infiltrated enamel to resemble the healthy enamel^{18,9}.

Resin can optimize enamel color scheme, even in greater depth lesions, since it infiltrates deeper lesions, and the effect seems quick recovery compared to remineralization agents such as CPP-ACP

and fluoride¹⁸. Park et al¹⁹ noticed that cariogenic activity had significantly slower in the infiltrated enamel compared to non-infiltrated lesions.

Resin infiltration showed effectiveness in ceasing the progression of incipient caries in the recent systematic review and was indeed encouraging minimal intervention therapy. The masking of WSL in mild to moderate fluorosis case report using resin infiltration is significantly greater than that of natural remineralization or the routine application of fluoride varnishes as well as the patient having resin infiltration was the highest satisfied²⁰. Despite the fact that the WSL was not totally masked, the outcome of all four cases was steady at the end of the 19-month follow-up and was satisfactory to patients. In such severe cases, the authors even proposed microabrasion prior to resin infiltration or bleaching. In certain cases, improvement can be measured solely through the use of resin infiltration and necessitates minor wear in the reformed enamel to eliminate or minimize the WSL²¹.

A study exhibited masking of demineralized active post-orthodontic lesions was better than developmental anomaly lesions. There may be partial or no masking effect in deeper WSL, and inactive WSL have a thicker surface layer that inhibits infiltration. The researchers concluded the differences in outcomes depend on the depth and activity of the lesion¹⁸.

Therefore, accurate diagnosis of each case must be based on medical and dental history, a full assessment of etiology, and appropriate examination of teeth defects, including clinical manifestations, severity, depth, and activity of lesions, to implement the right treatment plan.

Conclusions

Minimally invasive therapy is considered an ease acceptable, and satisfactory treatment option for patients. The resin infiltration showed significant teeth esthetic improvement immediately and good follow-up outcome for six months, preceded by microabrasion. More high-quality and long-term clinical studies are needed to verify durability and factors that may affect treatment quality.

Acknowledgment

The researcher would like to thank the Deanship of Scientific Research, Qassim University, for funding the publication of this project.

Conflict of Interest

The authors declare that they have no conflict of interests.

References

- 1) Meyer LH, Paris S, Effenberger S, Ekstrand KR, Meyer-Lueckel H, Paris S, Ekstrand, KR, Alkilzy M, Amaechi BT, Blunck U, Buchalla W, Clarkson BH, Czajka-Jakubowska A, Doerfer C, Eggertsson H, Frankenberger R, Haak R, Hilgert LA, Leal SC, Martignon S, Soviero VM, Ricketts DNJ, Schiffner U, Schneider CA, Shellis P, Splieth CH, Twetman S, Tyas MJ, Loveren C, Meerbeek BV, Wicht MJ, Yoshida Y, Zero DT. Caries Management-Science and Clinical Practice 2013. Thieme.
- 2) Heymann GC, Grauer DA. Contemporary review of white spot lesions in orthodontics. *J Esthet Restor Dent* 2013; 25: 85-95.
- 3) Kidd EA, Fejerskov O. What constitutes dental caries? Histopathology of carious enamel and dentin related to the action of cariogenic biofilms. *J Dent Res* 2004; 83: C35-38.
- 4) Canetti MG, Cattaneo S, Hu YQ, Campus G. Amelogenesis imperfecta: a noninvasive approach to improve esthetics in young patients. Report of two cases. *J Clin Pediatr Dent* 2017; 41: 332-335.
- 5) Cochrane NJ, Shen P, Byrne SJ, Walker GD, Adams GG, Yuan Y, Reynolds C, Hoffmann B, Dashper SG, Reynolds EC. Remineralisation by chewing sugar-free gums in a randomised, controlled in situ trial including dietary intake and gauze to promote plaque formation. *Caries Res* 2012; 46: 147-155.
- 6) Ericson D, Kidd E, McComb D, Mjör I, Noack MJ. Minimally invasive dentistry--concepts and techniques in cardiology. *Oral Health Prev Dent* 2003; 1: 59-72.
- 7) Dalli M, Çolak H, Mustafa Hamidi M. Minimal intervention concept: a new paradigm for operative dentistry. *J Investig Clin Dent* 2012; 3: 167-175.
- 8) Kielbassa AM, Ulrich I, Werth VD, Schüller C, Frank W, Schmidl R. External and internal resin infiltration of natural proximal subsurface caries lesions: a valuable enhancement of the internal tunnel restoration. *Quintessence Int* 2017; 48: 357-368.
- 9) Paris S, Meyer-Lueckel H. Inhibition of caries progression by resin infiltration in situ. *Caries Res* 2010; 44: 47-54.
- 10) Kantovitz KR, Pascon FM, Nobre-dos-Santos M, Puppini-Rontani RM. Review of the effects of infiltrants and sealers on non-cavitated enamel lesions. *Oral Health Prev Dent* 2010; 8: 295-305.
- 11) Chandra S, Chawla TN. Clinical evaluation of the sandpaper disk method for removing fluorosis stains from teeth. *J Am Dent Assoc* 1975; 90: 1273-1276.

- 12) Anthony A. Removal of white spot lesions by controlled acid-pumice abrasion. *Journal of Clinical Orthodontics* <https://www.jco-online.com/archive/1989/10/690-removal-of-white-spot-lesions-by-controlled-acid-pumice-abrasion/> (accessed 2021 -10 -23).
- 13) Pini NI, Sundfeld-Neto D, Aguiar FH, Sundfeld RH, Martins LR, Lovadino JR, Lima DA. Enamel microabrasion: an overview of clinical and scientific considerations. *World J Clin Cases* 2015; 3: 34-41.
- 14) Houwink B. The index of refraction of dental enamel apatite. *Br Dent J* 1974; 137: 472-475.
- 15) Sundfeld RH, Sundfeld-Neto D, Machado LS, Franco LM, Fagundes TC, Briso AL. Microabrasion in tooth enamel discoloration defects: three cases with long-term follow-ups. *J Appl Oral Sci* 2014; 22: 347-354.
- 16) Ashfaq NM, Grindrod M, Barry S. A discoloured anterior tooth: enamel microabrasion. *Br Dent J* 2019; 226: 486-489.
- 17) Scholz KJ, Federline M, Hiller KA, Ebensberger H, Ferstl G, Buchalla W. EDX-analysis of fluoride precipitation on human enamel. *Sci Rep* 2019; 9: 13442.
- 18) Kim S, Kim EY, Jeong TS, Kim JW. The evaluation of resin infiltration for masking labial enamel white spot lesions. *Int J Paediatr Dent* 2011; 21: 241-248.
- 19) Park JH, Duarte S Jr, Meyer-Lueckel H, Paris S. Caries infiltration with resins: a novel treatment option for interproximal caries. *Compend Contin Educ Dent* 2009; 30: 13-17.
- 20) Bourouni S, Dritsas K, Kloukos D, Wierichs RJ. Efficacy of resin infiltration to mask post-orthodontic or non-post-orthodontic white spot lesions or fluorosis - a systematic review and meta-analysis. *Clin Oral Investig* 2021; 25: 4711-4719.
- 21) Tirlet G, Chabouis HF, Attal JP. Infiltration, a new therapy for masking enamel white spots: a 19-month follow-up case series. *Eur J Esthet Dent* 2013; 8: 180-190.