

# Effective combined treatment in ectopic cervical pregnancy preserving fertility: a case report and literature review

C. MININNI<sup>1</sup>, S. GARIBALDI<sup>2</sup>, L. FORNARI<sup>2</sup>, L. DOMENICI<sup>2</sup>,  
R. CATTANI<sup>2</sup>, P. BOTTONE<sup>2</sup>

<sup>1</sup>1<sup>st</sup> Unit Obstetrics and Gynecology Santa Chiara University Hospital, Pisa, Italy

<sup>2</sup>2<sup>nd</sup> Unit Obstetrics and Gynecology Santa Chiara University Hospital, Pisa, Italy

**Abstract.** – **OBJECTIVE:** Cervical ectopic pregnancy (CEP) is a rare obstetric complication but carries the risk of life-threatening maternal hemorrhage.

**CASE PRESENTATION:** A 43-year-old nulliparous woman, presented to the Emergency Room with vaginal bleeding. Initial quantitative serum  $\beta$ -hCG value was 85,220 mIU/mL. Obstetrical ultrasound demonstrated a single, live pregnancy of approximately 9 weeks' gestation located within the endocervix. After discussing different management options, intramuscular methotrexate injection in association with intra-amniotic chloride potassium installation was decided in order to preserve patient's desire for childbearing. Three months later, the patient was readmitted due to a massive vaginal bleeding. Angiographic uterine artery embolization (UAE) with an absorbable gelatin sponge was performed. After the procedure and two days of hospitalization, no significant bleeding was observed. The clinical course was uneventful, and serum human chorionic gonadotropin decreased immediately. The cervical mass gradually shrank and disappeared a month after UAE.

**CONCLUSIONS:** To preserve fertility in the management of CEP, clinicians could consider a combination of strategies, including UAE. A review of the current literature and possible treatment options for conservative CEP management are analyzed and discussed.

*Key Words:*

Cervical ectopic pregnancy, Ectopic pregnancy, Methotrexate, UAE.

## Introduction

Cervical ectopic pregnancy (CEP) is a rare and life-threatening form of gestation that occurs in less than 1% of all ectopic pregnancies<sup>1</sup>. CEP is a

result of blastocyst implantation outside the endometrium of the uterine cavity, localized in the lining of the endocervical canal<sup>1</sup>.

This pathological condition is associated with severe vaginal hemorrhage rarely concomitant with lower abdominal pain, occurring in the first trimester. The old approach considered hysterectomy as the only radical solution to definitely control hemorrhage even though unfavorable in terms of fertility preservation. Improved ultrasound resolution and earlier detection of these pregnancies consented to develop more conservative treatments to limit morbidity and preserve fertility<sup>2</sup>. Different agents as methotrexate, mifepristone or misoprostol have all been used successfully to terminate cervical ectopic pregnancy medically, usually in combination with interventional measures<sup>3</sup>.

Nevertheless, although the conservative approach allows patients to maintain their reproductive capability, on the other hand it requires a longer time with an higher complications rate risk and an uncertain success<sup>4</sup>.

Herein, we present a case of nine weeks old cervical ectopic pregnancy with fetal heart activity, emphasizing the successful diagnosis and management of this rare and critical condition.

## Case Presentation

A 43-year-old Caucasian nulliparous woman was admitted to the Emergency Room (ER) of Santa Chiara Academic Hospital (COG2) with vaginal bleeding and nine weeks' amenorrhea.

Her past gynecologic and medical history was unremarkable, with the only exception of anxiety disorder. Gynecologic examination revealed an enlarged cervix with minimal vaginal bleeding. Intravaginal ultrasonography examination dis-

closed the absence of intrauterine pregnancy and the presence of gestational sac within the cervix with a nine-week heart-beating embryo (Crown-Rump Length: 22 mm). US images were compatible with a cervical gestation (Figure 1).

Routine blood tests were matching with initial gestational age. Hemoglobin level was 11.7 g/dL and quantitative human chorionic gonadotrophic hormone ( $\beta$ -hCG) was 85,220 mUI/mL.

Treatment modalities were discussed with the patient in an accurate counseling mentioning potential risks and the severity of the condition. The patient decided for medical treatment. The proposed treatment was a single intramuscular injection of 65 mg of methotrexate (according to the Obstetrics and Gynecology Department Institutional Protocol). During the week of MTX administration, the serum  $\beta$ -hCG levels were determined at day-1, 4 and 7 since the beginning of the treatment.

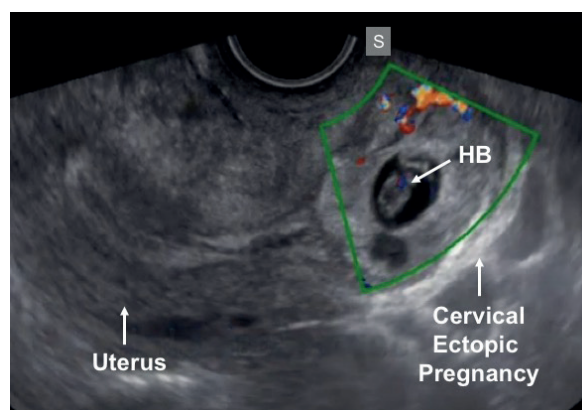
Furthermore, an US-guided intramniotic injection of Chloride Potassium (KCl) was performed with the support of local anesthesia. General blood tests were normal after the treatment. Serum  $\beta$ -hCG levels were monitored during patient hospitalization and at discharging day (last dosage: 70,726 mUI/mL with a decline of initial serum amount of 17%).

A weekly follow-up with ultrasound screening was conducted and quantitative serum  $\beta$ -hCG level decreased progressively until levels fell back to normal range in 3 months, as described in Figure 2.

Quite surprisingly, two months after, the patient was readmitted to the ER with a massive vaginal bleeding, with a reduction of 3 g/dL of hemoglobin in less than 12 hours. In order to control the risk of massive hemorrhage and to preserve fertility, angiographic uterine artery embolization (UAE) with an absorbable gelatin sponge was chosen as conservative treatment.

The UAE procedure was carried out in the Angiography Unit of Cisanello Hospital. After percutaneous puncture of right femoral artery (Seldinger technique), a 5-F catheter was inserted into one side of the internal iliac artery. Right uterine artery was selectively cannulated with a 2.2-F-tipped microcatheter.

Intraoperative angiographic examination confirmed the position of the CEP with its feeding vessels. Then, 100 mg absorbable gelatin sponge was injected into the horizontal portion of the uterine artery occluding the vessel. The procedure was repeated on the opposite side (Figure 3).



**Figure 1.** US at diagnosis: evidence of cervical ectopic pregnancy with heart-beating embryo.

After the procedure, patient's general physical conditions were optimal with stable vital signs.

The patient was informed about the possibility of late-appearing hemorrhage and the necessity of more invasive procedure. The patient was discharged after 2 days of hospitalization.

The woman did not require any further treatment and the ultrasound image of cervical mass disappear completely four months later since the diagnosis of CEP.

At the last gynecological examination, cervical vascularization was evident and preserved. The patient gave full consent to the publication of the case data and images, according to Italian law.

## Discussion

Cervical ectopic pregnancy is a rare, life threatening form of ectopic pregnancy<sup>5</sup>. The etiology of CEP is still not fully understood, and the patient of the current case did not present common risk factors related with EP, i.e., story of pelvic inflammatory disease, endometrial damage after curettage, insertion of intrauterine device (IUD) or *in vitro* fertilization<sup>2</sup>. Nevertheless, current literature has hypothesized that post-traumatic stress disorder, anxiety and depression could play a role in EP development<sup>4</sup>. Ectopic pregnancy is associated to a higher risk of severe maternal complications, such as acute critical bleeding requiring emergency hysterectomy<sup>6</sup>. CEP clinical presentation varies from asymptomatic to profuse vaginal bleeding. Pain and lower abdominal cramps occur only in one-third of the patients<sup>7</sup>. Vaginal examination, including speculum and bimanual palpation of pelvic organs, allow to identify clinical

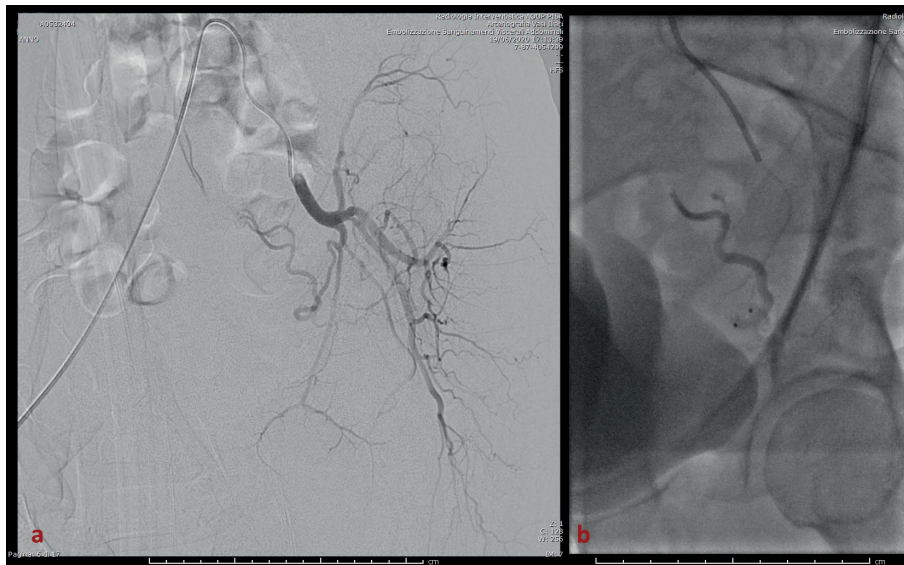


Figure 2. Regression pattern of  $\beta$ -hCG levels.

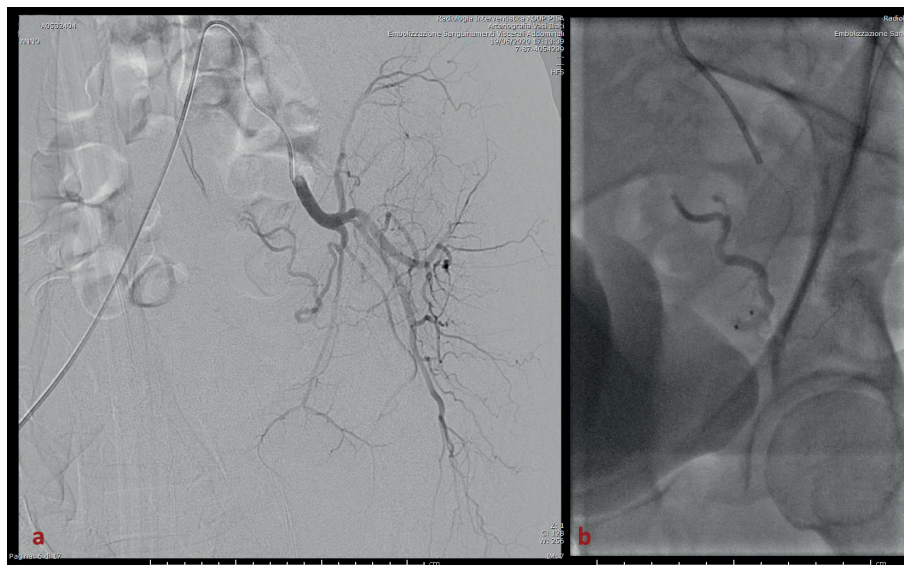

Figure 3. Angiographic embolization of the uterine arteries. Diagnostic study obtained before the uterine artery embolization show hypertrophied uterine artery (A). Post-embolization arteriogram shows the absence of opacification of distal uterine arteries as a sign of successful of the procedure (B).

signs of cervical ectopic pregnancy (e.g., uterine bleeding without cramping pain after a period of amenorrhea; softened enlarged cervix equal/larger than the corporal portion of the uterus; products of conception entirely confined within, and firmly attached to the endocervix, snug internal os and partially opened external os)<sup>4,12</sup>. In modern clinical practice, where the suspect of miscarriage or ectopic pregnancy is high, the diagnosis is es-

tablished by trans-abdominal or/and trans-vaginal ultrasound, identifying empty uterine cavity, barrel-shaped cervix, gestational sac below the level of the internal cervical os, absence of sliding-sign or blood flow around the gestational sac using Color Doppler<sup>8</sup>.

The “sliding-sign” is a probe method to establish a differential diagnosis to miscarriages: when pressure is applied to cervix, in miscarriages, the

gestational sac slides against the endocervical canal. This sign would not be seen in an implanted cervical pregnancy<sup>9</sup>. The 3D transvaginal-US is also used in obese women and in the presence of a retroverted uterus which aids detail of the endometrial cavity. When an ultrasonographic impression is inconclusive or in doubtful cases, we can use MRI<sup>10</sup>.

The most appropriate therapeutic approach for cervical ectopic pregnancy should be individualized and depend on hemodynamic conditions of the patient<sup>32</sup>. Generally, the desire of reproductive preservation leads to a conservative management. However, its success depends on gestational age and the grade of trophoblast infiltration into a connective tissue, unable to respond to mechanical hemostasis. There are no literature data that correlate maternal and gestational age and risk of medical and/or surgical related complications. This additional information could be useful to discuss and address the best and safer approach.

Systemic chemotherapy with methotrexate, used in a single or multiple doses, is the most common conservative treatment with a success rate of 91%<sup>11</sup>.

Routinely, a single dose is administered (50 mg/m<sup>2</sup> intramuscularly) with monitoring serum  $\beta$ -hCG levels on days 1, 4 and 7. If reduction of  $\beta$ -hCG levels is 15% or greater, the test is repeated weekly until it becomes untraceable. Otherwise, another methotrexate dose should be repeated with the same monitoring protocol<sup>8</sup>. Alternatively, multiple-dose regimen can be used with 1 mg/kg on days 1, 3, 5, 7, and 9 intramuscularly either with or without the folinic acid rescue dose on the days in between<sup>12</sup>.

Treatment failure was observed in gestational period more than 9 weeks with a crown-rump length > 10 mm, initial serum  $\beta$ -hCG level > 10,000 mIU/mL and presence of fetal heart activity in US scan. In clinically stable patient, the addition of intra-amniotic or intracardiac potassium chloride (KCl) instillation (3-5 mL of 2 mEq/mL) to interrupt pregnancy evolution became necessary to complete the procedure<sup>13</sup>. Alternatively an intraamniotic single dose of methotrexate can be used (50 mg/mq)<sup>6</sup>. Both these procedures require skill and expertise. In the case presented, due to advanced gestational age with fetal heartbeat and serum  $\beta$ -hCG levels, over 10,000 mIU/mL at diagnosis both local and systemic treatment were performed, in order to avoid further invasive interventions and reduce treatment failure. Sometimes, surgical treatment can be used either alone or in combination with medical treatment.

Surgical curettage can be made in order to preserve fertility but could produce abnormal acute hemorrhage requiring hysterectomy in 40% of cases<sup>14,15</sup>. Combination of surgical evacuation with other medical or surgical methods to control blood loss can prevent hysterectomy in selected cases<sup>16</sup>. In particular, selective Uterine Angiographic Embolization (UAE) can control pelvic massive hemorrhage. UAE was firstly introduced in 1990 by Lobel et al<sup>17</sup> to control bleeding in pelvic trauma or as a treatment for uterine fibroid by temporary occlusion of the uterine vessels. UAE for CEP was reported as effective adjuvant measure combined with medical treatment or surgical evacuation to reduce blood loss in these patients, becoming the real alternative to hysterectomy for bleeding control in cases of caesarean scar and cervical ectopic pregnancies<sup>5</sup>. The fundamental advantage of UAE in the treatment of CEP is preservation of fertility by using absorbable gelatin sponge. However, adverse effects as uterine infarction, ischemia or necrosis have been reported in patients treated with UAE<sup>18</sup>. Hysterectomy is the gold standard approach in patients with unstable vital signs and excessive bleeding, advanced CEP and in a woman not desiring pregnancy to avoid emergency surgery and blood transfusion<sup>6</sup>. There is a lack of evidence regarding CEP management and treatment protocols are still debated, as current literature is still scarce.

A review of literature was performed searching through all studies in PubMed database using keywords like "cervical pregnancy" and "cervical ectopic pregnancy".

From January 1999 to September 2020 information from 47 case reports of cervical gestation were gathered, in addition to the present report. Studies published before 1999 were excluded due to the uniformity in surgical treatment for CEP, since the scarce knowledge of methotrexate utilization in CEP itself.

Exclusion criteria were the presence of patients with a hemodynamic instability, abnormal vital signs, heterotopic pregnancy patients who aimed to maintain the intrauterine (IU) pregnancy. Of these selected studies, 21 were used in our analysis while 26 were excluded due to exclusion criteria. Demographic parameters including age, gestational age were recorded.

In Table I, a case series regarding clinical and conservative management is presented. In this literature review, 21 women with a single CEP and a mean age of  $35.3 \pm 4.6$  years were stud-

**Table 1.** Overview of cervical ectopic pregnancies: a case series analysis. Legend: NR, not reported; CS, cesarean section.

Author (year)	Maternal age	Risk factors	Gestational age at diagnosis	Treatment	Presenting symptom/Complications
Current paper 2020	43	NR	9 weeks	MTX IM, uterine artery embolization	Vaginal bleeding/ bleeding
Mssoud et al <sup>10</sup> 2020	37	NR	5 weeks	MTX IM	Vaginal bleeding
Khatib et al <sup>19</sup> 2020	30	NR	8-10 weeks (bimanual diagnosis)	Misdiagnosed cervical pregnancy treated with CG aspiration that caused uncontrollable bleeding/LPT hysterectomy	Vaginal bleeding
Ozcivit et al <sup>11</sup> 2019	37	NR	11 weeks	Local and systemic MTX injection	Asymptomatic
Dobrosavljevic et al <sup>20</sup> 2019	35	NR	8 weeks	curettage (with local application of chemical coagulant, human fibrinogen and human thrombin set) and suture	Vaginal bleeding
Laya et al <sup>21</sup> 2019	31	NR	10 weeks	MTX IM ligation of cervical artery and Foley catheter insertion	Vaginal bleeding and abdominal pain/ blood transfusion
Mahdavi et al <sup>22</sup> 2019	35	ICSI and 3 Embryo Transfer	6 weeks	(MTX refused) McDonald cerclage suture and OXY EV	Vaginal bleeding
Drezett et al <sup>23</sup> 2019	36	IVF	6 weeks	CG aspiration	Vaginal bleeding
Saito et al <sup>24</sup> 2018	39	IVF	5 weeks	CG extraction with forceps (US guided)	Vaginal bleeding/Blood transfusion, total placenta accreta, hysterectomy
Elmahdy et al <sup>15</sup> 2018	33	NR	11 weeks	intra-amniotic installation of KCl, uterine artery embolization and curettage, Bakri balloon	Vaginal bleeding/blood transfusion
Takeda et al <sup>5</sup> 2018	44	NR	8 weeks	MTX IM and artery embolization	Vaginal bleeding
Mouhajer et al <sup>16</sup> 2017	35	Grand multipara (para 8)	16 weeks	Cervical pregnancy misdiagnosed: LPT Hysterectomy	Vaginal bleeding and anemia/blood transfusion
Kuzmar et al <sup>25</sup> 2017	39	IVF (3 embryo transfer) and prior CS	6 weeks	MTX IM and hysterectomy	Abdominal pain and vaginal bleeding
Kadija et al <sup>26</sup> 2016	39	NR	12 weeks	Curettage, prostin into the cervix and Foley catheter insertion + secondary aspiration and MTX IM (1° and 7° days)	Asymptomatic
Kaur et al <sup>27</sup> 2016	27	NR	6 weeks	Uterine artery embolization and curettage	Vaginal bleeding
Singh S <sup>6</sup> 2013	32	NR	9 weeks	MTX IM, CG aspiration, Foley catheter insertion	Vaginal bleeding
Firoozeh A <sup>28</sup> 2012	38	Resection of uterine septum and ICSI	7 weeks	Both local and systemic KCl and MTX injection	Asymptomatic
Ferrara et al <sup>9</sup> 2007	34	6 elective first trimester abortions, and 1 cervical pregnancy	7 weeks	MTX IM and intra-amniotic installation of both KCl and MTX	Vaginal bleeding

*Table continued*

**Table 1. (Continued).** Overview of cervical ectopic pregnancies: a case series analysis. Legend: NR, not reported; CS, cesarean section.

Author (year)	Maternal age	Risk factors	Gestational age at diagnosis	Treatment	Presenting symptom/Complications
Cepni et al <sup>29</sup> 2004	27	NR	7 weeks	MTX IM, CG aspiration	Asymptomatic/bleeding and blood transfusion
Gun et al <sup>30</sup> 2002	39	Dilatation and curettage 3 years before and abnormal pap smear (erosions) with colposcopy and diathermy also 3 years previously	6 weeks	MTX IM, uterine artery embolization	Vaginal bleeding and abdominal pain
Nappi et al <sup>31</sup> 1999	32	NR	11 weeks	MTX EV for 5 days, uterine artery embolization, Vacuum evacuation and curettage, Foley balloon	Asymptomatic

Legend: NR, not reported; CS, cesarean section.

ied. Mean gestational age was  $8.3 \pm 2.8$  weeks. Of these 21 women, 13 women (61.9%) had not risk factors CEP-related, while 8 women (38.1%) had risk factors. Symptoms, like vaginal bleeding, abdominal pain, recurred in 16 cases (76.2%). Medical treatment was the first-line strategy in 13 cases (61.9%), and complications, emerged in 10 cases (47.6%) requiring surgical treatment. In this group, hemorrhage was the only complication appeared, and in a single case hysterectomy was necessary. Surgical treatment was performed as a first-line strategy in 8 cases (38.1%), due to patient decision since the medical treatment would have been prolonged and uncertain in time. Medical treatment was successful, without any complications, in women with a maternal age of  $37.3 \pm 0.6$  years, and with a gestational age of  $7.7 \pm 3.1$  weeks.

Post-operative complications, that required blood transfusion or more invasive surgical treatment, appeared in 13 cases (61.9%). These complications, occurred in women with a mean age of  $35.9 \pm 1.3$  years and with a gestational age of  $9.3 \pm 0.7$  weeks. No significant differences were reported in relation with maternal age ( $p$  0.46), but gestational age seemed to be directly related with post-operative complications (beta 0.08,  $p$  0.036). Moreover, a gestational age older than eight weeks can predict an higher post-operative complication rate with a sensibility of 77% and a specificity of 88.5% (AUC 0.79).

## Conclusions

Despite the limitations, our study is one of the few papers highlighting the effective role of a combined therapy (medical plus UAE) in the treatment of CEP when patients desire to preserve fertility.

However, it is worth mentioning that the number of literature reports is still insufficient to safely establish the best treatment for this condition.

UAE is desirable in patients with CEP because recovery time is rapid after this minimally invasive conservative surgical procedure, as uterus and fertility are preserved. If clinical circumstances are amenable to a trial of embolization, results of interventional radiology should be consulted for management of CEP.

From our literature review, advanced gestational age represents a significant risk factor for post-operative complications, there are no correlation with maternal age.

Although CP can be life-threatening and might sometimes require hysterectomy, the combination of systemic methotrexate and UAE could be considered an effective and safe treatment for non-tubal ectopic pregnancy in women who desire to conceive.

Nonetheless, treatment should be individually chosen considering the patient's compliance and the personal experience of the doctor in charge.

### Acknowledgements

Authors' conflict of interest disclosure, research funding, employment or leadership: nothing to declare.

### Conflict of Interest

The Authors declare that they have no conflict of interests.

## References

- 1) Surampudi K. A case of cervical ectopic pregnancy: successful therapy with methotrexate. *J Obstet Gynaecol India* 2012; 62:1-3.
- 2) Pertegal-Ruiz M, García-Sánchez F, Pérez-Carrión A, Capel-Aleman A, Parilla-Paricio JJ, Abad-Martínez L. Fertility preservation in heterotopic cervical pregnancy: what is the best procedure? *Fetal Diagn Ther* 2011; 30: 229-233.
- 3) Gómez García MT, Aguarón Benitez G, Barberá Belda B, Callejón Rodríguez C, González Merlo G. Medical therapy (methotrexate and mifepristone) alone or in combination with another type of therapy for the management of cervical or interstitial ectopic pregnancy. *Eur J Obstet Gynecol Reprod Biol* 2012; 165: 77- 81.
- 4) Jacob L, Kalder M, Kostev K. Risk factors for ectopic pregnancy in Germany: a retrospective study of 100,197 patients. *Ger Med Sci* 2017; 15: Doc19.
- 5) Takeda K, Mackay J, Watts S. Successful management of cervical ectopic pregnancy with bilateral uterine artery embolization and methotrexate. *Case Rep Emerg Med* 2018; 2018: 9593824
- 6) Singh S. Diagnosis and management of cervical ectopic pregnancy. *J Hum Reprod Sci* 2013; 6: 273-276.
- 7) Surampudi K. A case of cervical ectopic pregnancy: successful therapy with methotrexate. *J Obstet Gynaecol India* 2012; 62: 1-3.
- 8) Green-top Guideline No. 21 RCOG/AEPU Joint Guideline. November 2016.
- 9) Ferrara L, Belogolovkin V, Gandhi M, Litton C, Jacobs A, Saltzman D, Rebarber A. Successful management of a consecutive cervical pregnancy by sonographically guided transvaginal local injection: case report and review of the literature. *J Ultrasound Med* 2007; 26: 959-965.
- 10) Massoud D, Halimeh R, Sleiman R, Geahchan A, Abdallah A, Feghali J, Arida B. Cervical ectopic pregnancy, a case report and literature review. *J Gynecol Obstet* 2020; 8: 85-90.
- 11) Ozcivit IB, Cepni I, Hamzaoglu K, Erenel H, Madazlı R. Conservative management of 11 weeks old cervical ectopic pregnancy with transvaginal ultrasound-guided combined methotrexate injection: case report and literature review. *Int J Surg Case Rep* 2020; 67: 215-218.
- 12) Meis L De, Bolletta M, Fratto R, Sansavini S, Orsini LF. Diagnosi e terapia della gravidanza extrauterina. *Riv It Ost Gin* 2010; 161-170.
- 13) Nazac A, Gervaise A, Bouyer J, de Tayrac R, Cappella-Allouc S, Fernandez H. Predictors of success in methotrexate treatment of women with unruptured tubal pregnancies. *Ultrasound Obstet Gynecol* 2003; 21: 181-185.
- 14) Fylstra DL. Cervical pregnancy: 13 cases treated with suction curettage and balloon tamponade. *Am J Obstet Gynecol* 2014; 210: 581.e1-5.
- 15) Elmahdy A, Yousef R, Badr SS, Al-Obadli A, Szmi-gielski W, Elkady B, Ashwini G, Ibrahim AA, Manal T. Cervical ectopic pregnancy with cervical placental invasion. A case report of a rare entity: diagnosis and management. *Indian J Appl Radiol* 2018; 4: 123.
- 16) Mouhajer M, Obed S, Okpala AM. Cervical ectopic pregnancy in resource deprived areas: a rare and difficult diagnosis. *Ghana Med J* 2017; 51: 94-97.
- 17) Lobel SM, Meyerovitz MF, Benson CC, Goff B, Bengtson JM. Preoperative angiographic uterine artery embolization in the management of cervical pregnancy. *Obstet Gynecol* 1990; 76: 938-941
- 18) Elmokadem AH, Abdel-Wahab RM, El-Zayadi AA, Elrakhawy MM. uterine artery embolization and methotrexate infusion as sole management for caesarean scar and cervical ectopic pregnancies: a single-center experience and literature review. *Can Assoc Radiol J* 2019; 70: 307-316.
- 19) Khatib Y, Khashikar A, Wani R, Patel RD. Cervical ectopic pregnancy: a case report of missed diagnosis. *Med J dy Patil Univ* 2016; 9: 741-743.
- 20) Dobrosavljevic A, Nikolic B, Jurisic A, Zečević N, Aničić R, Jeftović M. Diagnosis and treatment of cervical ectopic pregnancy - case report. *CEOG* 2019; 46: 139-140.
- 21) Shirinzadeh L, Jafarian AH, Davachi B, Seresht LM, Azimi H, Akbarzadeh S, Nikooiyan Y, Yousefi Z. Successful Management of cervical ectopic pregnancy: a case report. *J Midwifery Reprod Health* 2020; 8: 2254-2258.
- 22) Mahdavi A, Aleyasin A, Sheibani N. Pre-curettage cerclage in a viable triplet cervical pregnancy: a case report and review of literature. *Int J Reprod Biomed* 2019; 17: 521-524.
- 23) Drezett J, Marques D, Ottoboni R, Dzik A, Cava-gna M. Cervical ectopic pregnancy after in vitro fertilization: case report successfully treated with cervical electric aspiration. *JBRA Assist Reprod* 2019; 23: 434-438.
- 24) Saito K, Fukami M, Miyado M, Ono I, Sumori K. Case of heterotopic cervical pregnancy and total placenta accreta after artificial cycle frozen-thawed embryo transfer. *Reprod Med Biol* 2017; 17: 89-92.
- 25) Kuzmar L, Jordan J. Cervical ectopic pregnancy with colic abdominal pain. *Ciencia Innov Salud* 2017; 4: 1-5.
- 26) Kadija S, Stefanovic A, Jeremic K, Radojevic M, Cerovic-Popovic R, Srbinovic M, Likic-Ladjevic I. Successful conservative treatment of a cervical ectopic pregnancy at 13 weeks. *Clin Exp Obstet Gynecol* 2016; 43: 291-293.
- 27) Kaur R, Singh R. Effective management of early cervical pregnancy with bilateral uterine artery em-

- bolization followed by immediate evacuation and curettage: a case report. *J Obstet Gynaecol India* 2017; 67: 66-69.
- 28) Ahmadi F, Irani S. Cervical ectopic pregnancy following assisted reproductive technology: a case report. *Int J Fertil Steril* 2012; 6: 201-204.
- 29) Cepni I, Ocal P, Erkan S, Erzik B. Conservative treatment of cervical ectopic pregnancy with transvaginal ultrasound-guided aspiration and single-dose methotrexate. *Fertil Steril* 2004; 81: 1130-1132.
- 30) Gun M, Mavrogiorgis M. Cervical ectopic pregnancy: a case report and literature review. *Ultrasound Obstet Gynecol* 2002; 19: 297-301.
- 31) Nappi C, D'Elia A, Di Carlo C, Giordano E, De Placido G, Iaccarino V. Conservative treatment by angiographic uterine artery embolization of a 12 week cervical ectopic pregnancy. *Hum Reprod* 1999; 14: 1118-1121.
- 32) Albahlol IA. Cervical pregnancy management: an updated stepwise approach and algorithm. *J Obstet Gynaecol Res* 2021; 47: 469-475.