

Carbon ions therapy as single treatment in chordoma of the sacrum. Histologic and metabolic outcome studies

G. EVANGELISTI¹, M.R. FIORE³, S. BANDIERA¹, G. BARBANTI BRODANO¹, S. TERZI¹, M. GIROLAMI¹, V. PIPOLA¹, A. RIGHI⁶, C. NANNI², S. FANTI², R. GHERMANDI¹, S. MOLINELLI³, R. ORECCHIA⁴, S. BORIANI⁵, A. GASBARRINI¹

¹Oncologic and Degenerative Spine Surgery Unit, IRCCS Istituto Ortopedico Rizzoli, Bologna, Italy

²Nuclear Medicine Unit, Azienda Ospedaliera Policlinico Sant'Orsola-Malpighi, Bologna, Italy

³National Center for Hadrontherapy for the Treatment of Tumors, Pavia, Italy

⁴National Center of Oncological Hadrontherapy (CNAO), Pavia, Italy; European Institute of Oncology, Milan, Italy

⁵IRCCS Istituto Ortopedico Galeazzi, Milan, Italy

⁶Anatomy and Pathological Histology Unit, IRCCS Istituto Ortopedico Rizzoli, Bologna, Italy

Abstract. – **OBJECTIVE:** Even though carbon ions treatment (CIRT) of sacral chordoma (SC) substantially reduces tumor mass, tumor remnants are observed in most patients. Differentiating tumor remnants from necrosis is challenging, expensive in terms of imaging and time-consuming. So far, there has not been a systematic histological and metabolic analysis of post-CIRT lesions. We designed a prospective study aiming to histologically and metabolically differentiate between viable tumor and foci of necrosis and of fibrosclerosis after CIRT and correlate these findings to clinical outcome in patients with SC.

PATIENTS AND METHODS: Between January 2013 and December 2016 18 patients, 12 males and 6 females, with histological confirmation of sacral chordoma, underwent CIRT. The total dose was 70.4 GyE, with a daily fraction of 4.4 GyE, for 4 weeks. MRI was performed every three months after treatment. FDG PET-CT scan and CT-guided needle biopsy were performed 6-12 months after CIRT. The incidence of complications (intraoperative and postoperative), local control (LC), overall survival (OS) and progression-free survival (PFS), changes in neurological status, clinical outcomes and toxicity were considered.

RESULTS: All histological analysis but 2 reported signs of necrosis and of fibrosclerosis after CIRT. One of these 2 patients turned into a dedifferentiated chordoma. Radiological partial response (PR) was observed in 10 patients (56.3%) and stable disease (SD) in 5 patients (28.3). Two patients (11%) had a local relapse.

The overall survival rate was 100% at 24 months. FDG PET CT after CIRT showed uptake decreasing compared with the baseline exam in all but one patient.

CONCLUSIONS: The histological presence of necrosis and of fibrosclerosis after CIRT at the histological analysis supports the previous clinical evidence on the efficacy of CIRT. Volumetric stability of the residual mass should be considered as a success of treatment. In cases of a volumetric increase of the mass, a CT needle biopsy should always be performed. In our series, during the follow-up, the FDG-PET was able to promptly detect an increased uptake in the case which later was histologically defined as dedifferentiated chordoma.

Key Words

Chordoma, Carbon ions therapy, Particle therapy, PET-TC, Biopsy.

Introduction

Chordoma is a malignant mesenchymal tumor that shows notochordal differentiation¹. It is the most frequent primary malignant tumor of the spine and its incidence rate is 0.8 cases each 100,000 persons¹⁻³. In 50-60% of cases, it arises in the sacrum-coccyx followed by the clival region (25-30%), the cervical region (10%) and the thoracolumbar spine (5%)^{1,4}.

Usually, in the sacrococcygeal region, the symptoms are delayed and non-specific: constipation, dull and continuous pain, hemorrhoids, dysuria, hypoesthesia distributed in the sacral roots' dermatomes, bladder or bowel dysfunction. *En-bloc* surgical resection with wide/marginal margins is the mainstay of treatment for these tumors. However, surgery with appropriate oncological

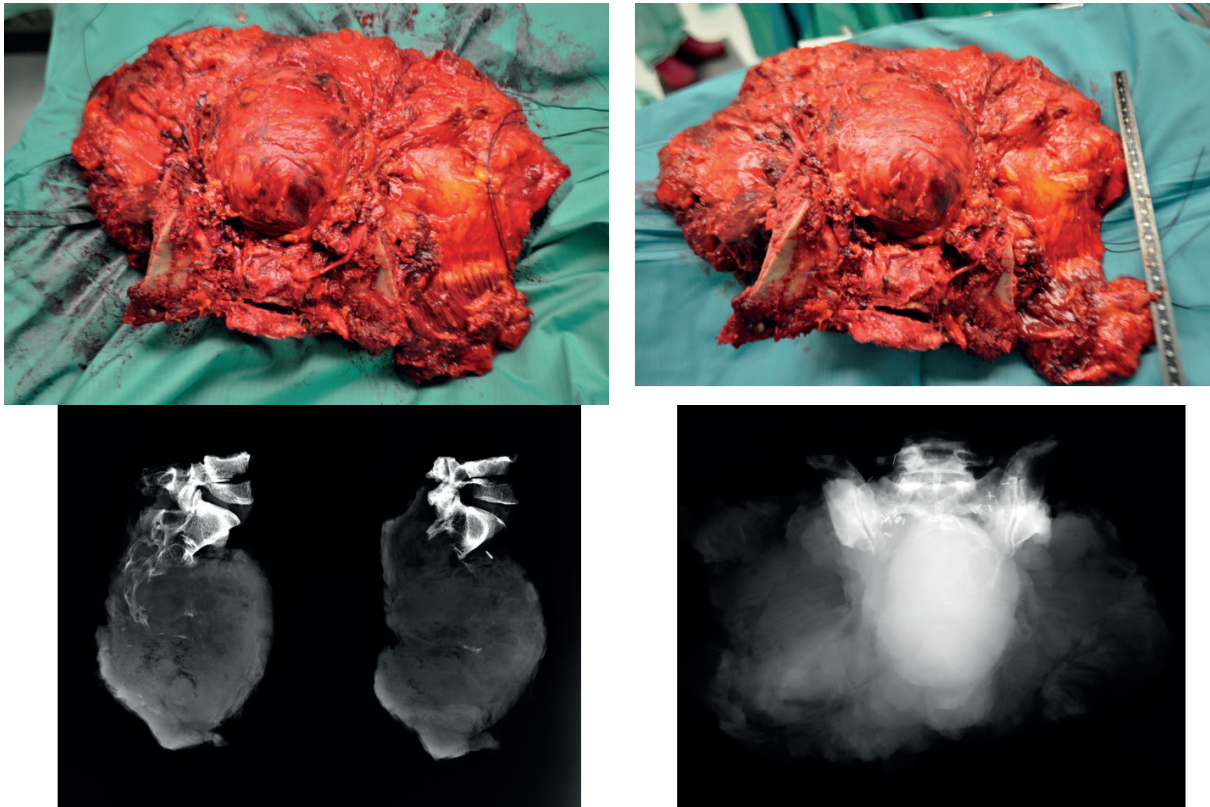


Figure 1. Surgical sample of huge mass of sacrum chordoma after sacrectomy.

margins is difficult to be achieved because of the thin pseudocapsule and the huge mass (Figure 1). Further, *en-bloc* resection of the sacrum is surgically demanding and associated with severe functional losses². The advances in the fields of high-energy particle therapy provide new opportunities for a less invasive approach. In the last years, more data have been published about local control of sacral chordoma showing stable disease or reduction of the tumor volume after carbon ions radiotherapy (CIRT)⁵⁻⁷. In the majority of cases, CIRT does not eradicate the tumor but allows disease control for many years. As a consequence, the health care providers (spine surgeons, oncologists, radiotherapists) face with a growing group of patients having a residual mass of chordoma. A big concern for the clinicians is how to deal with this remnant of the tumor. While chordoma seems to be resistant to conventional radiotherapy^{8,9}, both physical intrinsic selectivity and radiobiological properties of carbon ions allow optimal dose volume coverage sparing the healthy tissue and producing multiple damages strongly limiting the DNA repair mechanisms¹⁰.

The aim of the present prospective study is to investigate the effectiveness of carbon ion therapy alone in patients with sacral chordoma.

The tumor response to the CIRT was evaluated by CT guided biopsy. The volume changes were evaluated by fluorodeoxyglucose positron emission tomography-computed tomography (FDG PET CT) and MRI.

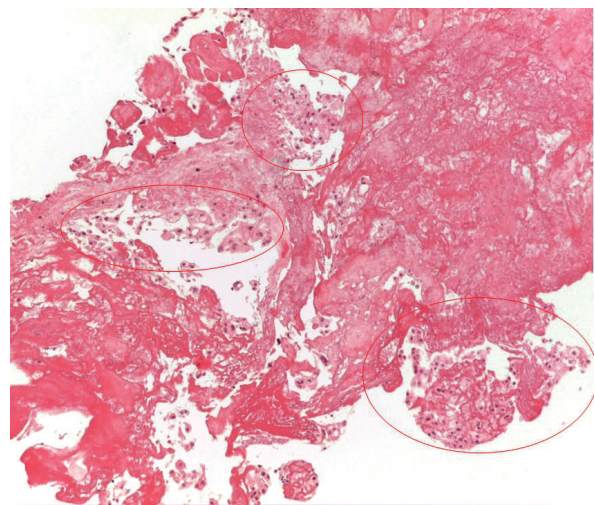


Figure 2. An example of chordoma post-CIRT where areas of necrosis and of fibrosclerosis are evident in the context of vital chordoma (circles) (10X of original magnification).

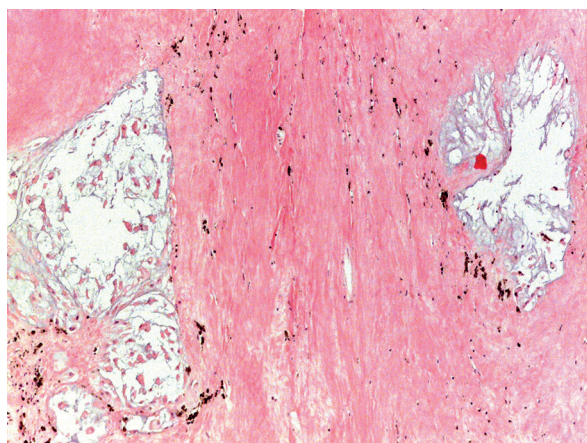


Figure 3. An example of chordoma post-CIRT with tumoral necrosis, fibrosclerosis associated with hemosiderotic deposits without foci of viable chordoma (10X of original magnification).

Patients and Methods

Between January 2013 and December 2016, 18 patients, 12 males, and 6 females, with sacral conventional chordoma histologically diagnosed, were prospectively enrolled for CIRT treatment. This study was authorized by our Institutional Ethics Committee.

The inclusion criteria were the following:

- 1) Histologically confirmed primary sacral chordoma without metastases;
- 2) No previous radiotherapy;
- 3) Adequate organ function (such as heart, lung, liver, and kidney functions good enough for radiotherapy);
- 4) No active concomitant malignancy;
- 5) Written informed consent;
- 6) Karnofsky performance status $\geq 70\%$;
- 7) Patients age 18-85 years.

The exclusion criteria were the following:

- 1) Presence of distant metastasis;
- 2) Lack of macroscopic tumor;
- 3) Metal implants at the level of the tumor that could influence the treatment planning;
- 4) Inability of the patient to lie quietly for at least 20 minutes (e.g., due to pain);
- 5) Prior radiotherapy of the pelvic region;
- 6) patient age <18 or >85 years old.

One patient was recurrent after surgical resection of the coccyx performed 7 years before. In the remaining 17 patients, the surgical planning of *en-bloc* resection would have included as potential side effects severe urinary, sexual and lower extremity functional damages. In patients over 70

years, the morbidity of *en-bloc* resection of the sacrum can also be considered a contra-indication.

All patients signed an informed consent form after a careful discussion concerning the advantages and disadvantages of surgery versus carbon-ions treatment.

Patients' characteristics are summarized in Table I.

All 18 patients performed biopsy and fluorodeoxyglucose positron emission tomography-computed tomography (FDG PET-CT) scan before treatment. All patients underwent carbon ions radiotherapy using an active scanning beam delivery system. The patients underwent to computed tomography (CT) images previously immobilized in customized support and thermoplastic sheet and followed by high field magnetic resonance (MRI) to accurately define tumor target volume and organs at risk. Three-dimensional treatment planning of CIRT was performed. The total dose was 70.4 GyE, once daily fraction dose of 4.4 GyE, for a total of 16 fractions within 4 weeks¹².

To avoid radiation toxicity, a bowel displacement from the tumor by implanting a silicon sheet was performed in 3 patients

Local control was defined as a reduction or stability volume of the mass at MRI control compared with baseline images. Furthermore, the metabolic target volume (MTV) was measured on pre-treatment and post-treatment PET evaluation; this was intended as the mean volume of the mass with metabolic activity. Reduction in the metabolic target volume was considered a parameter of local control.

Local recurrence was suspected after an enlargement of the primary tumor, measured on CT and MRI control, or in case of a new localization outside the treatment fields and confirmed histologically with a biopsy.

All patients were followed up for late toxicity and radiologic response every three months after CIRT with clinical examinations and magnetic resonance imaging (MRI).

Table I. Characteristics of patients with sacral chordoma treated with carbon ions therapy.

Characteristic	N=18
Mean age (range)	64.7 (83-43)
Male	12 (66.7%)
Female	6 (33.3%)
Spacer placement	3 (16.7%)
Proximal tumor extension	L5: 1 pts S1-S2: 10 pts S3-S4 or below: 7 pts

FDG PET-CT scan and biopsy were performed after 6-12 months after CIRT. The patients lost to follow-up were included to the time of their last follow-up.

Recurrences have been managed as follows: re-irradiation and eventual subsequent cryosurgical intralesional resection in case of new recurrence.

The occurrence of complications (intraoperative and postoperative), local control (LC), overall survival (OS), and progression-free survival (PFS), changes in neurological status, clinical outcomes and toxicity were considered. Clinical outcomes of the patients were evaluated by the numeric rating scale (NRS) score for pain. Toxicity was evaluated using the NCI Common Terminology Criteria for Adverse Events¹³.

Histological and Immunohistochemically analysis

The surgical biopsies were embedded in paraffin, sectioned using a microtome at 3-5- μ m-thickness (Microm International GmbH, Heidelberg, Germany) and stained with hematoxylin and eosin for light microscopic examination. Immunohistochemically reactions were performed to assess the viable neoplastic cells of chordoma using two specific and sensible antibodies as follows. Serial, 4-mm-thick paraffin sections mounted on precoated slides were processed according to standardized automated procedures (Ventana Medical Systems, Tucson, AZ, USA) and were immunostained with the following antibodies: pan-cytokeratin AE1/AE3 (mouse monoclonal antibody, clone AE1/AE3/PCK26, Ventana, pre-diluted) and brachyury (Santa Cruz Biotechnology, Santa Cruz, CA, USA; Rabbit polyclonal antibody, 1:50 dilution). Pretreatment for antigen retrieval was performed at 95°C with Tris-EDTA pH 8 for 20 minutes. Staining was performed with an UltraView Universal DAB Detection Kit (Ventana Medical Systems, Tucson, AZ, USA). Appropriate positive and negative controls were included in each run, and the absence of a primary antibody was used as a negative control. A semi-quantitative evaluation was done to assess the viable neoplastic tissue comparing to foci of necrosis and fibrosclerosis after CIRT on the biopsies.

Statistical Analysis

Following a statistical evaluation of the data, we obtained two groups of patients (pre-treatment and post-treatment) with Gaussian distribution; therefore, the statistical significance of the differences was calculated through the Student's *t*-test.

The “*p*” value has been considered statistically significant for values <0.05. The statistical analysis has been done with the aid of the software IBM-SPSS.

Results

The mean patient age was 64.7 years (range 38-83). The mean follow-up was 23.3 months (range 6-47). The most proximal tumor extension was S1-S2 for 10 patients, S3-S4 for 7 patients, L5 for 1 patient.

Radiological partial response (PR) was observed in 10 patients (56.3%) and stable disease (SD) in 5 patients (28.3). Two patients (11%) had local relapse close to the irradiation field. One patient had a progression of the disease.

At baseline MRI images, the mean maximum axial lesion diameter for PR and SD were 81.14 mm (range: 58-124) and 89.25 mm (range: 58-122), respectively. At the last available follow-up, the mean value of maximum axial lesion diameter for PR and SD were 75.0 mm (range: 49-100 mm) and 90.2 mm (range: 76-122), respectively. No statistical significance was found (*p*-value=0.058 for the PR group and *p*-value=0.170 for the SD group).

The mean clinical target volume (cc/mm³) of the tumor before and after treatment were 374 cm³ (range 51.6-1.740) and 166 cm³ (range 17.1-651), respectively; this difference has a statistical significance since the *p*-value=0.001. The clinical target volume after CIRT was calculated on 16 patients. Two patients performed MRI at other centers. Two patients had local relapse close to the irradiation field after 9-10 months since the end of the treatment. They underwent salvage surgery and re-irradiation respectively showing local control after 30 months from the first treatment. No relapse was observed in the biopsy tract. For all patients treated with CIRT the local control rate after 24 months was 84.6%.

No patients had distant metastasis at their initial referral for treatment nor developed metastasis during or after the treatment with carbon ions. The overall survival rate was 100% at 24 months.

All patients had a histological diagnosis of conventional chordoma confirmed to the immunohistochemical expression of pan-cytokeratin AE1/AE3 and brachyury.

FDG PET CT after CIRT was available for 14 patients and showed decreasing uptake compared with the baseline exam in all but one patient. In this case, 29 months after diagnosis of conventional chordoma, CIRT, and reirradiation, a sec-

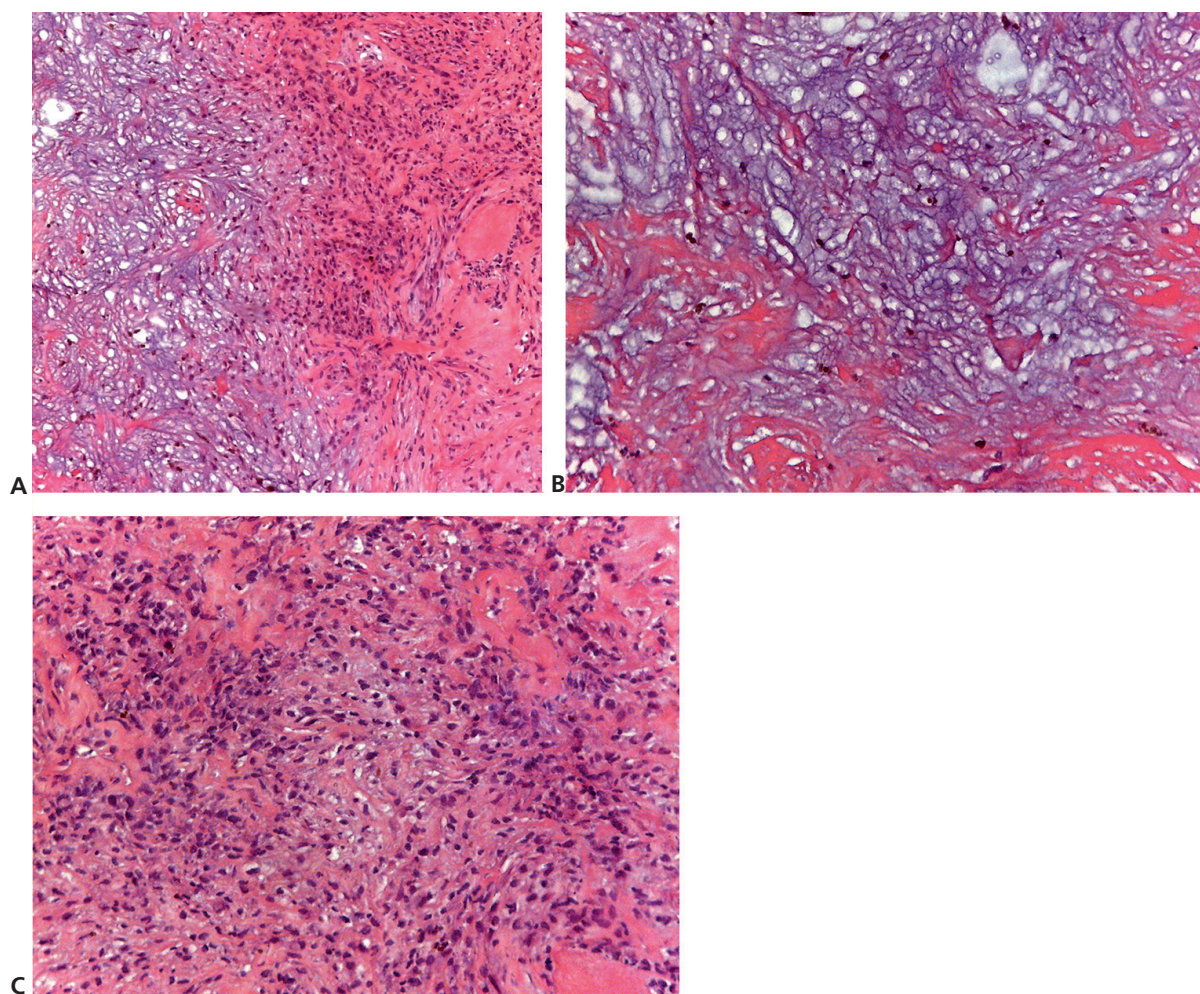


Figure 4. Dedifferentiated chordoma. **A**, On histology, typical features of chordoma with foci of necrosis and of fibrosclerosis is evident on the left with a change to an undifferentiated spindle cell sarcoma on the right (10x of original magnification). **B**, To a high magnification, foci of fibrosclerosis associated with hemosiderotic deposits and isolated physaliphorous cells embedded in abundant extracellular myxoid matrix are present. Dedifferentiated component is constituted to spindle and pleomorphic cell proliferation with collagen matrix (**C**, 20X of original magnification).

ond biopsy allowed the diagnosis of dedifferentiated chordoma (DC) (Figure 4 A, B, C).

The mean metabolic target volume (MTV) pretreatment was 203.3 cc while the mean metabolic target volume post-treatment was 223.9 cc. If we include the case subsequently diagnosed as DC, the difference is not statistically significant ($p=0.907$).

Excluding the case of DC, which had a huge enlargement of the tumor mass during the CIRT, the treatment with carbon ions gained a clear reduction in the MTV; indeed, the mean pre-treatment MTV was 156.4 cc and a mean MTV post-treatment of 57.2 cc. This difference is statistically significant ($p=0.043$).

The mean of the max SUV pretreatment was 5.1 while post-treatment was 3.4. This difference is statistically significant ($p=0.0393$).

The mean SUV pre-treatment was 2.7 and post-treatment was 1.9. This difference is not statistically significant ($p=0.0847$).

One patient (5.6%, 83 years old) died during follow-up. Death, not related to chordoma, occurred 31 months after the end of the treatment with carbon ions. Two patients (11.1%) after the treatment was completed, were not available for follow-up because of neuropsychological conditions.

The biopsy was performed to 10 patients, after 6-12 months from the end of the CIRT; the biopsy was CT-guided, not performed on PET hotspots, but

on a safely achievable portion of the mass²⁷. In 2 patients, the CT-guided biopsy was not done because the patients refused to undergo a biopsy since all the radiological reports were negative including PET-CT. 2 patients were not available at follow-up for biopsy because of the neuro-psychological conditions. 2 patients were lost at follow-up. 2 patients were still waiting for a CT-biopsy at the moment of data evaluation.

All histological evaluations but 2 reported signs of tumoral necrosis and of fibrosclerosis in the majority of the neoplastic tissue examined.

One patient was submitted to two different biopsies. A first biopsy was performed 6 months after CIRT and showed areas of necrosis and of fibrosclerosis in the context of vital chordoma (Figure 2). Since at 24 months of follow-up the MRI showed a huge reduction of the volume of the mass, we decided to study the tumor with a second post-CIRT biopsy. The pathologist reported a complete necrosis of the mass (Figure 3).

Of the 18 patients, 16 were able to walk without an assistive device at the end of CIRT. The remaining 2 patients were confined to a wheelchair before the beginning of the treatment. One of them recovered the ability to walk with the aid of one cane after 1 year since the end of treatment.

Mean NRS score before treatment and at the end of radiotherapy was 5.7 and 3.6, respectively with a statistically significant difference ($p=0.02$). Mean NRS at the last FU visit was 2.36 with a statistically significant difference compared to the mean NRS before treatment ($p=0.003$).

Toxicity

Eight patients out of 18 (44%) developed late neuropathy; of these 62.5% (5 patients) experienced mild paresthesia (G1 neuropathy), 37.5% (3 patients) developed a mild or severe pain (G2-G3) after CIRT.

Six (33.3%) patients developed skin reactions; among these 5 developed erythema (G1) while 1 developed fibrosis (G2=1). One (5.5%) patient developed mild and sporadic urinary incontinence (G1), while 1 recovered from mild urinary incontinence. One (5.5%) patient developed late gastrointestinal toxicity (G2).

No colostomies or urinary diversions were carried out as a consequence of CIRT.

Discussion

In the last years, CIRT has been gaining a significant role in the treatment of chordoma.

Sacral chordoma, because of its low growth rate, is generally diagnosed incidentally or due to huge mass symptoms. Oncologically appropriateness of *en-bloc* resection is limited by the thin thickness of the margins and by the concrete risk of tumor dissemination by surgical manipulation of the specimen, due to the jelly-like pattern of chordoma. The local recurrence rate is therefore significant, ranging from 17%-20% to 81%-100% at 5 years depending on whether the margins of resection are wide/marginal or intralesional^{17,20}.

Lee et al²⁶ reported the largest population-based study of patients with chordoma to determine factors affecting both overall survival and disease-specific survival after diagnosis. In this series, surgery is an independent good prognostic factor in vertebral and sacral chordoma; according to the experience of our center, we totally agree.

In our series, we reported carbon ions therapy being utilized as monotherapy for patients with inoperable tumors or complex resection margins cases. This means that our series is composed mostly of challenging cases that would have had a high risk of inadequate margins after surgical resection and consequently high risk of local recurrence.

Radiation therapy alone for chordoma has been reported by the same authors [26] as an independent negative prognostic factor both for overall survival and for disease-free survival. Anyway, the study does not differentiate between different types of radiation available and reports, within the same cohort of patients, those treated with photons and those treated with particles.

Even though surgery followed by radiotherapy showed a slight improvement in local control, data about local control of huge mass are not still available^{14,15,18,24}.

The superior radiobiological efficacy of CIRT^{15,16,22} and its peculiarity to deliver high doses even where the tumors are close to organs at risk offers a potential therapeutic alternative.

Despite the small number of patients, the present study supports data already published about CIRT as an effective alternative to surgery in the local control of sacral chordoma^{5,6,15-17,21,23,25}. Our results in terms of local control (84.6% at 24 months) and overall survival rates (100% at 24 months) are encouraging.

In the last 10 years, the data concerning the results of CIRT are increasing^{5-7,11,15,16,18,23,24}, but how to assess the residual tumor volume after CIRT is still to be defined. To the best of our knowledge, this is the first study where the results of the CIRT are histologically evaluated.

The histological study, performed in 10 patients after 6 to 12 months from the end of CIRT, showed areas of necrosis and fibrosclerosis in the areas of chordoma irradiated with carbon ions, confirming the efficacy of this technique histologically in the majority of patients evaluated. In one patient, a second biopsy performed after 24 months from the end of the treatment showed complete necrosis of the chordoma, suggesting a delayed effect of this therapy.

The mean metabolic volume and the clinical target volume lowered in all patients except one; this was a case of dedifferentiation. The patient, a female aging 53, showed an enlargement of the tumor mass 7 months after the end of CIRT. The tumor mass in this specific case was the biggest in our series, 1740 cm³, being widely above the mean volume of other tumors (374 cm³). This is not surprising since the volume of the mass, according to other studies¹⁵, is related to a better overall survival rate after particle therapy. Since in this case, the tumor included the sacrum and part of the ileum, the only surgical option that could provide adequate oncological margins could have been a hindquarter amputation. Following the patient's request of a conservative solution, an intralésional resection of the mass was decided, followed by CIRT reirradiation. The MRI performed at the end of reirradiation showed a significant reduction of the tumor mass corresponding to pain relief. Tumor progression started 24 months later. A second intralésional resection was performed using the augmented cryosurgery technology. The pathologist diagnosis was a dedifferentiated chordoma (Figure 4a, 4B, 4C). There is no evidence to support if dedifferentiation was spontaneous or radiation-induced¹⁸.

Dedifferentiated chordoma is a well-defined entity¹⁹. A histological examination should always be performed in cases of unexpected growth of the tumor mass after CIRT.

A mild toxicity of the structures in proximity of the irradiation field was found, but no cases of sphincter, sexual or motor dysfunctions occurred in this series. Mima et al¹⁵ reported an augmented rate of skin toxicity with 16 fractions-protocol compared to a more fractionated therapy of 32 fractions while Imai et al¹¹ reported a higher incidence of neuropathy with a total radiation dose of 70.4 GyE hypofractionated in 16 doses. In our experience, besides the 16 fractions protocol, we faced just mild skin and nerve reactions.

Our project does not end with the present article. Patients are still currently enrolled while the follow-up of the patients already enrolled is under the update process.

Our case load suggests that 6 months after CIRT could be too early to perform a biopsy. We will publish new data as soon as they are available.

Conclusions

Our preliminary results seem to confirm the efficacy of the carbon ions therapy (CIRT) for the control of sacrum chordoma. In the majority of cases, CIRT does not completely eliminate the mass; during the follow-up of patients treated with CIRT, it is often challenging to evaluate the clinical significance of the residual mass. A volumetric evaluation, performed through CT and MRI, is often inconclusive and, as a consequence, a metabolic investigation is indicated: to this purpose 18 FDG-PET scan seems the best exam when some doubts arise of the tumor growth. The validity of the PET scan in the study of chordoma is commonly accepted; it shows and quantifies the metabolic activity of the residual mass, analyzes the hypoxic areas, and could eventually guide the trocar biopsy. A CT trocar biopsy is mandatory in cases of evident growth of the residual mass, while in case of stable volume a "wait and see" attitude could be the best choice. Eleven percent of our patients had a progression of the disease close to the irradiation field; those patients underwent a new surgical excision followed by reirradiation. One of the re-irradiated cases showed a transformation to dedifferentiated chordoma.

Acknowledgements

The Authors thank Carlo Piovani and Cristiana Griffoni for their helpful collaboration in imaging storage and data management.

The work was supported by "5x1000 Grant - Healthcare research of the Italian Ministry of Health- 2018

Conflict of Interests

The Authors declare that they have no conflict of interests.

References

- 1) FLETCHER CDM, BRIDGE JA, HOGENDOORN PCW, MERTENS F. WHO Classification of Tumors of Soft Tissue and Bone. Book Published by the International Agency for Research on Cancer, Lyon, 2013.
- 2) RUGGERI P, ANGELINI A, USSIA G, MONTALTI M, MERCURI M. Surgical margins and local control in resection of sacral chordomas. Clin Orthop Relat Res 2010; 468: 2939-2947.

- 3) KIMBALL BY, YAMADA Y. Radiation Therapy for Primary Bone Tumors. Book Chapter number 4 from AOSpine Master Series, Primary Spinal Tumors, Vol. 2. Thieme, New York-Stuttgart-Delhi-Rio, 2015.
- 4) MUKHERJEE D, CHAICHANA KL, GOKASLAN ZL, AARONSON O, CHENG JS, MCGIRT MJ. Survival of patients with malignant primary osseous spinal neoplasms: results from the Surveillance, Epidemiology, and End Results (SEER) database from 1973 to 2003. *J Neurosurg Spine* 2011; 14: 143-150.
- 5) IMAI R, KAMADA T, SUGAHARA S, TSUJI H, TSUJII H. Carbon ions radiotherapy for sacral chordoma. *Br J Radiol* 2011; 84: 48-53.
- 6) IMAI R, KAMADA T, TSUJI H, SUGAWARA S, SERIZAWA I, TSUJII H, TATEZAKI S. Working Group for Bone and Soft Tissue Sarcomas. Effect of carbon ion radiotherapy for sacral chordoma: results of Phase I-II and Phase II clinical trials. *Int J Radiat Oncol Biol Phys* 2010; 77: 1470-1476.
- 7) IMAI R, KAMADA T, TSUJI H, YANAGI T, BABA M, MIYAMOTO T, KATO S, KANDATSU S, MIZOE JE, TSUJII H, TATEZAKI S; Working Group for Bone, Soft Tissue Sarcomas. Carbon ion radiotherapy for unresectable sacral chordomas. *Clin Cancer Res* 2004; 10: 5741-5746.
- 8) CATTON C, O'SULLIVAN B, BELL R, LAPERRIERE N, CUMMINGS B, FORNASIER V, WUNDER J. Chordoma: long-term follow-up after radical photon irradiation. *Radiother Oncol* 1996; 41: 67-72.
- 9) CHENG EY, OZERDEMOGLU RA, TRANSFELDT EE, THOMPSON RC JR. Lumbosacral chordoma: prognostic factors and treatment. *Spine* 1999; 24: 1639-1645.
- 10) KRAFT G. The radiobiological and physical basis for radiotherapy with protons and heavier ions. *Strahlenther Onkol* 1990; 166: 10-13.
- 11) TSUJII H, MIZOE J, KAMADA T, BABA M, TSUJI H, KATO H, KATO S, YAMADA S, YASUDA S, OHNO T, YANAGI T, IMAI R, KAGEI K, KATO H, HARA R, HASEGAWA A, NAKAJIMA M, SUGANE N, TAMAKI N, TAKAGI R, KANDATSU S, YOSHIKAWA K, KISHIMOTO R, MIYAMOTO T. Clinical results of carbon ion radiotherapy at NIRS. *J Radiat Res* 2007; 48 Suppl A: A1-A13.
- 12) FOSSATI P, MOLINELLI S, MATSUFUJI N, CIOCCA M, MIRANDOLA A, MAIRANI A, MIZOE J, HASEGAWA A, IMAI R, KAMADA T, ORECCHIA R, TSUJII H. Dose prescription in carbon ion radiotherapy: a planning study to compare NIRS and LEM approaches with a clinically-oriented strategy. *Phys Med Biol* 2012; 57: 7543-7554.
- 13) COMMON TERMINOLOGY CRITERIA FOR ADVERSE EVENTS (CTCAE) Version 4.0 Published: May 28, 2009 (V4.03: June 14, 2010) U.S. Department of Health and Human Services, National Institutes Of Health National Cancer Institute.
- 14) MOOJEN WA, VLEGGEERT-LANKAMP CL, KROL AD, DIJKSTRA SP. Long-term results: adjuvant radiotherapy in en bloc resection of sacrococcygeal chordoma is advisable. *Spine (Phila Pa 1976)* 2011; 36: 656-661.
- 15) MIMA M, DEMIZU Y, JIN D, HASHIMOTO N, TAKAGI M, TERASHIMA K, FUJII O, NIWA Y, AKAGI T, DAIMON T, HISHIKAWA Y, ABE M, MURAKAMI M, SASAKI R, FUWA N. Particle therapy using carbon ions or protons as a definitive therapy for patients with primary sacral chordoma *Br J Radiol* 2014; 87: 20130512.
- 16) FUJISAWA H, GENIK PC, KITAMURA H, FUJIMORI A, UESAKA M, KATO TA. Comparison of human chordoma cell-kill for 290 MeV/n carbon ions versus 70 MeV protons in vitro. *Radiat Oncol* 2013; 8: 91.
- 17) BERGH P, KINDBLUM LG, GUNTERBERG B, REMOTTI F, RYD W, MEIS-KINDBLUM JM. Prognostic factors in chordoma of the sacrum and mobile spine. A study of 39 patients. *Cancer* 2000; 88: 2122-2134.
- 18) WALCOTT BP, NAHED BV, MOHYELDIN A, COUMANS JV, KAHLE KT, FERREIRA MJ. Chordoma: current concepts, management, and future directions. *Lancet Oncol* 2012; 13: 69-76.
- 19) KATO S, GASBARRINI A, GHERMANDI R, GAMBAROTTI M, BANDIERA S. Spinal chordomas dedifferentiated to osteosarcoma: a report of two cases and a literature review. *Eur Spine J* 2016; 25: 251-256.
- 20) BORIANI S, BANDIERA S, BIAGINI R, BACCHINI P, BORIANI L, CAPPUCIO M, CHEVALLEY F, GASBARRINI A, PICCI P, WEINSTEIN JN. Chordoma of the mobile spine: fifty years of experience. *Spine* 2006; 31: 493-503.
- 21) COMBS SE, ELLERBROCK M, HABERER T, HABERMEHL D, HOESS A, JÄKEL O, JENSEN A, KLEMM S, MÜNTER M, NAUMANN J, NIKOGHOSYAN A, OERTEL S, PARODI K, RIEKEN S, DEBUS J. Heidelberg Ion Therapy Center (HIT): initial clinical experience in the first 80 patients. *Acta Oncologica* 2010; 49: 1132-1140.
- 22) ROTONDO RL, FOLKERT W, LIEBSCH NJ, CHEN YLE, PEDLOW FX, SCHWAB JH, ROSENBERG AE, NIELSEN G P, SZYMONIFKA J, FERREIRA AE, HORNICEK FJ, DELANEY TF. High-dose proton-based radiation therapy in the management of spine chordomas: outcomes and clinicopathological prognostic factors. *J Neurosurg Spine* 2015; 23: 788-797.
- 23) PREDAL L, STOPPA D, FIORE MR, FONTANA G, CAMISA S, SACCHI R, GHITTI M, VISELNER G, FOSSATI P, VALVO F, VITOLO V, BONORA M, IANNALFI A, VISCHIONI B, VAI A, MASTELLA E, BARONI G, ORECCHIA R. MRI evaluation of sacral chordoma treated with carbon ion radiotherapy alone. *Radiother Oncol* 2018; 128: 203-208
- 24) PENNICOOKE B, LAUFER I, SAHGAL A, VARGA PP, GOKASLAN ZL, BILSKY MH, YAMADA YJ. Safety and local control of radiation therapy for chordoma of the spine and sacrum. *Spine* 2016; 41: 186-192.
- 25) PIPOLA V, GIROLAMI M, GHERMANDI R, TEDESCO G, EVANGELISTI G, GASBARRINI A. Cryosurgery in the excision of a giant local recurrent sacral chordoma: a case report and literature review. *Eur Spine J* 2018; 27: 3059-3063.
- 26) LEE IJ, LEE RJ, FAHIM DK. Prognostic factors and survival outcomes in patients with chordoma in the United States: a population-based analysis. *World Neurosurg* 2017; 104: 346-355.
- 27) AHUJA N, SHARMA H. The effectiveness of computed tomography-guided biopsy for the diagnosis of spondylodiscitis: an analysis of variables affecting the outcome. *Eur Rev Med Pharmacol Sci* 2017; 21: 2021-2026.