

Correlation between presence of primary iris- and ciliary body cysts and intraocular pressure

R. ZHU, L. CHENG, D.-M. WANG

Institute of Xuzhou Eye Prevention and Control, Department of Ophthalmology, the First People's Hospital of Xuzhou City, Jiangsu Province, China

Abstract. – OBJECTIVE: The objective of this study was to examine the correlation between the presence of primary iris-ciliary cysts and the intraocular pressure.

PATIENTS AND METHODS: Sixty patients with short-sightedness undergoing routine examination for laser vision correction in our hospital in 2003 were enrolled. Patients with known high intraocular pressure and risk of glaucoma were excluded from the study. A total of 119 eyes were examined by the Ultrasound Biomicroscope (UBM), and the presence of the primary iris-ciliary cysts was confirmed. Intraocular pressure was measured by using a blowing tonometer for each eye in triplicate. Through Pentacam correction of intraocular pressure using the Ehlers formula, the influence of the thickness of central cornea on intraocular pressure was excluded.

RESULTS: Among all participants, 62 eyes (52.1%) were with high myopia, 57 eyes (47.9%) with low and moderate myopia, 27 eyes (22.7%) with single cyst, 20 eyes (16.8%) with multiple cysts, and 72 eyes (60.5%) were free from cysts. Moreover, the intraocular pressure was found within the normal range in 72 eyes (60.5%), and abnormally high in 47 eyes (39.5%).

CONCLUSIONS: Our results showed that the presence of primary iris-ciliary cysts and the intraocular pressure were positively correlated, with a correlation coefficient of 0.235 ($p = 0.01$). These findings may prove useful for prediction and screening of high intraocular pressure.

Key Words

Iris and ciliary cysts, Intraocular pressure, Ultrasound biomicroscope (UBM), Pentacam.

Introduction

Primary iris and ciliary cysts, usually developed in the iris or ciliary body, are a common eye disorder hardly detected by using common ophthalmic examinations. Ultrasound Biomicroscope (UBM) examination is a more advanced

diagnostic imaging test that makes it possible to visualize the anterior segment of the eye including the cornea, iris, and ciliary body¹. An UBM exam allows to ophthalmologists to view parts of the eye including iris and ciliary cysts that would otherwise not be visible².

It has been found in clinical practice that patients with iris and ciliary cysts usually experience no severe symptoms and required no special treatment. However, their intraocular pressure may be slightly higher than normal, though iris and ciliary cysts also occurred in people with normal intraocular pressure³. It was reported that cysts were the main cause of glaucoma and closure glaucoma was secondary to iris-ciliary cysts. To elucidate the correlation of these two conditions, we examined the intraocular pressure in patients with iris and ciliary cysts who underwent UBM examination and received treatment in our refractive correction and laser center. Statistical analyses were performed on collected data to assess the relationship between intraocular pressure and the presence of iris and ciliary cysts.

Patients and Methods

Patients

The protocol of this study was approved by the Ethic Committee of the First People's Hospital of Xuzhou City. Signed patients' consent was obtained before participation.

We recruited 60 patients (119 eyes) in this study, among them were 31 males (61 eyes) and 29 females (58 eyes), aged between 18 years-old and 40 years-old (mean age 29 ± 6 yr-old). The inclusion criteria were: (1) to fully anesthetize ciliary with compound tropicamide and then confirm the refractive diopter (confirmed by the MPMVA subjective refraction of phoropter), the refractive diopter could be converted by equiva-

lent sphere lens (diopter of spherical power+1/2 diopter of cylindrical power), the diopter was in the range of 1.5D-20D; (2) did not wear corneal contact lens in recent days. Additional inclusion criteria for patients with intraocular hypertension were: (1) intraocular pressure of one or two eyes was higher than 21 mmHg, recorded at least twice after Pentacam correction; (2) without glaucomatous visual field defects; (3) the optic disk and retinal nerve fiber were in normal conditions after fundus examination; (4) patients whose chamber angle was open and who didn't have history of angle closure; (5) had no other possible diseases that may lead to increased intraocular pressure. Exclusion criteria were: (1) severe complications such as keratoconus, uveitis and amotio retinae (retinal detachmen), (2) previous history of ocular injury and operation; (3) short-sighted patients whose sight was not fixed.

Methods

In this study, eye examination was performed using an UBM (Tianjin Suoer Electronics Co, Ltd, Tianjin, China). The scanning frequency and its range were set at 68 MHz and 5 mm x 5 mm, respectively. Detailed scanning procedures are described as follows. Firstly, the whole corneal limbus was divided into 8 quadrants. Each quadrant was done radially and scanned horizontally. Secondly, the chamber-angle structure and ciliary body were examined to identify the presence of iris and ciliary cyst. Then, the quantity, size and anterior chamber angle of the ciliary cyst were measured, the latter of which was the mean measurements obtained from the upper, lower, temporal and nasal positions, defined by using the positions at 0 o'clock, 3 o'clock, 6 o'clock and 9 o'clock as the dividing lines. Moreover, the intraocular pressure was measured by using a blowing tonometer (or non-contact tonometer). Three measurements were taken for each eye by the same doctor, and mean values were reported. Additionally, the thickness of cornea was measured via Pentacam¹, and its impact on Pentacam was eliminated⁴.

Statistical Analysis

SPSS 19.0 software (SPSS Inc., Chicago, IL, USA) was employed to perform statistical analyses by calculating the Spearman correlations, efficiency between intraocular pressure and the presence of iris and ciliary cysts, their size, the thickness of cornea and diopter. $p < 0.05$ was considered statistically significant

Results

Eye Abnormalities Observed in Study Participants

Results showed that among all participants, 62 eyes (52.1%) were with high myopia, 57 eyes (47.9%) with low and moderate myopia, 27 eyes (22.7) with single cyst, 20 eyes (16.8%) with multiple cysts, and 72 eyes (60.5%) were free from cysts. Moreover, the intraocular pressure was found within the normal range (from 10 mmHg to 21 mmHg) in 72 eyes (60.5%), and abnormally high (>21 mmHg) in 47 eyes (39.5%).

Morphological Study of Iris and Ciliary Cysts

Results from UBM examination showed that the ciliary cysts were mainly round and oval. The content was mainly anechoic cystic fluid with good sonolucency. The diameter of these ciliary cysts ranged between 0.1 mm to 2.5 mm (averaged 0.66 mm). The number of confirmed ciliary cysts per eye varied from none, one, to multiple (Table I). Representative ultrasound biomicroscope images are shown in Figure 1.

In regard to the general distribution of these ciliary cysts, we defined the positions at 0 o'clock, 3 o'clock, 6 o'clock and 9 o'clock as the dividing lines. The whole region was divided into four quadrants, the upper, the lower, the temporal and the nasal. We found that the temporal side was the most vulnerable site of ciliary cysts, accounting for 24 cases. There were 22 cases in the lower position, 3 cases in the upper position and 2 in the nasal side. Most of them were located the crown of ciliary cysts and at the back of iris root.

Moreover, the average value of anterior chamber angle, measured by UBM, was 36.795 ± 4.039 . Results from statistical analysis showed that the presence of primary iris-ciliary cysts and the intraocular pressure were positively correlated, with a correlation coefficient, R of 0.235 and $p=0.01$ (data not shown). Our results also showed strong positive correlations between intraocular pressure

Table I. Classification of the presence of primary iris-ciliary cysts in study participants according to the level of intraocular pressure (cases).

Intraocular pressure	No cyst	Single cyst	Multiple cysts
High	21	14	12
Normal	51	13	8

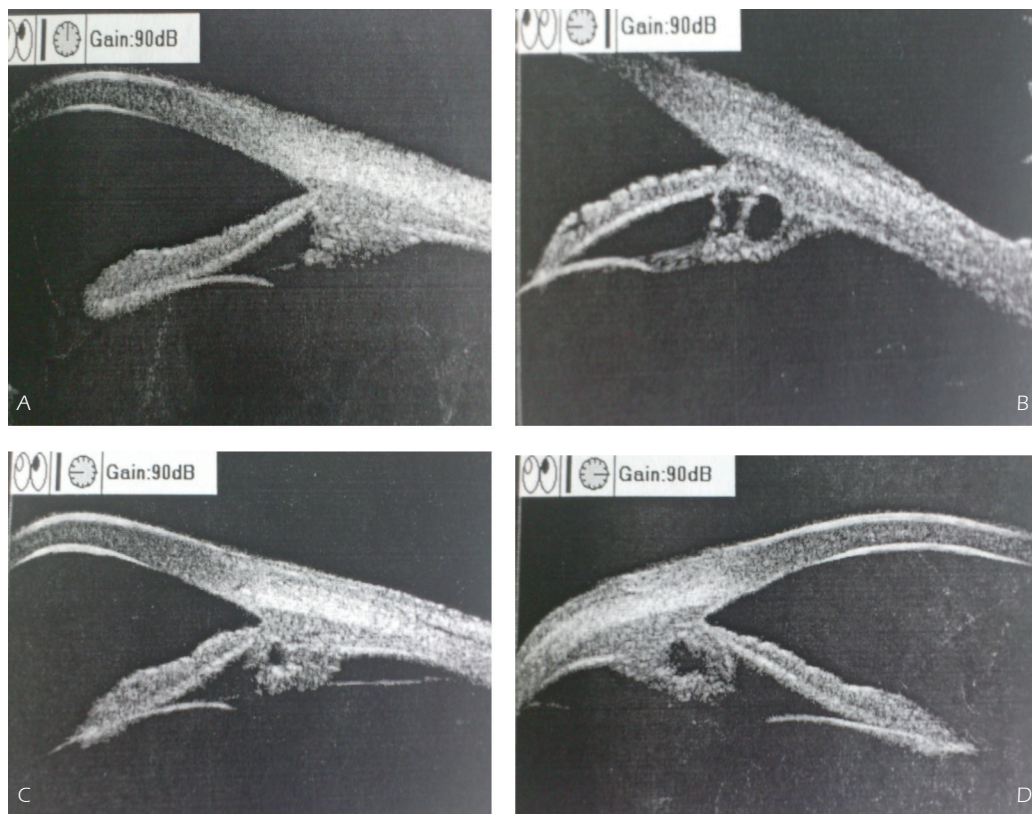


Figure 1. Representative images showing the presence of ciliary cysts. **A**, No cyst in the ciliary groove; **B**, Multiple cysts in the ciliary groove, one in the back of the iris root and one in the crown of the ciliary body; **C**, Single small cyst; **D**, Large single cyst.

with the number and the size of iris and ciliary cysts ($R= 0.278$ and 0.330 , respectively, $p<0.05$), (Table II). Strong negative correlations between anterior chamber angle with the intraocular pressure and the size of ciliary cysts were also evidenced, with $R= -0.449$ and -0.255 , respectively ($p\leq 0.005$), (Table III).

Discussion

UBM is a new ophthalmic imaging tool using ultra-high frequency and ultrasound technolo-

gy to observe sectional images⁵. Usually, it uses high transducer frequency (>40 MHz), and the imaging range covers an area of $5\text{ mm} \times 5\text{ mm}$ to $8\text{ mm} \times 12\text{ mm}$, with a high resolution, up to $20\text{ }\mu\text{m}$ ⁶. It could not only be used to observe the anterior segment, but also to show the posterior segment that most examination tools may hardly reach². In our laser center, iris and ciliary cysts were detected in some of the patients who had high intraocular pressure confirmed via the UBM examination. While the ciliary body is likely affected by many diseases, the primary iris-ciliary cysts are usually static and benign in nature. Pa-

Table II. Correlation of intraocular pressure with the quantity and the size of iris and ciliary cysts, the diopter, and the thickness of cornea (correlation coefficient (R) and *p* value).

	Iris and ciliary cysts				Diopter		Thickness of Cornea	
	Quantity		Size		R	p	R	p
	R	p	R	p				
Intraocular pressure	0.278	0.002	0.330	<0.001	0.361	<0.001	0.332	<0.001

Table III. Correlations of anterior chamber angle with intraocular pressure and the size of iris and ciliary cysts (correlation coefficient (R) and *p*-value).

	Intraocular pressure		Size of cysts	
	R	<i>p</i>	R	<i>p</i>
Anterior chamber angle	-0.449	<0.001	-0.255	0.005

tients with these cysts did not experience severe symptoms and required no special treatment³. The most common predilection site of primary cysts was the connecting site of the iris ciliary body¹. Common examination tools could not find them, but UBM could detect some structural changes of posterior chamber, the quantity, size and position of cysts. Our study has confirmed that iris-ciliary cysts were dominantly located in the crown of the ciliary body and the back of iris root, then the temporal side and the lower position, not so many in the upper position, and least on the nasal side, which was consistent with the conclusion reported by Shields et al⁷. Another finding of our study was that patients with ciliary cysts did not experience an increase in intraocular pressure and perceptible changes in size of ciliary cysts at the follow-up visits over a period of one year.

In this research, we adopted a Non-Contact Tonometer (NCT) blowing tonometer, rather than a Goldmann tonometer, to measure the intraocular pressure. According to the regression equation analysis, intraocular pressure measurement with NCT was less accurate, and slightly lower than the measurement obtained by Goldmann⁸. The authors believed that the discrepancy was attributed to the variable thickness of central cornea and diopter, a finding similar to our results presented in this study. A previous report⁹ showed that intraocular pressure was directly proportional to the thickness of central cornea and inversely proportional to diopter, but had no apparent correlation with age, gender and left or right eyes. The impact of diopter on intraocular pressure could be ignored for low or moderate short-sighted individuals. Based on these observations, we used Pentacam and the correct intraocular pressure Ehlers formula: $IOP\text{-correction} = 0.071 \times (545 \mu\text{m} - \text{the measurement of the thickness of cornea})$ for this short-sighted population, while for those high short-sighted people, we corrected the intraocular pressure except for the influence of thickness of central cornea by using the formula proposed by Kong et al¹⁰ $IOP = 0.039CCT - 0.082DIOP$ (spherical equivalent) $- 6.138$.

This investigation revealed strong correlations between intraocular pressure with the quantity and the size of iris ciliary cysts ($R = 0.278$ and 0.330 , respectively, both with $p < 0.05$). Possible reasons why ciliary cysts could lead to an increase in intraocular pressure may involve: (1) cysts stimulated ciliary body, causing an increase in aqueous fluid; (2) mucus and other materials produced by cysts deposited trabecular meshwork, thus preventing aqueous fluid from flowing out; (3) as cysts enlarged, the iris in the neighborhood moved forward, and chamber angle became narrow or closed up¹¹. Our study found that there was a significant correlation between intraocular pressure and iris and ciliary cysts, especially their size. To elucidate whether the size of cysts had an impact on the chamber angle, we further analyzed the association of the anterior chamber angle, the size of cysts and the intraocular pressure, and found that the anterior chamber angle was reversely proportional to the size of cysts and the intraocular pressure, i.e., the bigger the cysts were, the smaller the anterior chamber angle was and the higher the intraocular pressure was. We also confirmed that the squeeze of cysts on the chamber angle had an impact on the intraocular pressure, but its underlying mechanism remains unclear and requires further investigation. Although patients with iris-ciliary cysts didn't have many adverse symptoms at the time of eye examination, it was reported that cysts were the main cause of glaucoma and closure glaucoma was secondary to iris-ciliary cysts^{12,13}. Thus, ophthalmologists should pay close attention and monitor the changes in intraocular pressure of the patients for a longer period once the iris-ciliary cysts were detected, so as to avoid misdiagnosis of possibly existing glaucoma.

Conclusions

We found significant correlation between high intraocular pressure and the presence of iris-ciliary cysts, particularly the quantity and the size of the cysts. These results suggested that ophthal-

mologists should monitor the changes in patients' intraocular pressure for extended follow-up, once the iris-ciliary cysts were detected. Future investigation will continue to obtain more data on patients' intraocular pressure and UBM changes over a longer period.

Conflict of Interest

The Authors declare that they have no conflict of interests.

References

- 1) MARIGO FA, EASKI K, FINGER PT, ISHIKAWA H, GREENFIELD DS, LIEBMANN JM, RITCH R. Differential diagnosis of anterior segment cysts by ultrasound biomicroscopy. *Ophthalmology* 1999; 106: 2131-2135.
- 2) FRIELING E, DEMBINSKY B. Morphometry of the ciliary body using ultrasound biomicroscopy. *Ophthalmology* 1995; 92: 745-749.
- 3) ROCHE O, ORSSAUD C, BEBY F, DUPONT MONOD S, ROQUET W, DUFIER JL. Ultrasound biomicroscopy and physiopathology of iris congenital cysts. *Ophthalmol* 2007; 30: 25-30.
- 4) SIGNAOS DS, PAPASTERGIOU GI, MOEDAS C. Assessment of the Pascal dynamic contour tonometer in monitoring intraocular pressure in unoperated eyes and eyes after LASIK. *J Cataract Refract Surg* 2004; 30: 746-751.
- 5) PERKINS ES. Recent advances in the treatment of glaucoma. *Trans Ophthalmol Soc U K.* 1966; 86: 199-210.
- 6) ZHAO K, YANG P. *Ophthalmology*, 8th ed. Beijing: People's Medical Publishing House, 2013.
- 7) SHIELDS JA, KLINE MW, AUGSBURGER JJ. Primary iris cyst: a review of the literature and report of 62 cases. *Br J Ophthalmol* 1984; 68: 152-166.
- 8) KAUFMANN C, BACHMANN LM, THIEL MA. Comparison of dynamic contour tonometry with Goldmann applanation tonometry. *Invest Ophthalmol Vis Sci* 2004; 45: 3118-3121.
- 9) KONG X, SUN X, WANG L. The value of intraocular pressure of the short-sighted people and analysis of its influence factors. *Chin J EENT* 2005; 9: 299-300.
- 10) DOGAN B, KAZIM EM, DOGAN U, HABIBI M, BULBULLER N, TURGUT CD, BULLUT M. The retinal nerve fiber layer, choroidal thickness, and central macular thickness in morbid obesity: An evaluation using spectral-domain optical coherence tomography. *Eur Rev Med Pharmacol Sci* 2016; 20: 886-891.
- 11) LANGFORD MP, CHEN D, GOSSLEE J, MISRA RP, REDENS TB, TEXADA DE. Intracameral toxicity of bacterial components muramyl dipeptide and staurosporine: ciliary cyst formation, epithelial cell apoptosis and necrosis. *Cutan Ocul Toxicol* 2006; 25: 85-101.
- 12) STEIGERWALT RJ, VINGOLO EM, PLATEROTI P, NEBBIOSO M. The effect of latanoprost and influence of changes in body position on patients with glaucoma and ocular hypertension. *Eur Rev Med Pharmacol Sci* 2012; 16: 1723-1728.
- 13) VELA A, RIESER JC, CAMPBELL DG. The heredity and treatment of angle-closure glaucoma secondary to iris and ciliary body cysts. *Ophthalmology* 1984; 91: 332-337.