

# Study on the value of the prenatal-postnatal integrated management model in the screening, diagnosis, and treatment of fetal heart malformations

J.-O. SU<sup>1</sup>, N. LI<sup>2</sup>, J. DUAN<sup>3</sup>, J. ZHANG<sup>4</sup>, K.-Y. LIU<sup>1</sup>, C.-X. SUN<sup>2</sup>

<sup>1</sup>Office of Quality Management, <sup>2</sup>Ultrasonography Department, <sup>3</sup>Department of Radiology, <sup>4</sup>Prenatal Diagnostic Center, The Fourth Hospital of Shijiazhuang, Chang'an District, Shijiazhuang City, Hebei, China

*J.-O. Su and N. Li equally contributed to the manuscript*

**Abstract. – OBJECTIVE:** With the development and widespread use of fetal ultrasound and magnetic resonance technology in recent years, approximately 75% of fetuses are diagnosed prenatally with congenital structural malformations, a serious birth defect that endangers the life and health of the newborn. In this study, we aimed to study and analyze the value of the prenatal-postnatal integrated management model in the screening, diagnosis and treatment of fetal heart malformations.

**PATIENTS AND METHODS:** All pregnant women who were to undergo delivery in our hospital between January 2018 and December 2021 were recruited as the first subjects in this study, and after excluding those who refused to participate in the study, a total of 3,238 cases were finally included as subjects of this study. All pregnant women were screened for fetal heart malformations using the prenatal-postnatal integrated management model. Maternal files were established for all cases of heart malformations, grading the fetuses according to their heart disease grade, observing and recording their deliveries, treatment results and follow-ups.

**RESULTS:** After screening for heart malformations using the prenatal-postnatal integrated management model, 33 cases of heart malformations were identified, including 5 cases of Grade I (all delivered), 6 cases of Grade II (all delivered), 10 cases of Grade III (1 induced), and 12 cases of Grade IV (1 induced); 2 cases of ventricular septal defect healed spontaneously after delivery, and 18 infants were treated accordingly. The results of the later follow-up showed that 10 children had normalized their heart structure, 7 cases had slight alterations in the heart valves, and 1 case died.

**CONCLUSIONS:** The prenatal-postnatal integrated management model is a multidisciplinary cooperation model with certain clinical value in the screening, diagnosis and treatment of fetal heart malformations, which is beneficial to com-

prehensively improve the ability of hospital physicians in the grading management of heart malformations, detecting fetal heart malformations early and predicting fetal changes after birth. It further reduces the incidence of serious birth defects, conforms to the development trend of the diagnosis and treatment of congenital heart diseases, enables to reduce child mortality with timely treatment, effectively improves the surgical prognosis of critical and complex congenital heart diseases, with a promising application prospect.

*Key Words:*

Prenatal-postnatal integrated management, Fetal heart malformation, Screening, Diagnosis and treatment, Value.

## Introduction

Neonatal structural malformations represent a very high percentage of neonatal diseases. Heart malformations are the most common congenital malformations, with an incidence of about 30% in stillbirths and 0.5%-2.7% in live births<sup>1</sup>. They pose a relatively high risk, and some of them are difficult to treat<sup>2</sup>. With the development of fetal ultrasound screening and magnetic resonance technology, both doctors and patients are faced with such questions: is fetal heart malformation serious? How serious is it? Can I continue my pregnancy? What are the precautions to take during pregnancy? Is there a need or measure for intervention during pregnancy? Are there any special conditions for delivery? When and how is postpartum care provided? What is the final prognosis? These questions plague many patients deeply<sup>3</sup>.

A previous study<sup>4</sup> concluded that combined ultrasound and imaging screening can better detect structural malformations. The treatment of congenital structural malformations currently largely relies on neonatal surgery, most of which have a good outcome, but some of which have a poor prognosis<sup>4</sup>. In a paper published in the Chinese Journal of Pediatric Surgery in 2020, “Expert Consensus on Prenatal Consultation for Common Fetal Structural Anomalies”, it is stated that if fetal structural malformations are identified, prenatal diagnosis, consultation, follow-up or intervention recommendations should be made and measures should be developed, continuing from pregnancy until after the birth of the fetus<sup>5</sup>. The division of labor between different specialties in the comprehensive diagnosis and treatment of fetal structural malformations for transport, evaluation and early standardized treatment significantly reduces the abortion rate of fetuses with non-fatal malformations and structural malformations, increases the rate of resuscitation and cure of newborns, and improves surgical outcomes and newborns’ quality of life<sup>6</sup>. Therefore, we can tentatively determine that in early prenatal screening and diagnosis of congenital structural malformations of the fetus, scientific determination of their prognosis will improve the quality of the population and quality of life and reduce the risk of the disease to the child’s family, where the initial determination will be clinically significant for the mitigation of the condition<sup>7</sup>.

National and international research<sup>8</sup> on congenital structural malformations has focused on how to deal with them, while less research has been done on early detection, early diagnosis, early intervention, and the prenatal and postnatal integrated management system for congenital structural malformations, making this study clearly relevant. As our province is the most populous province in the country, this study will better improve the quality of our population, and enable doctors to develop better surgical treatment plans, reducing unnecessary financial and emotional burdens for families.

## Patients and Methods

### *Research Subjects*

With the approval and consent of the Ethics Committee of our hospital, all pregnant women who were to undergo delivery in our hospital between January 2018 and December 2021 were recruited as the first subjects in this study, and after

excluding pregnant women who did not meet the criteria of this study for various reasons, a total of 3,238 cases were finally included as study subjects. All study subjects were adult females, aged 22-35 years, and all had singleton pregnancies, 12-39+ weeks of gestation. All pregnant women were screened for fetal heart malformations using the prenatal-postnatal integrated management model, and fetuses with confirmed heart malformations were treated accordingly. All study subjects voluntarily signed a written informed consent after being informed about the content of this study.

### *Inclusion and Exclusion Criteria*

Inclusion criteria: women who came to our Ultrasound Department for prenatal screening at 12-39+ weeks of gestation were randomly selected, fetuses with heart malformations on prenatal ultrasound screening (fetal MRI if necessary) were counted and retrospectively analyzed, and maternal files were established for all cases of heart malformations.

Exclusion criteria: those who lost visits after delivery were excluded.

### *Methodology and Principle*

The GE VOLUSON E8 (GE Healthcare, Zipf, Tiefenbach, Austria) and Samsung WS80A (Samsung Medison, Seoul, Korea) all-digital real-time color ultrasound diagnostic instruments with transabdominal 3.5-5.0 MHz probes were applied to examine and measure the fetus by experienced physicians using the segmental analysis and diagnosis method. Prenatal-postnatal integrated management model: pregnant women screened for fetal heart abnormalities were consulted and graded according to the results of fetal echocardiography and clinical prognosis (grades I-IV); obstetricians, ultra-sonographers, genetic counselors, pediatricians, and psychological counselors conducted perinatal counseling and psychological intervention with patients face-to-face based on the results of consultations at provincial hospitals to ensure that pregnant women and their families had a comprehensive understanding of the disease and could make a final decision; appropriate surgical treatment for neonatal heart malformations can be performed postnatally, with postoperative follow-up<sup>9</sup>.

Principle: research on fetuses with heart malformations is conducted to find methods for early detection and diagnosis; for serious malformations, abortion can be induced to reduce the burden on society and families; for treatable malformations, prenatal and postnatal integrated management can be achieved in conjunction with

pediatric surgery, and corresponding treatment plans can be developed to provide timely treatment and reduce mortality.

### Observation Index

1) Fetal heart disease grading: Grade I (mild heart disease, basically no treatment needed), Grade II (simple heart disease, requiring treatment after birth, but quality of life is no different from normal), Grade III (complex heart disease with good treatment), Grade IV (severe complex heart disease). 2) All deliveries (normal delivery, cesarean section, induction of labor), treatments, and follow-ups were recorded (return to normal heart structure, presence of minor alterations in the heart valves, and death).

### Technical Keys and Routes

1) Rigorous experimental design: cases were screened in strict accordance with diagnostic and inclusion criteria; data collection, recording and

calculation were performed by dedicated personnel; the ultrasound instruments selected were stable in performance and rigorous in operation and operated in strict accordance with treatment norms. 2) Accurate and skilled examination techniques: normal and abnormal ultrasound images were accurately identified, in which abnormal fetuses were diagnosed by experienced attending physicians or senior physicians. 3) Follow-up patient data (physician telephone follow-up and patient outpatient and inpatient follow-up). 4) Statistical processing: statistical methods were correctly selected, and the test results were reliable. The technical route is detailed in Figure 1 as follows:

### Statistical Analysis

SPSS version 26.0 (IBM Corp., Armonk, NY, USA) was used to organize and statistically analyze the data; the measurement data were expressed as ( $\pm s$ ), and the *t*-test was used for the comparison of statistical differences; the enumer-

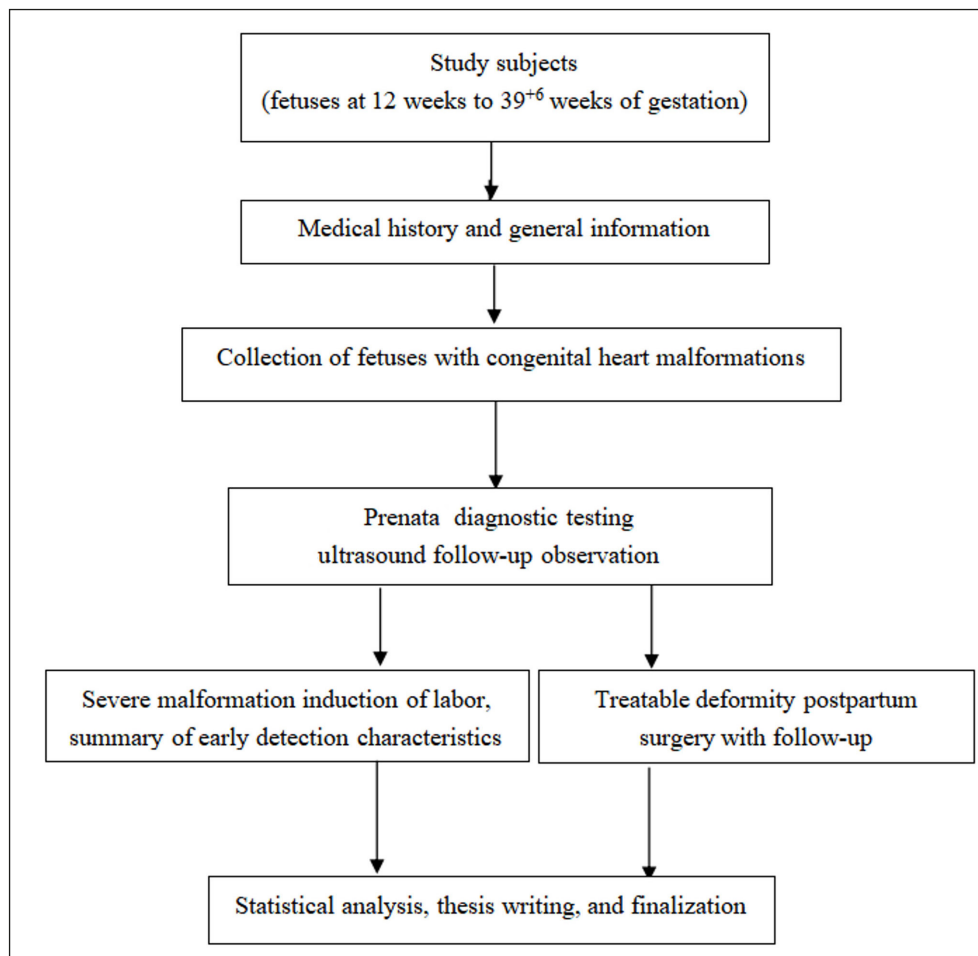


Figure 1. Technology roadmap (flowchart).

ation data were expressed as rate (%), and the Chi-square test  $\chi^2$  was used for the comparison of statistical differences;  $p$ -value<0.05 indicated that the comparison was statistically significant.

## Results

### General Information

A total of 3,238 cases were studied, of which 3,172 were married and 66 were unmarried; all were between 22-35 years old, with a mean age of  $25.45 \pm 5.45$  years; height was between 151-173 cm, with a mean height of  $164.05 \pm 5.85$  cm; gestational weeks were between 12-43 weeks, with a mean gestational weeks of  $25.89 \pm 4.56$  weeks; weight was between 58-85 kg, with a mean weight of  $70.61 \pm 10.94$  kg; years of education between 7-16 years, with an average of  $15.94 \pm 5.21$  years of education; past medical history: 456 cases of diabetes, 325 cases of hypertension, and 845 other cases (Table I).

### Screening Results

Antenatal ultrasound screening for heart malformations in the prenatal-postnatal integrated management model was performed in 3,238 pregnant women included in this study, resulting in 33 cases of cardiac abnormalities, 22 of which were later confirmed by anatomic pathology and 11 by postnatal echocardiography, with no misdiagnosis.

### Fetal Heart Disease Grading

The 33 study subjects diagnosed with fetal heart malformations were graded according to their specific conditions, including 5 cases of Grade I, 6 cases of Grade II, 10 cases of Grade III, and 12 cases of Grade IV, and the major heart malformations diagnosed prenatally and postnatally matched. The details are shown in Table II as follows:

### Delivery

Among the 5 pregnant women in Grade I, 4 cases of normal delivery, 1 case of cesarean section, and 0 case of induced labor; among the 6 pregnant women in Grade II, 3 cases of normal delivery, 3 cases of cesarean section, and 0 case of induced labor; among the 10 pregnant women in Grade III, 2 cases of normal delivery, 6 cases of cesarean section, and 2 cases of induced labor; and among the 12 pregnant women in Grade IV, 0 case of normal delivery, 1 case of cesarean section, and 11 cases of induced labor (Table III).

### Treatment

A total of 20 children required treatment, of which 18 children underwent surgical or medical interventions including percutaneous pulmonary valvuloplasty and atrial/ventricular septal defect closure, except for 2 children with spontaneous healing of the ventricular septal defect. The specific treatment plan depended on the child condition, and 14 of them were treated in the neonatal period.

**Table I.** General information of study subjects.

Indicators	-	Study Subjects
Total cases	-	3,238
Marital status	Married	3,172 (97.96)
-	Unmarried	66 (2.04)
Age (year)	Range	22-35
-	Average	$25.45 \pm 5.45$
Height (cm)	Range	151-173
-	Average	$164.05 \pm 5.85$
Gestational weeks (week)	Range	12-43
-	Average	$25.89 \pm 4.56$
Weight (kg)	Range	58-85
-	Average	$70.61 \pm 10.94$
Years of education (year)	Range	7-16
-	Average	$15.94 \pm 5.21$
Past medical history	Diabetes	456 (14.08)
-	Hypertension	325 (10.04)
-	Other	845 (26.09)

**Table II.** Grading of fetal heart malformations.

Indicators	Study Subjects
Total cases	33
Grade I	5 (15.15)
Grade II	6 (18.18)
Grade III	10 (30.30)
Grade IV	12 (36.36)

**Follow-Up Visits**

The follow-up results of the 18 children who underwent treatment suggested 10 cases of normalization of the heart structure, 7 cases of minor alterations in the heart valves, and 1 case of death (Table IV).

**Discussion**

Heart malformation, also known as “congenital heart disease”, is the most common birth defect, seriously endangering the health and quality of life of children and affecting the quality of health and population<sup>10</sup>. For children with complex heart malformations, if they are discovered to have congenital heart disease after birth, they may present with acute conditions such as severe hypoxia, acidosis, and heart failure at the time of consultation, and the risk of surgery is subsequently increased<sup>11</sup>. With the rapid development of prenatal diagnosis technology in recent years, the medical and surgical treatment of congenital

**Table IV.** Follow-up of the treated children.

Indicators	Study Subjects
Total cases	18
Normalization of heart structure	10 (55.56)
Minor alterations in heart valves	7 (38.89)
Death	1 (5.56)

heart disease has become increasingly mature<sup>12</sup>. With the rapid development of clinical treatments, most congenital heart diseases can be cured after birth and can achieve certain therapeutic effects<sup>13</sup>. Therefore, induction of labor after prenatal diagnosis of congenital heart disease is no longer the only option, and prenatal diagnosis can not only predict postnatal changes in the fetus, but also exclude acute and severe postnatal conditions of complex congenital heart disease<sup>14</sup>.

Although there is some national literature on follow-up studies of patients with prenatally diagnosed congenital heart disease, there is still a lack of large prospective cohort studies of congenital heart disease in the perinatal period. In this study, all pregnant women who were to undergo delivery in our hospital between January 2018 and December 2021 were managed for screening and treatment of fetuses diagnosed with heart malformations, in order to study and analyze its value in the screening and treatment of fetal heart malformations. The results showed that the prenatal-postnatal integrated management model was effective in prenatal screening of pregnant women, with a

**Table III.** Mode of delivery in subjects with fetal heart malformation.

Grading	Mode of delivery	Number of study subjects
Grade I	-	5
-	Natural birth	4 (80.00)
-	Cesarean section	1 (20.00)
-	Induced labor	0 (0.00)
Grade II	-	6
-	Natural birth	3 (50.00)
-	Cesarean section	3 (50.00)
-	Induced labor	0 (0.00)
Grade III	-	10
-	Natural birth	2 (20.00)
-	Cesarean section	6 (60.00)
-	Induced labor	2 (20.00)
Grade IV	-	12
-	Natural birth	0 (0.00)
-	Cesarean section	1 (8.33)
-	Induced labor	11 (91.67)



better prognosis after treatment and definite clinical value. The current situation in our country is that the risk of the existence of congenital heart disease remains high because of the variety and severity of congenital heart disease, which may be accompanied by hereditary diseases and extracardiac malformations complications, etc., and the limited information that families with prenatal diagnosis receive from obstetricians for the treatment of congenital heart disease<sup>15</sup>. In addition, the lack of treatment modalities for prenatal screening in remote and poor areas prevents severe and complex congenital heart disease in children from being cured immediately after birth, leading to unmanageable abandonment rates and mortality in children<sup>16</sup>. The prenatal diagnosis and postnatal treatment of birth defects requires team integration into multiple disciplines, including obstetrics, prenatal diagnosis, neonatology, pediatrics, pediatric surgery and other specialties, making it a systematic project. The diagnosis and treatment of congenital heart disease requires a thorough understanding of cardiac embryogenesis, hemodynamic changes, and treatment modalities to initiate comprehensive management of congenital heart disease from the fetal stage<sup>16</sup>. Over recent years, the prevention and prenatal management of congenital heart disease in the medical and health system has been strengthened, and prenatal screening and diagnosis of fetal congenital heart disease has been gradually implemented nationwide with remarkable results. With the development of society and advances in medical technology, especially in medical imaging and the establishment of interdisciplinary cooperation models, prenatal diagnosis and perinatal management of fetal heart disease are receiving increasing attention from medical professionals. As one of the comprehensive management models, the prenatal-postnatal integrated management model was used in Europe and the United States in the 1990s and includes prenatal and postnatal consultations, diagnosis and combined treatment<sup>17</sup>. The model is highly specialized, contributing to the optimization of medical resources, the improvement of treatment effectiveness, and the protection of medical safety, encompassing interdisciplinary fields and issues, covering the natural history of different prenatal and postnatal diseases, further exploiting the advantages of prenatal diagnosis, and maintaining continuity in the diagnosis and treatment of congenital heart disease from prenatal to postnatal, thus reducing the impact of congenital heart disease on child survival and

growth. The prenatal-postnatal integrated management includes not only the stratified diagnosis of risk factors, prognostic consultation, establishment of green channels, and emergency care and transportation of fetuses after birth, but also the integrated management of related medical resources. By combining prenatal ultrasound with laboratory techniques and pediatric procedures, it has been found<sup>18</sup> that early detection and diagnosis can be achieved in children with congenital structural malformations, raising awareness of congenital heart disease in pregnant women, managing the severity of congenital heart disease and receiving appropriate treatment, and grading management according to the severity of congenital heart disease. For severe malformations, labor can be induced; for some malformations, endometrial fetoscopy or radiofrequency ablation can be performed; postpartum malformations can be treated in combination with pediatric surgery, so as to achieve an integrated prenatal and postpartum management and reduce mortality with timely treatment<sup>19</sup>.

### **Limitations**

There are still some limitations in this study, such as small sample size, lack of diversity, and lack of comparative illustration, resulting in less convincing conclusions, which need to be demonstrated again with the subsequent addition of a research protocol. As prenatal diagnosis technology has developed rapidly, medical and surgical treatment techniques for congenital heart disease are increasingly mature, but the level of prevalence of prenatal diagnosis of complex congenital heart disease is still low compared with that of other developed countries, leaving significant differences. The retention rate of these cases will gradually improve through interdisciplinary consultations as the domestic economy develops and people's perceptions change.

Adhering to the comprehensive management concept of "eugenics", this study organically combined prenatal ultrasound diagnosis, MRI diagnosis with prenatal clinical examination, neonatal surgery, and pediatric surgical treatment etc., to provide early detection, early diagnosis, early intervention, and early treatment of congenital structural malformation diseases with a variety of modern techniques and equipment, in order to reduce the damage caused by congenital structural malformation diseases to the children<sup>20</sup>. Meanwhile, the most suitable intervention plan for puerpera, special examination plan at the later

stage, and precise surgery plan were developed to provide the best treatment for the children in a timely and effective manner, so as to provide the best treatment opportunities for the children from being delayed due to transfer and other links. When severe structural malformations of the fetus are detected during prenatal testing, early intervention can effectively reduce the incidence of birth defects and reduce unnecessary financial and emotional burdens for the majority of families, thus contributing to society and reaping great benefits, both economically and socially.

### Conclusions

The prenatal-postnatal integrated management model is a multidisciplinary cooperation model with certain clinical value in the screening, diagnosis and treatment of fetal heart malformations, which is beneficial to comprehensively improve the ability of hospital physicians in the grading management of heart malformations, detecting fetal heart malformations early and predicting fetal changes after birth. It further reduces the incidence of serious birth defects, conforms to the development trend of the diagnosis and treatment of congenital heart diseases, enables to reduce child mortality with timely treatment, effectively improves the surgical prognosis of critical and complex congenital heart diseases, with a promising application prospect.

### Ethics Approval

This study has been approved by The Fourth Hospital of Shijiazhuang Ethics Committee (No. 5197197). All the methods were carried out in accordance with the Declaration of Helsinki.

### Informed Consent

Patients and their families were informed of the research content and voluntarily signed the informed consent.

### Availability of Data and Materials

All data generated or analyzed during this study are included in this published article.

### Conflict of Interests

The authors declare that they have no competing interests.

### Funding

No funds were received.

### Authors' Contributions

J.-Q. Su, N. Li, J. Duan performed the majority of experiments and designed and coordinated the research; J. Zhang, K.-Y. Liu, C.-X. Sun analyzed the data. All authors reviewed the manuscript. All authors have read and approved the manuscript.

### ORCID ID

Congxin Sun: 0009-0008-7236-9495

### References

- 1) Friedman KG, Tworetzky W. Fetal cardiac interventions: Where do we stand? *Arch Cardiovasc Dis* 2020; 113: 121-128.
- 2) Syngelaki A, Hammami A, Bower S, Zidere V, Akolekar R, Nicolaides KH. Diagnosis of fetal non-chromosomal abnormalities on routine ultrasound examination at 11-13 weeks' gestation. *Ultrasound Obstet Gynecol* 2019; 54: 468-476.
- 3) Wielandner A, Mlczoch E, Prayer D, Berger-Kulemann V. Potential of magnetic resonance for imaging the fetal heart. *Semin Fetal Neonatal Med* 2013; 18: 286-297.
- 4) Watanabe M, Strainic JP. Introduction to "fetal interventions to alleviate heart defects". *Birth Defects Res* 2019; 111: 367-369.
- 5) Turan S, Goetzinger KR. First-trimester fetal heart evaluation: time to move forward. *Ultrasound Obstet Gynecol* 2021; 57: 677-680.
- 6) Tsuritani M, Morita Y, Miyoshi T, Kurosaki K, Yoshimatsu J. Fetal Cardiac Functional Assessment by Fetal Heart Magnetic Resonance Imaging. *J Comput Assist Tomogr* 2019; 43: 104-108.
- 7) Gittenberger-de Groot AC, Bartelings MM, Poelmann RE, Haak MC, Jongbloed MR. Embryology of the heart and its impact on understanding fetal and neonatal heart disease. *Semin Fetal Neonatal Med* 2013; 18: 237-244.
- 8) Cali G, Timor-Tritsch IE, Palacios-Jaraquemada J, Monteaugudo A, Buca D, Forlani F, Familiari A, Scambia G, Acharya G, D'Antonio F. Outcome of Cesarean scar pregnancy managed expectantly: systematic review and meta-analysis. *Ultrasound Obstet Gynecol* 2018; 51: 169-175.
- 9) Tutunji L, Thekrallah F, Basha A, Awaysheh B, Amer S, Khatib L, Hamdan L, Saber N, Mustafa A, Jadallah R, Kazaleh F, Al-Lawama M, Badran E, Al-Ammouri I. Prenatal detection of fetal heart disease at Jordan University Hospital: early experience in a developing country. *Cardiol Young* 2019; 29: 1072-1077.
- 10) Chitra N, Vijayalakshmi IB. Fetal echocardiography for early detection of congenital heart diseases. *J Echocardiogr* 2017; 15: 13-17.
- 11) Minnella GP, Crupano FM, Syngelaki A, Zidere V, Akolekar R, Nicolaides KH. Diagnosis of major heart defects by routine first-trimester ultrasound examination: association with increased nuchal translucency, tricuspid regurgitation and abnormal flow in ductus venosus. *Ultrasound Obstet Gynecol* 2020; 55: 637-644.

- 12) Gardiner HM. Advances in fetal echocardiography. *Semin Fetal Neonatal Med* 2018; 23: 112-118.
- 13) Khalil A, Nicolaides KH. Fetal heart defects: potential and pitfalls of first-trimester detection. *Semin Fetal Neonatal Med* 2013; 18: 251-260.
- 14) Howell HB, Zaccario M, Kazmi SH, Desai P, Sklamberg FE, Mally P. Neurodevelopmental outcomes of children with congenital heart disease: A review. *Curr Probl Pediatr Adolesc Health Care* 2019; 49: 100685.
- 15) Nurmaini S, Rachmatullah MN, Sapitri AI, Darmawahyuni A, Tutuko B, Firdaus F, Partan RU, Bernolian N. Deep Learning-Based Computer-Aided Fetal Echocardiography: Application to Heart Standard View Segmentation for Congenital Heart Defects Detection. *Sensors (Basel)* 2021; 21: 8007.
- 16) Garcia-Canadilla P, Sanchez-Martinez S, Crispi F, Bijns B. Machine Learning in Fetal Cardiology: What to Expect. *Fetal Diagn Ther* 2020; 47: 363-372.
- 17) Ruican D, Petrescu AM, Istrate-Ofițeru AM, Iliescu DG. Postmortem Evaluation of First Trimester Fetal Heart. *Curr Health Sci J* 2022; 48: 247-254.
- 18) Mellick JD, Radford DJ, Galbraith AJ. Fetal echocardiography in the diagnosis of congenital heart disease. *Aust Paediatr J* 1989; 25: 356-360.
- 19) Haberer K, Fruitman D, Power A, Hornberger LK, Eckersley L. Fetal echocardiographic predictors of biventricular circulation in hypoplastic left heart complex. *Ultrasound Obstet Gynecol* 2021; 58: 405-410.
- 20) Fyfe DA, Kline CH. Fetal echocardiographic diagnosis of congenital heart disease. *Pediatr Clin North Am* 1990; 37: 45-67.