

# Laparoscopic pancreaticoduodenectomy for tumors of the head of pancreas; 10 cases for a single center experience

F. CARUSO<sup>1</sup>, G. ALESSANDRI<sup>2</sup>, G. CESANA<sup>1</sup>, G. CASTELLO<sup>1</sup>, M. UCCELLI<sup>1</sup>, F. CICCARESE<sup>1</sup>, R. GIORGI<sup>1</sup>, R. VILLA<sup>1</sup>, B. SCOTTO<sup>1</sup>, S. OLMI<sup>1</sup>

<sup>1</sup>Laparoscopic Unit of Surgical Department of San Marco Hospital, Osio Sotto, Zingonia, BG, Italy

<sup>2</sup>Department of HPB and Transplant Surgery, Freeman Hospital, The Newcastle Upon Tyne Hospitals NHS Foundation Trust, High Heaton, Newcastle Upon Tyne, UK

*Francesco Caruso and Giorgio Alessandri contributed equally to this work*

**Abstract. – OBJECTIVE:** The tumors of the head of the pancreas are one of the leading causes of cancer-related death in Western countries. The current gold standard for these tumors is a Whipple procedure. This procedure did not change in its surgical steps since when it was initially introduced in 1935. More recently, a laparoscopic approach with similar outcomes has been described. The aim of this paper is to describe the laparoscopic surgical technique performed in our unit, reporting single center postoperative outcomes.

**PATIENTS AND METHODS:** From the 1<sup>st</sup> January 2013 to the 31<sup>st</sup> December 2015 a database was created. Data about patients who underwent a laparoscopic pancreaticoduodenectomy (LPD) were collected prospectively. All patients were preoperatively assessed with blood samples, tumor markers, CT chest abdomen and pelvis and/or MRI pancreas. Only patients with specific characteristics were considered eligible for an LPD: performance status 0, body mass index (BMI) less than 30 kg/m<sup>2</sup>, a small neoplastic lesion (< 3.5 cm) confined into the pancreas, the absence of infiltrated organs and/or blood vessels (T1 or T2). Postoperative data and complications were recorded and described according to the Clavien-Dindo classification and the international study group of pancreatic surgery definitions.

**RESULTS:** In a time interval of 36 months, 31 patients with an initially considered resectable pancreatic cancer were referred. 11 patients were found to have metastasis during the preoperative workout. Only 10 patients were considered eligible for a LPD. Six of them were men (60%). The mean BMI was 25.01 kg/m<sup>2</sup> (19.6-29.8). 5 patients, who underwent to LPD did not have any comorbidities. An overall 50% of all patients were jaundice at the time of diagnosis with a mean bilirubin level of 181.3 μmol/L (119.7-307.8). All patients with a direct bilirubin greater than 250 μmol/L underwent a preoperative percutaneous biliary drainage. In the majority of the LPD performed (50%), the histology reported a pancreatic adenocarcinoma. Other postoperative histology described were: IPMN (20%), ampullar neoplasia

(20%) and neuroendocrine tumor (10%). Neo-adjuvant chemotherapy was never considered indicated. The reported postoperative complications were: 1 anastomotic bleeding, 2 pancreatic fistula, 1 infected intra-abdominal collection and 1 delay gastric emptying. The pancreatic fistulas were considered grade A and grade B. One fatality after LPD occurred because of an uncontrollable, diffuse severe hemorrhagic gastritis associated with a GJ anastomosis bleeding in the POD 25. The mean hospital stay was 12.3 days (8-25). The mean operative time was 224 min (170-310). There were no intraoperative complications. The main intraoperative blood loss was 220 ml (180-400) and intraoperative blood transfusions were not required. The resection margins were negative (R0) in 100% of cases and the mean lymph nodes harvested were 24 (18-40). The LPD is still a not common practice. Our results are comparable with those reported in literature about the open technique. These remarkable surgical outcomes are probably related to the extremely careful preoperative patient selection performed. The indication for a laparoscopic vs. an open pancreaticoduodenectomy was based on a CT scan pancreas performed less than 30 days before the planned date of surgery and a careful preoperative assessment. A low complication rate and a relative short stay in hospital were associated to a good quality of life in the early postoperative period and an early referral for postoperative chemotherapy. Good clinical outcomes were associated with outstanding oncological results.

**CONCLUSIONS:** Laparoscopic pancreaticoduodenectomy is a feasible surgical procedure. Remarkable oncological and surgical outcomes can be achieved with a morbidity and mortality rate in line with the data reported by the large series of open procedures.

*Key Words:*

Laparoscopic pancreaticoduodenectomy, Laparoscopic Blumgart, Minimally invasive surgery, Pancreatic cancer.

## Introduction

Pancreatic head tumors are one of the leading causes of cancer related death in Western countries<sup>1</sup>. Most of these tumors are represented by pancreatic ductal adenocarcinomas, which represent the fourth leading cause of cancer mortality in the USA, with more than 30,000 deaths per year<sup>2</sup>. Currently the gold standard of treatment for a pancreatic cancer is surgery. It can be associated with a variety of neo-adjuvant or adjuvant chemotherapy protocols. Surgery represents the only potentially curative option in patients with a resectable cancer. The first pancreaticoduodenectomy (PD) was described by Whipple et al<sup>3</sup> as a “prohibitive” procedure that could be performed safely only by extremely expert surgeons. Several recent reports<sup>4,5</sup> showed a significant reduction of the postoperative morbidity rate when a pancreatic resection is performed in high volume centers. The laparoscopic pancreaticoduodenectomy (LPD) was first described by Gagner and Pomp in 1994<sup>6</sup>. However, the high laparoscopic technical skills required and lack of evidence in clinical advantages compared to the open procedure, prevented a large spread of the technique. To date, LPD is considered a technically challenging operation currently performed only in few laparoscopic specialized units. At the same time, it was showed to be a safe procedure with similar oncological outcome to the open PD (OPD) in well-selected patients<sup>7,8</sup>. The aim of this paper is to describe the laparoscopic surgical technique performed in our unit, reporting single center postoperative outcomes.

## Patients and Methods

From the 1<sup>st</sup> January 2013 to the 31<sup>st</sup> December 2015, a prospectively collected database was arranged. It recorded peri-operative data about all patients who underwent a PD for a tumor in the head of pancreas (HOP). 31 patients with a HOP cancer were referred to our specialist laparoscopic center (Surgical Department of San Marco Tertiary Hospital, Osio Sotto, Zingonia, BG, Italy). Before collecting data an informed consent was stipulated and then approved by the Ethic Committee of the hospital. The obtained consent was discussed with all patients and an extensive explanation about the project was given. All patients agreed to take part in the research. All patients had a thorough pre-operative as-

essment<sup>9</sup>. It included: routine bloods (full blood count, liver functional tests, urea, electrolytes and clothing), tumor markers (CEA, CA 19.9, CA 125) and a staging CT chest-abdomen-pelvis for all patients. A MRI pancreas was performed for cystic lesions. Pre-operative biopsies were carried out by endoscopic ultrasound (EUS) and fine needle aspiration (FNA) or with endoscopic retrograde cholangiography (ERCP) and brushing of the biliary tree. After all these investigations, all patients considered to have a resectable disease underwent a staging laparoscopy to evaluate the presence of peritoneal disease. Among the 31 referred patients, 11 were found to have metastatic disease (liver or peritoneal). In 5 of them the metastatic deposits were identified only with the staging laparoscopy. 10 patients underwent OPD because of the high volume of the tumor (> 3.5 cm) and/or a pre-operative suspicion of vascular involvement. A LPD was performed in 10 cases; all patients presented in good general condition (performance status 0), a body mass index (BMI) < 30 kg/m<sup>2</sup>, with a small neoplastic lesion (< 3.5 cm) confined into the pancreas, without infiltration of other organs and/or blood vessels (T1 or T2).

General postoperative complications were described according to the Clavien-Dindo classification<sup>10</sup>. Postoperative pancreatic leak (PL), delay gastric emptying (DGE) and postoperative hemorrhage (PH), were defined and graded according to the international study group of pancreatic surgery (ISGPF)<sup>11</sup>. The conversion to an open procedure was defined as the necessity to perform a laparotomy at any moment during surgery, with the exception of the incision made to extract the resected specimen.

### ***Surgical Procedure: Laparoscopic Pancreatoduodenectomy***

The day before surgery polyethylene glycol (PEG) solution and simethicone were prescribed to all patients who underwent LPD. These medications were prescribed with the intent of emptying the bowel and reducing the intestinal gas content before surgery. All patients were positioned in Lloyd Davies with a reverse Trendelenburg. A nasogastric tube and urinary catheter were inserted soon after the induction of the general anesthesia. Ceftriaxone (2 g) was given as antibiotic prophylaxis between 30 and 60 min before the skin incision. The procedure started with the induction of pneumoperitoneum using the verses needle. Usually an assessment

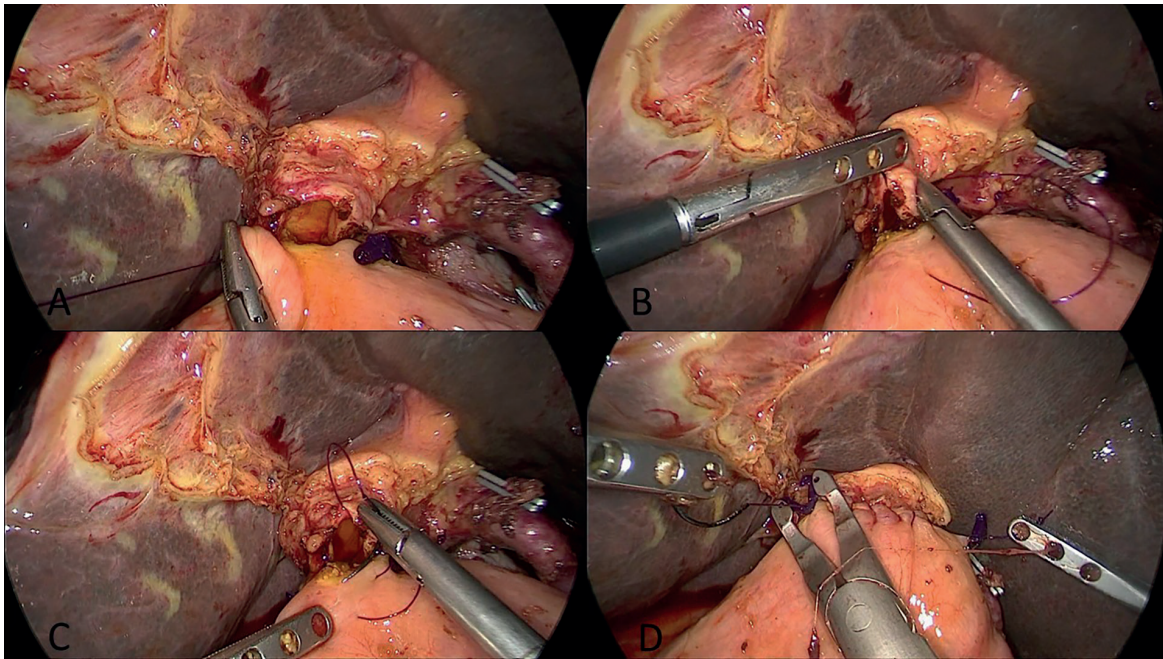
of intraperitoneal adhesions was performed injecting N-saline in the peritoneal cavity with a spinal needle in the area where the first port was placed. The first port was usually inserted by the mean of an optical trocar. The position and number of trocars were a key step of the procedure. A 10 mm optical trocar was inserted on the mid-line, 2 cm below the umbilicus. Four other ports were put under direct vision: a 5 mm trocar in epigastrium, one (5 mm) in left upper quadrant (LUQ), one (5 mm) in the right flank (RF) and one 12 mm trocar in left flank (LF). A 30-degree lens was used for the optic system. Ports in the LUQ and RF were mainly used by the operator, the others by the assistant for retraction. After the introduction of the first port, a careful assessment of the peritoneal cavity and the liver was performed to rule out any metastasis. If there was any concern about a new finding, biopsy and frozen section were performed. After this first step, the lesser sac was opened resecting the gastrocolic ligament with the radiofrequency knife (LigaSure™ Maryland, Medtronic, Parkway, MN, USA). The left gastroepiploic vessels were preserved, whereas the right ones were clipped and cut with the ligasure. The common hepatic artery (CHA) was then isolated removing the lymph nodes usually located around the artery (station 8a lymphadenectomy). The gastroduodenal artery (GDA) was isolated, clipped (2 endo-clips were usually left on the GDA stump) and cut. This step of the procedure cleared the anterior surface of the portal vein (PV) just above the neck of the pancreas. The Cattell and an extended Kocher maneuver were performed until the left renal vein (RV) and the origin of the superior mesenteric artery (SMA) were clearly recognized and exposed. Next, the anterior surface of the superior mesenteric vein (SMV) was dissected free. This was performed until the inferior margin of the neck of the pancreas, preserving the middle colic vein (MCV). A tunnel was created behind the neck of the pancreas, anteriorly to the SMV and the PV. A fundus first cholecystectomy and a lymphadenectomy of the hepatic pedicle (stations 12a and 12c) were then accomplished. The common hepatic duct (CHD) was cut just above the insertion of the cystic duct (CD) with scissors. The stomach was then resected at the level of the antrum (Van Goethem line) with a laparoscopic stapler (EndoGia 60, purple cartridge, Medtronic, Parkway, MN, USA). The pancreas was transected on the medial side of the SMV with the ligasure. The

first jejunal loop was prepared and cut with a stapler (EndoGia 60, purple cartridge, Medtronic, Parkway, MN, USA). The mesentery was resected along the bowel margin with the ligasure. The Treitz ligament was cut. The duodenum and the first jejunal loop were retracted laterally to the SMV with a grasper introduced from the port in the RF. The retroportal lamina was resected with the ligasure and the specimen put in an endobag and left above the liver. The haemostasis was checked. A single trans-mesocolic jejunal loop was pooled into the sovra-mesocolic compartment for the hepaticojejunostomy (HJ) and the pancreaticojejunostomy (PJ). The HJ (Figure 1) was obtained first. It was a single layer, end to side anastomosis, performed with two running sutures in PDS 3/0, one for the posterior wall and the second for the anterior wall of the CHD. The PJ (Figure 2) was a ducto-mucosal anastomosis (Blumgart). A 7 Fr stent (Bracci) was usually introduced into the main pancreatic duct to facilitate the anastomosis and it was left there. It was a single layer, end to side anastomosis operated by 5/0 PDS interrupted stitches. A second ante-colic jejunal loop was pooled up to the stomach to perform a side-to-side gastrojejunostomy (GJ). It was operated with an endo-stapler (EndoGia 60, purple cartridge, Medtronic, Parkway, MN, USA) on the anterior wall of the stomach. During this step of the procedure, a naso-jejunal (NJ) feeding tube was carefully introduced by the anesthetist into the stomach and it was guided by the surgeon into the lumen of the efferent jejunal loop. To an abundant washout of the abdominal cavity and a check of all anastomosis were performed. The specimen was retrieved by endobag from a small epigastric incision, and two Jackson-Pratt drains were positioned; one was left in the RF, posterior to the HJ, and the other was carefully located in the LF, nearby the PJ.

#### ***Postoperative Recovery Protocol***

The patient started to eat and drink postoperative day (POD) 1. An enteral feeding by NJ tube was prescribed to support the patient from the POD 1. All patients had an early mobilization and were encouraged to accomplish specific exercise from the POD 1. The POD 1, POD 3, POD 5, and the level of the amylase were checked in the drain fluid. If there was no concern about a possible bile or pancreatic leak, the right side abdominal drain was removed on POD 3. The drain on the left side was taken away on POD 6 if the drain amylase was negative on POD 5.



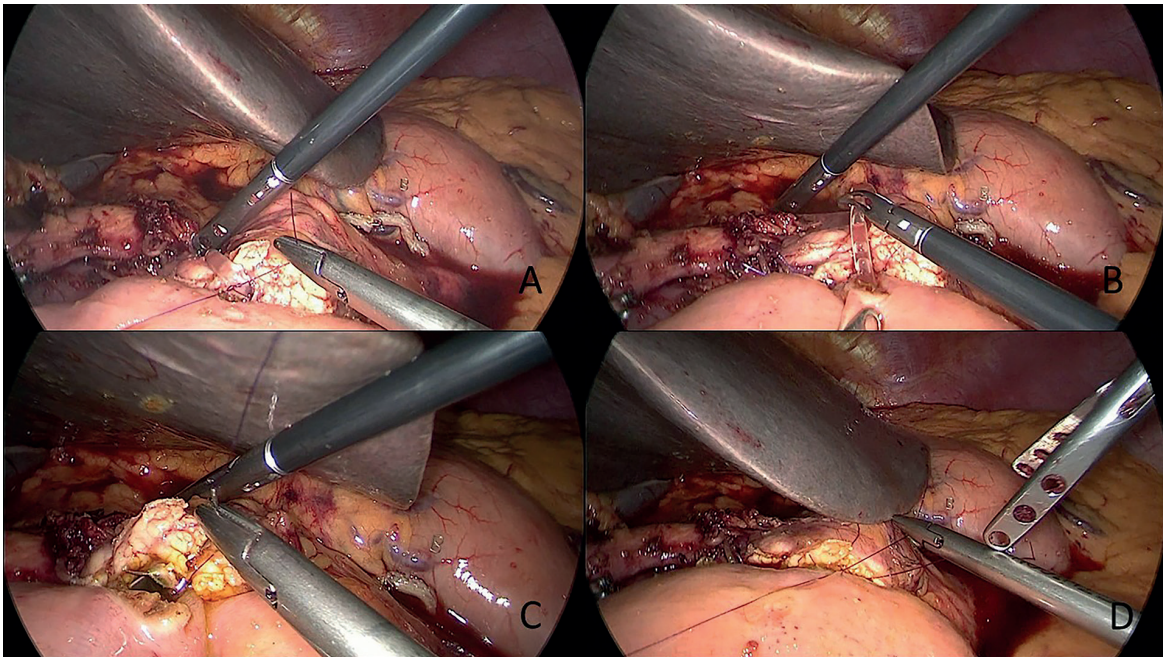


**Figure 1.** End to side laparoscopic hepaticojejunostomy with a continuous running suture in single layer 3/0 PDS. **A**, The suture of the posterior wall of the anastomosis is performed first. **B**, and **C**, The suture of the anterior wall is performed then. **D**, PDS Agraphes placed on the stitch and anastomosis accomplished.

### **Statistical Analysis**

Data were reported with the mean, to give a measure of the central tendency of the sample. The median was used when discrete data were not

represented appropriately by the mean. The range of the sample was reported to describe the deviation from the central tendency. Percentages were calculated to clarify the portion of the whole set of



**Figure 2.** Laparoscopic ducto-mucosal pancreaticojejunostomy (Blumgart), end to side on a 7 Fr Bracci stent, performed with interrupted stitches of 5/0 PDS. **A**, The suture of the posterior wall of the Main Pancreatic Duct is facilitated by the use of the stent. **B**, Bracci stent placed in the jejunum. **C**, Anterior wall of the anastomosis. **D**, Anastomosis accomplished.

data taken into consideration and to allow a comparison with outcomes of other centers. In view of the small sample considered in this paper, comparisons between groups were not performed, so more complex statistical calculators were not used.

## Results

From the 1<sup>st</sup> of January 2013 to the 31<sup>st</sup> of December 2015, 10 patients underwent a LPD at the Specialized Laparoscopic Unit of San Marco Tertiary Center Hospital (Zingonia, Osio Sotto, BG, Italy). All patients had a pancreatic head cancer. From the definitive postoperative histology reports, the most common cancer was an adenocarcinoma of the main pancreatic duct (MPD) (5 cases). Data on histology and size of the tumor are summarized in Table I. The mean age of all patients underwent LPD was 63.6 years (range 42-75) with an average Body Mass Index (BMI) of 25.01 kg/m<sup>2</sup> (range 19.6-29.8). 5 patients presented obstructed jaundice before surgery; the medium levels of conjugated bilirubin were 181.3 µmol/L (ranging from 119.7 to 307.8). Only one patient underwent percutaneous trans-hepatic internal-external drainage (PTC) before surgery; his direct bilirubin was 307.8 µmol/L. According to the Local Guidelines of our Surgical Unit a preoperative biliary drainage is indicated in all patients with an obstructive jaundice and direct bilirubin greater than 250 µmol/L. The biliary drainage is usually

performed percutaneously by the mean of a PTC. The PD is performed when the bilirubin drops below 170 µmol/L. All LPD were accomplished by the same surgeon with a standard surgical technique (described above). Intraoperative data are summarized in Table II. The mean operative time was 224 (170-310) min. All procedures were completed laparoscopically. No additional trocars were necessary to finish the procedures. No intraoperative complications were recorded. The average blood loss was 220 ml (180-400). No intraoperative transfusions were given. R0 resections were accomplished in 100% of cases. The average number of lymph nodes in the specimen was 24 (20-40). Vascular resections were not performed in any laparoscopic case. The 90 days postoperative mortality was 10% and it was accounting for a single patient who experienced severe acute hemorrhagic gastritis in the POD 25. This patient developed a delay gastric emptying (DGE) after surgery. The nasogastric (NG) tube was left in situ persistently after surgery until POD 20. The drain amylase in POD 1, 3 and 5 were always negative. Drains were removed in POD 10 after a CT abdomen and pelvis that did not show any postoperative complication. The CT was arranged due to a concern about a possible not detected pancreatic fistula (PF) causing the DGE<sup>12</sup>. The patient so was managed conservatively with TPN and a NG tube on free drainage for the following 10 days. The patient showed a gradual improvement of the NG output and the NG was removed POD 20 as

**Table I.** Preoperative patients data.

Patient data and diagnoses	Results
Age, years (range)	63.6 (42-75)
Sex	
– M, n (%)	6 (60%)
– F, n (%)	4 (40%)
Mean BMI, kg/m <sup>2</sup> (range)	25.01 (19.6-29.8)
Preoperative jaundice, n (%)	5 (50%)
– Bilirubin level, µmol/L (range)	181.3 (119.7-307.8)
– Preoperative biliary drainage, n (%)	1 (10%)
– Waiting after biliary drainage, week	2
– Bilirubina level after biliary drainage, µmol/L	136.8
Comorbidity	
– Cardiovascular diseases, n (%)	3 (30%)
– Type II Diabetes, n (%)	2 (20%)
Tumor dimension, cm (range)	3.1 (1.8-3.5)
Tumor Type	
– Head adenocarcinoma, n (%)	5 (50%)
– IPMN, n (%)	2 (20%)
– Ampullar neoplasia, n (%)	2 (20%)
– NET, n (%)	1 (10%)
Neoadjuvant therapy, n (%)	0 (0%)



**Table II.** Intraoperative data.

Operative and oncologic variables	Results
Operative time, min (range)	224 (170-310)
Number of trocars, n (% of cases)	5 (100%)
Open conversion, n (%)	0 (0%)
Intraoperative morbidity, n (%)	0 (0%)
R0 resections, n (%)	10 (100%)
Mean lymphnodes number, n (range)	24 (18-40)
Vascular resections, n (%)	0 (0%)
Intraoperative blood loss, ml (range)	220 (180-400)
Intraoperative transfusions, n (%)	0 (0%)

the output was 200 ml per 24 hours. The patient stayed in hospital for a poor nutritional status until POD 24 when he had 2 episode of coffee-ground vomiting followed by a sudden cardio-pulmonary arrest. He was resuscitated for 30 min. The patient had blood transfusions and a CT angiogram scan was performed. It showed a considerable amount of blood in the stomach without a specific source of bleeding. An emergency endoscopy was performed and it described a diffuse severe hemorrhagic gastritis associated with a GJ anastomosis bleeding. The GJ bleeding was stopped with Adrenaline injection and clips application. A continuous infusion of proton pump inhibitors (PPI) and tranexamic acid were given, however the clothing profile was only minimally deranged (pT 15). The decision of not performing any emergency gastrectomy was taken in the light of the very poor condition of the patient. The bleeding stopped as demonstrated by the stabilization of hemoglobin after the blood transfusions. The patient died POD 25 for multi-organ failure as consequence of the cardiopulmonary arrest. The overall postoperative complication rate was 40%; 2 patients developed a pancreatic fistula. One of them was a grade A

who required a prolonged stay of the surgical drains (12 days) but not medical treatment was necessary. The second one was a grade B fistula. One patient developed postoperative sepsis due to an intra-abdominal collection. In this occasion a percutaneous drain was placed after surgery, none amylase or bilirubin rich fluids were isolated from the collection. The patient was treated with intravenous antibiotic for 15 days. None postoperative wound infection was detected. Only one patient developed a delayed gastric emptying. The mean length of the postoperative in hospital stay was 12.3 days (range 8-25). The mean postoperative follow up was 9 months. All postoperative results are summarized in Table III.

### Discussion

It has already been documented as the prevalence of the pancreatic tumors is recently increased<sup>1</sup>. This is probably related to an improvement of the quality of the diagnostic techniques available to investigate the pancreas. However not all pancreatic tumors are amenable of sur-

**Table III.** Postoperative complications and length of hospital stay.

Postoperative complications	Results
Postoperative morbidity	
– Anastomotic Bleeding, n (%)	1 (10% – cause of mortality)
– Pancreatic fistula, n (%)	2 (20%)
– Infected abdominal collection, n (%)	1 (10%)
– Delayed gastric emptying, n (%)	1 (10%)
– Wound infection, n (%)	0 (0%)
Pancreatic fistula	
• Grade A, n (%)	1
• Grade B, n (%)	1
• Grade C, n (%)	0
Clavien-Dindo grade III-IV, n (%)	2 (2%)
90-day mortality, n (%)	1 (10%)
Length of hospital stay, days (range)	12,3 (8-25)

gical treatment<sup>13-16</sup>. Pancreatic ductal adenocarcinoma is the most common histology among cancers of the head of pancreas and it represents the fourth cause of death for cancer in the US<sup>2</sup>. Surgery is the only therapeutic option that can give the possibility of a curative treatment to a patient with pancreatic cancer<sup>1,3</sup>. It has to be performed with a radical intent and it can be associated with different protocols of adjuvant or neo-adjuvant chemotherapy<sup>2,4,5</sup>. Patient selection is crucial to avoid unnecessary procedures with a poor oncological or surgical outcome<sup>7,8</sup>. Although the remarkable improvement of the cross section imaging, the thorough preoperative assessment and the development of new postoperative enhanced recovery protocols (ERAS), the PD has still a considerable complication rate. The overall complication rate of the PD is reported between 30 and 60%<sup>17,18</sup>. Equally the 90 days postoperative mortality rate is between 1 and 17%<sup>19,20</sup>. LPD was first described by Gagner and Pomp in 1994<sup>6</sup>. However it is still currently performed selectively only in few HPB centers; this is because of the technical challenging aspect of this procedure. Up to date there are no prospective randomized studies comparing LPD and OPD. However many evidences were collected to demonstrate the feasibility and safety of the laparoscopic surgical procedure. Boggi et al<sup>7</sup> published a review, which reported the LPD as a feasible and safe surgical technique in well-selected patients. These findings were confirmed by Liao et al<sup>21</sup> who highlighted the good postoperative surgical and oncological results. A retrospective study was conducted by Adam et al<sup>22</sup>. It included 11,464 patients who underwent pancreatic resection for cancer in the United States (USA). All procedures were performed between 2010 and 2011. Pancreaticoduodenectomies were performed in 7061 cases; 983 patients (14%) underwent a LPD and 6078 (86%) received an OPD. In the first group of patients, who had a laparoscopic procedure, it was reported a conversion rate to open surgery of 30% (n = 294). In the 2 years interval (from 2010 to 2011) the number of operations performed by laparoscopic technique increased by 45%. 402 LPDs were performed in 2010 and 581 in 2011 ( $p < 0.01$ ). The 983 LPDs were accomplished in 246 American hospitals. The number of procedures performed in each center ranged from 1 to 81. In 92% of cases (226 hospitals) less than 10 laparoscopic procedures were performed over the period of 2 years. In 50% of hospitals (123

only one minimally invasive procedure was operated. The study reported an overall 30 days postoperative mortality rate of 4.8% after LPD, compared to the 3.7% of the OPD ( $p = 0.11$ ). Similar results were obtained comparing the two techniques performed in patient with a diagnosis of pancreatic cancer ( $p = 0.10$ ). There were no statistically significant differences between the laparoscopic and the open procedure in terms of number of lymph nodes removed ( $p = 0.27$ ), positive resection margins ( $p = 0.11$ ), in hospital length of stay ( $p = 0.60$ ), 30 days readmissions rate ( $p = 0.85$ )<sup>22</sup>. This American retrospective study showed an increasing interest towards the LPD, which was documented to have remarkable surgical and oncological results. From the 1<sup>st</sup> of January 2013 to the 31<sup>st</sup> of December 2015, we prospectively collected data from 10 patients who underwent LPD for a tumor of the head of pancreas. Surgical procedures were performed by a single operator with more than 10 years' experience in laparoscopic and pancreatic surgery. The mean operative time was 224 min (170-310 min). There were no intraoperative complications. None of the procedures were converted to open, and the mean total blood loss was 220 ml (180-400 ml). Data reported in literature about LPD described a conversion rate from laparoscopic to open of 30%<sup>22</sup> and a mean operative time of 464.3 min<sup>7</sup>. Our remarkable surgical outcomes are probably related to the extremely careful preoperative patient selection performed in our center. The preoperative CT scan pancreas was performed less than 30 days before the planned date of surgery. The LPD was indicated if the CT showed no evidence of vascular involvement, no extra-pancreatic extension into surrounding organs or tissues (T1 or T2) and small diameter of the pancreatic tumor (less than 3 cm). In our series there was one case of death, accounting for a 90 days mortality rate of 10%; the patient had a history of severe high blood pressure and type 1 diabetes with a new onset of obstructive jaundice. After a thorough preoperative assessment, he was found to have a ductal adenocarcinoma of the head of pancreas. The patient developed an uncontrollable, diffuse severe hemorrhagic gastritis associated with a GJ anastomosis bleeding in the POD 24 that was considered as the first cause of his death. Interestingly the patient was on PPI therapy since POD 1 (20 mg once a day). The postoperative morbidity rate documented in our series (Table III) was accounting for 30%

(Clavien Dindo grade III and IV complication rate was accounting for 20%). Two patients developed pancreatic fistula. One of them required no further medical treatment but the surgical drains were left in place until POD 12 (Grade A). The second patient was treated with subcutaneous Octreotide and parenteral nutrition (TPN) until the resolution of the pancreatic fistula (Grade B). One patient developed postoperative sepsis and a CT abdomen showed an abdominal collection. It was drained percutaneously and the patient had a full course of intravenous antibiotic therapy. The fluid isolated from the abdominal collection was found to be neither amylase nor bilirubin rich. In our series there was one case of DGE however there were not cases of bile leakage neither wound infection. The remarkable postoperative surgical outcomes recorded in our cases were associated with good standard oncological resections (Table II). All LPD were concluded with a histology report confirming no involvement of margins of the specimen (R0). An adequate lymphadenectomy was performed in all LPD, describing a mean of 24 (18-40) lymph nodes harvested in each procedure. All these results are comparable with those reported in literature for the laparoscopic and open technique<sup>7,8,13</sup>. The mean length of hospital stay was 12.3 days (ranging between 8 and 25 days). Taking into consideration the results of the reported literature the laparoscopic procedure is associated with a shorter length of hospital stay, a lower occurrence of delayed gastric emptying (DGE) and a smaller rate of surgical wound infections. These factors are responsible for an early postoperative recovery that can be associated with an improvement of the postoperative quality of life and an earlier administration of adjuvant therapy. Croome et al<sup>8</sup> recently showed an improvement of the progression-free survival of patients who underwent a LPD. This was considered to be mainly related to an early course of postoperative chemotherapy offered to the patients who had a laparoscopic operation. The considerations expressed in this paper explain the general increasing interest into the LPD, which is associated to outstanding surgical and oncological outcomes, similar to those of the open procedure.

### Conclusions

Laparoscopic pancreaticoduodenectomy is a feasible surgical procedure. The results reported

by our case series agree with data reported in literature. Remarkable oncological and surgical outcomes can be achieved. The postoperative complication and 90 days mortality rates are similar to those of large series of open procedures. The length of in hospital stay can be drastically reduced by a laparoscopic procedure, improving the quality of life of the early postoperative recovery in patients who usually have a poor prognosis. Laparoscopic surgery enables a fast recovery and decreases the risk of complications, which are usually related to a prolonged admission (such as wound infection, hospital acquired pneumonia and urinary tract infection). An early discharge can expedite adjuvant chemotherapy, which has been showed to influence the prognosis. This paper presents a case series of a single center as preliminary outcomes of an increasing surgical activity that is becoming more common among different laparoscopic and HPB surgical units.

### Conflict of Interest

The Authors declare that they have no conflict of interests.

### References

- 1) VINCENT A, HERMAN J, SCHULICK R, HRUBAN RH, GOGGINS M. Pancreatic cancer. *Lancet* 2011; 378: 607-620.
- 2) YEO CJ, CAMERON JL. Prognostic factors in ductal pancreatic cancer. *Langenbeck Arch Surg* 1998; 383: 129-133.
- 3) WHIPPLE AO, PARSONS WB, MULLINS CR. Treatment of carcinoma of the ampulla of Vater. *Ann Surg* 1935; 102: 763-779.
- 4) VAN HECK NT, KUHLMANN KF, SCHOLTEN RJ, DE CASTRO SM, BUSCH OR, VAN GULIK TM, OBERTOP H, GOUMA DJ. Hospital volume and mortality after pancreatic resection: a systematic review and an evaluation of intervention in the Netherlands. *Ann Surg* 2005; 242: 781-788.
- 5) SCHMIDT CM, TURRINI O, PARIKH P, HOUSE MG, ZYROMSKI NJ, NAKEEB A, HOWARD TJ, PITT HA, LILLEMORIE KD. Effect of hospital volume, surgeon experience, and surgeon volume on patient outcomes after pancreaticoduodenectomy: a single-institution experience. *Arch Surg* 2010; 145: 634-640.
- 6) GAGNER M, POMP A. Laparoscopic pylorus-preserving pancreaticoduodenectomy. *Surg Endosc* 1994; 8: 408-410.
- 7) BOGGI U, AMORESE G, VISTOLI F, CANIGLIA F, DE LIO N, PERRONE V, BARBARELLO L, BELLUOMINI M, SIGNORI S, MOSCA F. Laparoscopic pancreaticoduodenectomy: a systematic literature review. *Surg Endosc* 2015; 29: 9-23.



- 8) CROOME KP, FARNELL MB, QUE FG, REID-LOMBARDO KM, TRUTY MJ, NAGORNEY DM, KENDRICK ML. Total laparoscopic pancreaticoduodenectomy for pancreatic ductal adenocarcinoma: oncologic advantages over open approaches? *Ann Surg* 2014; 260: 633-638.
- 9) LATERZA L, SCALDAFERRI F, BRUNO G, AGNES A, BOŠKOSKI I, IANIRO G, GERARDI V, OJETTI V, ALFIERI S, GASBARRINI A. Pancreatic function assessment. *Eur Rev Med Pharmacol Sci* 2013; 17: 65-71.
- 10) DINDO D, DEMARTINES N, CLAVIEN PA. Classification of surgical complications: a new proposal with evaluation in a cohort of 6336 patients and results of a survey. *Ann Surg* 2004; 240: 205-213.
- 11) BASSI C, DERVENIS C, BUTTURINI G, FINGERHUT A, YEO C, IZBICKI J, NEOPTOLEMOS J, SARR M, TRAVERSO W, BUCHLER M. International Study Group on Pancreatic Fistula Definition. *Surgery* 2005; 138: 8-13.
- 12) BENTIVEGNA F, CORTESE V, BENTIVEGNA S, CARDI F, DI MATTIA P, BARBERA G, BORZI AM, ZANGHI G. Treatment of the pancreatic stump after DCP. *Eur Rev Med Pharmacol Sci* 2014; 18: 36-39.
- 13) DI CATALDO A, PALMUCCI S, LATINO R, TROMBATORE C, CAPPELLO G, AMICO A, LA GRECA G, PETRILLO G. Cystic pancreatic tumors: should we resect all of them? *Eur Rev Med Pharmacol Sci* 2014; 18: 16-23.
- 14) CENTONZE DC, CINARDI N, GIANNONE G. Surgical resection for neuroendocrine tumors of the pancreas: a fourteen years single institutional observation. *Eur Rev Med Pharmacol Sci* 2014; 18: 32-35.
- 15) PAGLIARI D, SAVIANO A, SERRICCHIO ML, DAL LAGO AA, BRIZI MG, LANZA F, MANFREDI R, GASBARRINI A, ATTILI F. Uptodate in the assessment and management of intraductal papillary mucinous neoplasms of the pancreas. *Eur Rev Med Pharmacol Sci* 2017; 21: 2858-2874.
- 16) YUAN TW, LIU HQ, WANG SB, CAO J. Comparison of plastic stents with self-expandable metal stents in palliative treatment of malignant biliary obstruction: a meta-analysis. *Eur Rev Med Pharmacol Sci* 2017; 21: 2847-2857.
- 17) HU BY, WAN T, ZHANG WZ, DONG JH. Risk factors for postoperative pancreatic fistula: Analysis of 539 successive cases of pancreaticoduodenectomy. *World J Gastroenterol* 2016; 22: 7797-7805.
- 18) BERTENS KA, CROWN A, CLANTON J, ALEMI F, ALSEIDI AA, BIEHL T, HELTON WS, ROCHA FG. What is a better predictor of clinically relevant postoperative pancreatic fistula (CR-POPF) following pancreaticoduodenectomy (PD): postoperative day one drain amylase (POD1DA) or the fistula risk score (FRS)? *HPB (Oxford)* 2017; 19: 75-81.
- 19) CAMERON JL, RIALI TS, COLEMAN J, BELCHER KA. One thousand consecutive pancreaticoduodenectomies. *Ann Surg* 2006; 244: 10-15.
- 20) HYDER O, DODSON RM, NATHAN H, SCHNEIDER EB, WEISS MJ, CAMERON JL, CHOTI MA, MAKARY MA, HIROSE K, WOLFGANG CL, HERMAN JM, PAWLIK TM. Influence of patient, physician, and hospital factors on 30-day readmission following pancreatoduodenectomy in the United States. *JAMA Surg* 2013; 148: 1095-1102.
- 21) LIAO CH, WU YT, LIU YY, WANG SY, KANG SC, YEH CN, YEH TS. Systemic review of the feasibility and advantage of minimally invasive pancreaticoduodenectomy. *World J Surg* 2016; 40: 1218-1225.
- 22) ADAM MA, CHOUDHURY K, DINAN MA, REED SD, SCHERI RP, BLAZER DG 3RD, ROMAN SA, SOSA JA. Minimally invasive versus open pancreaticoduodenectomy for cancer: practice patterns and short-term outcomes among 7061 patients. *Ann Surg* 2015; 262: 372-377.