

Dexmedetomidine alleviates vacuolization and necrosis in tubular epithelial cells induced by aortic cross-clamping

S. ERGENE¹, D. HEMSINLI¹, S.O. KARAKISI¹, L. TUMKAYA²,
T. MERCANTEPE², A. YILMAZ³

¹Department of Cardiovascular Surgery, Faculty of Medicine, Recep Tayyip Erdogan University, Rize, Turkey

²Department of Histology and Embryology, Faculty of Medicine, Recep Tayyip Erdogan University, Rize, Turkey

³Department of Medical Biochemistry, Faculty of Medicine, Recep Tayyip Erdogan University, Rize, Turkey

Abstract. – OBJECTIVE: Acute kidney injury (AKI) is one of the main causes of mortality in patients undergoing emergency surgery due to an abdominal aortic aneurysm. This study aimed to determine the potential nephroprotective characteristics of dexmedetomidine (DMD) for the establishment of a standard therapeutic method for AKI.

MATERIALS AND METHODS: Thirty Sprague Dawley rats were allocated to 4 groups: control, sham, ischemia-reperfusion, and ischemia/reperfusion (I/R)+dexmedetomidine.

RESULTS: Necrotic tubules, degenerative Bowman's capsule and vascular congestion were observed in the I/R group. In addition, there was an increase in tissue malondialdehyde (MDA), interleukin (IL)-1 and IL-6 levels in tubular epithelial cells. In contrast, we observed decreased tubular necrosis, IL-1, IL-6 and MDA levels in the DMD treatment group.

CONCLUSIONS: DMD has a nephroprotective effect against acute kidney injury resulting from I/R, which is related to aortic occlusion used in the treatment of ruptured abdominal aortic aneurysms.

Key Words:

Acute kidney injury, Dexmedetomidine, Oxidative stress, Ruptured abdominal aortic aneurysms.

Introduction

Despite all the advances made in the treatment and follow-up of the ruptured abdominal aortic aneurysm (rAAA), no noteworthy improvement has been achieved in mortality rates, which are 53.1% and 65.9% in the UK and USA, respec-

tively¹. Acute kidney injury (AKI) is one of the main causes of mortality in patients undergoing emergency surgery due to rAAA^{2,3-6}.

Prolonged lower extremity ischemia, during the treatment of rAAA and subsequent reperfusion injury associated with revascularization, affect numerous organs including the lower extremities and kidneys. Mechanisms such as hypoxia, reactive oxygen species (ROS), and intensive release of systemic inflammatory mediators play a role in the pathophysiology of this condition, known as a pyonephrosis-metabolic syndrome⁴⁻⁶. AKI developing perioperatively in patients undergoing rAAA repair is one of the most important problems that cardiovascular surgeons⁴ have to face. Studies² have identified postoperative renal replacement therapy as an independent risk factor for rAAA-related death rates. AKI requiring renal replacement therapy following rAAA surgery is a marker of poor prognosis, with a 38-100% mortality rate³. Although several surgical and pharmacological methods have been developed for preserving renal perfusion and preventing AKI in rAAA patients and establishing optimal hemodynamic conditions, the problem has not been resolved³⁻⁵.

Various substances have been investigated^{7,8} to reduce AKI following rAAA surgery in recent years. However, further pharmacological and clinical studies are needed for their clinical use. Dexmedetomidine (DMD), widely used in intensive care patients in the postoperative period, is a selective α -2 adrenoreceptor agonist capable of providing sedation, analgesia and hemodynamic stabilization with minimal respiratory

depression. Its renoprotective effects have been shown in animal experiments⁹⁻¹¹. The present study, modeled by attaching a cross-clamp to the abdominal aorta of rats, focused on the effects of DMD on AKI developing after rAAA surgery.

Materials and Methods

The study was performed with the approval of the University Experimental Animals' Ethical Committee (Approval Number: 2017-23). Thirty male Sprague-Dawley rats (mean weight 256±37 g) were randomly assigned into four groups.

Control, DMD, ischemia/reperfusion (I/R), and I/R+DMD groups were established. The rats were given standard chow (Bayramoglu, Erzurum, Turkey) in polyethylene containers and tap water. Their living conditions were compatible with the Guide for the Care and Use of Laboratory Animals criteria.

Ischemia/Reperfusion Protocol

A previously established rAAA model^{7,8,12-14} for studying distant organ I/R injury in rats was employed. The rats received 10 mg/kg xylazine hydrochloride (Alfazyne[®], Alfasan International B.V., Woerden, Netherlands) and 50 mg/kg ketamine hydrochloride (Ketalar[®], Eczacıbaşı Parke-Davis, Istanbul, Turkey) intraperitoneally (ip) to maintain respiration. The rats were then fixed in the surgical position using a heating lamp to maintain their body temperature. Monitoring procedures for vital signs including mean arterial pressure (MAP), vascular cannulation procedures for blood collection, and volume replacement were performed according to reference studies^{7,8,13,14}.

The rats from the control group were subjected to monitoring and cannulation under anesthesia. No procedure apart from aortic exploration was performed on these animals. After four hours, the abdominal incisions of the control group were closed. Hypovolemic shock due to acute loss of intravascular volume in patients with rAAA was first simulated in the DMD, I/R, and I/R+DMD groups. For that purpose, blood was collected from the intricate inserted in the carotid using an injector containing 500 IU heparin (Nevparin, 5,000 U/mL, Mustafa Nevzat, Turkey) in such a way as not to compromise the hemodynamics. The rats were thus exposed to hypovolemic shock by maintaining MAP ≤50 mm Hg for one hour. Hemodynamic stabilization was then achieved with the application of

a cross-clamp to the abdominal aorta for one hour, and the ischemic process in which the aorta was repaired was simulated. For that purpose, the abdominal aorta was accessed using a retroperitoneal approach following an abdominal midline incision. After systemic heparinization (250 IU intravenous heparin), two bulldog clamps were attached to the abdominal aorta below the renal arteries and above the iliac arteries. The rats in the DMD and I/R+DMD groups received 100 µg/kg DMD in 2 mL saline solution ip half an hour before the installation of the bulldog clamps. Rats in the I/R group received only an equivalent amount of saline solution ip¹⁴. At this stage, the blood stored at room temperature in the heparin syringe was returned to the animal. At the end of one hour of ischemia, the bulldog clamps were released, and the abdominal incisions were closed. In the final two hours, the reperfusion phase was simulated, when the cross clamps were removed, and systemic circulation was restored in the infrarenal abdominal aorta. The isotonic solution was given when required to ensure that MAP remained at approximately 100 mmHg^{7,8,12-14}. The rats were sacrificed by draining systemic blood from the carotid artery.

Biochemical Analysis

The rat kidney was first washed in phosphate buffer. 50% w/w cold phosphate buffer was then added to the kidney tissues. The tissue was homogenized for 1 min at 30 Hertz, centrifuged at 3,000 g/15 min at +4°C, and the resultant supernatant was used for biochemical analyses^{7,8,14}.

Tissue MDA and Thiol Measurement

Malondialdehyde (MDA), the final product of lipid peroxidation, was measured using the method described by Draper and Hadley¹⁵. Thiol levels were determined spectrophotometrically by measuring the color formed by the free sulfhydryl groups in the tissue homogenate with the Ellman reagent¹⁶.

Histopathological Analysis

The rat kidney tissues were fixed in 10% formalin (Sigma Aldrich, St. Louis, MO, USA) for 24 h. Routine histological procedures were then applied. The tissues were dehydrated by exposing to increasing ethanol series (Merck GmbH, Darmstadt, Germany) using a tissue processing device (Shandon Citadel 2000, Thermo Scientific Inc., Braunschweig, Germany). They were then cleared in two series of xylol solutions (Merck, Darmstadt, Germany) and embedded in hard and soft paraffin for embedding in paraffin blocks (Merck GmbH,

Table I. Renal Pathological Damage Score (RPDS).

Grade	Findings
Tubular necrosis score (Sung et al¹⁹)	
0	> 5%
1	6-25%
2	26-50%
3	≥ 50%
Proximal tubule brush border loss	
0	> 5%
1	6-25%
2	26-50%
3	≥ 50%
Vascular congestion	
0	> 5%
1	6-25%
2	26-50%
3	≥ 50%
Atypical glomeruli	
0	> 5%
1	6-25%
2	26-50%
3	≥ 50%

Darmstadt, Germany). 2-3 µm sections were taken from these paraffin blocks using a rotary microtome (Leica RM2525, Leica Biosystems, Nußloch, Germany). The tissues were finally stained with Harris hematoxylin (Merck, Darmstadt, Germany) and eosin G (Merck, Darmstadt, Germany) using a histological staining device (Leica Biosystems, 5020ST, Nußloch, Germany).

Immunohistochemical Analysis

Primary murine antibodies for interleukin-1 (IL-1, E-AB-40454, Elabscience, Houston, TX, USA) and interleukin-6 (IL-6, E-AB-65802, Elabscience, Houston, TX, USA), and matching secondary rabbit anti-mouse IgG-HRP conjugate [with 3,3'-Diaminobenzidine (DAB) solution, E-IR-R217, Elabscience, Houston, TX, USA] were used for immunostaining. The sections were deparaffinized and then treated with 3% H₂O₂ solu-

Table II. Tubular cell immunopositivity grading.

Grade	Findings
0	> 5%
1	6-25%
2	26-50%

tion for 15 min before being blocked for 20 min. The sections were then incubated with the primary and secondary antibodies as per instruction before counterstaining with Harris hematoxylin (Merck, Darmstadt, Germany).

Semi-Quantitative Analysis

In agreement with previous I/R studies^{8,17-19} involving the rAAA rat model, the Renal Pathological Damage Score (RPDS) was calculated based on tubular necrosis, atypical glomeruli, and vascular congestion in kidney sections (Table I). Thirty different areas in each section were evaluated by two blinded histopathologists. Apoptotic cells exhibiting IL-1 and IL-6 positivity were scored as shown in Table II.

Statistical Analysis

All data were analyzed on SPSS version 20.0 software (IBM Corp., Armonk, NY, USA). Non-parametric data were calculated as median and 25% and 75% interquartile ranges (IQR). Differences between the groups were analyzed using the non-parametric Kruskal-Wallis and Tamhane T2 tests. *p*-values <0.05 were regarded as statistically significant.

Results

Biochemical Analysis Results

There was no statistically significant difference in the MDA levels between the control and DMD groups (Table III). The MDA levels of the control and I/R groups were 0.93±0.36 µmol/g and

Table III. Biochemical results (mean standard deviation).

Group	MDA (µmol/g tissue)	Total thiol (µmol/g tissue)
Control	0.93 ± 0.36	19.06 ± 1.05
DMD	0.91 ± 0.328	19.35 ± 1.26
I/R	1.01 ± 0.35 ^a	15.70 ± 1.48 ^c
I/R+DMD	0.94 ± 0.24 ^b	17.75 ± 0.60 ^d

DMD: Dexmedetomidine, I/R: Ischemia/Reperfusion, MDA: malondialdehyde. ^a*p* = 0.012 vs. control group, ^b*p* = 0.016 vs. I/R group, ^c*p* = 0.001 vs. control group, ^d*p* = 0.009 vs. I/R group. One-Way ANOVA/Tukey HSD test.

1.01±0.35 µmol/g tissue, respectively (Table III, $p=0.012$). The MDA levels in the I/R group were higher than those of the DMD group (0.91±0.32 µmol/g tissue) (Table III, $p=0.016$).

No significant difference in total thiol levels was determined between the control and DMD groups (Table III). The total thiol levels were 19.06±1.05 µmol/g and 15.70±1.48 µmol/g tissue in the control and I/R groups, respectively (Table III, $p=0.001$). Total thiol in the DMD group (17.75±0.60 µmol/g tissue) was higher than the I/R group (Table III, $p=0.009$).

Histopathological Analysis Results

Examination of control group sections under light microscopy revealed normal glomeruli in Bowman's capsules. The brush border was distinct in the proximal tubules, and the distal tubular epithelial cells were normal in appearance [Figure 1A-B, Table IV, RPDS: 1 (0-1)]. Similarly, in the DMD group, typical glomeruli and tubular epithelial cells were observed [Figure 1C-D, Table IV, RPDS: 1 (0-1)]. In contrast, necrotic tubules containing epithelial cells with widespread cytoplasmic vacuoles were observed in the I/R group. Marked losses were also observed in brush border structures in the proximal tubules. Widespread vascular congestion and atypical glomeruli were present in the peritubular areas [Figure 1E-F, Table IV, $p<0.001$, RPDS: 9 (8-9)]. On the other hand, decreased necrotic tubules and vascular congestion and atypical glomeruli were observed in the I/R+DMD group [Figure 1G-H, Table IV, $p<0.001$, RPDS: 3 (2-3)].

Immunohistochemical (IHC) Analysis Results

Tubular epithelial cells in the control and DMD groups were immunonegative for IL-1 [Figure 2A-B, Table V, IL-I positivity score: 0 (0-0) for both]. In contrast, IL-1 positivity was elevated in the I/R group [Figure 2A-C, Table V, $p<0.001$, IL-I positivity score: 2 (2-3)]. However, IL-1 positivity in the I/R+DMD group was lower than the I/R group [Figure 2C-D, Table V, $p<0.001$, IL-I positivity score: 0 (0-1)].

Tubular epithelial cells in the control and DMD groups were negative for IL-6 [Figure 3A-B, Table V, IL-6 positivity scores 0 (0-1) and 0 (0-1), respectively]. IL-6 positivity in the I/R group was higher compared to the control and DMD groups [Figure 3A-C, Table V, $p<0.001$, IL-6 positivity

score 2 (2-2)]. However, the number of tubular epithelial cells exhibiting intense IL-6 positivity was lower in the I/R+DMD group than in the I/R group [Figure 3C-D, Table V, $p<0.001$, IL-6 positivity score 0 (0-1)].

Discussion

The current study showed increases in inflammatory cytokines such as IL-1 and IL-6 of ischemia and reperfusion in the abdominal aortic clamping model. However, DMD treatment showed an anti-inflammatory effect by decreasing IL-1 and IL-6 levels. In addition, we observed an increase in MDA levels in ischemia and reperfusion due to the aortic clamping model, but on the contrary, we found a decrease in glutathione (GSH) levels. In DMD treatment, we observed a decrease in MDA levels, but an increase in GSH levels. In the present study, we will shed light on new treatment horizons in the future by addressing the effect of α -2 adrenoreceptor agonists in acute kidney injury due to rAAA surgery.

Factors such as age, sex, comorbidity, hemodynamic stability, postoperative care, and the experience of the surgical team have all been reported^{2,20} to affect rAAA-related morbidity and mortality. Although hypovolemic shock can be corrected within a short period, AKI due to I/R injury is the principal cause of death in many patients undergoing rAAA-related interventions under emergency conditions^{2,20}. Sinicrope et al²⁰ described AKI as the most important predictive factor in rAAA mortality. Although renal perfusion disorder deriving from massive bleeding is generally responsible for the development of AKI, factors such as the use of contrast material during imaging tests and suprarenal cross-clamp attachment have also been described^{2,3,8} as contributing to this. Infrarenal positioning of the cross-clamps, use of intraoperative blood protection techniques, perioperative fluid replacement, and optimal systemic perfusion are considered as important factors in reducing kidney injury by clinicians. In addition to these basic prevention methods, the use of medical agents capable of reducing the incidence of AKI in the perioperative period has recently attracted significant attention from cardiovascular surgeons and anesthesiologists^{2,3,8,9,20}.

Renal blood flow has been shown to decrease during rAAA surgery, even if the cross-clamp is attached infrarenal, due to turbulent flow in the

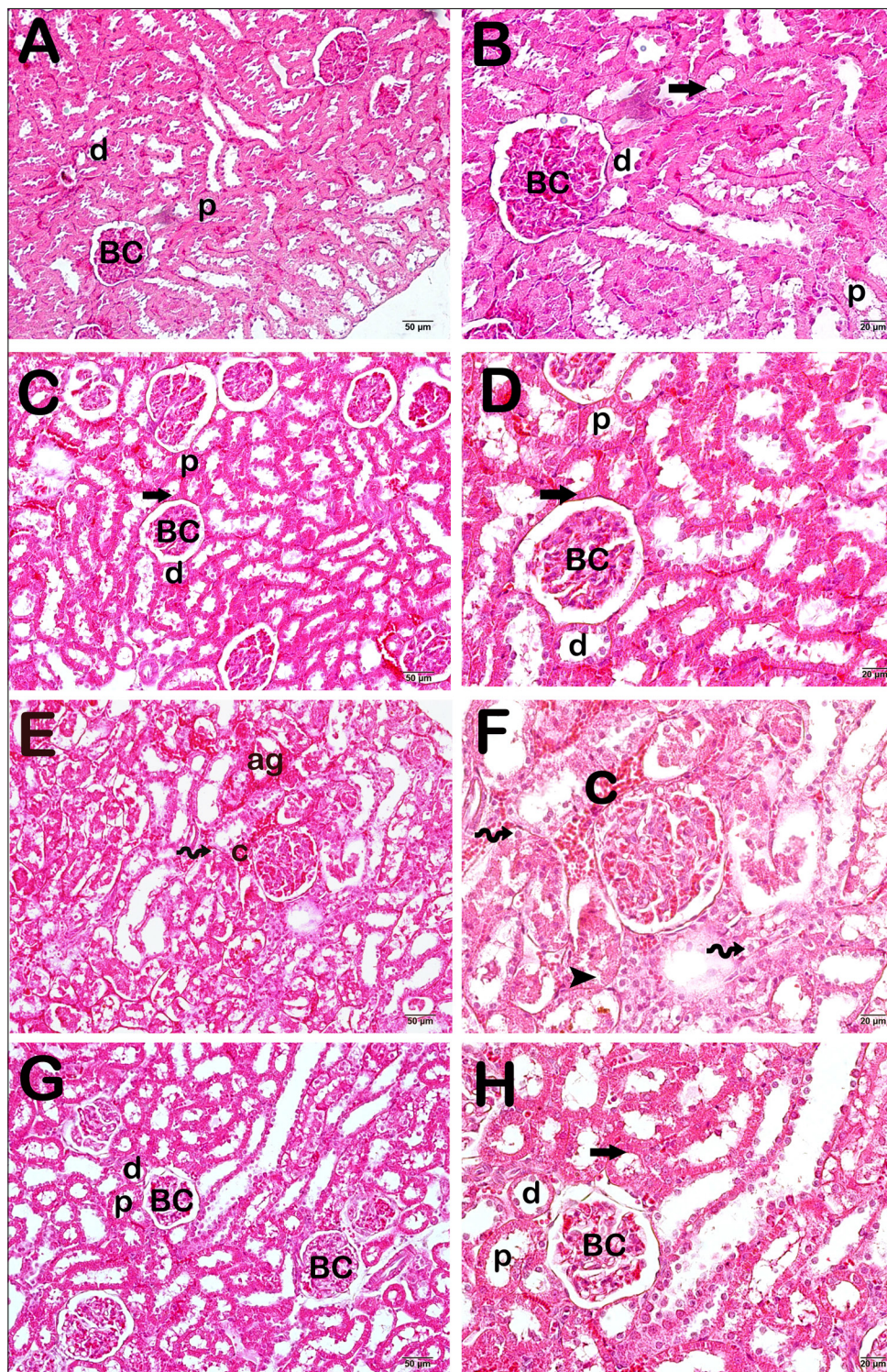


Figure 1. Light microscope photographs of myocardial tissue stained with H&E. Bowman's capsule (BC), proximal tubules (p), distal tubule (d). **A**, ($\times 20$) - **B**, ($\times 40$), Control group: The normal structure is observed in renal tissue sections (*arrow*), [RPDS median: 1 (0-1)]. **C**, ($\times 20$) - **D**, ($\times 40$), DMD group: Normal Bowman capsules proximal and distal tubules (tailed arrow) are observed [RPDS median: 1 (0-1)]. **E**, ($\times 20$) - **F**, ($\times 40$), I/R group: Degenerative Bowman capsules (spiral arrow) and necrotic renal tubules with loss of brush border structure (arrowhead) and cytoplasmic vacuoles are observed. In addition, atypical glomerules (ag) and vascular congestion (c) are shown [RPDS median: 9 (8-9)]. **G**, ($\times 20$) - **H**, ($\times 40$), I/R+DMD group: A decrease in degenerative Bowman capsules and necrotic tubules is observed. In addition, brush border structures are clearly shown in the proximal tubules [RPDS median: 3 (2-4)].

Table IV. RPDS (median, 25-75% interquartile range).

Group	Tubular necrosis score	Proximal tubule brush border loss	Vascular congestion	Atypical glomeruli	RPDS
Control	0 (0-0)	0 (0-0)	0 (0-0)	0 (0-0)	1 (0-1)
DMD	0 (0-0)	0 (0-0)	0 (0-0)	0 (0-0)	1 (0-1)
I/R	3 (2-3) ^{a,b}	2 (2-2) ^{a,b}	2 (2-2) ^{a,b}	2 (2-2) ^{a,b}	9 (8-9) ^{a,b}
I/R+DMD	1 (1-2) ^{a,b,c}	1 (0-1) ^{a,b,c}	1 (1-1) ^{a,b,c}	0 (0-1) ^{a,b}	3 (2-4) ^{a,b,c}

RPDS: Renal Pathological Damage Score. ^a $p < 0.05$; vs. control group, ^b $p < 0.05$; vs. DMD group, ^c $p < 0.05$; vs. I/R group. Kruskal-Wallis/Tamhane T2 test.

aorta at the level of the renal arteries. Additionally, clamping at any level of the aorta results in decreased cardiac output. These adverse changes in renal blood flow result in the impairment of cortical nephron perfusion^{4,5}. Several studies^{4,5,8,21} examining renal tissues using an aortic I/R model have described the ensuing histopathological changes. Tubular damage characterized by cast formation in renal tissue due to I/R injury, interstitial tissue edema, tubular necrosis accompanied by loss of the brush border structure, and cellular separation in the basal membranes have been observed in such studies^{4,5,8,21}. Similarly, in the present study, widespread peritubular vascular congestion, marked loss of the proximal tubule brush border, and necrotic tubules containing epithelial cells with cytoplasmic vacuoles were observed in renal tissues due to I/R, and exposure to I/R caused a significant increase in RPDS (Figure 1, Table IV).

ROS is one of the most important components of the complex tissue damage mechanisms resulting from I/R^{4,6,22}. In addition to stimulating leukocyte chemotaxis and proteolytic enzyme release, ROS formation during reperfusion also causes tissue damage through various mechanisms⁶. Increased oxidative stress and tissue damage primarily derive, not from ROS formation, but rather from an imbalance between ROS production and antioxidant systems. Cellular damage occurs if the ROS is not removed by exogenous antioxidants^{5,6}. Endogenous antioxidant enzymes protect the cells against these deleterious effects by detoxifying ROS. Various studies^{4-6,8} have employed antioxidant enzyme levels to determine the severity of oxidative stress caused by I/R. Yüksel et al⁴ concluded that I/R significantly reduced superoxide dismutase and catalase enzyme levels in renal tissue, while thiol levels were unaffected. Other studies^{5,6,8} have observed a severe decrease in thiol levels in

renal tissue under the effect of I/R. Thiol levels also decreased significantly in the renal tissues subjected to I/R administration in the present study (Table III).

Lipid peroxidation resulting from ROS leads to cell damage by impairing the viscosity and permeability of the cell membrane. Lipid peroxidation is therefore closely associated with tissue damage developing due to I/R. MDA, the final product of lipid peroxidation in the cell membrane, is a good marker of the speed of lipid peroxidation and thus of oxidative stress^{4,6,22}. Previous studies^{4,6,8,22} showed a significant increase in MDA levels in renal tissues exposed to I/R. Similarly in the present study, MDA levels in renal tissue increased significantly due to I/R, and this was also consistent with RPDS (Table III).

Proinflammatory cytokines like IL-1 and IL-6 play an important role in the pathological mechanism of I/R injury in tissues^{5,22,23}. The functions of these cytokines include stimulating macrophage inflammatory protein, monocyte chemotactic protein, interferon-gamma production, and mediating macrophage activation. Research⁵ has shown that inflammatory cytokine levels decrease, epithelial cell proliferation is increased by inhibiting apoptosis in renal epithelial cells, and macrophage migration is inhibited as a result of pharmacological neutralization of these cytokines in renal I/R injury. Studies^{5,22,23} have also shown that IL-1 and IL-6 levels increase significantly in kidney tissues exposed to I/R. In agreement with these findings in the literature, IL-1 and IL-6 levels also rose significantly in renal tissues exposed to I/R in the present study (Figure 2, Table V).

DMD, an anxiolytic and analgesic, is widely employed in the perioperative period since it does not cause respiratory suppression^{10,11,24}. Surgical stress leads to renal artery vasocon-

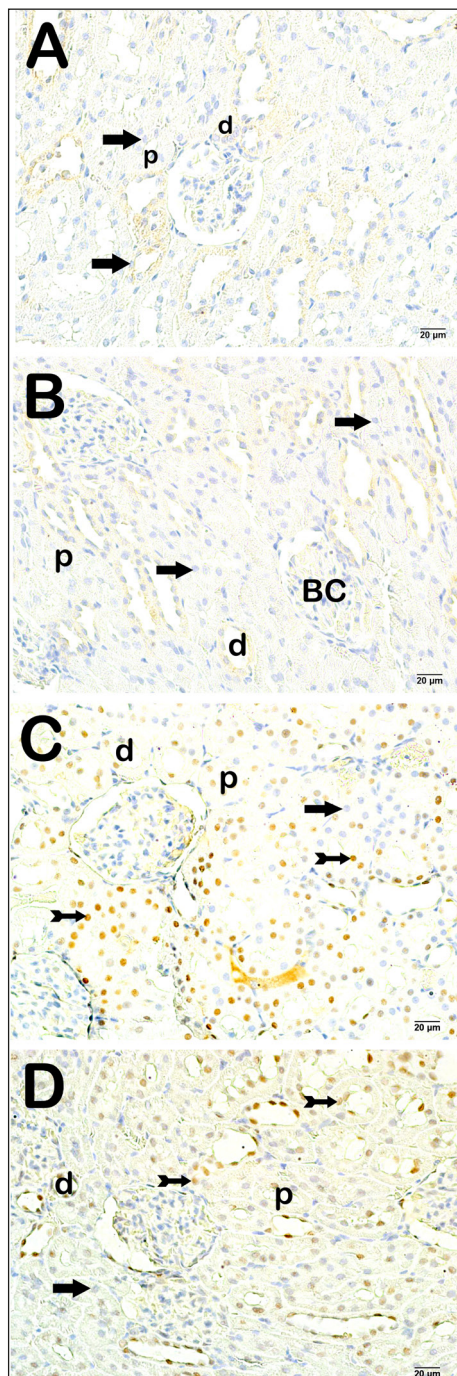


Figure 2. Light microscope images of renal tissue incubated with IL-1 primary antibodies. Bowman capsules (b), Proximal Tubules (p), Distal tubules (d). **A**, ($\times 40$), Control group: Normal structure is observed in renal epithelial cells (arrow), [IL-1 positivity score: 0 (0-0)]. **B**, ($\times 40$), DMD group: Typical Bowman capsules and renal tubular cells (tailed arrow) are observed [IL-1 positivity score: 0 (0-0)]. **C**, ($\times 40$), I/R group: Dense IL-1 positive cells (arrow) present in the necrotic tubules [IL-1 positivity score: 2 (2-3)]. **D**, ($\times 40$), I/R+DMD group: A decrease in IL-1 positivity score is apparent in tubular epithelial cells (arrow), [IL-1 positivity score: 1 (0-1)].

striction as a result of sympathetic hyperactivation. Renal functions in the perioperative period of rAAA surgery are closely associated with sympathetic activity and hemodynamic stability. DMD reduces sympathetic tone and lowers catecholamine levels by stimulating the central α -2 adrenoreceptors. It thus also provides hemodynamic stabilization in addition to its sedative, analgesic, anti-inflammatory, and diuretic effects. It also suppresses renin release, increases sodium and water secretion, and increases nitric oxide-induced vasodilation by activating α -2 adrenoreceptors in the renal vascular bed and tubules^{11,24}. The number of studies^{25,26} examining the effects of DMD on I/R-induced kidney injury is limited. Almost all studies in this field have focused on I/R injury developing in the kidney as a distant organ during cardiac surgery. In a meta-analysis involving 1,575 adult patients undergoing cardiac surgery, Liu et al⁹ found that perioperative DMD use was associated with a decreased risk of AKI in the postoperative period. Studies^{10,24} of congenital cardiac surgery patients have also reported that DMD exhibits a renoprotective effect by providing hemodynamic stability and improving tubular structure and functions. In the present study, DMD lowered levels of MDA, the final product of lipid peroxidation, in renal tissues exposed to I/R, increased thiol levels, reduced atypical glomeruli with necrotic tubules and vascular congestion, and lowered the number of tubular epithelial cells exhibiting IL-1 and IL-6 positivity.

To the best of our knowledge, the present study is the first to focus on the effects of DMD against I/R in renal tissue in an rAAA model. The principal limitation of this study is that the results are not supported by other antioxidant enzymes and kidney function tests. Further studies are required for dosage optimization and timing of administration of DMD.

Table V. Immunopositivity Score Results (median, 25%-75% interquartile range).

Group	IL-1	IL-6
Control	0 (0-0)	0 (0-1)
DMD	0 (0-0)	0 (0-1)
I/R	2 (2-3) ^{a,b}	2 (2-2) ^{a,b}
I/R+DMD	1 (0-1) ^{a,b,c}	0 (0-1) ^{a,b,c}

^a $p < 0.05$; vs. the control group, ^b $p < 0.05$; vs. DMD group, ^c $p < 0.05$; vs. I/R group. Kruskal-Wallis / Tamhane T2 test.

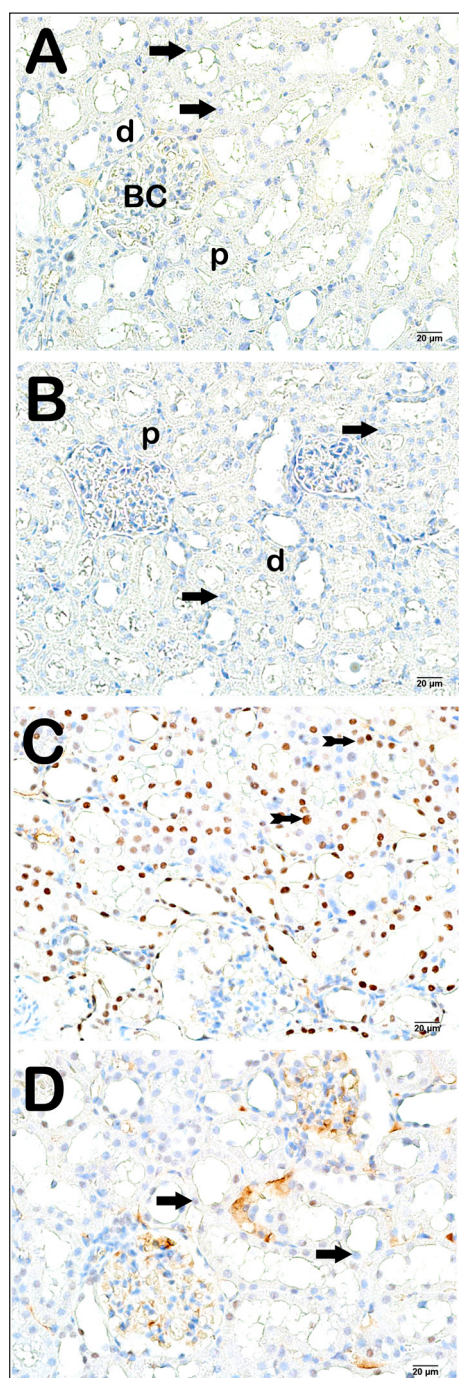


Figure 3. Light microscope images of renal tissue incubated with anti-IL-6 antibody. Bowman capsules (b), Proximal Tubules (p), Distal tubules (d). **A**, ($\times 40$), Control group: normal structure is observed in renal epithelial cells (arrow), [IL-6 positivity score: 0 (0-0)]. **B**, ($\times 40$), DMD group: typical Bowman capsules and renal tubular cells (arrow) are observed [IL-6 positivity score: 0 (0-0)]. **C**, ($\times 40$), I/R group: dense IL-6 positive cells (tailed arrow) are apparent in the necrotic tubules [IL-6 positivity score: 2 (2-3)]. **D**, ($\times 40$), I/R+DMD group: decrease in IL-6 positivity score is observed in tubular epithelial cells (arrow), [IL-6 positivity score: 1 (0-1)].

Conclusions

Dexmedetomidine has a nephroprotective effect against acute kidney injury resulting from I/R, which is related to aortic occlusion used in the treatment of ruptured abdominal aortic aneurysms. The use of dexmedetomidine may be an advantageous alternative in patients with ruptured abdominal aortic aneurysms undergoing aortic occlusion.

Conflict of Interest

The Authors declare that they have no conflict of interests.

Acknowledgements

None.

Ethics Approval

The study protocol was approved by the Ethics Committee of the Faculty of Medicine of Recep Tayyip Erdogan University and was conducted following the principles of the Declaration of Helsinki (Approval number 2017-23).

Authors' Contribution

SE: designed the study, performed experiments, analyzed data, provided resources, acquired funding and wrote the manuscript. DH: designed the study, performed experiments and analyzed data. SOK: conceptualized research, designed the study and performed experiments. LT: designed the study, performed experiments, analyzed data and revised and edited the manuscript. TM: compiled and interpreted histopathological findings, analyzed data, and revised, and edited the manuscript. AY: compiled and interpreted biochemical findings, analyzed data, and revised, and edited the manuscript. All authors reviewed the manuscript.

Funding

No financial support was received from any institution for this project.

Availability of Data and Materials

The datasets generated for this study are available from the corresponding author upon request.

Informed Consent

Not applicable.

ORCID ID

Saban Ergene: 0000-0003-1806-3168; Dogus Hemsinli: 0000-0002-0033-6220; Sedat Ozan Karakisi: 0000-0002-0055-7496; Levent Tumkaya: 0000-0001-5387-4666; Tolga Mercantepe: 0000-0002-8506-1755; Adnan Yilmaz: 0000-0003-4842-1173.

References

- 1) Rixen TS, Keese M, Hakimi M, Peters A, Böckler D, Nelson K, Grundmann RT. Ruptured abdominal aortic aneurysm—epidemiology, predisposing factors, and biology. *Langenbecks Arch Surg* 2016; 401: 275-288.
- 2) Kim SD, Hwang JK, Park SC, Kim JI, Moon IS, Park JS, Yun SS. Predictors of Postoperative Mortality of Ruptured Abdominal Aortic Aneurysm: A Retrospective Clinical Study. *Yonsei Med J* 2012; 53: 772-780.
- 3) Davies RSM, Samir Dawlatly, Clarkson JR, Bradbury AW, Adam DJ. The outcome in Patients Requiring Renal Replacement Therapy After Open Surgical Repair for Ruptured Abdominal Aortic Aneurysm. *Vascu Endovascular Surg* 2010; 44: 170-173.
- 4) Yuksel S, Sezer MT, Sahin O, Sutcu R, Kocogullari C, Yilmaz HR, Uz E, Kara Y, Aydin B, Altuntas A. The Role of Carnitine in Preventing Renal Damage Developed as a Result of Infrarenal Aortic Ischemia-Reperfusion. *Renal Failure* 2011; 33: 440-449.
- 5) Adali F, Gonul Y, Aldemir M, Hazman O, Ahsen A, Bozkurt MF, Sen OG, Keles I, Keles H. Investigation of the effect of crocin pretreatment on renal injury induced by infrarenal aortic occlusion. *J Surg Res* 2016; 2003: 145-153.
- 6) Goksin I, Adali F, Enli Y, Akbulut M, Teke Z, Sackan G, Ocak E, Ozcan AV. The Effect of Phlebotomy and Mannitol on Acute Renal Injury Induced by Ischemia/Reperfusion of Lower Limbs in Rats. *Ann Vasc Surg* 2011; 25: 1118-1128.
- 7) Hemsinli D, Tumkaya L, Ergene S, Karakisi SO, Mercantepe T, Yilmaz A. Dexmedetomidine attenuates pneumocyte apoptosis and inflammation induced by aortic ischemia-reperfusion injury. *Clin Exp Hypertens* 2022; 44: 595-600.
- 8) Ergene Ş, Hemşinli D, Karakişi SO, Mercantepe T, Tumkaya L, Yilmaz A. The Role of Vaccinium Myrtillus in the Prevention of Renal Injury in an Experimental Model of Ruptured Abdominal Aortic Aneurysm. *Braz J Cardiovasc Surg* 2020; 35: 490-497.
- 9) Liu Y, Sheng B, Wang S, Lu F, Zhen J, Chen W. Dexmedetomidine prevents acute kidney injury after adult cardiac surgery: a meta-analysis of randomized controlled trials. *BMC Anesthesiol* 2018; 18: 1-7.
- 10) Kim EH, Lee JH, Kim HS, Jang YE, JiS H, Kim WH, Kwak JG, Kim JT. Effects of intraoperative dexmedetomidine on the incidence of acute kidney injury in pediatric cardiac surgery patients: A randomized controlled trial. *Paediatr Anaesth* 2020; 30: 1132-1138.
- 11) Cho JS, Shim JK, Soh S, Kim MK, Kwak YL. Perioperative dexmedetomidine reduces the incidence and severity of acute kidney injury following valvular heart surgery. *Kidney Int* 2016; 89: 693-700.
- 12) Plin C, Tillement JP, Berdeaux A, Morin D. Resveratrol protects against cold ischemia-warm reoxygenation-induced damages to mitochondria and cells in rat liver. *Eur J Pharmacol* 2005; 528: 162-168.
- 13) Pulathan Z, Altun G, Hemşinli D, Menteşe A, Yuluğ E, Civelek A. Role of ethyl pyruvate in the systemic inflammatory response and lung injury in an experimental model of ruptured abdominal aortic aneurysm. *Biomed Res Int* 2014; 2014: 1-9.
- 14) Karakişi O, Hemşinli D, Tümkaya L, ErgeneŞ, Mercantepe T, Yilmaz A. The effects of dexmedetomidine against ruptured abdominal aortic aneurysm injury to myocardial tissue induced by abdominal aorta clamping. *Turkish Journal of Vascular Surgery* 2021; 30: 93-101.
- 15) Drapper HH, Hadley M. Malondialdehyde determination as index of lipid peroxidation. *Methods Enzymol* 1990; 186: 421-431.
- 16) de Almeida RBM, de Almeida Luz RLS, Leite FHA, Botura MB. A Review on the In Vitro Evaluation of the Anticholinesterase Activity Based on Ellman's Method. *Mini Rev Med Chem* 2022; 22: 1803-1813.
- 17) Simon F, Scheuerle A, Gröger M, Stahl B, Wachter U, Vogt J, Speit G, Hauser B, Möller P, Calzia E, Szabó C, Schelzig H, Georgieff M, Radermacher P, Wagner F. Effects of intravenous sulfide during porcine aortic occlusion-induced kidney ischemia/reperfusion injury. *Shock* 2011; 35: 156-163.
- 18) Doulamis I, Guarienta A, Saeed M, Nomoto R, Duignan T, Del Nido P, McCully J. A Large Animal Model for Acute Kidney Injury by Temporary Bilateral Renal Artery Occlusion. *J Vis Exp* 2021; 2: 1-10.
- 19) Sung MJ, Kim DH, Yu Jung YJ, Kang KP, Lee AS, Lee S, Kim W, Davaatseren M, Hwang JT, Kim HJ, Kim MS, Kwon DY, SK. Genistein protects the kidney from cisplatin-induced injury. *Kidney Int* 2008; 74: 1538-1547.
- 20) Sinicrope RA, Serra RM, Engle JE, Nicholas GG, Devine MF, Schoolwerth AC. Mortality of acute renal failure after rupture of abdominal aortic aneurysms. *Am J Surg* 1981; 141: 240-242.
- 21) Aydin MS, Caliskan A, Kocarlan A, Kocarlan S, Yildiz A, Günay S, Savik E, Hazar A, Yalcin F. Intraperitoneal curcumin decreased lung, renal and heart injury in abdominal aorta ischemia/reperfusion model in rat. *Int J Surg* 2014; 12: 601-605.
- 22) Mohammadi M, Najafi H, Yarijani ZM, Vaezi G, Hojati V. Protective effect of piperine in ischemia-reperfusion induced acute kidney injury through inhibition of inflammation and oxidative stress. *J Tradit Complement Med* 2020; 10: 570-576.
- 23) Baker RC, Armstrong MA, Young IS, McClean, O'Rourke D, Campbell FC, Barros D'Sa AAB,

- McBride WT. Methylprednisolone Increases Urinary Nitrate Concentrations and Reduces Sub-clinical Renal Injury During Infrarenal Aortic Ischemia-Reperfusion. *Ann Surg* 2006; 244: 821-826.
- 24) Kwiatkowski DM, Axelrod DM, Sutherland SM, Tesoro TM, Krawczeski CD. Dexmedetomidine Is Associated with Lower Incidence of Acute Kidney Injury After Congenital Heart Surgery. *Pediatr Crit Care Med* 2016; 17: 128-134.
- 25) Chen R, Dou XK, Dai MS, Sun Y, Sun SJ, Wu Y. The role of dexmedetomidine in immune tissue and inflammatory diseases: a narrative review. *Eur Rev Med Pharmacol Sci* 2022; 26: 8030-8038.
- 26) Dil E, Tumkaya L, Mercantepe T, Rakici S, Yilmaz A, Celik Samanci T, Yazici ZA. Radioprotective effects of dexmedetomidine on X-ray-induced testicular damage. *Eur Rev Med Pharmacol Sci* 2023; 27: 673-680.