

Development of psoriasis scalp with alopecia during treatment of Crohn's disease with infliximab and rapid response to both diseases to ustekinumab

G. ANDRISANI, M. MARZO, L. CELLENO¹, L. GUIDI, A. PAPA, A. GASBARRINI, A. ARMUZZI

IBD Unit, Complesso Integrato Columbus-Gemelli Hospital, School of Medicine, Catholic University of the Sacred Heart, Rome, Italy

¹Dermatology DH, Complesso Integrato Columbus, School of Medicine, Catholic University of the Sacred Heart, Rome, Italy

Abstract. – Anti tumor necrosis factor antibodies are used to treat both psoriasis and inflammatory bowel disease. Several paradoxical cases of psoriatic skin lesions induced by tumor necrosis factor antagonist therapy have been described in IBD patients in the recent years. Ustekinumab, a fully human anti-interleukin-12/23 monoclonal antibody, is the first drug of a new class of biologic therapy approved for the treatment of moderate to severe plaque psoriasis. Data on the efficacy of ustekinumab in patients with moderate-to-severe Crohn's disease, especially in patients previously treated with infliximab, have been recently published. We report about the effectiveness of ustekinumab in the treatment of both severe scalp psoriasis lesions with alopecia and active Crohn's disease.

Key Words:

Ustekinumab, Infliximab, Psoriasis scalp with alopecia, Crohn's disease.

Introduction

The occurrence of new onset psoriasis in a patient treated with anti-tumor necrosis factor (TNF) antibody therapy is increasingly recognized. This phenomenon is apparently paradoxical as anti TNF agents are also effective in the treatment of psoriasis¹⁻³. Most of current data on this apparent drug reaction come from the rheumatology literature, but there has been increasing recognition of psoriasis and psoriasis-like skin rashes developing in inflammatory bowel disease (IBD) patients treated with anti TNF antibodies. Psoriasis is a chronic skin disease affecting 1-3% of the population. The scalp is the common site of involvement at the onset and dur-

ing the disease. Fifty to eighty percent of patients with psoriasis report scalp psoriasis or concomitant psoriasis of the scalp and the body, leading to a prevalence of scalp psoriasis of 1.5% to 2% in north western Europe⁴. The clinical presentation of scalp psoriasis can be highly variable, ranging from mild disease, with slight, fine scaling, to very severe disease, with thick, crusted plaques covering the entire scalp⁵. Ustekinumab, a fully human anti-interleukin-12/23 monoclonal antibody, is the first drug of a new class of biologic therapy approved for the treatment of moderate-to-severe plaque psoriasis. Data on the efficacy of ustekinumab in patients with moderate-to-severe Crohn's disease (CD), especially in patients previously treated with infliximab, have been recently published⁶⁻⁷.

We report here the case of young female patient with severe scalp psoriasis-alopecia, developed during infliximab therapy, and with clinically active CD successfully treated with ustekinumab.

Case Report

A 26-year old girl, with an 6 year history of CD diagnosed after ileocolonic resection for ileal perforation. She had no personal or family history of psoriasis. Because of thiopurine intolerance, she had been treated with only mesalazine (3.2 g daily) for CD and systemic corticosteroids in case of relapse until February 2012, when she first visited our Clinic for diffuse abdominal pain and diarrhea (7 to 8 bowel movements per day). Her abdominal examination showed diffuse abdominal tenderness to palpation, especially in right iliac fossa, where it was possible to reveal a

minimal bowel distension without no rebound or guarding signs. Blood tests showed increase of white blood cell count [$12.5 \times 10^9/L$; range: 4.3 to 10.8×10^9 cells/L], C-reactive protein (CRP) [24.5 mg/L; range: 1-3 mg/L] and erythrocyte sedimentation rate (ESR) [44; range < 30]. Stool culture and Clostridium difficile toxin were negative. Ileocolonoscopy revealed substenosis of the ileotransverse anastomosis > 5 aphthous lesions with normal mucosa between the lesions (grade i4 Rutgeerts' score) (Figure 1).

Small bowel magnetic resonance imaging (MRI) showed wall thickening and irregular mesenteric margin of the anastomosis adjacent to a segment of neoterminal ileum of about 8 cm, with focal wall thickening (Figure 2).

After screening for biologic therapy she was started on infliximab therapy at the dose of 5 mg/kg body weight at week 0, 2, and 6. Eight weeks after the third infliximab infusion her intestinal symptoms significantly improved according to normalization of inflammatory parameters. However, she complained of the persistence of intense itching of the scalp and hair loss. Her physical examination revealed only diffuse erythematous scaly plaque on the scalp with severe hair loss (Figure 3). Two skin biopsies were performed and showed the characteristic of psoriasis without any evidence of a scarring alopecia: lymphoid perifollicular infiltrate with follicular atrophy and a parakeratosis and superficial dermic

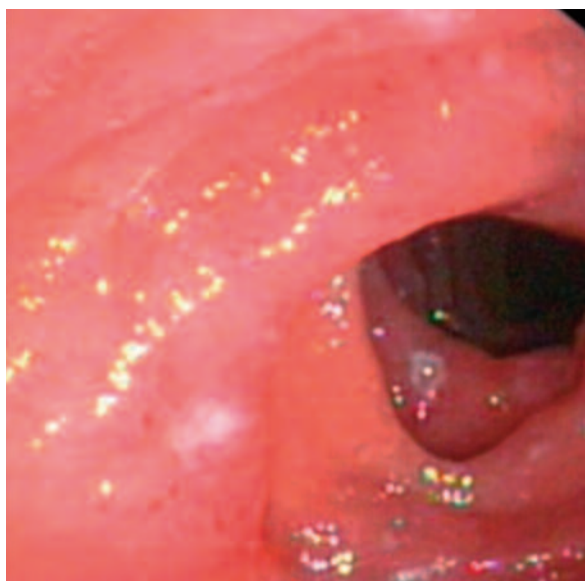


Figure 1. Ileotransverse anastomosis substenotic with > 5 aphthous lesions with normal mucosa between the lesions (grade i2 Rutgeerts' score).

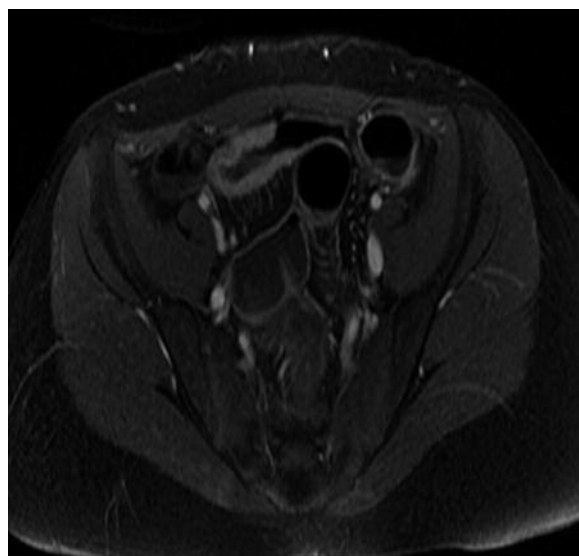


Figure 2. ICORONAL B-FFE image showed the segment of neoterminal ileum with focal wall thickening.

perivascular infiltrates. No bacterial organism was identified by culture. Treatment with infliximab was discontinued and was started a daily topical administration of clobetasol propionate and oral prednisone. However, after four week, scalp psoriasis showed progression with extensive alopecia (Figure 4) and the patient reported also abdominal complaints: diarrhea (9 to 10 bowel movements per day), mild fever $37.1^{\circ}C$ and abdominal pain. Contrast-enhanced power doppler sonography of the small bowel excluded abscesses and fistulas and showed an increase of vascularization and thickness of the preanastomotic intestinal wall. Blood tests showed increase of white blood cell count [$11.5 \times 10^9/L$] and CRP [21.0 mg/L]. According to dermatologist consultation, she was then started on ustekinumab therapy at the dose of 45 mg subcutaneously injected at day 0, week 4 and every 12 weeks. Both the scalp psoriasis with alopecia and intestinal symptoms significantly improved after ustekinumab induction regimen: one to two bowel movements per day and marked improvement of alopecia. We performed blood tests that showed normal white blood cell count and CRP. Complete remission of scalp psoriasis with alopecia and itching was achieved after 6 months of treatment (Figure 5). Moreover, after 28 weeks of treatment the ileocolonoscopy showed ileotransverse anastomosis with only hyperemic mucosa without endoscopic signs of recurrence of Crohn's disease (grade i0 Rutgeerts' score).

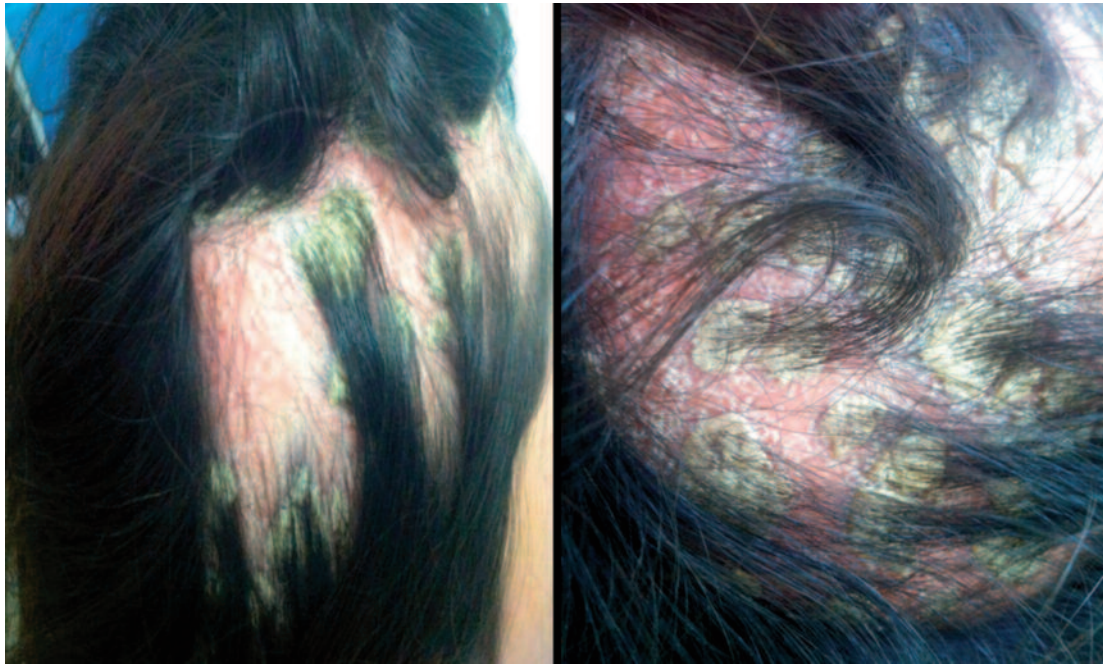

Figure 3. Diffuse erythematous scaly plaque on the scalp with severe hair loss.

Discussion

There are currently over 200 cases of suspected TNF antagonist induced or exacerbated psoriasis in the literature⁸. The underlying pathophysiological mechanism is unknown and several theories

have been postulated. One suggested mechanism is the activation of nascent autoreactive T-cells that cause psoriasis by means of altered immunity⁹. Moreover, it has been hypothesized that the pathogenesis of TNF antagonist induced psoriasiform lesions involves a disruption in cytokine balance by TNF blockade, allowing unopposed interferon-alpha ($INF\alpha$) production by plasmacytoid dendritic cells (PCDs) in genetically predisposed individuals¹⁰⁻¹¹. $INF\alpha$ is known to induce expression of the chemokine receptor CXCR3 on T-cells, which leads to recruitment of T cells into the skin¹². T-cell producing TNF- α causes psoriatic skin lesions^{8,13}. Psoriasis is known also to have a strong genetic component with multifaceted mode of inheritance involving multiple chromosome loci¹⁴, and other polymorphisms could play a role in patients with this paradoxical response to TNF- α blockade. Genome-wide association scans of psoriasis patients have also found variants in the gene encoding the interleukin-23 receptor, among other cytokines. Interleukin-23 receptor variants have also been identified in CD¹⁴. TNF antagonists have the potential to disrupt the delicate balance of gene products, cytokines, and chemokines that normally prevent the development of psoriasis in a genetically predisposed patient who would not have otherwise developed the skin condition. Some

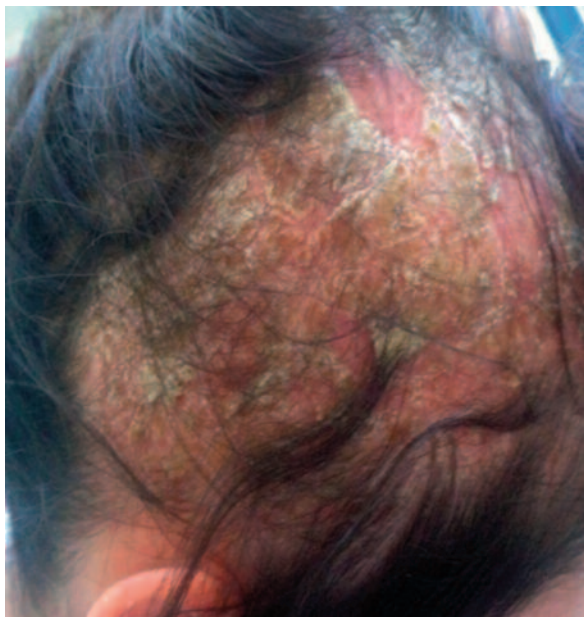

Figure 4. Progression with extensive alopecia.

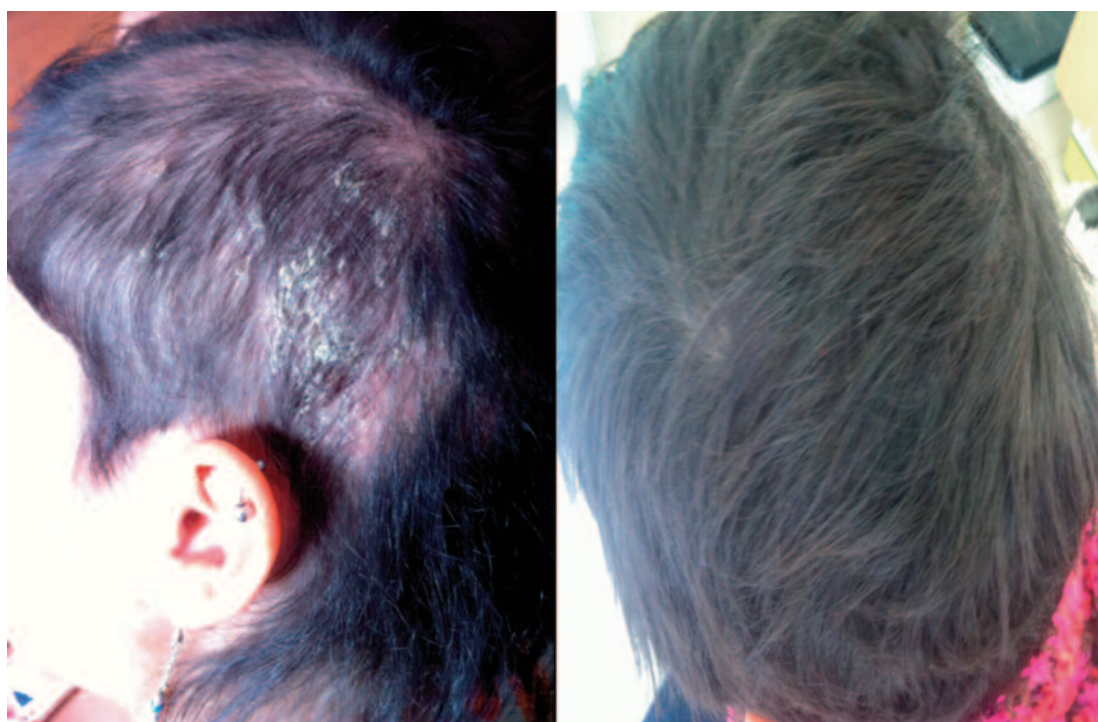

Figure 5. Complete remission of scalp psoriasis and alopecia after 6 months of treatment.

studies^{15,16} have shown that the psoriasis was the most common adverse effect during anti-TNF, in particularly on infliximab, and the majority of patients were women, without personal or family history of psoriasis¹⁵⁻¹⁷. Several therapeutic approaches have been described for the case of paradoxical psoriasis subsequent to TNF- α antagonists administration. The interruption or replacement of anti TNF- α inhibitor led, regardless of concomitant disease, to the resolution of cutaneous lesions in 24% and in 15% of cases, respectively^{10,18}. In other reviews^{10,19} this strategy has been more successful, especially in IBD patients, with resolution of skin lesions after anti TNF- α discontinuation in 46%-88% of cases, while in only 34% of patients without suspension of the biological⁸. These data must be cautiously interpreted, because anti TNF- α withdrawal can determine the aggravation of intestinal manifestations^{20,21}. IBD patients developing psoriasis during anti-TNF- α therapy must be treated by conventional psoriasis approach (topical corticosteroids, phototherapy, vitamin-D analogs, methotrexate and/or cyclosporine) without the need to suspend infliximab. However, Buisson et al²² showed that methotrexate does not appear effective in treating psoriasiform lesions associated with anti-TNF therapy refractory to topical thera-

py in IBD. The discontinuation of anti TNF- α must be considered, especially in severe cases of psoriasis with important impact on quality of life. In our case it was necessary to suspend infliximab for the severity of scalp psoriasis, but CD relapsed and it was necessary to consider a new therapeutic approach, with the potential to be effective on both diseases. Ustekinumab is a human monoclonal antibody that binds with high specificity and affinity to the p40 subunit of cytokines IL-12 and IL-23, and it was recently approved in Europe and United States for the treatment of moderate-to-severe psoriasis. The therapeutic efficacy of approved dosages (45 and 90 mg) of subcutaneous ustekinumab in adult patients with moderate-to-severe plaque psoriasis was evaluated in two randomized, double-blind, placebo controlled, phase III trials (PHOENIX 1²³ and PHOENIX 2²⁴) and a phase III, randomized, single-blind, multinational, comparison with etanercept (ACCEPT) conducted in Europe and North America²⁵. Preclinical studies have implicated IL-12 and IL-23^{26,27} and the overexpression of the interleukin-12 p35 and interleukin-12/23 p40 subunits in the pathophysiology of CD. Others studies showed polymorphisms in genes encoding the interleukin-12/23 p40 subunit and interleukin-23 receptor^{26,28}, which were linked in the pathogene-

sis of CD. In a previous phase 2a study, ustekinumab showed efficacy in patients with moderate-to-severe CD, particularly among patients previously receiving infliximab⁶. Sandborn et al⁷, in a recent study, evaluated ustekinumab in adults with moderate-to-severe CD that was resistant to anti-TNF treatment. During induction, 526 patients were randomly assigned to receive intravenous ustekinumab (at a dose of 1, 3, or 6 mg/kg) or placebo at week 0. The primary end point was clinical response at 6 weeks (≥ 100 point decrease from baseline CDAI). The proportions of patients who achieved the primary end point were 36.6%, 34.1%, and 39.7% for 1, 3, and 6 mg/kg of ustekinumab, respectively, as compared with 23.5% for placebo ($p = 0.005$ for the comparison with the 6-mg group).

Conclusions

Our patient represents the first case of severe scalp paradoxical psoriasis with alopecia associated with CD exacerbation successfully treated with ustekinumab. This approach was chosen because the severity of alopecia and the relapse of the underlying CD. Ustekinumab treatment demonstrated rapid effectiveness in the resolution of scalp psoriasis with alopecia, with a positive impact on the patient's quality of life, and in the achievement of clinical remission of CD. At present, there are ongoing studies to evaluate the efficacy and safety of ustekinumab in CD. However, in these particular clinical settings a close collaboration between gastroenterologists and dermatologists to determine the best therapeutic strategy would be necessary.

Competing of Interest

A.A, L.G: educational grants and lecture fees from Abbott and MSD.

Conflict of Interest

The Authors declare that they have no conflict of interests.

References

- 1) GOTTSLIEB AB, EVANS R, LI S, DOOLEY LT, GUZZO CA, BAKER D, BALA M, MAARANO CW, MENTER A. Infliximab induction therapy for patients with severe plaque-type psoriasis: a randomized, double-blind, placebo controlled trial. *J Am Acad Dermatol* 2004; 51: 534-542.
- 2) MENTER A, TYRING SK, GORDON K, KIMBALL AB, LEONARDI CL, LANGLEY RG, STROBER BE, KAUL M, GU Y, OKUN M, PAPP K. Adalimumab therapy for moderate to severe psoriasis: a randomized controlled phase III trial. *J Am Acad Dermatol* 2008; 58: 106-115.
- 3) SAURAT JH, STINGL G, DUBERTRET L, PAPP K, LANGLEY RG, ORTONNE JP, UNNEBRINK K, KAUL M, CAMEZ A. Efficacy and safety results from the randomized controlled comparative study of adalimumab vs. methotrexate vs. placebo in patients with psoriasis (CHAMPION). *Br J Dermatol* 2008; 158: 558-566.
- 4) PAPP K, BERTH-JONES J, KRAGBALLE K, WOZEL G, DE LA BRASSINNE M. Scalp psoriasis: a review of current topical treatment options. *J Eur Acad Dermatol Venereol* 2007; 21: 1151-1160.
- 5) VAN DE KERKHOFF PC, DE HOOP D, DE KORTE J, KUIPER MV. Scalp psoriasis, clinical presentations and therapeutic management. *Dermatology* 1998; 197: 326-334.
- 6) SANDBORN WJ, FEAGAN BG, FEDORAK RN, SCHERL E, FLEISHER MR, KATZ S, JOHANNIS J, BLANK M, RUTGEERTS P; FOR USTEKINUMAB CROHN'S DISEASE STUDY GROUP. A randomized trial of ustekinumab, a human interleukin-12/23 monoclonal antibody, in patients with moderate-to-severe Crohn's disease. *Gastroenterology* 2008; 135: 1130-1141.
- 7) SANDBORN WJ, GASINK C, GAO LL, BLANK MA, JOHANNIS J, GUZZO C, SANDS BE, HANAUER SB, TARGAN S, RUTGEERTS P, GHOSH S, DE VILLIERS WJ, PANACCIONE R, GREENBERG G, SCHREIBER S, LICHTIGER S, FEAGAN BG; CERTIFI STUDY GROUP. Ustekinumab induction and maintenance therapy in refractory Crohn's disease. *N Engl J Med* 2012; 367: 1519-1528.
- 8) COLLAMER AN, BATTAFARANO DO. Psoriatic skin lesions induced by tumor necrosis factor antagonist therapy: clinical features and possible immunopathogenesis. *Semin Arthritis Rheum* 2010; 40: 233-240.
- 9) SFIKAKIS PP, KOLLIAS G. Tumor necrosis factor biology in experimental and clinical arthritis. *Curr Opin Rheumatol* 2003; 15: 380-386.
- 10) COLLAMER AN, GUERRERO KT, HENNING JS, BATTAFARANO DF. Psoriatic skin lesions induced by tumor necrosis factor antagonist therapy: a literature review and potential mechanisms of action. *Arthritis Rheum* 2008; 59: 996-1001.
- 11) DE GANNES G, GHOREISHI M, POPE J, RUSSELL A, BELL D, ADAMS S, SHOJANIA K, MARTINKA M, DUTZ JP. Psoriasis and pustular dermatitis triggered by TNF-alpha inhibitors in patients with rheumatologic conditions. *Arch Dermatol* 2007; 143: 223-231.
- 12) SHABRAWI-CAELEN L, LA PLACA M, VINCENZI C, HAIDN T, MUELLEGGGER R, TOSTI A. Adalimumab induced psoriasis of the scalp with diffuse alopecia: a severe potentially irreversible cutaneous side effect of TNF alpha blockers. *Inflamm Bowel Dis* 2010; 16: 182-183.

- 13) GILLET M, CONRAD C, GEIGES M, COZZIO A, THÜRLMANN W, BURG G, NESTLE FO, DUMMER R. Psoriasis triggered by toll-like receptor 7 agonist imiquimod in the presence of dermal plasmacytoid dendritic cell precursors. *Arch Dermatol* 2004; 140: 1490-1495.
- 14) NESTLE FO, KAPLAN DH, BARKER J. Psoriasis. *N Engl J Med* 2009; 361: 496-509.
- 15) WOLLINA U, HANSEL G, KOCH A, SCHÖNLEBE J, KÖSTLER E, HAROSKE G. Tumor necrosis factor a inhibitor-induced psoriasis or psoriasiform exanthemata: first 120 cases from the literature including a series of six new patients. *Am J Clin Dermatol* 2008; 9: 1-14.
- 16) SHMIDT E, WETTER DA, FERGUSON SB, PITTELKOW MR. Psoriasis and palmoplantars pustulosis associated with tumor necrosis factor-alpha inhibitors: the Mayo Clini experience, 1998 to 2010. *J Am Acad Dermatol* 2012; 67: e179-185.
- 17) RAHIER JF, BUCHE S, PEYRIN-BIROULET L, BOUHNIC Y, DUCLOS B, LOUIS E, PAPAY P, ALLEZ M, COSNES J, CORTOT A, LAHARIE D, REIMUND JM, LÉMANN M, DELAPORTE E, COLOMBEL JF; GROUPE D'ÉTUDE THÉRAPEUTIQUE DES AFFECTIONS INFLAMMATOIRES DU TUBE DIGESTIF (GETAID). Severe skin lesions cause patients with inflammatory bowel disease to discontinue anti-tumor necrosis factor therapy. *Clin Gastroenterol Hepatol* 2010; 8: 1048-1055.
- 18) CONKLIN LS, COHEN B, WILSON L, CUFFARI C, OLIVAHENKER M. Rash induced by anti tumor necrosis factor agents in an adolescent with Crohn's disease. *Nat. Rev Gastroenterol Hepatol* 2010; 7: 174-177.
- 19) FIORINO G, ALLENZ M, MALESCI A, DANESE S. Review article: anti TNF alpha induced psoriasis in patients with inflammatory bowel disease. *Aliment Pharmacol Ther* 2009; 29: 921-927.
- 20) AVILA ALVAREZ A, GARCÍA-ALONSO L, SOLAR BOGA A, SOLAR BOGA A, GARCÍA-SILVA J. Flexural psoriasis induced by infliximab and adalimumab in patient with Crohn's disease. *An Pediatric (Barc)* 2009; 70: 278-281.
- 21) TICHY M JR, TICHY M, KOPOVA R, STERNBERSKY J, DITRICHOVA D. Psoriasis and psoriatic arthritis induced in a patient treated with infliximab for Crohn's disease. *J Dermatolog Treat* 2012; 23: 208-211.
- 22) BUISSON A, CUNY JF, BARBAUD A, SCHMUTZ JL, BIGARD MA, GUÉANT JL, PEYRIN-BIROULET L. Methotrexate for psoriasiform lesions associated with anti-tumour necrosis factor therapy in inflammatory bowel disease. *Aliment Pharmacol Ther* 2012; 35: 1175-1180.
- 23) LEONARDI CL, KIMBALL AB, PAPP KA, YEILDING N, GUZZO C, WANG Y, LI S, DOOLEY LT, GORDON KB; PHOENIX 1 STUDY INVESTIGATORS. Efficacy and safety of ustekinumab, a human interleukin-12/23 monoclonal antibody, in patients with psoriasis:76-week results from randomized, double-blind, placebo-controlled trial (PHOENIX 1). *Lancet* 2008; 371: 1665-1674.
- 24) PAPP KA, LANGLEY RG, LEBWOHL M, KRUEGER GG, SZAPARY P, YEILDING N, GUZZO C, HSU MC, WANG Y, LI S, DOOLEY LT, REICH K; PHOENIX 2 STUDY INVESTIGATORS. Efficacy and safety of ustekinumab, a human interleukin-12\23 monoclonal antibody, in patients with psoriasis:52-week results from randomized, double-blind, placebo-controlled trial (PHOENIX 2). *Lancet* 2008; 371: 1675-1684.
- 25) GRIFFINTHS CE, STROBER BE, VAN DE KERKHOFF P, HO V, FIDELUS-GORT R, YEILDING N, GUZZO C, XIA Y, ZHOU B, LI S, DOOLEY LT, GOLDSTEIN NH, MENTER A; ACCEPT STUDY GROUP. Comparison of ustekinumab and etanercept for moderate-to-severe plaque psoriasis. *N Engl J Med* 2010; 362: 118-128.
- 26) DUERR RH, TAYLOR KD, BRANT SR, BRANT SR, RIOUX JD, SILVERBERG MS, DALY MJ, STEINHART AH, ABRAHAM C, REGUEIRO M, GRIFFITHS A, DASSOPOULOS T, BITTON A, YANG H, TARGAN S, DATTA LW, KISTNER EO, SCHUMM LP, LEE AT, GREGERSEN PK, BARMADA MM, ROTTER JI, NICOLAE DL, CHO JH. A genome-wide association study identifies IL23R as an inflammatory bowel disease gene. *Science* 2006; 314: 1461-1463.
- 27) STROBER W, ZHANG F, KITANI A, FUSS I, FICHTNER-FEIGL S. Proinflammatory cytokines underlying the inflammation of Crohn's disease. *Curr Opin Gastroenterol* 2010; 26: 310-317.
- 28) BERREBI D, BESNARD M, FROMONT-HANKARD G, PARIS R, MOUGENOT JF, DE LAGAUSIE P, EMILIE D, CEZARD JP, NAVARRO J, PEUCHMAUR M. Interleukin-12 expression is focally enhanced in the gastric mucosa of pediatric patients with Crohn's disease *Am J Pathol* 1998; 152: 667-672.