

# Acute embolisms in multiple arterial districts following Ad26.COVS vaccine

V. MURRU<sup>1</sup>, V. COCCO<sup>1</sup>, C. MARRAS<sup>1</sup>, A. SESTU<sup>1</sup>, F. MARONGIU<sup>2,3</sup>,  
L. SABA<sup>2,3</sup>, M.E. CIANCHETTI<sup>2</sup>, A. SCUTERI<sup>2,3</sup>

<sup>1</sup>Post-Graduate Medical School of Internal Medicine, University of Cagliari, Cagliari, Italy

<sup>2</sup>University Hospital (AOU) Cagliari, Policlinico Universitario Monserrato, Cagliari, Italy

<sup>3</sup>Dipartimento Scienze Mediche e Sanità Pubblica, Università di Cagliari, Cagliari, Italy

**Abstract.** – A case of multiple arterial thrombosis/embolisms in a 74-year-old Caucasian man with no other cardiovascular risk factors who received Ad26.COVS vaccine 16 days before is reported. The unusual presentation required a longer diagnostic workup. The clinical manifestations and the therapy-specific response suggest an unusual presentation of Vaccine-induced immune thrombotic thrombocytopenia (VITT).

#### Key Words:

COVID-19 vaccine, Janssen vaccine, Ad.26.COVS, Splenic infarction, Arterial embolism, Thrombosis of celiac artery, VITT.

## Introduction

After the identifications of the first cases in Wuhan, China, in December 2019, coronavirus disease 2019 (COVID-19) rapidly spread worldwide and took on pandemic proportions. By the end of September 2021, the COVID-19 pandemic has affected more than 229 million people worldwide and 4.71 million have died<sup>1</sup>.

Currently, vaccines represent the most powerful and effective instrument to fight the COVID-19. In Europe, the European Medicine Agency (EMA) approved four vaccines and five more are under rolling review.

To date, up to 528 millions of subjects underwent vaccination for COVID-19 in Europe. The adverse reactions to vaccination should not be intended as an argument against vaccination. Notably, the serious and life-threatening or fatal events involved arterial and venous thrombosis<sup>2</sup>.

Cerebral venous sinus thrombosis with thrombocytopenia (platelet count <150.000/ $\mu$ L of blood) have been observed more commonly with CHADOX1 NCOV-19 (AstraZeneca), and Ad26.COVS (Janssen – Johnson & Johnson)<sup>3</sup>.

We report a case of a 74-year-old Caucasian man who developed multiple arterial thromboses following the Ad26.COVS vaccination.

## Clinical Presentation

A 74-year-old Caucasian man was admitted to our Hospital Unit because of abdominal pain, vomit, loss of appetite, constipation, and polyuria, appearing 15 days before hospitalization. He also referred mild hypoesthesia and paresthesia in the right foot and right-side brachialgia. He denied any fever or cough. The patient gave the consent to access his data during Hospital admission.

The medical, surgical, or family history was negative for relevant diseases or risk factors (including alcohol or cigarette use), except the presence of treated arterial hypertension (AT-1 blocker). The patient had not previously been exposed to heparin nor reported any previous positive COVID-19 molecular test.

Thirty days prior to hospital admission, the patient was vaccinated with the adenoviral vector vaccine Ad26.COVS (Table I). On admission, he had a negative test result to nose-pharyngeal swab SARS-CoV-2 by polymerase chain reaction. In ED, the patient was stable (temperature 36.8°C, blood pressure 160/90 mmHg, pulse rate 112 beats/minute, oxygen saturation of 96% on room air). His body mass index (BMI) was 24.2 kg/m<sup>2</sup>. Cardiovascular system examination noticed a systolic murmur (intensity 2/6) and tachycardia. Crackling sounds were reported at lung auscultation. No alteration in the physical examination of the abdomen was observed.

An electrocardiogram (ECG) reported sinus tachycardia; the PR, QRS, and T-waves were normal with no changes in the ST-segment. The results of blood tests were normal except for a spe-

**Table I.** Timeline of the patient's story.

Date	Day of hospitalization	Sequence Outline
June 14, 2021		The patient received the J&J vaccine
June 30, 2021		Development of abdominal pain, vomit, loss of appetite
July 14, 2021	0	Admittance to the ER for worsening abdominal pain, vomit, loss of appetite, constipation, and polyuria
July 16, 2021	2	<i>Acute subclavian artery occlusion - Fogarty arterial embolectomy</i>
July 19, 2021	5	Subacute superficial femoral artery occlusion
July 20, 2021	6	<i>Fogarty femoral arterial embolectomy</i>
July 23, 2021	9	Total body CT with contrast PF4
July 26, 2021	12	Haemostasis medical consultation
July 27, 2021	13	
August 12, 2021	29	Discharge of the patient

cific mild elevation of amylase, lipase, creatinine, and PCR levels (Table II). Chest x-ray was normal, while direct abdominal x-ray displayed constipation, few air-fluid levels and rectal fecaloma.

A subsequent contrast-enhanced abdominal CT showed mesenteric panniculitis and diverticulosis not needing surgical attention for which he initiated therapy with Metronidazole 500 mg

three times daily, Ceftriaxone 2 g once daily and Enoxaparin 4000 UI once daily. On day 2 of hospital stay, the patient presented sudden pain in the right arm, with the disappears of the right radial pulse. Arterial Doppler ultrasound displayed acute subclavian artery occlusion in an arterial district without any local lesion or alteration in the whole supra-aortic arterial district. Therefore, the patient had successful Fogarty arterial embolectomy. Enoxaparin 4000UI was increased twice a day. From day 3 to day 5 of hospital stay, the patient presented paraesthesia of the right leg and progressive reduction of the right leg pulse. Arterial Doppler ultrasound showed superficial right femoral artery occlusion. The patient had another successfully Fogarty arterial embolectomy.

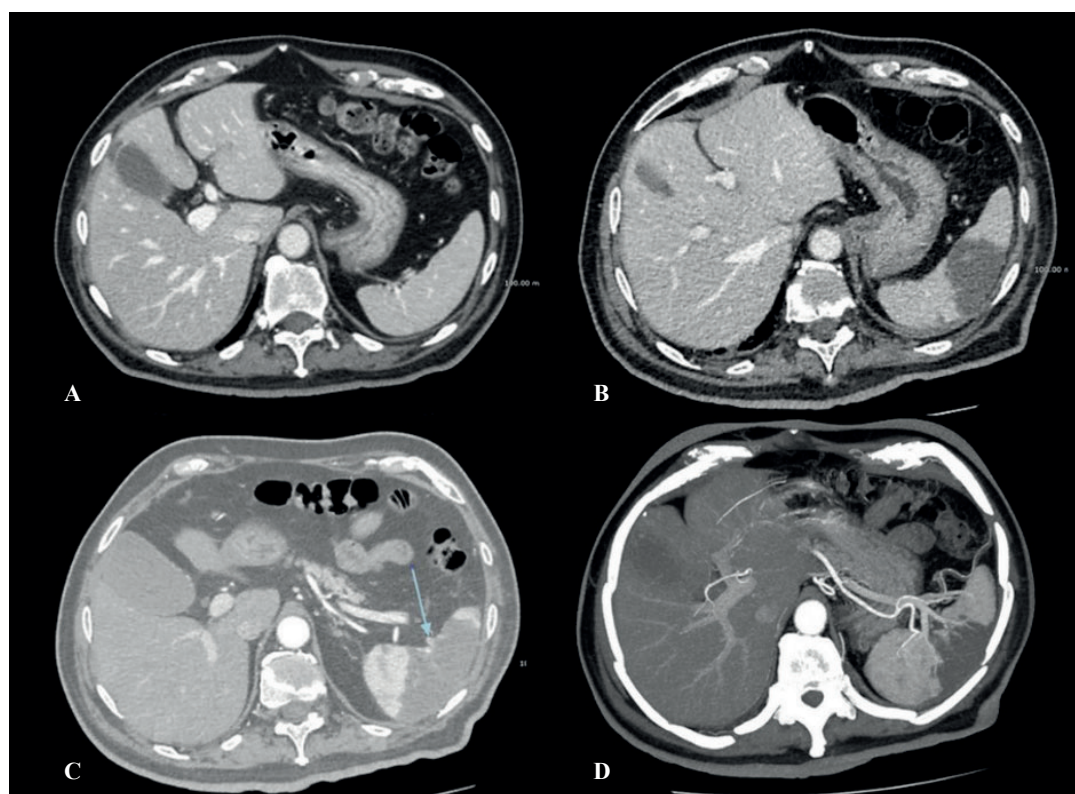
Suspecting a cardiac source of embolization (Septal Defects? Paroxysmal Atrial Fibrillation?) the patient underwent Echocardiography and prolonged (72 hours) Holter ECG, both resulting normal.

On day 9 of hospital stay, the persisting anorexia and nausea, leading the patient to significant weight loss and reduced ability to concentrate with psychomotor retardation, induced us to rule out cancer diagnoses. Thus, a contrast-enhanced total body CT was performed. This test showed coeliac artery occlusion with splenic infarction (Figure 1), and mesenteric panniculitis (not requiring surgical attention).

Blood test [homocysteine, lupus anti-coagulant antibodies (LAC), beta-2 glycoprotein antibodies, anti-nuclear antibody (ANA), anti-neutrophil cytoplasmic antibodies (ANCA), IgG4, CA 125, CA 19.9, CEA, PSA total and free, NSE] gastric and colon endoscopy were negative mak-

**Table II.** Laboratory findings on admission.

Laboratory analysis	Day 0
Haemoglobin (g/dL)	15.5
Platelet count (x 10 <sup>9</sup> /L)	244
Leukocytes (x 10 <sup>9</sup> /L)	5.170
Neutrophil (%)	58.1
Absolute neutrophil (x 10 <sup>9</sup> /L)	2.9
Lymphocyte (%)	28.6
Partial thromboplastin time (sec)	30
Prothrombin time (INR)	1.21
D-dimer (µg/mL)	4.84
Fibrinogen (mg/dL)	734
Aspartate aminotransferase (U/L)	19
Alanine aminotransferase (U/L)	44
Total Cholesterol (mg/dL)	88
HDL Cholesterol (mg/dL)	22
LDL Cholesterol (mg/dL)	42
Triglycerides (mg/dL)	133
Glucose (mg/dL)	164
HBA1C (%)	6.4
Creatinine (mg/dL)	1.48
Amylase (U/L)	123
Lipase (U/L)	120
Pancreatic Amylase (U/L)	105
PCR (mg/L)	237.2



**Figure 1.** Contrast-enhanced CT at admission (A) shows a normal spleen; after 9 days, a large spleen infarction is evident (B) that is attributable to arterial obstruction (indicated by arrow in panel C), confirmed by Maximum Intensity Protection -MIP – reconstruction (D).

ing unlikely the presence of autoimmune disease, vasculitis, or primary coagulation disorders.

On the same day (day 9), suspecting an unusual VITT (absence of thrombocytopenia and PF4 negative), the patient underwent treatment with intravenous immune globulin (0.4 g/Kg/die), Methylprednisolone 80 mg once daily (1 mg/kg/die) and Fondaparinux 7.5 mg once daily.

During the last two weeks of hospitalization, the patient had been under close clinical observation, and he started physical/motor rehabilitation to prevent loss of motor function; he also started the intravenous steroid tapering. On day 29 the patient felt better and was discharged at home.

After the hospital discharge, it was possible to perform the anti-PF $\beta$  antibody assay (ASSE-RACHROM HPIA IgG; absorbance at 405 nm, 0.063 e 1.478 for negative or positive case, respectively) on the blood sample drawn on July 28<sup>th</sup> – prior to any treatment indicated for VITT. The assay was frankly positive.

At an outpatient follow-up visit approximately 30 days after hospital discharge, the patient was in good general condition, feeding normally (3 kg

of weight gain), denying abdominal pain, with a walking autonomy of 50-100 meters. Ultrasound control showed good patency of the right common and deep femoral artery. Nevertheless, complete obstruction of the right superficial femoral artery and the popliteal artery was still evidenced, with the resumption of blood flow in the anterior tibial artery which appeared to be free.

## Discussion

At the beginning of September 2021, the Italian Network of Pharmaco-vigilance reported a total of 1242 adverse reactions out of approximately 2 million doses of COVID-19 vaccine Janssen administered. Of those, 255 were recognized as serious, 953 not serious and 24 were fatal. Among these, our case was the first and only report of splenic infarction, arterial embolism, and thrombosis of celiac artery.

On the 3<sup>rd</sup> of September 2021, the EudraVigilance, available at [www.adrreports.eu](http://www.adrreports.eu), contains 1565 thromboembolic events (ADRs) across Eu-

rope following the use of the Janssen vaccine; despite the report of 7 events of spleen infarction, no cases of celiac artery embolism or thrombosis has been reported.

USA's ADRs are published on the Vaccine Adverse Events Reporting System (VAERS), available at [vaers.hhs.gov](http://vaers.hhs.gov); on the 3<sup>rd</sup> of September 2021 there are 713 thromboembolic events related to Janssen vaccine, of which 5 splenic infarction events and 3 arterial embolisms are listed.

These data confirm once more the safety of COVID-19 vaccination. Contemporarily, they support the unusual presentation of the adverse reaction to COVID-19 vaccines presented by the case here reported.

The COVID-19 pandemic required and is still requiring new learning, including the more and more frequent reports of unusual clinical presentation<sup>4</sup>. This also concerns the adverse reaction to vaccination: the impact on the thrombosis and hemostasis system includes also hemophilia, as well as cerebral arterial thrombosis<sup>5,6</sup> – though venous and arterial thrombosis recognize different pathways of activation<sup>7</sup>.

The first and major unusual clinical presentation of the adverse reaction to COVID-19 vaccine illustrated by the recent case consist of the arterial and embolic nature of the (multiple) organ damage.

Underlying causes of diffuse arterial thrombosis are usually related to embolic phenomenon secondary to atrial fibrillation, or atherosclerotic plaque rupture, solid organ malignancies, myeloproliferative neoplasms, vasculitis, and coagulation disorder as antiphospholipid antibody syndrome and hyperhomocysteinemia<sup>7,8</sup>. Tests for heritable thrombophilia (Factor V Leiden, Prothrombin G20210A mutation, and deficiencies of Protein C, Protein S, or Antithrombin) are not indicated<sup>8</sup>. We gradually exclude all these etiologies in our patient. Ultrasounds and CT angiography showed healthy arteries without significant atherosclerotic plaques. Echocardiography and Holter ECG excluded atrial fibrillation. Cancer as well was ruled out. Prothrombotic screening for artery thrombosis with normal arterial blood vessels typically relies on the assay of antiphospholipid syndrome, hyperhomocysteinemia, and fibrinogen<sup>7-9</sup>. All these factors were not present in our patient.

In our case, arterial embolisms in unusual sites (mesenteric panniculitis, splenic infarction and left renal ischemia, acute subclavian artery occlusion, and subacute superficial femoral artery occlusion), was suggestive for VITT<sup>10-12</sup>.

VITT typically manifests in women aged 18-49 years, approximately 5-30 days after vaccination with cerebral or venous thromboses; arterial thromboses have also been reported, though they are rare<sup>10-14</sup>.

The pathophysiology of VITT has been hypothesized to be mediated by immunoglobulin G (IgG) antibodies that recognize PF4 and activate platelets through their FcγIIa receptors. The use of intravenous immune globulin paralleled its efficacy in the treatment of autoimmune heparin-induced thrombocytopenia (aHIT – a thrombocytopenic disorder caused by the formation of IgG antibodies against PF4, upon exposure to heparin<sup>15</sup>) because it inhibits platelet activation<sup>10</sup>. It is important not to use intravenous immune globulin (IVIG) batches obtained from the plasma collected during the SARS-CoV-2 pandemic, to avoid from reducing the vaccine efficacy and induce vaccination failure in these patients<sup>16</sup>.

At the moment, the pathogenic mechanism of VITT is unclear. To date, VITT has been described only related to adenoviral vector-based DNA virus vaccines, thus implying that the syndrome could be related to the vector or other constituents in the vaccine preparation<sup>15</sup>. De Bruijn et al<sup>17</sup> recently reported the first episode of immune-mediated thrombotic thrombocytopenic purpura associated with an mRNA-based anti- COVID-19 vaccination. Othman et al<sup>15</sup> recently reported seven potential mechanisms concerning adenovirus induction of VITT, from the binding of adenovirus to platelets or anticoagulation factors, to vaccine-induced COVID mimicry, to link of adenovirus capsid to PF4, to impurities in vaccine preparation triggering autoantibodies, to possible acute infection with SARS-CoV-2 following vaccine administration. During the recovery, the patient was periodically tested for COVID-19 infection using molecular PCR test on nasal swab; all tests were negative.

At hospital admission, PF4 antibodies were measured using the rapid assay HemosIL HIT-Ab<sub>(PF4-H)</sub> and they were negative (< 1 U/mL). Platon et al<sup>18</sup> remarked that these kits have a high sensitivity for HIT, but they have poor sensitivity for VITT in comparison to ELISA, which was not available in our laboratory at that time. Subsequently, ELISA assay was positive for anti-PF4 antibodies. Therefore, the patient had 4 out of 5 criteria for VITT. Notably, thrombocytopenia was not observable in our patient, though it is considered a typical feature of VITT.

Nevertheless, because of strong suspicion of VITT, the patient received usual therapy based on

intravenous immune globulin (0.4 g/Kg/die) for 5 days, Methylprednisolone 80 mg once daily (1 mg/kg/die) for a week, and Fondaparinux 7.5 mg once a day<sup>19,20</sup>.

After VITT treatment had finished, the patient had no new thromboembolic events, and his clinical conditions slowly get better with the disappearance of nausea, improvement of appetite, and weight gain (3 kg after discharge). He hasn't yet fully regained physical fitness, still presenting claudication after 50-100 meters of walk.

At the moment, there is not enough evidence to establish a causal relationship between these events and the Janssen vaccine.

## Conclusions

An increase in vigilance regarding extremely rare side effects associated with COVID-19 vaccination is needed. VITT is a serious complication of vaccination that is not possible to predict or prevent and that can occur also in the absence of thrombocytopenia. When patients, among 5-30 days post-vaccination, begin to manifest sustained headache, neurologic symptoms/signs, abdominal pain, dyspnea, or limb pain/swelling, platelet count, D-dimer, and PF4 must be measured, and imaging for thrombosis performed<sup>14</sup>.

Reporting unusual adverse events of the vaccinations is crucial to help clinicians better understand the long-term outcomes.

## Acknowledgments

V. Murru, V. Cocco, C. Marras, A. Sestu gratefully acknowledge the Autonomous Region of Sardinia (RAS) for the financial support of their specialist medical training in Internal Medicine.

All Authors have given approval of the submitted and final versions.

## Author's Contribution

V. Murru drafted the paper and contributed to acquisition and interpretation of data.

V. Cocco revised the paper and contributed to acquisition and interpretation of data.

C. Marras revised the paper and contributed to acquisition and interpretation of data.

A. Sestu revised the paper and contributed to acquisition and interpretation of data.

F. Marongiu revised the paper and contributed to acquisition and interpretation of data.

L. Saba revised the paper and contributed to acquisition and interpretation of data.

M.E. Cianchetti revised the paper and contributed to acquisition and interpretation of data.

A. Scuteri revised the paper and contributed to interpretation of data.

## Conflict of Interests

The authors declare that they have no conflict of interests.

## References

- 1) Ministero della Salute. Covid-19 - Situazione nel mondo. Accessed September 27, 2021. <http://www.salute.gov.it/portale/nuovocoronavirus/dettaglioContenutiNuovoCoronavirus.jsp>
- 2) European Medicine Agency. COVID-19 Vaccine Janssen. Accessed September 27, 2021. <https://www.ema.europa.eu/en/human-regulatory/overview/public-health-threats/coronavirus-disease-covid-19/treatments-vaccines/vaccines-covid-19/safety-covid-19-vaccines>
- 3) Abbattista M, Martinelli I, Peyvandi F. Comparison of adverse drug reactions among four COVID-19 vaccines in Europe using the EudraVigilance database: thrombosis at unusual sites. *J Thromb Haemost* 2021; 19: 2554-2558.
- 4) Hunt B. Education of healthcare professionals and the public about thrombosis and COVID-19. *J Thromb Haemost* 2021; 19: 2369-2371.
- 5) Radwi M, Farsi S. A case report of acquired hemophilia following COVID-19 vaccine. *J Thromb Haemost* 2021; 19: 1515-1518.
- 6) Blauenfeldt RA, Kristensen SR, Ernstsens SL, Kristensen CCH, Simonsen CZ, Hvas AM. Thrombocytopenia with acute ischemic stroke and bleeding in a patient newly vaccinated with an adenoviral vector-based COVID-19 vaccine. *J Thromb Haemost* 2021; 19: 1771-1775.
- 7) Previtali E, Bucciarelli P, Passamonti SM, Martinelli I. Risk factors for venous and arterial thrombosis. *Blood Transfus* 2011; 9: 120-138.
- 8) O'Donnell M, Shatzel JJ, Olson SR, Daughety MM, Nguyen KP, Hum J, DeLoughery TG. Arterial thrombosis in unusual sites: a practical review. *Eur J Haematol* 2018; 101: 728-736.
- 9) Gavrış CM, Nedelcu LD, Pascu AM. Thrombotic risk in antiphospholipidic syndrome: from hypothesis to current evidence (Review). *Exp Ther Med* 2021; 21: 1-4.
- 10) Greinacher A, Thiele T, Warkentin TE, Weisser K, Kyrle PA, Eichinger S. Thrombotic Thrombocytopenia after ChAdOx1 nCov-19 Vaccination. *N Engl J Med* 2021; 384: 2092-2101.
- 11) Schultz NH, Sørvoll IH, Michelsen AE, Munthe LA, Lund-Johansen F, Ahlen MT, Wiedmann M, Aamodt AH, Skattør TH, Tjønnfjord GE, Holme PA. Thrombosis and thrombocytopenia after ChAdOx1 nCoV-19 Vaccination. *N Engl J Med* 2021; 384: 2124-2130.
- 12) Scully M, Singh D, Lown R, Poles A, Solomon T, Levi M, Goldblatt D, Kotoucek P, Thomas W,

- Lester W. Pathologic antibodies to platelet factor 4 after ChAdOx1 nCoV-19 vaccination. *N Engl J Med* 2021; 384: 2202-2211.
- 13) Favaloro EJ. Laboratory testing for suspected COVID-19 vaccine-induced (immune) thrombotic thrombocytopenia. *Int J Lab Hematol* 2021; 43: 559-570.
- 14) Iba T, Levy JH, Warkentin TE. Recognizing vaccine-induced immune thrombotic thrombocytopenia. *Crit Care Med* 2021; 13: 1-7.
- 15) Othman M, Baker AT, Gupalo E, Elsebaie A, Bliss CM, Rondina MT, Lillicrap D, Parker AL. To clot or not to clot? Ad is the question - insights on mechanisms related to vaccine-induced thrombotic thrombocytopenia. *J Thromb Haemost* 2021; 19: 2845-2856.
- 16) Karnam A, Lacroix-Desmazes S, Kaveri S V., Bayry J. Vaccine-induced immune thrombotic thrombocytopenia: consider IVIG batch in the treatment. *J Thromb Haemost* 2021; 19: 1838-1839.
- 17) de Bruijn S, Maes MB, De Waele L, Vanhoorelbeke K, Gadisseur A. First report of a de novo iTTP episode associated with an mRNA-based anti-COVID-19 vaccination. *J Thromb Haemost* 2021; 19: 2014-2018.
- 18) Platton S, Bartlett A, MacCallum P, Makris M, McDonald V, Singh D, Scully M, Pavord S. Evaluation of laboratory assays for anti-platelet factor 4 antibodies after ChAdOx1 nCoV-19 vaccination. *J Thromb Haemost* 2021; 19: 2007-2013.
- 19) Marongiu F, Barcellona D. Trombocitopenia trombotica indotta da vaccino: gli algoritmi per gestirla. *Anticoagulazione.it* 2021.
- 20) Nazy I, Sachs UJ, Arnold DM, McKenzie SE, Choi P, Althaus K, Ahlen MT, Sharma R, Grace RF, Bakchoul T. Recommendations for the clinical and laboratory diagnosis of VITT against COVID-19: communication from the ISTH SSC subcommittee on platelet immunology. *J Thromb Haemost* 2021; 19: 1585-1588.