

Early ultrasonographic diagnosis of placental mesenchymal dysplasia

S. GERLI, C. GIORDANO, R. DEL SORDO¹, D. FRATINI¹, G.C. DI RENZO

Department of Surgical and Biomedical Sciences, Division of Obstetrics and Gynecology, University of Perugia, Perugia, Italy

¹Institute of Pathological Anatomy and Histology, University of Perugia, Perugia, Italy

Abstract. – Placental mesenchymal dysplasia (PMD) is a rare pathology characterized by vascular anomalies, placentomegaly and grape-like vesicles resembling partial molar pregnancy. PMD is often associated with fetal growth restriction or intrauterine fetal demise.

We report a case of an early diagnosis of PMD at 10 weeks' gestation, with a regular intrauterine growth and a fetal demise occurring at 31 week's gestation. The placenta showed aneurysmally dilated and tortuous vessels with luminal thrombosis.

Even in presence of a regular fetal growth, a fetal demise may always occur, suggesting the option of an early heparin administration to reduce the risk of thrombosis of chorionic vessels.

Key Words:

Placental mesenchymal dysplasia, Ultrasonographic diagnosis.

Introduction

Placental mesenchymal dysplasia (PMD) is a rare placental vascular anomaly characterized by placentomegaly and grapelike vesicles resembling partial molar pregnancy by ultrasonography and by gross placental examination. The pathology is characterized by aneurysmal dilatation of vessels on the fetal surface of the placenta, with dilated stem villi and, in contrast to molar pregnancies, no trophoblastic proliferation.

The true incidence of PMD is unknown because it has been previously reported under a variety of names such as "placentomegaly with massive hydrops of placental stem villi" and "pseudopartial moles"^{1,2}. It was initially described by Moscoso et al³ in 1991 as stem villous hyperplasia when they identified two cases with elevated maternal serum alpha fetoprotein levels and enlarged placentas with corresponding ultrasonographic features suggestive of partial mole.

There were aneurysmally dilated vessels on the fetal surfaces of the placentas and dilated stem villi filled with clear gelatinous material in the subchorionic region. Histologically, however, these placentas could be distinguished from partial moles because of the absence of trophoblastic proliferation.

Although PMD is generally accepted as a rare entity, there has been an increasing number of case series^{2,4-6} and case reports^{7,8} in recent literature regarding this condition. Arizawa and Nakayama⁹ found a prevalence of only 0.02% among 30758 placentas examined over a 21 year period.

Placental mesenchymal dysplasia is associated with Beckwith- Wiedemann syndrome (BWS) and fetal growth restriction (IUGR) in the majority of the cases or intrauterine fetal demise (IUID), but can also be associated with normal-appearing fetuses. Approximately one quarter of the reported cases of PMD is associated with fetal BWS^{1,4-6}. Umazume et al⁷ described a case of early diagnosis of PMD at 8th weeks' gestation.

This report represents the second case of PMD early diagnosis at 10 weeks' gestation. Although a close ultrasound fetal monitoring was performed and a regular intrauterine growth was observed, intrauterine fetal demise occurred at 31 week's of gestation.

Case Report

A 33-year-old, gravida 3, para 0, was referred to the Department of Obstetrics and Gynecology, University of Perugia, Italy, in July 2012. The patient at 31 weeks' gestation had a physiological personal history with a previous early miscarriage. Antenatal ultrasound screening performed at 10 weeks' gestation was suggestive for "mounted in snow" trophoblastic tissue (Figure 1A). In order to exclude a molar pregnancy a quantitative β -hCG was determined showing a value within normal limits (110.450 mU/ml).

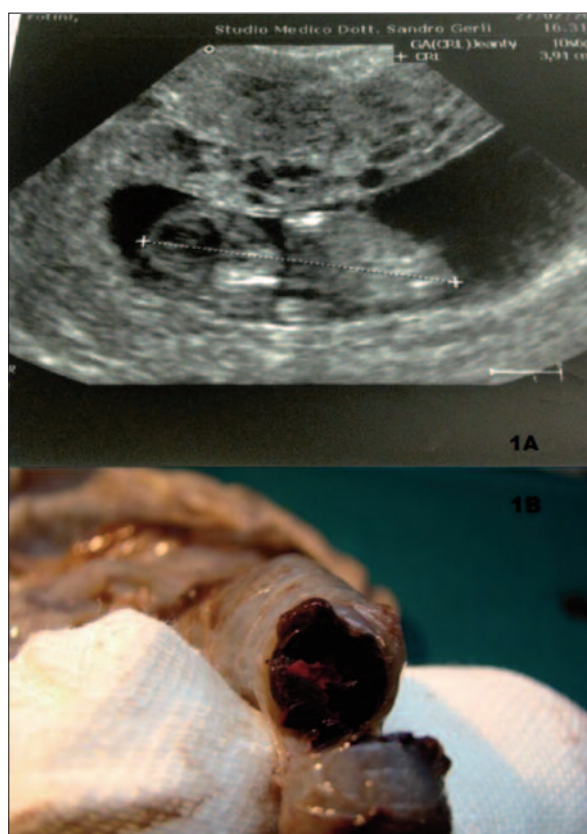


Figure 1. *A*, Transabdominal ultrasonographic study at 10 weeks' gestation showing a placenta with multiple hypoechoic cysts, suggestive of a partial hydatidiform mole. *B*, The fetal surface showed aneurysmally dilated and tortuous vessels measuring up to 3 cm in diameter with abnormal branching and with or without luminal thrombosis.

Chorionic villous sampling (CVS) was performed at 13 weeks' gestation, revealing a normal male karyotype. The fetus had an apparent normal morphology and a retarded growth up to 23 weeks' gestation. An increased size of placenta with multiple anechoic areas were noted. The pregnancy follow-up did not show any significant abnormality: pregnancy induced hypertension, gestational diabetes were not diagnosed. A close ultrasound monitoring of fetal well-being was performed and an improvement in growth was revealed during the following weeks up to 31st weeks' gestation, with a partial reduction of placental anechoic areas. A 75 centile fetal growth was registered at 29 weeks. Suddenly fetal intrauterine demise occurred at 31 weeks. In relation to patient's choice a cesarean section was performed and a stillborn male of 1790 g was delivered. Placenta weight was 800 g, characterized by multiple cystic tumors on the surface.

The fetal karyotype was normal male. The autopsy findings were of fetus weighing 1800 g with no malformations on external or internal examination.

The placenta was markedly enlarged, weighed 800 g and measured 20 × 25 × 3.5 cm. The umbilical cord measured 40 cm in length, 1.2 cm in diameter and contained three vessels. It was tortuous and markedly right-twisted and had a velamentous and branched insertion. The fetal surface showed aneurysmally dilated and tortuous vessels measuring up to 3 cm in diameter with abnormal branching and with or without luminal thrombosis (Figure 1b).

On the maternal plate there were grape-like cystic vesicles mixed with villi of normal appearance.

The cut surface showed multiple small cysts scattered in all the placenta and heterogeneous areas of abnormal tan and gelatinous parenchyma, adjacent to apparent normal red-brown and spongy parenchyma.

The placenta was systematically sampled, fixed in 10% buffered formalin and embedded in paraffin. The 4- μ m tissue sections were stained with hematoxylin and eosin. Immunostains for vimentin (clone V9, ready to use, Leica/Menarini), desmin (clone DE-R-11, ready to use, Leica/Menarini), smooth muscle actin (clone asml, ready to use, Leica/Menarini), D2-40 (clone D2-40, dilution 1:200, Dako, Glostrup, Denmark) and CD31 (clone JC70A, ready to use, Dako,) were performed on selected sections.

The primary antibody was detected using a biotin-free polymeric-horseradish peroxidase (HRP)-linker antibody conjugate system (Bond Polymer Refine Detection, Vision Systems Ltd, Melbourne, Australia) with a heat-induced epitope retrieval, conducted with the Bond Max automated immunostainer (Vision BioSystems Ltd, Melbourne, Australia).

Microscopically variable villous maturation was present, ranging from mature with increased syncytial knotting to enlarged stem villi. The later showed the dilated, muscularized chorionic vessels contained organized thrombi, surrounded by markedly myxomatous stroma. The thick-walled vessels showed focally fibrinoid necrosis. Villous stromal cystic degeneration, forming cisterns simulating those in molar villi, has been found focally. No abnormal trophoblastic proliferation was observed in any of the sections examined. The cisternal lining cells in dysplastic villi were positive for vimentin, desmin, D2-40 and negative for smooth muscle actin and CD31.

Discussion

The underlying cause of PMD is currently unknown. It has been hypothesized that PMD is a congenital malformation of the mesoderm. This theory is based on observations of mesenchymal hyperplasia in stem villi along with other placental mesenchymal proliferative disorders such as chorangiomas and chorionic vessel dilatation as well as hemangiomas of the fetus. In addition, the enlarged stem villi contain acid mucopolysaccharide, which is found in the connective tissue layers of the normal chorionic mesoderm¹⁰.

Many genetic anomalies are evocated to explain PMD, such as anomalies in imprinting genes on chromosome 11 or androgenetic/biparental mosaicism due to endo-reduplication of the haploid paternal genome; or anomalies in X chromosome, as PMD is characterized by vascular malformations and VEGF gene is just located in Xp22.31. These hypotheses can explain the predominance in females, as the 46, YY cell lines are incompatible with life⁹.

Two different genes have been proposed for the development of PMD, VEGF-D and IGF-2 that are involved in lymphangiogenesis⁹. It has been reported that placental tissue expresses many lymphatic markers¹¹, but the role of an abnormal lymphangiogenesis in PMD is controversial¹². Recently Heazell et al¹³ showed that the cisternae in stem villi of PMD are structurally similar to lymphatic channels and cells lining were labelled with D2-40 that is a lymphatic endothelial marker. Kotani et al¹⁴ demonstrated that D2-40 was positive in the stromal cells around the cistern, but VEGFR-3, the main lymphatic endothelial growth factor receptor, was expressed in the lining of the cistern. Castro et al¹² demonstrated that no lymphatic vasculature is present in the chorionic villi during the development, or at term or in selected edematous placental disorders. The cisternal lining cells are not endothelial cells but they could be originated from stromal cells. In this case D2-40, vimentin and desmin have been expressed in stromal cells in the villi. This finding is consistent with the hypothesis that abnormal gene expression in PMD alter local hormonal sensitivity and lead to differences in placental villus mesenchymal phenotype.

There is no specific clinical symptomatology associated with PMD. Most cases of PMD in early pregnancy are diagnosed by prenatal ultrasonography done either for routine prenatal

checkup or because of an abnormal amniocentesis result. The most common abnormal laboratory test includes increased level of maternal serum alpha fetoprotein, which is thought to be of fetal origin. It has been assumed that the increase in the surface transfer area because of increased placental volume and increased vessels within the stem villi may lead to increase transfer of alpha fetoprotein (AFP) into the maternal circulation³. The level of β -human chorionic gonadotropin is normal to slightly increased but returns to normal levels soon after delivery^{2,4}. Later in the pregnancy, the patient usually presents intrauterine growth restriction or fetal demise. Although most of the fetuses associated with PMD are structurally normal and shows no developmental problems on follow up, complications like intrauterine growth restriction, fetal anemia, thrombocytopenia, prematurity and intrauterine fetal death had been reported^{6,15-17}. Sander et al¹⁵ postulated that the growth retardation seen in these patients may be due to the diversion of fetal blood within the vascular malformation complex from the maternal intervillous space, and the occurrence of anemia or thrombocytopenia could be due to a microangiopathic process related to thrombosis within the malformed vessels. Højberg et al¹⁸ attributed the low birth weight, anemia, intrauterine growth and high maternal serum AFP to the relative placental insufficiency and vascular leakage.

Patients may also present polyhydramnios if the fetus has swallowing difficulty as part of BWS. Many cases are asymptomatic and are diagnosed postpartum because of delivery of an abnormally large placenta.

A 5-year follow-up of mothers with PMD showed no sign of trophoblastic disease or recurrence of PMD in subsequent pregnancies¹⁹.

The sonographic features of PMD are very similar to those of partial moles³, and are generally evidenced between 15-17 week's of gestation. In the described case we report an early diagnosis where PMD was suspected at 10 weeks' of gestation. A thickened placenta with hypoechoic spaces are classical sonographic findings of both PMD and molar pregnancies. It is important to distinguish PMD from molar pregnancy because it may avoid unnecessary termination of pregnancy especially if prenatal ultrasonographic examination shows features suggestive of molar pregnancy in the presence of a normal-appearing fetus. The main differential diagnoses of PMD, both clinically and pathologically, are partial hy-

datidiform moles, a twin gestation with complete mole, spontaneous abortion with hydropic changes, and confined placental mosaicism. Unlike partial moles, the placenta in PMD is almost always diploid (except in rare instances), and histologically the villi do not show proliferation of trophoblast or stromal trophoblastic inclusions. The triploid fetus associated with a partial mole shows growth restriction with a variety of external and internal defects. In twin gestations with complete moles, the abnormal fetal vessels in the stem villi characteristic of PMD are absent even though the fetus may have a diploid karyotype.

Gizzo et al⁸ described a case of PMD with favorable neonatal outcome, performing close sonographic monitoring of fetal well being. A close sonographic monitoring of fetal well-being has been recommended by several authors in order to guarantee a positive outcome^{12,20}.

In this case, although an early diagnosis of PMD has been made with ultrasound, a CVS was performed confirming a normal male karyotype and a regular intrauterine fetal growth was registered, IUFD unexpectedly occurred. The causes of IUFD is currently unclear and may be heterogeneous. Thrombosis of chorionic vessels and umbilical cord anomalies are thought to be likely causes of IUFD in PMD cases, and Truc et al. reported that IUFD may be explained by a potentially chronic hypoxia secondary to obstructive fetal vascular thrombosis with a decrease in maternal-fetal gas exchange as a result of an insufficient amount of normal chorionic villi and the shunting of blood from the exchange surface in chorioangiomas and dysplastic villi²¹.

Conclusions

This evidence suggests that an early sonographic diagnosis of PMD can be made. Even in presence of a regular fetal growth, a fetal demise can always occur, probably due to vascular thrombosis, suggesting the possibility of an early heparin administration to reduce the risk of thrombosis of chorionic vessels. Additional clinical evidences in a greater case-series of patients are needed to redefine the pathology and to guarantee a better outcome of the pregnancy.

Conflict of Interest

The Authors declare that there are no conflicts of interest.

References

- 1) LAGE JM. Placentomegaly with massive hydrops of placental stem villi, diploid DNA content and fetal omphaloceles: possible association with Beckwith-Wiedemann syndromes. *Hum Pathol* 1991; 22: 591-597.
- 2) PARADINAS FJ, SEBIRE NJ, FISHER RA, REES HC, FOSKETT M, SECKL MJ, NEWLANDS ES. Pseudo-partial moles: placental stem vessel hydrops and the association with Beckwith-Wiedemann syndrome and complete moles. *Histopathology* 2001; 39: 447-454.
- 3) MOSCOSO G, JAUNIAUX E, HUSTIN J. Placental vascular anomaly with diffuse mesenchymal stem villous hyperplasia: a new clinico-pathological entity? *Pathol Res Pract* 1991; 187: 324-328.
- 4) COHEN MC, ROPER EC, SEBIRE NJ, STANEK J, ANUMBA DO. Placental mesenchymal dysplasia associated with fetal aneuploidy. *Prenat Diagn* 2005; 25: 187-192.
- 5) CHAN YF, SAMPSON A. Placental mesenchymal dysplasia: a report of four cases with differentiation from partial hydatidiform mole. *Aust N Z J Obstet Gynaecol* 2003; 43: 475-479.
- 6) JAUNIAUX E, NICOLAIDES KH, HUSTIN J. Perinatal features associated with placental mesenchymal dysplasia. *Placenta* 1997; 18: 701-706.
- 7) UMAYUMI T, KATAOKA S, KAMAMUTA K, TANUMA F, SUMIE A, SHIROGANE T, KUDOU T, IKEDA H. Placental mesenchymal dysplasia, a case of intrauterine sudden death of fetus with rupture of cirsoid periumbilical chorionic vessels. *Diagn Pathol* 2011; 6: 38-45.
- 8) GIZZO S, DI GANGI S, PATRELLI TS, SACCARDI C, D'ANTONA D, NARDELLI GB. Placental mesenchymal dysplasia: can early diagnosis ensure a good maternal-foetal outcome? A case report. *Arch Gynecol Obstet* 2012; 286: 15-17.
- 9) ARIZAWA M, NAKAYAMA M. Suspected involvement of the X chromosome in placental mesenchymal dysplasia. *Congenit Anom* 2002; 42: 309-317.
- 10) CHEN CP, CHERN SR, WANG TY, HUANG ZD, HUANG MC, CHUANG CY. Pregnancy with concomitant chorangioma and placental vascular malformation with mesenchymal hyperplasia. *Hum Reprod* 1997; 12: 2553-2556.
- 11) WANG Y, SUN J, GU Y, ZHAO S, GROOME LJ, ALEXANDER JS. D2-40/podoplanin expression in the human placenta. *Placenta* 2011; 32: 27-32.
- 12) CASTRO E, TONY PARKS W, GALAMBOS C. Neither normal nor diseased placentas contain lymphatic vessels. *Placenta* 2011; 32: 310-316.
- 13) HEAZELL AEP, SAHASRABUDHE N, GROSSMITH AK, MARTINDALE EA, BHATIA K. A case of intrauterine growth restriction in association with placental mesenchymal dysplasia with abnormal placental lymphatic development. *Placenta* 2009; 30: 654-657.
- 14) KOTANI T, SUMIGAMA S, TSUDA H, MANO Y, YAMAMOTO E, IWASE A, SHIMOYAMA Y, NAGASAKA T, HAYAKAWA

- H, YAMAMOTO T, INO K, KIKKAWA F. A case report of placental mesenchymal dysplasia with an increased VEGF-D expression. *Placenta* 2012; 33: 888-891.
- 15) SANDER CM. Angiomatous malformation of placental chorionic stem vessels and pseudopartial molar placentas: a report of Wve cases. *Pediatr Pathol* 1992; 13: 621-633.
- 16) PHAM T, STEELE J, STAYBOLDT C, CHAN L, BENIRSCHKE K. Placental mesenchymal dysplasia is associated with high rates of intrauterine growth restriction and fetal demise. *Am J Clin Pathol* 2006; 126: 67-78.
- 17) NAYERI UA, WEST AB, GROSSETTA NARDINI HK, COPEL JA, SFAKIANAKI AK. Systematic review of sonographic findings of placental mesenchymal and subsequent pregnancy outcome. *Ultrasound Obstet Gynecol* 2013; 41: 366-374.
- 18) HOJJBORG KE, AAGAARD J, HENRIQUES U, SUNDE L. Placental vascular malformation with mesenchymal hyperplasia and a localized chorangioma. A rarity simulating partial mole. *Pathol Res Pract* 1994; 190: 808-813.
- 19) MATSUI H, IITSUKA Y, YAMAZAWA K, TANAKA N, MITSUHASHI A, SEKI K, SEKIYA S. Placental mesenchymal dysplasia initially diagnosed as partial mole. *Pathol Int* 2003; 53: 810-813.
- 20) JALIL S SA, MAHRAN AM, SULE M. Placental mesenchymal dysplasia--can it be predicted prenatally? A case report. *Prenat Diagn* 2009; 29: 713-714.
- 21) TRUC P, JULIE S, CARLA S. Placental mesenchymal dysplasia is associated with high rates of intrauterine growth restriction and fetal demise. A report of 11 new cases and a review of the literature. *Am J Clin Pathol* 2006, 126: 67-78.