

# Application of minimally invasive 23G vitrectomy via corneal approach for the treatment of pediatric cataract

S.-Y. LI, Z.-P. ZHANG, S.-J. JI, H.-Y. LIU, M.-Y. SI, K.-S. FAN

Eye Institute of Xuzhou, Jiangsu, China

**Abstract. – OBJECTIVE:** To determine the curative effect and complications of 23G vitrectomy via corneal approach for the treatment of pediatric cataract.

**MATERIALS AND METHODS:** We performed anterior circular capsulotomy, lentectomy and aspiration, posterior circular capsulotomy, and anterior vitrectomy via corneal approach in 40 eyes from 25 children with congenital cataract. In patients aged > 2 years, foldable intraocular lens (IOL) was implanted and frame glasses were prescribed at younger age. The intraoperative/postoperative complications, comfort level, and inflammatory reaction after surgery were observed.

**RESULTS:** No intraoperative complications occurred and 9 eyes were simultaneously implanted IOL. All patients could blink normally except one child who suffered from corneal epithelial abrasion for one day. All corneas were clear and only mild postoperative inflammation was observed. There was no hyphema, effusion, hypotony, and hypertension. A week later, the mild congestion also disappeared. All parents reported good vision of their babies allowing them free play during 3-50 months follow-up. This surgical technique provided a clear 4-6 mm diameter visual axis and circular pupil in all cases. The IOL positions were centered at the pupil area. No secondary cataract developed.

**CONCLUSIONS:** The 23-gauge vitrectomy via corneal approach for the treatment of pediatric cataract involves only mild discomfort and fewer complications.

*Key Words:*

23G, Vitrectomy, Pediatric, Cataract.

## Introduction

Posterior capsule opacification (PCO) is rapid and virtually inevitable in very young children when adult-style cataract surgery is performed and the posterior capsule is left intact. In eyes with pediatric cataract, primary posterior capsu-

lotomy and vitrectomy are considered routine surgical steps, especially in younger children. The traditional surgical method involves removal of the anterior capsule by curvilinear capsulorhexis, aspirating the cortex of the lens and sequentially performing posterior circular capsulorhexis or anterior vitreous removal<sup>1,2</sup>. In recent years, a few attempts have been made to treat the infantile cataract by crystalline resection using the minimally invasive vitrectomy<sup>3-5</sup>. Herein, we treated 40 pediatric cataracts in 25 patients using 23G minimally invasive vitrectomy via the corneal incision at our hospital during the time period from October 2007 to July 2012. In this procedure, the anterior lens capsule is circularly incised, cortex is aspirated, and the posterior capsule is circularly incised combined with front part vitreous humor vitrectomy. This method is minimally invasive, causes mild postoperative inflammatory reaction, involves fewer complications and has good efficacy.

## Patients and Methods

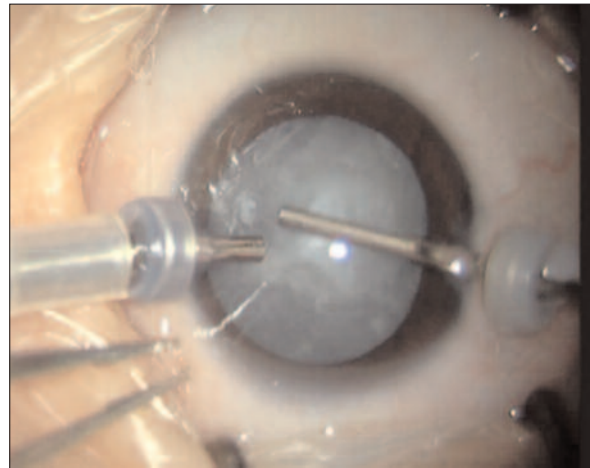
### *Patients*

The study was conducted on 40 eyes from 25 children. Of them, 26 eyes were from 16 boys and 14 eyes were from 9 girls. The average age was  $20.76 \pm 27.80$  (range: 3-120) months. Six patients, 4 with bilateral and 2 with monocular cataract, had preterm and oxygen-uptake history. At preoperative examination, no sign of premature baby retinopathy was found. In two patients, bilateral congenital cataract was associated with atrial septal defects and one of them was combined with hypoxic encephalopathy. One patient had monocular cataract with leucoma and congenital aniridia, 4 patients had strabismus in 6 eyes, 2 patients had nystagmus, and 1 patient had mental retardation associated with ptosis and strabismus. One case that had bilateral cataract

was associated with congenital iridocoloboma and coloboma of choroid in both eyes and morning glory syndrome and persistent hyperplastic primary vitreous (PHPV) in one eye. The anterior and posterior segments were examined after pupil dilation preoperatively. In all children, lens opacity was found which interfered with visual axis. Retinal detachment and space-occupying lesions were ruled out using ultrasound examination. PHPV was detected by ultrasound in 5 eyes and was confirmed during the surgery. In another patient, PHPV was not detected by ultrasound examination and was revealed at the time of surgery. PHPV was indicated by the white cord connected with the optic disc posterior to the opacity of posterior capsule of the lens. The patients were enrolled following written informed consent from their parents and the study protocol was approved by the Institutional Ethics Committee.

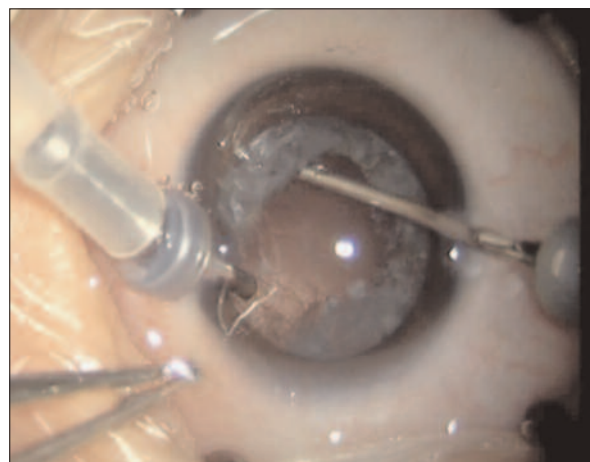
### **Surgical Procedures**

All surgeries were done under general anesthesia with the pupils fully dilated. In case of patients who had pupil diameter less than 6 mm, pupil dilation was performed by anterior chamber injection of diluted epinephrine hydrochloride (0.001 g/1000 ml). Two oblique puncture incisions were made at 2-3 o'clock and 9-10 o'clock directions in the transparent cornea near limbus using a 23G stab knife. Trocars were inserted – one side was connected to the infusion tube and the other side was for 23G vitreous cutter (Figure 1). The cutting rate was 1500 cpm (cuts per minute) and the maximum suction pressure was 500 mmHg. The crystal capsulotomy was performed with the diameter of about 6 mm. After central and side parts of cortex were sucked out, the cutter and the perfusion tube were exchanged and then the residual crystal cortex was sucked out. After the posterior crystal capsule was incised, about 5 mm diameter transparent area was formed and the corresponding anterior vitreous was removed (Figure 2). Subsequently, the anterior capsule polishing was conducted (Figures 3 and 4). In case of children with monocular cataract, the IOL implantation was conducted during the cataract surgery in babies who were above 2 years old but it was not conducted in younger babies. For children with binocular cataract, two operations were conducted separately in infants older than 2 years. In each operation, one eye was operated and meanwhile one IOL was implanted. The second opera-

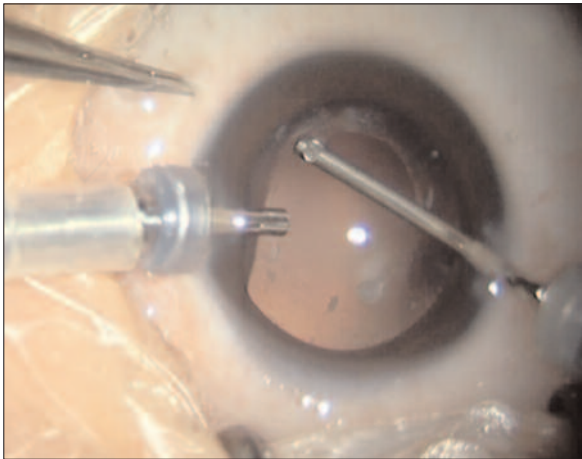


**Figure 1.** The 23G micro-casting tubes were placed into the two corneal incisions (*black arrows*). One side was connected to perfusion and through the other side a 23G vitreous cutter was introduced to perform the curvilinear incision of the anterior capsule.

tion was conducted one month later. If the babies with biocular cataract were younger than 2 years, both operations were conducted simultaneously but without IOL implantation. Later, at an age over 2 years, IOL implantation was performed in both eyes. Briefly, regarding IOL implantation method, a 3.2 mm tunnel incision was made in transparent cornea after cataract surgery at the top of the cornea and then the IOL was implanted. In 6 patients combined with PHPV, the cloudy cord and crystal capsule were connected. In 2 out of the 6 patients, vascular in-growth in posterior capsule was observed. Therefore, the turbid posterior capsule was removed and also

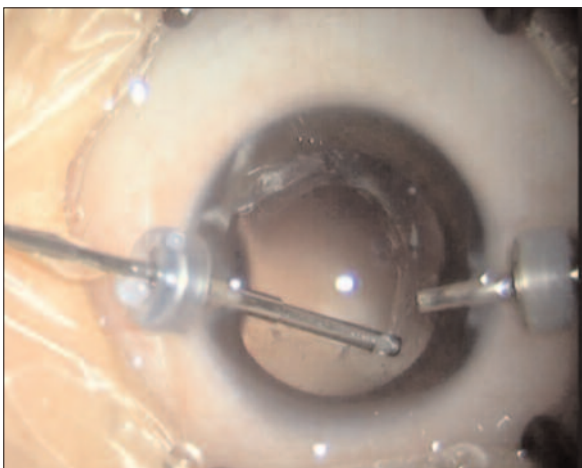


**Figure 2.** The crystal cortex was sucked out and the posterior capsule was curvilinearly incised.

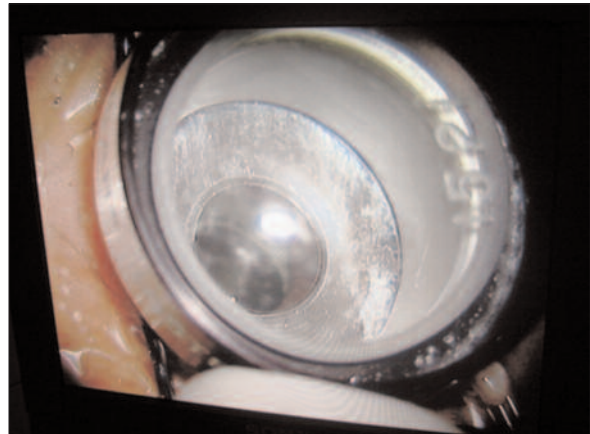


**Figure 3.** Both the anterior and posterior capsules were curvilinear incised and polishing of the inferior part of vitreous anterior capsule was conducted using 23G vitreous cutter.

the cord connected to the posterior capsule was cut off. The trocars were unplugged after surgery and a small amount of viscoelastic was injected into the anterior chamber around the wound and balanced salt solution was injected into the corneal incision to cause corneal stromal edema for the purpose of wound closure. A simple applanation tonometer was used to measure the intraocular pressure in order to control the intraocular pressure at 15 mmHg (Figure 5). There are two pressure marks 15 and 21 on the surface of applanation tonometer. When the intraocular pressure is measured, the bottom of the tonome-



**Figure 4.** The figure shows exchanging directions of the perfusion and vitreous cutter head, sucking out above the surrounding crystal cortex and performing polishing at the inferior part of the vitreous anterior capsule.



**Figure 5.** The intraocular pressure (IOP) was measured after surgery using simple intraocular pressure tonometer. The figure shows watermark of the corneal surface which is consistent with the outer ring of the tonometer (black arrow), suggesting that IOP was 15 mmHg.

ter touches the cornea and forms an annular watermark. The greater the watermark on the surface of the cornea, the lower the IOP is. If the watermark of cornea is consistent with the outer ring, the IOP is 15 mmHg. If the watermark of cornea is consistent with the inner ring, the IOP is 21 mmHg.

#### **Indicators**

The intraoperative indicators included the duration of operation, intraoperative anterior chamber stability, post-operative IOP, and wound leakage. The postoperative indicators included the degree of conjunctival hyperemia, corneal clarity, anterior chamber reaction, exudation in the pupil area and location of IOL.

#### **Results**

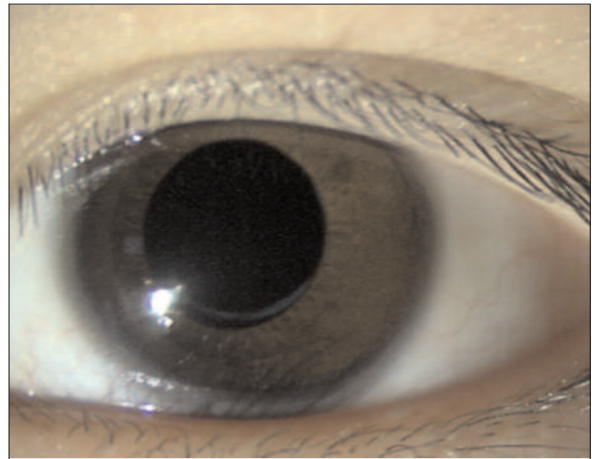
All operations were completed successfully. IOLs were implanted during the cataract surgery in 9 eyes of 7 patients. No intraoperative complications were observed. The average duration of operation was  $35 \pm 13.16$  (range: 10-55) min. During surgery, the anterior chamber was found to be stable. The postoperative formation of the anterior chamber was also good and there was no wound leakage.

One baby cried due to the corneal epithelial exfoliation for 1 day after the surgery and looked normal the next day as the cornea healed up. All other children were able to freely open their treated eyes at day 1 postoperatively. The

eyes of the patient (shown in Figure 4) can be seen open as normal at day 1 after the cataract surgery (Figure 6). Only mild congestion was seen in these eyes which completely faded away at 1 week postoperatively. There were no other complications observed, such as corneal edema, anterior chamber exudation, bleeding, high or low intraocular pressure, or IOL displacement. IOL was implanted 8-15 months after the primary surgery in 8 eyes of 5 patients. All 23 eyes in 13 patients were undergoing visual function training by wearing glasses due to the age below 2 years at the time of latest follow-up. The patients were followed up for an average of  $15.37 \pm 13.78$  (range: 3-50) months. All patients without IOL implantation were suggested to wear glasses 1 month after surgery. The parents of sick children reported that all patients could see objects and play freely. The best corrected visual acuity of 7 eyes in 4 patients who could cooperate was 0.2-0.8. Those babies who showed strabismus and congenital nystagmus are now undergoing amblyopia training. At eye examination, we observed transparent cornea, clear anterior chamber, transparent visual axis and 4-6 mm diameter translucent round area in the middle of anterior and posterior capsules. Among 40 eyes, 2 eyes in one patient showed no turbidity in the crystal surrounding capsule. Other 38 eyes (95%) showed surrounding capsule proliferation (Figure 7). No deviation of all IOL could be seen. The pupil was a perfect circular shape. In 7 eyes of 5 patients (17.5%), focal pupil iris adhesions occurred. At the last follow-up, the average intraocular pressure was  $15.43 \pm 3.25$  (range: 9.2-20.55) mmHg in 19 eyes of 13 babies who could fit check.



**Figure 6.** The eyes of the patient (shown in Figure 4) can be seen opened as normal at day 1 after the cataract surgery.



**Figure 7.** Seven months after congenital cataract surgery, the visual axis is clear; a 5 mm diameter transparent area can be seen. The proliferation at the edge of the incision of crystal capsule can be seen (white arrow).

## Discussion

PCO is the most common complication of cataract surgery in infants and young children. It is also the main reason for the impaired recovery of their visual acuity. The frequency of PCO is as high as 95%<sup>6</sup>. In order to prevent the occurrence of PCO, the posterior crystal capsule needs to be cut off and the anterior vitreous membrane-like hyperplasia also needs to be removed by combined anterior vitrectomy and cataract surgery. It is important because the epithelial cells of lens, after cataract surgery, can grow not only along the posterior lens capsule but also along the anterior vitreous limiting membrane which leads to dense membrane opacities.

The traditional method is to first curvilinear the anterior capsule and aspirate lens cortex. Then, under coaxial perfusion, the posterior crystal capsule is incised and the anterior vitreous is removed or, via the pars plana, the posterior capsule is incised using 20G vitrectomy stab knife and the anterior vitreous is resected. This method has some disadvantages, such as low frequency of excision and dramatic intraoperative vitreous disturbance which increase the risks of retinal detachment and development of macular sac-like edema. Because of the immaturity of the anatomical structure of infant eye and defects of the anterior vitrectomy resection instrument, controllability of the incision range and position is poor which leads to incomplete vitrectomy. As a result, 8-10% children have posterior capsular opacification. In addition, due to the poor close-

ness of vitrectomy under coaxial perfusion and the instability of the anterior chamber, some postoperative complications are prone to develop, such as corneal edema, anterior chamber exudation and posterior synechia. Since the eyes of infants are not yet mature and the palpebral fissures and eyeballs are small, the judgment of the anatomical location of pars plana is not very precise. The conduction of vitreous operation via pars plana using 20G stab knife generates more severe injury in infants and leads to severe complications, such as hemorrhage, retinal tears and retinal detachment. The sutures used in surgery generate foreign body sensation, stinging and tearing in infants and these discomforts of children increase the difficulty in stitching after surgery. Stitches are, therefore, mostly performed under general anesthesia.

In this scenario, the main goal for ophthalmologists has been to reduce the surgical trauma of cataract surgery in infants and young children as well as reduce the intraoperative and postoperative complications. This goal can be achieved through application of the minimally invasive vitrectomy in treating pediatric cataract. It was previously reported<sup>7-10</sup> that the minimally invasive vitrectomy in pediatric cataract surgery could be performed by using a method of puncturing through the pars plana. Xie and Huang<sup>11</sup> incised the posterior capsule without perfusion using 25G vitrectomy system in 40 eyes of 30 patients after phacoemulsification cataract incision and achieved good effects. In all children operated in this study, the pupils were round and located in the center without iris adhesions. Transient hypotony occurred in 2 eyes and returned to normal within 3 days. Anterior chamber fibrous exudation occurred in 2 eyes and was completely absorbed in 3-7 days. In another study<sup>12</sup>, 23G minimally invasive surgery was performed involving direct lensectomy and anterior vitreous excision via the pars plana in 43 eyes of 26 patients with congenital cataract. The eye reaction was mild after surgery with little fibrinous exudation and a few complications.

Arguably, due to the immature development of infant eye and small eye structure, performing vitrectomy via pars plana may involve the risks of postoperative bleeding, retinal tears and retinal detachment. On the other hand, the minimally invasive vitrectomy using perfusion at the corneal incision avoids the above complications and is safer. The diameter of 25G devices is 0.5 mm which not only affects the efficiency of the crys-

tal cortex suction but also the controllability due to the soft texture of the device<sup>4</sup>. The diameter of 20G devices is 0.9 mm. Using 20G devices, the corneal incision is relatively big and, therefore, the corneal endothelial cells may be easily injured and lead to corneal opacity. The diameter of 23G is 0.6 mm which is between 25G and 20G size devices. Not only are the perfusion and crystal cortical suction efficiencies greater than 25G, but also is the texture of the device closer to 20G. Therefore, 23G device is easy to maneuver. The micro-casting on 23G devices makes it easy to approach the anterior chamber and be conducive to the replacement of perfusion direction.

In this study, we made two 23G micro incisions in the peripheral clear cornea and curvilinear incision of the anterior capsule using micro-casting 23G in order to suck out the crystal cortex. The approach used skipped the steps of continuous curvilinear capsulorhexis and, therefore, made the surgical procedure more simple and convenient. The crystal cortex at 12 o'clock position can be easily sucked out by mutually exchanging the directions of the perfusion tube and the vitreous cutter. Because of the small incision and good closeness and stable pressure in the anterior chamber, postoperative reactions are usually mild. The injection of viscoelastic agent into the anterior chamber at the end of surgery and control of intraocular pressure at 15 mmHg avoid the occurrence of postoperative low intraocular pressure and make surgery safer. Since the incision is made at the clear cornea, there is no incision at the conjunctiva or sclera. This choice of corneal incision leads to less bleeding during the operation and reduced ball hemorrhage and retinal damage. This method of vitrectomy via cornea compared with vitrectomy via pars plana offers the benefit of a smaller operation space. Before surgery, the full dilation of pupil is very important. Considering that the pupil dilation is difficult in infants and young children, we injected diluted adrenaline in the anterior chamber in order to effectively dilate the pupils. This intervention achieved good result. Full dilation of pupils can prevent the contact between micro-casting and iris and, therefore, reduce the postoperative reaction of anterior segment uveal. In our pediatric patients, no postoperative discomfort was observed except corneal epithelial exfoliation observed in one child. All patients were able to open their eyes at day 1 postoperatively. We followed-up on the patients for 4-50 months with an average of 17 months. In all patients, the visu-

al axes were transparent. The edges at the posterior capsulotomy had different levels of proliferation in 26 (92.85%) eyes, suggesting that the diameter of the incision in the posterior capsule needs to be large enough in order to avoid the possibility that the turbid posterior capsule impairs light reflection on the visual axis. The intraocular pressures were normal in all patients and no secondary glaucoma developed.

### Conclusions

The 23G minimally-invasive vitrectomy via corneal incision in pediatric cataract surgery has many advantages, such as simple operation, mild postoperative reaction, less pain in patients, quick recovery and fewer complications. It is especially effective in minimizing the occurrence of postoperative complications. Therefore, we suggest that this is an effective method of treating pediatric cataract, especially in infants. However, whether this method can be used as a primary option for treating pediatric cataract requires further studies involving larger sample size.

---

### Conflict of Interest

The Authors declare that there are no conflicts of interest.

### References

- 1) VASAVADA AR, PRAVEEN MR, TASSIGNON MJ, SHAH SK, VASAVADA VA, VASAVADA VA, VAN LOOVEREN J, DE VEUSTER I, TRIVEDI RH. Posterior capsule management in congenital cataract surgery. *J Cataract Refract Surg* 2011; 37: 173-193.
- 2) THOUVENIN D. Management of infantile cataracts: surgical techniques and choices in lens implantation. *J Fr Ophthalmol* 2011; 34: 198-202.
- 3) MEIER P, STERKER I, TEGETMEYER H, WIEDEMANN P. 23-gauge-lentectomy for the treatment of congenital cataract. *Ophthalmologie* 2010; 107: 241-245.
- 4) CHEE KY, LAM GC. Management of congenital cataract in children younger than 1 year using a 25-gauge vitrectomy system. *J Cataract Refract Surg* 2009; 35: 720-724.
- 5) HUANG Y, XIE L. Short-term outcomes of dry pars plana posterior capsulotomy and anterior vitrectomy in paediatric cataract surgery using 25-gauge instruments. *Br J Ophthalmol* 2010; 94: 1024-1027.
- 6) YOU C, XIE L. The applied study of the 25 G-vitreous surgery system without suture or perfusion in treating infant cataract. *J Ophthalmol* 2009; 45: 762-765.
- 7) LEE HK, KIM CY, KWON OW, KIM EK, LEE SC, SEONG GJ, KIM SS. Removal of dense posterior capsule opacification after congenital cataract extraction using the transconjunctival sutureless vitrectomy system. *J Cataract Refract Surg* 2004; 30: 1626-1628.
- 8) CACCIATORI M, ARPA P. Surgical technique for anterior segment surgery in pediatric patients using 25 gauge instruments. *J Cataract Refract Surg* 2006; 32: 562-564.
- 9) YOU C, WU X, YING L, XIE L. Ultrasound biomicroscopy imaging of sclerotomy in children with cataract undergoing 25-gauge sutureless pars plana anterior vitrectomy. *Eur J Ophthalmol* 2010; 20: 1053-1058.
- 10) XIE LX, HUANG YS. Dry pars plana capsulotomy and anterior vitrectomy using 25-gauge vitrectomy system during children cataract surgery. *Zhonghua Yan Ke Za Zhi* 2009; 45: 688-692.
- 11) XIE L, HUANG Y. The application of the 25-G vitrectomy system in the cataract surgery in children. *J Ophthalmol* 2009; 45: 688-689.
- 12) WANG H, SUN F, ZHANG Q. 23G vitrectomy surgery system in treating infants with congenital cataract. *Strabism Pediatr Ophthalmol* 2011; 19: 128-130.