

Internal limiting membrane handling in macular hole surgery: the infusion direction manipulation and infusion off techniques

J.M. YANG^{1,2}, J.-G. KIM¹

¹Department of Ophthalmology, Asan Medical Center, University of Ulsan College of Medicine, Seoul, Republic of Korea

²Department of Ophthalmology, Dongguk University Ilsan Hospital, Goyang, Republic of Korea

Abstract. – **OBJECTIVE:** Herein, we introduce the infusion direction manipulation technique and the infusion off technique. These relatively simple methods control intra-vitreous fluid flow direction and turbulence and release negative pressure in the microforceps to facilitate handling of the internal limiting membrane. The aim of this study is to introduce an effective and uncomplicated method to handle the internal limiting membrane (ILM) during the temporal inverted ILM flap and free ILM flap techniques in macular hole surgery by controlling the direction and status of the infusion.

MATERIALS AND METHODS: The direction of the infusion flow was controlled with a free finger (usually the 4th finger) during the inverted ILM flap surgery to stabilize the flap location during the fluid-air exchange. A valved trocar was used, and the infusion was discontinued during the free ILM flap surgery. Turbulence was minimized, and negative pressure around the head-shaft junction of the microforceps was released.

RESULTS: The ILM flap remained stable in all patients who underwent macular hole surgery with our technique.

CONCLUSIONS: Infusion direction manipulation technique and infusion off technique are efficient and simple methods to handle the ILM during ILM surgery.

Key Words:

Flap surgery, Infusion, Internal limiting membrane, Macular hole surgery.

MH, and MH associated with high myopia, retinal detachment, foveoschisis, or hole marginal ERM^{2,3}. In this regard, various surgical techniques for manipulating the ILM were developed to improve the hole closure rate and patient's visual outcome. Among the ILM manipulation techniques, inverted ILM flap and free ILM flap are the most popular and have excellent surgical outcomes^{4,5}. However, handling the ILM flap during the vitrectomy is challenging and requires a significant learning curve.

During vitrectomy, the infusion system enables surgeons to maintain stable intraocular pressure by controlling fluid flow into the vitreoretinal space. However, constitutive fluid flow inside the vitreous cavity increases the chances of flap displacement and loss during ILM manipulation. Because the flap should cover the MH for surgical success, Morizane et al⁵ introduced discontinuing the infusion and placing low molecular weight viscoelastic material above the free flap to stabilize the flap position during autologous free ILM flap transplantation. As their study's main focus was to introduce a novel free flap procedure, they did not emphasize using the procedure to easily manipulate the ILM flap during the surgery; thus, basic background information and detailed instructions for this issue are warranted. Therefore, considering the fluid direction and movements during vitrectomy, we introduce a simple and efficient technique to handle the ILM during inverted ILM flap and free ILM flap procedures by manipulating infusion status and direction.

Introduction

The success of macular hole (MH) surgery has improved significantly since the introduction of internal limiting membrane (ILM) peeling and gas tamponade¹. However, this surgical technique might yield insufficient anatomical and functional outcomes in cases of intractable MH, such as large MH (hole size > 400 μ m), degenerative

Materials and Methods

This study adhered to the tenets of the Declaration of Helsinki and was approved by the Institutional Review Boards of Asan Medical Center

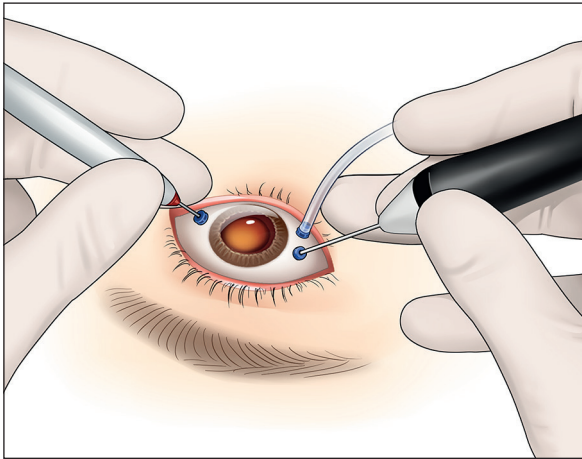


Figure 1. Fourth finger-assisted infusion direction manipulation technique. The direction of the infusion flow is adjusted by manipulating the infusion cannula using the fourth finger.

(IRB No. 20211603). All surgeries are performed under local or general anesthesia. A standard 23/25-gauge three-port transconjunctival sutureless vitrectomy is performed. The infusion cannula is placed in the inferotemporal area. After completion of core vitrectomy, indocyanine green 0.25% dye is used to stain the ILM.

Infusion Direction Manipulation Technique for Inverted ILM Flap Procedure

Using the end-grasping ILM microforceps, a long incision is made toward the macula. Start-

ing with multiple small curvilinear flaps, a large temporal flap with a hinge of adequate size and width is generated. The redundant part of the flap is trimmed with a vitreous cutter. To start the fluid-air exchange, an extrusion needle is placed above the optic nerve. A free finger not holding the instrument (4th finger is recommended) is used to manipulate the infusion cannula to change the direction of the infusion tip inside the eye (Figure 1; **Video 1** and **Video 2**). During the initiation of the fluid-air exchange, the direction of the infusion cannula tip is turned toward the farthest area of the macula using the 4th finger, because the residual fluid in the infusion cannula could potentially flow inside the eye and cause turbulence that displaces the ILM flap. Then, the cannula tip direction is turned toward the flap, and the air inflow in the temporal side will cause the fluid in the posterior pole to flow in the temporal-to-nasal direction. This procedure will flip the temporal flap to cover the MH.

Infusion Off Technique for Free ILM Flap Procedure

The microforceps has a space in the head-shaft junction (Figure 2). Therefore, constitutive negative pressure is formed around the head-shaft junction when the infusion is turned on (**Video 3**). During the free flap procedure, the light ILM flap is easily floated and lost. Moreover, this flap easily collapses or adheres to the head-shaft junction of the forceps, causing difficulty in releasing the flap from the forceps (**Video 4**). Therefore,

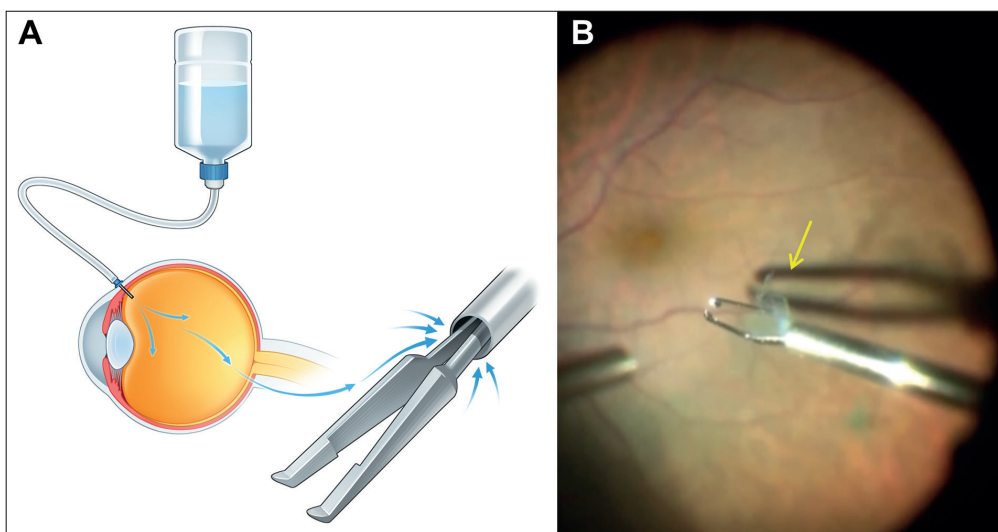


Figure 2. Negative pressure formation around microforceps during vitrectomy. **A**, Schematic illustration showing negative pressure formed at the gap in the head-shaft junction of the microforceps. **B**, Surgical image showing adherence of the internal limiting membrane (ILM) to the head-shaft junction of the microforceps (yellow arrow).

to overcome negative pressure in the forceps and turbulence generated by fluid flow, we suggest the infusion off technique which includes two elements: (1) using a valved trocar, and (2) turning off the infusion. This technique will reduce the possibility of ILM flap adherence to the forceps and will enable the flap to freely fall into the hole after its release (Video 5). The infusion cannula tip is turned toward the farthest area of the macula during the fluid-air exchange to avoid displacement of the ILM flap by turbulence.

At the end of the surgery, 14% C3F8 gas is used for tamponade, and the patients are instructed to maintain a face-down position.

Results

The ILM flap remained stable in all patients who underwent macular hole surgery with our technique.

Discussion

In this report, we have introduced the infusion direction manipulation technique and the infusion off technique, which significantly improve control of the ILM during vitreoretinal surgery. These relatively simple techniques control the direction of intra-vitreous fluid flow and turbulence and release negative pressure in the microforceps to facilitate handling of the ILM. Our technique does not require the additional time and cost of an extra procedure and can be easily performed during the routine surgical procedure.

Since the introduction of the ILM flap technique by Michalewska et al⁴, surgical outcomes in intractable MHs have improved significantly⁶⁻⁸. However, achieving adequate postoperative flap position – covering the MH – is still challenging with this technique. Our infusion direction manipulation technique facilitates control of fluid flow direction using an unoccupied finger (usually the 4th) and allows flipping of the uncovered flap and maintenance of flap position covering the hole during the fluid-air exchange.

The free ILM flap is one of the most challenging techniques among ILM surgeries and has a high risk of flap loss⁵. Meticulous handling of the ILM is necessary; however, a light ILM is difficult to manipulate during the procedure. We focused on controlling turbulence and the microforceps using our infusion off technique. There is a thin tube-like gap between the head and shaft of the micro-

forceps⁹. Due to this structure, there is a capillary effect and an outflow from this gap, causing outward fluid flow, thereby creating negative pressure. Eliminating inflow of fluid relieves this negative pressure. Therefore, our infusion off technique is an excellent way to release negative pressure. If a valved trocar is used, the outflow that creates turbulence can also be minimized while maintaining the intraocular pressure. Many adjuvant techniques (e.g., applying viscoelastic material, perfluorocarbon liquid, and autologous blood) have been developed to stabilize the flap position^{5,10,11}. These techniques involve additional time-consuming surgical steps; however, our techniques can significantly reduce surgical time, thereby having an advantage over these procedures.

Conclusions

We have described the infusion direction manipulation and infusion off techniques, which facilitate the surgeon's handling of the ILM during MH surgery. This method is simple and exceptionally practical to perform during the ILM surgery and may significantly increase flap stability and shorten the surgical time.

Conflict of Interest

The Authors declare that they have no conflict of interests.

Acknowledgements

We thank the Faculties of the Medical Contents Unit (Chul Ho Jang, Ho Sun Cho, and Yu Jin Lee) and Yuna Kim, Chan Hong Min, and Sang-Uk Choi from Asan Medical Center for technical assistance. We also thank Ki baek Choi at School of Applied and Engineering Physics, Cornell University for academic advice. The 125th Annual Meeting of the Korean Ophthalmological Society, Seoul, Republic of Korea (Best Video award), April 3-4, 2021. The Euretina 2021 Virtual Meeting, Sep 12-14, 2021. Film Festival at ASRS 39th Annual Meeting (2021), San Antonio, TX, USA, Oct 8-12, 2021.

References

- 1) Park DW, Sipperley JO, Sneed SR, Dugel PU, Jacobsen J. Macular hole surgery with internal-limiting membrane peeling and intravitreal air. *Ophthalmology* 1999; 106: 1392-1398.
- 2) Yang JM, Choi SU, Kim YJ, Kim R, Yon DK, Lee SW, Shin JI, Lee JY, Kim JG. Association between epiretinal membrane, epiretinal proliferation, and prognosis of full-thickness macular hole closure. *Retina* 2022; 42: 46-54.

- 3) Zhao P, Wang S, Liu N, Shu Z, Zhao J. A Review of Surgical Outcomes and Advances for Macular Holes. *J Ophthalmol* 2018; 2018: 1-10.
- 4) Michalewska Z, Michalewski J, Adelman RA, Nawrocki J. Inverted internal limiting membrane flap technique for large macular holes. *Ophthalmology* 2010; 117: 2018-2025.
- 5) Morizane Y, Shiraga F, Kimura S, Hosokawa M, Shiode Y, Kawata T, Hosogi M, Shirakata Y, Okanouchi T. Autologous transplantation of the internal limiting membrane for refractory macular holes. *Am J Ophthalmol* 2014; 157: 861-869.e1.
- 6) Narayanan R, Singh SR, Taylor S, Berrocal MH, Chhablani J, Tyagi M, Ohno-Matsui K, Pappuru RR, Apte RS. Surgical outcomes after inverted internal limiting membrane flap versus conventional peeling for very large macular holes. *Retina* 2019; 39: 1465-1469.
- 7) Iwasaki M, Kinoshita T, Miyamoto H, Imaizumi H. Influence of inverted internal limiting membrane flap technique on the outer retinal layer structures after a large macular hole surgery. *Retina* 2019; 39: 1470-1477.
- 8) Tsui MC, Yang CM. Early and Late Macular Changes After the Inverted Internal Limiting Membrane Flap Technique for a Full-Thickness Macular Hole. *Retina* 2021; 41: 20-28.
- 9) Lee JE, Byon IS, Park SW. *Internal Limiting Membrane Surgery*. Springer Nature Singapore, 2021.
- 10) Park SW, Pak KY, Park KH, Kim KH, Byon IS, Lee JE. Perfluoro-n-octane Assisted Free Internal Limiting Membrane Flap Technique for Recurrent Macular Hole. *Retina* 2015; 35: 2652-2656.
- 11) Lai CC, Chen YP, Wang NK, Chuang LH, Liu L, Chen KJ, Hwang YS, Wu WC, Chen TL. Vitrectomy with Internal Limiting Membrane Repositioning and Autologous Blood for Macular Hole Retinal Detachment in Highly Myopic Eyes. *Ophthalmology* 2015; 122: 1889-1898.