

# Combination therapy with retinaldehyde (0.1%) glycolic acid (6%) and efectiose (0.1%) in mild to moderate acne vulgaris during the period of sun exposure – efficacy and skin tolerability

F. MASINI, F. RICCI, B. FOSSATI, P. FRASCIONE<sup>1</sup>, R. CAPIZZI, C. DE WAURE<sup>2</sup>, C. GUERRIERO

Department of Dermatology, Catholic University of the Sacred Heart, School of Medicine, Rome, Italy

<sup>1</sup>Regina Elena National Cancer Institute Rome, Italy

<sup>2</sup>Institute of Public Health, Catholic University of the Sacred Heart, School of Medicine, Rome, Italy

**Abstract.** – **OBJECTIVES:** Acne vulgaris is the most common disease of the adolescence age (70-94%). Main topical treatments for acne vulgaris are retinoids, benzoyl peroxide and antibiotics in mono or combination therapy. Topical retinoids, some antibiotics and antiseptics although effective on acne lesions, can due photosensitivity or make the skin more sensitive to the sun. Our study is aimed to evaluate the efficacy and tolerability of a combination therapy with Retinaldehyde (0.1%), Glycolic acid (6%) and Efectiose (0.1%) (RGE) cream in patients affected by acne vulgaris, during the lasting period of sun exposure.

**PATIENTS AND METHODS:** We retrospectively observed 30 patients of Central Italy with mild or moderate acne between April and September. All the patients selected underwent only therapy with RGE cream once a day in the evening for 8 weeks, while in the morning they just applied SPF 50 sunscreen. We evaluate the efficacy at 30 and 60 days with the “Global Evaluation Scale” (GES) and the tolerability with a 0-3 qualitative scale.

**RESULTS:** The mean GES value showed a statistically significant reduction: 1.83 (SD 0.83) at baseline 1.57 (SD 0.77) and 0.90 (SD 0.76) respectively at 30 and 60 days ( $p < 0.01$ ). Side effects were very uncommon.

**CONCLUSIONS:** Topical treatments with retinoids, antibiotics and antiseptics can be associated with an increased occurrence of facial dryness and erythema restricting their use in sun exposure period. RGE cream has shown a good skin tolerability and efficacy, so it can be considerate an effective maintaining therapy to treat mild to moderate acne during the sun exposure period in which retinoids, antibiotics or antiseptic treatments are not recommended.

*Key Words:*

Acne vulgaris, Retinaldehyde, Glycolic acid, Efectiose, Tolerability.

## Introduction

Acne vulgaris is a very common disease of the pilosebaceous follicles which presents different features: non inflammatory lesions (open and closed comedones), inflammatory lesions (papules, pustules, cysts and nodules) or both of them. Acne vulgaris is typically located on the face, chest, upper back and interfering significantly with quality of life. In fact, psychological effects such as reduced self-esteem and, sometimes, depression, anxiety or unemployment, has been reported<sup>1</sup>. The pathogenesis is multifactorial, the biologic events that results in acne lesions are: sebaceous hyperplasia, follicular hyperkeratinization, proliferation of *Propionibacterium acnes* and inflammation<sup>2</sup>. In fact European evidence-based guidelines for acne suggest combination therapy as the most effective<sup>3</sup>.

Main topical treatments for mild to moderate acne vulgaris are: retinoids, benzoyl peroxide, antibiotics, alpha-beta hydroxide acids and nicotinamide in mono or combination therapy. However the use of some topical treatments as retinoids or benzoyl peroxide is often associated with local irritation which can reduce patient adherence to the treatment<sup>4,5</sup>; therefore, topical emollient compounds can be useful to reduce the cutaneous irritations<sup>6</sup>. Even more, topical retinoids, some antibi-

otics and antiseptics although effective on acne lesions, can due photosensitivity or make the skin more sensitive to the sun<sup>7</sup>.

Our study is aimed to evaluate the efficacy and tolerability of a combination therapy with Retinaldheyde (0.1%), Glycolic acid (6%) and Efec-tiose (0.1%) (RGE) cream in patients affected by mild to moderate acne vulgaris, during the last-ing period of sun exposure in Italy.

### Patients and Methods

A retrospective cohort epidemiological study on 30 patients of Central Italy with mild or moderate acne was carried out between April and September. Main inclusion criteria were: male or female, age between 10 and 30 years, mild to moderate acne vulgaris according to Lehmann et al<sup>8</sup> and defined as: at least 10 but less than 50 in-flammatory lesions or at least 10 but less than 100 non-inflammatory lesions and no more than

2 nodulocystic lesions. Patients with severe acne requiring and using other topical or systemic treatment were excluded from the study. From data of the first visit medical history of each pa-tient was collected, with respect to age, sex, fam-ily history, characteristics of menstrual cycles, skin diseases and comorbidity. All the patients selected underwent only therapy with RGE cream once a day in the evening for 8 consecu-tive weeks, while in the morning they just ap-plied SPF 50 sunscreen. The “Global Evaluation Scale” (GES)<sup>9</sup> grading system proposed by the FDA was used for objective evaluation of the ef-ficacy at 30 and 60 days. GES involves the as-signment of a 0-5 score depending on the type and number of acne lesions (Figure 1). Tolerabil-ity was assessed at 30 days and 60 days on a 0-3 qualitative scale (0, poor tolerability; 3 very good tolerability) and erythema, dryness, desquama-tion, pruritus, burning were evaluated using a 0-3 qualitative score (0 = None; 1 = Mild; 2 = Mod-erate; 3 = Severe).

“Global Evaluation Scale” (GES) grading system	
0	Healthy clear skin with no evidence of acne vulgaris.
1	Almost clear, rare non-inflammatory lesions present; rare non-inflamed resolving papules.
2	Some non-inflammatory lesions present; few inflammatory lesions (papules/pustules only, no nodulocystic lesions).
3	Non-inflammatory lesions predominate; multiple inflammatory lesions present; several to many comedones and papules/pustules; one small nodulocystic lesion .
4	Inflammatory lesions predominate; many comedones and papules/pustules; may or may not be a few nodulocystic lesions.
5	Highly inflammatory lesions predominate; variable number of comedones; many papules/pustules and nodulocystic lesions.

Figure 1. The “Global Evaluation Scale” (GES) grading system.

### Statistical Analysis

A descriptive analysis of the sample was carried out by means of absolute and relative frequencies and means and standard deviation (SD) for qualitative and quantitative variables respectively. In order to analyze treatment efficacy, a General Linear Model for repeated measurement was used to assess GES changes in time and a post-hoc analysis with Bonferroni correction was conducted. Furthermore a description of safety and tolerability results was performed by means of absolute and relative frequencies.  $p < 0.05$  was considered significant.

### Results

A total of 30 patients, 17 females (56.7%) and 13 males (43.3%) with a mean age of 12.4 years (SD 2.34) at the onset of the disease were enrolled in the study. Baseline GES score was 1.83 (SD 0.83). The analysis of repeated measures showed a statistically significant reduction of GES from baseline to 60 days ( $p < 0.01$ ). In particular, the mean GES value was 1.83 (SD 0.83) at baseline 1.57 (SD 0.77) and 0.90 (SD 0.76) respectively at 30 and 60 days. The post-hoc analysis demonstrated a significant difference between values at baseline and at 30 and 60 days ( $p < 0.01$ ) (Figure 2). As far as tolerability was concerned, 21 (70%) and 23 patients (76.7%) showed very good tolerability at 30 and 60 days respectively. Side effects were very uncommon both at 30 and 60 days as shown in Figure 3.

### Discussion

The combination of RGE has shown good efficacy and tolerability in replacement to other treatments that can be associated with an increased incidence of facial dryness, erythema and hyperpigmentations, restricting their use in sun exposure period. All the patients showed a significant reduction of GES value, they also applied SPF 50 sunscreen and at the end of the therapy none of our patients showed hyperpigmentations on the skin. Retinaldehyde regulates many cellular mechanisms including keratolysis, remodeling of the collagen and depigmentation. Glycolic acid promotes the cellular exfoliation and has anti-inflammatory effects<sup>10</sup>. Furthermore, glycolic acid decreases the excess of

pigment by a wounding and re-epithelialization process<sup>11</sup>. The main limitations of our study are that it was performed on a limited number of patients and the lacking of a control group, but during the periods of sun exposure is difficult to assess the GES value in patients who undergo other therapies because they often interrupt the treatments due to local irritation or photosensitivity. Furthermore, there are no valid scientific evidence that sun exposure reduces the gravity of the acne but in our group of patients treated with RGE cream we have seen a statistically significant reduction of GES from baseline to 60 days.

### Conclusions

A good skin tolerability is the crucial factor for patient compliance and the clinical experience suggests that compliance is a major obstacle in achieving favorable results. RGE cream has shown a good skin tolerability with a lower incidence of skin burning sensation and dryness, so it can be considered a useful tool to treat mild to moderate acne, such as maintaining therapy during the sun exposure period in which retinoids, antibiotics or antiseptic treatments are not recommended.

### Conflict of Interest

The last author (Guerriero C.) has been in the past consultant for acne products of other companies (Pierre-Fabre and GlaxoSmithKline) that have no relation with the product used in the study.

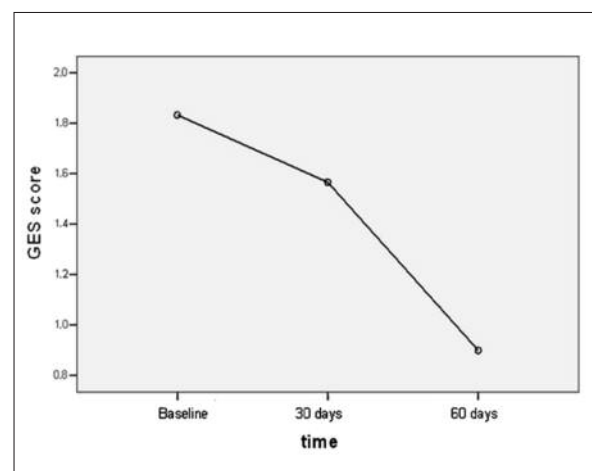


Figure 2. GES score from baseline to 60 days.

		30 days	60 days
Erythema	None	24 (80%)	25 (83.3%)
	Mild	3 (10%)	3 (10%)
	Moderate	2 (6.7%)	2 (6.7%)
	Severe	1 (3.3%)	0 (0%)
Dryness	None	28 (93.3%)	27 (90%)
	Mild	0 (0%)	2 (6.7%)
	Moderate	1 (3.3%)	0 (0%)
	Severe	1 (3.3%)	1 (3.3%)
Desquamation	None	25 (83.3%)	28 (93.3%)
	Mild	4 (13.3%)	1 (3.3%)
	Moderate	1 (3.3%)	1 (3.3%)
	Severe	0 (0%)	0 (0%)
Pruritus	None	22 (73.3%)	22 (73.3%)
	Mild	4 (13.3%)	5 (16.7%)
	Moderate	2 (6.7%)	2 (6.7%)
	Severe	2 (6.7%)	1 (3.3%)
Burning	None	17 (56.7%)	19 (63.3%)
	Mild	7 (23.3%)	8 (26.7%)
	Moderate	6 (20%)	3 (10%)
	Severe	0 (0%)	0 (0%)

Figure 3. Side effects at 30 and 60 days.

## References

- AKTAN S, OZMEN E, SANLI B. Anxiety, depression, and nature of acne vulgaris in adolescents. *Int J Dermatol* 2000; 39: 354-357.
- WEISS JS. Acne: evolving concepts of pathogenesis need to guide therapeutic developments. *J Drugs Dermatol* 2013; 12: s66.
- NAST A, DRÉNO B, BETTOLI V, DEGIZ K, ERDMANN R, FINLAY AY, GANCEVICIENE R, HAEDERSDAL M, LAYTON A, LÓPEZ-ESTEBARANZ JL, OCHSENDORF F, OPRICA C, ROSUMECK S, RZANY B, SAMMAIN A, SIMONART T, VEIEN NK, ZIVKOVI MV, ZOUBOULIS CC, GOLLNICK H. European Dermatology Forum. European evidence-based (S3) guidelines for the treatment of acne. *J Eur Acad Dermatol Venereol* 2012; 1: 1-29.
- ZEICHNER JA. Optimizing topical combination therapy for the treatment of acne vulgaris. *J Drugs Dermatol* 2012; 11: 313-317.
- GROVE G, ZERWECK C, GWAZDAUSKAS J. Tolerability and irritation potential of four topical acne regimens in healthy subjects. *J Drugs Dermatol* 2013; 12: 644-649.
- VERALDI S, GIOVENE GL, GUERRIERO C, BETTOLI V. Efficacy and tolerability of topical 0.2% Myrtacine® and 4% vitamin PP for prevention and treatment of retinoid dermatitis in patients with mild to moderate acne. *G Ital Dermatol Venereol* 2012; 147: 491-497.
- THIELITZ A, GOLLNICK H. Topical retinoids in acne vulgaris: update on efficacy and safety. *Am J Clin Dermatol* 2008; 9: 369-381.
- LEHMANN HP, ROBINSON KA, ANDREWS JS, HOLLOWAY V, GOODMAN SN. Acne therapy: a methodologic review. *J Am Acad Dermatol* 2002; 47: 231-240.
- LUCKY AW, BARBER BL, GIRMAN CJ, WILLIAMS J, RATTERMAN J, WALDSTREICHER J. A multirater validation study to assess the reliability of acne lesion counting. *J Am Acad Dermatol* 1996; 35: 559-565.
- DRENO B, CASTELL A, TSANKOV N, LIPOZENCIC J, SERDAROGLU S, GUTIERREZ V, GADROY A, MERAL-KIENY C, MERY S. Interest of the association retinaldehyde/glycolic acid in adult acne. *J Eur Acad Dermatol Venereol* 2009; 23: 529-532.
- KATSAMBAS AD. RALGA (Diacneal), a retinaldehyde and glycolic acid association and postinflammatory hyperpigmentation in acne--a review. *Dermatology* 2005; 1: 39-45.