

Serial EEG study in a girl with Landau-Kleffner Syndrome associated with continuous spikes and waves during slow sleep

G. IMATAKA, O. ARISAKA

Department of Pediatrics, Dokkyo Medical University School of Medicine, Tochigi, Japan

Abstract. Landau-Kleffner syndrome (LKS) is rare epileptic encephalopathy in childhood, characterized by both acquired epileptic aphasia and abnormal epileptiform discharges in electroencephalogram (EEG). We herein report a serial EEG study in LKS. A 22-month old girl was referred to our hospital because of frequently partial seizures in her left upper limb. On EEG performed and multifocal spikes were recognized. Oral treatment of carbamazepine was started but her seizures were not controlled. Her language ability did not progress after 2 years of her age. At age 4 years, carbamazepine was switched to valproic acid, leading to reduction in the frequency of seizure episodes. She was able to speak two-word sentences at 4 years of age, but her word output gradually decreased. At 5 years of age, addition of zonisamide further reduced the frequency of seizure episodes, but failed to achieve complete control of seizures. She increasingly asked for questions to be repeated. Auditory brainstem response testing performed at the department of otolaryngology revealed normal hearing ability. She was diagnosed as having intellectual deficits with an intelligence quotient (IQ) of 61 at 7 years of age. The EEG at 8 years of age showed continuous spikes and waves during slow sleep (CSWS), leading to a diagnosis of LKS. After age 11 years, the CSWS on EEG improved without requiring a change in antiepileptic drugs (AEDs). Treatment with the oral AEDs was discontinued at 13 years of her age. Her IQ at 13 years of age was in the low 70s.

Key words:

CSWS, ESES, Aphasia.

Introduction

Landau-Kleffner syndrome (LKS) is an epileptic encephalopathy, which is diagnosed based on acquired epileptic aphasia and electroencephalogram (EEG) abnormalities¹. LKS typically develops in children between 2 and 11 years of age and

is a rare syndrome according for 0.2% of all childhood epilepsy cases. It is believed to manifest auditory agnosia that involves the region close to Heschl's gyri in the temporal lobe². EEG abnormalities invariably occur with seizure foci in the temporal or parietal lobe in most cases and spikes may be seen in the both the right and left side of the brain. The EEG abnormalities tend to become more pronounced during sleep than while awake. Some LKS patients reportedly show continuous spikes and waves during slow sleep (CSWS)^{3,4}. Herein, we report on a girl who was diagnosed as having LKS with partial seizures as an initial symptom occurring at 1 year of age and her clinical course with the results of serial EEG studies conducted from an early age.

Case report

The patient was a 22 month old girl with unremarkable family history and no abnormalities in motor development. She was able to speak meaningful words at 16 months of age. She was brought to the hospital for management of partial seizures. The seizures were clonic in the left arm and leg, and showed various patterns with transient loss of consciousness and blinking. The seizure episodes occurred several times per day. The sleep-induced EEG record at 2 years of age showed single spike waves in the left frontal and right parietal regions. Treatment with oral carbamazepine (CBZ) was started and the frequency of the seizure episodes was reduced to several times per week. She was able to speak only 5 words at 3 years of age and was suspected to have autism on health screening. Her eye contact was normal and she was diagnosed as having language delay, rather than autism. Treatment with CBZ was discontinued at approximately 4 years of age, with a switch to valproic acid (VPA). The frequency of the seizure episodes diminished to

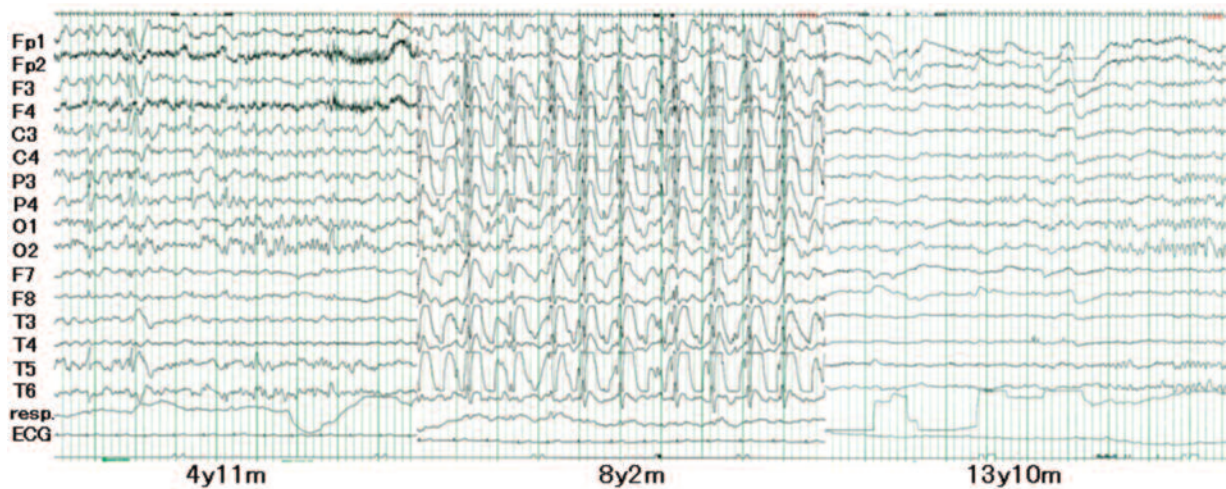


Figure 1. **A.** Sleep-induced EEG recording (4y11m): Multifocal single spikes are recorded in the left frontal, left central, right parietal, right occipital and left postero-temporal regions, etc. **B.** Sleep-induced EEG recording (8y2m): Continuous spikes and waves during slow sleep (CSWS) appeared in at least 85% of the EEG recordings obtained during sleep. **C.** Sleep-induced EEG recording (13y10m): There are no epileptic abnormalities.

several times per month. However, grand mal seizures with falling after transient loss of consciousness occurred. She was temporarily able to speak two-word sentences, but her word output gradually decreased after age 4 and a half. The sleep-induced EEG record showed multifocal spikes (Fig. 1A). Based on her clinical course, she was diagnosed as having acquired aphasia and intellectual deficits associated with epilepsy and EEG abnormalities, i.e., LKS. Addition of zonisamide to her treatment regimen at 5 years of age further reduced the frequency of seizure episodes, but failed to achieve complete control. After approximately age 5 and a half year, she began asking her mother to repeat questions with growing frequency. Auditory brainstem response testing performed revealed normal hearing ability. Although she entered a regular elementary school class at 6 years of age, she was transferred to special needs school because of poor learning performance. She was diagnosed as having intellectual deficits with an intelligence quotient (IQ) of 61 at 7 years and 7 months of age. Thereafter, the frequency of her speech as well as conversation diminished. The sleep-induced EEG record at 8 years of age revealed CSWS (Fig. 1B). She experienced menarche at 11 years of age. After 12 years of age, her seizure episodes resolved. At 13 years of age, she stopped taking antiepileptic drugs (AEDs). The sleep-induced EEG record showed no epileptic abnormalities (Fig. 1C). Her IQ at 13 years of age was in the low 70s.

Discussion

LKS patients first develop auditory language disorders followed by expressive language disorders; patients with severe LKS may develop global aphasia and intellectual deficits². The present patient had simple partial seizures as an initial symptom of LKS at age 1 year, earlier than typical onset age. The main symptom of LKS is acquired aphasia¹. No seizure episodes occur in 30% of LKS patients⁵. Acquired aphasia may easily be recognized when LKS without seizures develops in school-aged children who have already achieved some degree of language development. However, as in our present patient, it is difficult to detect epilepsy-associated language disorders in infants under 2 years of age who develop LKS without seizures. Thus, the findings of early onset LKS are often presumed to be attributable to a hearing disorder. LKS is often mistaken for autism because 30% of autistic cases are also complicated by epilepsy⁴. Based on these factors, it is important for children with language disorders or who are suspected to have autism to undergo examinations allowing LKS or comorbid epilepsy to be diagnosed by EEG.

However, EEG findings in LKS may vary with age. Early in the course of this disease, the EEG patterns are similar to those recorded in localization-related epilepsy or benign childhood epilepsy with centro-temporal spikes⁶. Some studies have shown that CSWS appears with language

disorder worsening³. In the present case, simple partial seizures initially occurred and CBZ was prescribed. However, CBZ is ineffective for the treatment of LKS and the use of this AED should be carefully considered in early-onset LKS in which identifying language disorders is difficult⁷. Concerning outcomes of LKS, most patients reportedly have residual language deficits and experience spontaneous resolution of seizure episodes after the school-age period. Interestingly, the EEG findings in the present case changed from multifocal spikes to CSWS and then improved.

Achieving language disorder improvement is a major target of treatment strategies for LKS. In LKS, an early-age onset and a longer duration of CSWS are believed to be associated with serious language deficits. Several studies have found that treatment with adrenocorticotrophic hormone, immunoglobulin is effective based on LKS being a form of encephalopathy^{3,8}. In the field of neurosurgery, the multiple subpial transection procedure is reportedly effective for ameliorating language disorders⁵. These treatments were not used in the present patient. Her seizure outcome was favorable, but intellectual deficits and the language disorder persisted. Patients who have autistic symptoms or language disorders should undergo serial EEG testing, even if they have no seizures. If CSWS is found, LKS should be considered in the differential diagnosis, and the implementation of early immunologic therapy or surgery for epilepsy should be considered.

Conflict of interest

The Authors declare that they have no conflict of interests.

References

- 1) LANDAU WM, KLEFFNER FR. Syndrome of acquired aphasia with convulsive disorder in children. *Neurology* 1957; 7: 523-530.
- 2) BERG AT, BERKOVIC SF, BRODIE MJ, BUCHHALTER J, CROSS JH, VAN EMDE BOAS W, ENGEL J, FRENCH J, GLAUSER TA, MATHEM GW, MOSHE SL, NORDLI D, PLOUNI P, SCHEFFER IE. Revised terminology and concepts for organization of seizure and epilepsies: report of the ILAE Commission on Classification and Terminology, 2005-2009. *Epilepsia* 2010; 51: 676-685.
- 3) DEVINSKY O, GOLDBERG R, MILES D, BOJKO A, RIVIELLO J Jr. Episodic epileptic verbal auditory agnosia in Landau-Kleffner Syndrome treated with combination diazepam and corticosteroids. *J Child Neurol* 2014 Jan 21 [Epub ahead of print].
- 4) LESCA G, RUDOLF G, LABALME A, HIRSH E, ARZIMANOGLU A, GENTON P, MOTTE J, DE SAINT MARTIN A, VALENTI MP, BOULAY C, DE BELLESCIZE J, KEO-KOSAL P, BOUTRY-KRYZA N, EDERY P, SANLAVILLE D, SZEPETOWSKI P. Epileptic encephalopathies of the Landau-Kleffner and continuous spike and waves during slow-wave sleep types: genomic dissection makes the link with autism. *Epilepsia* 2012; 53: 1526-1538.
- 5) CROSS JH, NEVILLE BG. The surgical treatment of Landau-Kleffner syndrome. *Epilepsia* 2009; 50(Suppl 7): 63-67.
- 6) DATTA AN, OSER N, RAMELLI GP, GOBBIN NZ, LANTZ G, PENNER IK, WEBER P. BECTS evolving to Landau-Kleffner Syndrome and back by subsequent recovery: a longitudinal language recognition case study using fMRI, source EEG, and neuropsychological testing. *Epilepsy Behav* 2013; 27: 107-114.
- 7) MARESCAUX C, HIRSH E, FRINK S, MARQUEST P, SHLUMBERGER E, SELLAL F, METZ-LUTZ MN, ALEMBIK Y, SALMON E, FRANK G, KURTZ D. Landau-Kleffner syndrome. A pharmacologic study of five cases. *Epilepsia* 1990; 31: 768-777.
- 8) MITAKI MA, SAAB R. Successful use of intravenous immunoglobulin as initial monotherapy in Landau-Kleffner syndrome. *Epilepsia* 2000; 41: 880-886.