

Methotrexate/mifepristone-combined with embryo removal in the treatment of caesarean scar pregnancy

S.-S. YU¹, M.-Y. MA¹, R. ZHOU¹, R. LIANG¹, Z. DUAN², J. WANG¹, Y. TIAN³, J. JIANG¹, X. HE¹, Q. ZHOU¹

¹Department of Ultrasound, The Second Affiliated Hospital of Xi'an Jiaotong University, Xi'an, China

²Department of Obstetrics and Gynecology, The Second Affiliated Hospital of Xi'an Jiaotong University, Xi'an, China

³Department of Medical Ultrasound Center, Northwest Women's and Children's Hospital, Xi'an, China

Shanshan Yu and Miaoyan Ma contributed equally to this paper

Abstract. – OBJECTIVE: The aim of this study was to compare the effect of different administration modalities of methotrexate (MTX)/mifepristone in the initial medication stage, followed by embryo transfer in the treatment of caesarean scar pregnancy (CSP).

PATIENTS AND METHODS: A retrospective analysis of 66 CSP patients who received treatment in our hospital from January 2015 to July 2021 was performed, and participants were divided into three groups: Group one (n=14) received mifepristone followed by embryo removal treatment, Group two (n=29) received MTX followed by embryo removal, and Group three (n=23) received a methotrexate/mifepristone combined treatment followed by embryo removal. The basic findings were analysed, along with the curative effects between the three groups. Risk factors predicting additional treatment after initial intervention failure were analysed.

RESULTS: There were statistically significant differences in gestational age, hospitalization days, costs, myometrial thickness, cardiac activity, and mean sac diameter between groups ($p<0.05$) after grouping by eight weeks. The initial intervention success rates were 92.86%, 89.66%, and 65.22% in Group one, two, and three, respectively ($p<0.05$), while the complication rates were 14.29%, 6.90%, and 26.87%, respectively ($p>0.05$). After grouping according to eight weeks of gestational age, the difference in initial serum β -hCG between Group two and three was statistically significant ($p<0.05$). Mean sac diameter was a risk factor for additional treatment after initial intervention failure, with an odds ratio of 1.113 ($p<0.05$). A cut-off of 22.75 mm was a preferable indicator.

CONCLUSIONS: MTX/mifepristone followed by embryo removal is a reliable way to treat CSP. Mean sac diameter was a risk factor for additional treatment after initial intervention failure.

Key Words:

Caesarean scar pregnancy (CSP), Ultrasonography, Methotrexate, Treatment.

Introduction

A caesarean scar pregnancy (CSP) is defined as a gestational sac (GS) located in the scar of an earlier caesarean section¹. It is a late, serious complication of a caesarean section (CS). The frequency of CS is increasing worldwide², especially in China in recent years¹. Due to the increase in caesarean deliveries (CDs), the incidence of CSP is rising³. CSP may progress into placenta accreta, uterine rupture, postpartum hysterectomy, and even life-threatening haemorrhage^{4,5}. Unfortunately, there are no standardized guidelines, and it is difficult to decide on the optimal management for individual CSP cases. A variety of medications have been adopted in the treatment of CSP⁶. Methotrexate (MTX) is a folic acid antagonist⁷ that can effectively kill trophocytes, so it is widely used in the treatment of CSP. Mifepristone has different working mechanisms in preventing embryo development with MTX. This occurs mainly through its strong anti-progesterone effect, which can cause villi tissues to metamorphosis and necrosis, resulting in embryonic death⁸. The rational application of the two drugs to achieve an optimal effect is still worthy of further discussion. Surgical management mainly includes dilation and suction (D&S)^{9,10}, hysteroscopy¹¹, and laparoscopy¹². Laparotomy is usually performed in emergencies such as uterine rupture or heavy bleeding. As an embryo removal management of CSP¹⁰, D&S

carries low cost and good curative effect, but it is accompanied by risks including haemorrhage, low success rate, and even uterine perforation due to lack of direct visualization. Hysteroscopic removal of CSP is an alternative minimally invasive operation that offers direct visualization, removal of the gestational tissue entirely and rapid normalization of β -hCG, but it requires experienced surgeons who are skillful at manipulating hysteroscopic instruments¹³. This study discusses the more rational use of MTX/mifepristone in the initial stage before embryo removal in patients with CSP, as well as the risk factors associated with additional treatment after failure of the initial intervention.

Patients and Methods

Patients

This was a retrospective study conducted in the Second Hospital of Xi'an Jiaotong University. Women who visited the hospital for treatment of CSP between January 1, 2015, and July 30, 2021 were consecutively enrolled in this study. The following eligibility criteria had to be met: (1) ultrasound images confirming the diagnosis were available, and the gestational sac was clearly visible; and (2) an adequate follow-up period was

precise and registered. Exclusion criteria included cervical pregnancy, inevitable abortion, incomplete abortion, caesarean scar choriocarcinoma, and significant maternal hepatic, renal, cardiac or blood system disease. Patients who received curettage or MTX treatment before admission, uterine artery embolization, and local injection of MTX into the GS as initial treatment for CSP were also not enrolled in this study. This study obtained informed consent for all patients.

Diagnosis of CSP

CSP was diagnosed through patient history, clinical manifestations, serum β -hCG level and standard ultrasonography criteria¹ (Figure 1): (1) the development of a gestational sac in the anterior portion of the lower uterine segment; (2) an empty uterine cavity and cervical canal; and (3) the absence of a healthy myometrium between the gestational sac and the bladder.

Apparatus Examination and Clinical Records

Sonographic examinations were performed by Voluson series (GE Healthcare, Milwaukee, WI, USA) ultrasound equipment. Demographic and clinical data were recorded, including maternal age, parity, gestational age, presenting symptoms, management method, and clinical outcome, with

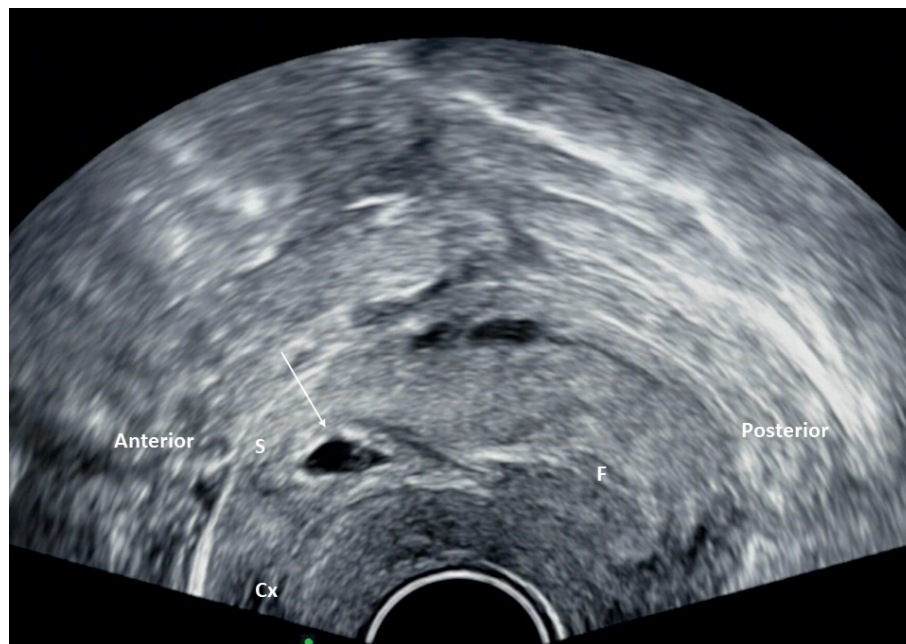


Figure 1. Transvaginal ultrasonography of the patient with caesarean scar pregnancy Transvaginal longitudinal sonogram of the lower uterine wall showing a gestational sac with a yolk sac (arrow) within the wall, at the region of caesarean section scar. The uterine cavity and cervical canal were empty. Cx, cervix; F, fundal endometrial cavity; S, scar of caesarean section.

approval from the Institutional Review Board of the Second Hospital of Xi'an Jiaotong University.

Treatment Methods and Grouping

With the exception of surgical management being chosen for women who had signs of uterine rupture or were haemodynamically unstable, the usual treatment was determined on a case-by-case basis depending on the woman's preference and presenting symptoms. For clinically stable women, medical management in the form of systemic methotrexate and/or mifepristone was given, followed by embryo removal. The initial medical treatment modalities in our study were as follows: (i) 14 patients in group one were administered oral mifepristone (50 mg twice daily, Day 2) only¹⁴; (ii) 29 patients in Group two received intramuscular MTX injection of a single dose of 50 mg/m² body surface area¹⁵ only; and (iii) 23 patients in Group three were administered 50 mg/m² body surface area MTX by intramuscular injection combined with oral mifepristone (50 mg twice daily, Day 2)¹⁴. Embryo removal was performed until ultrasound revealed the absence of blood flow velocity around the gestational sac, or serum β -hCG fell below 2000 mIU/L or was reduced by more than 60%⁸.

The embryo removal procedures included manual vacuum aspiration with a Karman cannula (D&S) under ultrasound guidance, transcervical resection (TCR) by hysteroscopy, and hysterotomy by laparotomy. The treatment modality was based on the clinician's experience with incorporating the patients' desire. The consensus for treatment involves the least invasive surgery for different CSPs. Patients who underwent D&S were in a lithotomy position. Transabdominal ultrasound was used to monitor the performance of the instruments. After adequately dilating the uterine cervical canal, suction curettage was performed to remove the retained products of conception and to remove blood clots. Sharp curettage was not performed to reduce the risk of bladder injury or uterine rupture. Patients who underwent hysteroscopy were placed in the dorsolithotomy position under spinal anaesthesia by experienced gynaecologists to remove the products of conception. After the cervix was carefully dilated by Hegar dilators from 5 mm to 11 mm, an operative hysteroscope (CA95138, Stryker, USA) with a 10 mm external diameter was placed inside the uterus under transabdominal ultrasound guidance. A continuous flow 26F hysteroscopic resectoscope with a 90-degree wire loop elec-

trode and an electrosurgical generator (VIO300S, ERBE, Germany) on a setting of 70 W of coagulation current and cutting current were used. The intervention began by identifying the implantation of the ectopic sac. First, the vessel bed of the implantation site was exposed and coagulated for haemostasis. Then, the electric loop was used without electricity to curettage the residual tissue in the diverticulum of the caesarean scar and to remove the residual villi. Finally, a hysteroscopic rolling ball was used to stop the bleeding point. Layer-by-layer laparotomy was performed under general anaesthesia. The bladder was separated from the cervix to expose the pregnancy. After injection of six units of saline into the lesion, the lesion was dissected and removed. Dilation and curettage of the uterus were then performed. The incision was sutured by a continuous double-layer lock stitch with 1-0 absorbable sutures. The peritoneum was closed using 2-0 absorbable sutures. The amount of bleeding during surgery was observed in all patients.

Our definition of complications included blood loss greater than 500 mL during and after treatment and internal organ injuries associated with treatment¹⁵. Treatment failure was defined as a reduction in serum β -hCG titer by <15% or an increase in serum β -hCG titer from pretherapy levels one week after initial treatment; these patients needed additional treatment¹⁶.

Follow-Up

Postoperative follow-up and telephone follow-up occurred until their serum β -hCG value returned to normal. Follow-up was focused on the patients' serum β -hCG, transvaginal colour Doppler ultrasound and any additional complications, including abnormal vaginal bleeding, abdominal pain, and intrauterine adhesions.

Statistical Analysis

Data are expressed as the mean \pm standard deviation (SD) and case number (n). All statistical analyses were performed with SPSS version 18.0 (SPSS Inc., Chicago, IL, USA). Comparisons between unpaired groups were made by the chi-squared (χ^2) test or Fisher's exact test for categorical variables. Comparisons for continuous variables between the three groups were performed using one-way analysis of variance (ANOVA) or the Kruskal-Wallis test according to homogeneity of variance. Comparisons for continuous variables between the two groups were performed using independent *t*-tests or Mann-Whitney U

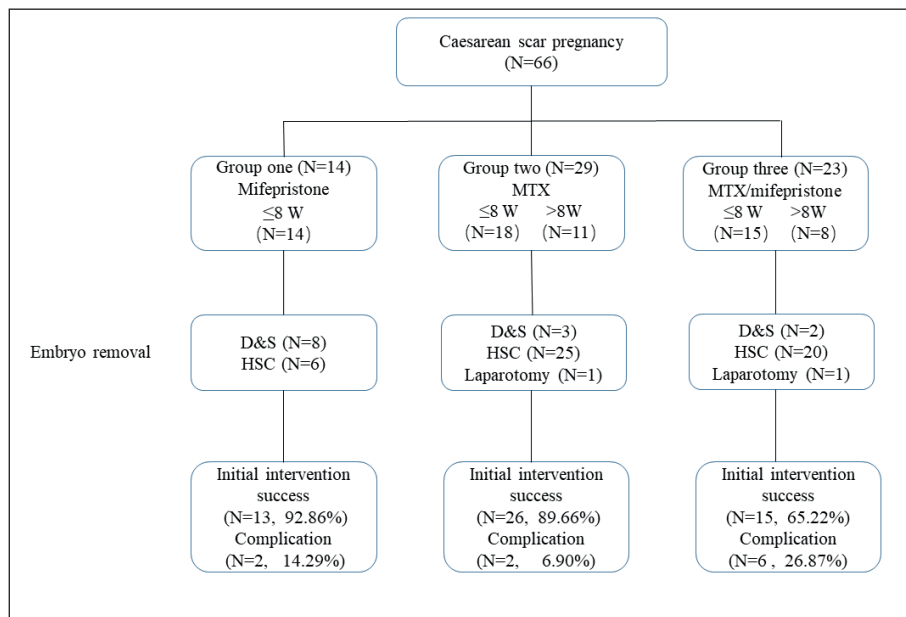


Figure 2. Flow chart of patients. W, weeks; MTX, methotrexate; D&S, dilation and suction; HSC, hysteroscopic resection.

tests according to homogeneity of variance. Logistic regression analysis and receiver operating characteristic (ROC) curve analysis were used to evaluate factors predicting additional treatment after initial intervention failure. A $p < 0.05$ was considered statistically significant.

Results

A total of 66 patients were admitted with CSP during the study period. The clinical characteristics of pregnancies are shown in Table I. According to our initial medical treatment modalities, 14, 29, and 23 patients were categorized as Group one, Group two and Group three, respectively. There were no statistically significant differences in the demographic characteristics between the three groups, except for a gestational age of >8 weeks, myometrial thickness, cardiac activity, mean sac diameter, hospitalization cost and hospitalization days. Women's ages ranged from 21.0 to 44.0 years (mean: 32.86 ± 4.64 years). The gestational age at diagnosis ranged from 5.29 to 12 weeks (mean: 7.37 ± 1.39 weeks) in our study, and there was no statistical significance between groups. Patients in Group one all showed a low gestational age (≤ 8 weeks) at the time of diagnosis and treatment. Eleven patients (37.93%) in Group two and eight patients (34.78%) in Group three had a gestational age of >8 weeks (Figure 2). There was a statisti-

cally significant difference after grouping according to eight gestational weeks. The mean time interval between the last CS and CSP was 65.76 ± 51.87 months (range 5-252 months). Regarding the number of caesarean sections before CSP, out of the 66 women who participated in the study, 40 (60.61%) had a caesarean section, and 26 (39.39%) had two CDs. The mean number of prior dilations and curettages was 0.76 ± 1.02 (range 0-4). There was one case of uterine rupture with surgical repair, and one previous case of surgical resection of CSP with repair of CS in Group three. A total of 26 (39.39%) patients had no symptoms, and irregular vaginal bleeding (35 patients, 53.03%) and abdominal pain (17 patients, 25.76%) were the most common presenting symptoms.

Ultrasonography of our cases showed a mean myometrial thickness of 3.45 ± 1.33 mm (range 1.20-8.0 mm), a mean sac diameter of 18.47 ± 9.92 mm (range 7.50-54.0 mm) and foetal heartbeat in 27 (40.91%) patients. The ultrasonographic findings of CSP significantly differed from the treatment groups ($p < 0.05$). Compared with Group one, Group two and Group three showed a thinner myometrial thickness and a higher percentage of cardiac activity. There was no significant difference between Group two and Group three. Further comparing the gestational sac diameter between each group, the sac diameter of Group three was significantly larger than that of Group one ($p = 0.008 < 0.05$).

Although there was no significant difference in the initial serum β -hCG level among the treatment groups (Table II), the situation was different after grouping according to eight weeks of gestational age (Figure 3). In patients with less than eight gestational weeks, there was no significant difference between treatment groups ($p < 0.05$). In patients with more than eight gestational weeks, there was a significant difference between Group two and Group three ($p = 0.029 < 0.05$). The time of serum β -hCG resolution after embryo removal did not differ between groups. Eight, three and two patients underwent ultrasound-guided D&S, and 6, 25, and 20 patients underwent hysteroscopic resection (HSC) of gestational tissue in Group one, Group two, and Group three, respectively (Table II). One woman in Group two underwent edge excision of the CSP by laparotomic hysterotomy with successful repair of the myometrial scar. A 32-year-old woman in Group three who underwent excision of CSP by laparotomic hysterotomy as primary surgical treatment had ultrasonographic findings of extremely thin myometrium and almost penetrating uterine serosa. The initial intervention success rates were 92.86%, 89.66%,

and 65.22% in Groups one, two, and three, respectively, while the complication rates were 14.29%, 6.90%, and 26.87%, respectively (Table II). Based on Fisher's exact test, Group three had a slightly lower initial success rate, and the complication rate showed no significant difference between groups. Two cases were found to have placenta accreta after embryo removal and needed additional treatment, one case in Group two, and one in Group three. Hysterotomy by laparotomy was performed in two women as a primary surgical treatment, one due to severe abdominal pain and bleeding suggestive of scar rupture at eight weeks of gestation in Group two, and another in Group 3 with heavy vaginal bleeding and a history of surgical resection of CSP five years prior whose ultrasonographic findings showed GS bulged out and covered only by uterine serosa. Additional treatment with intralesional methotrexate was given to three women who had developed foetal cardiac activity after intramuscular methotrexate therapy, one in Group two and two in Group three.

Table III lists the results of univariate analysis of risk factors for additional treatment after initial intervention failure. It is clear that the group that

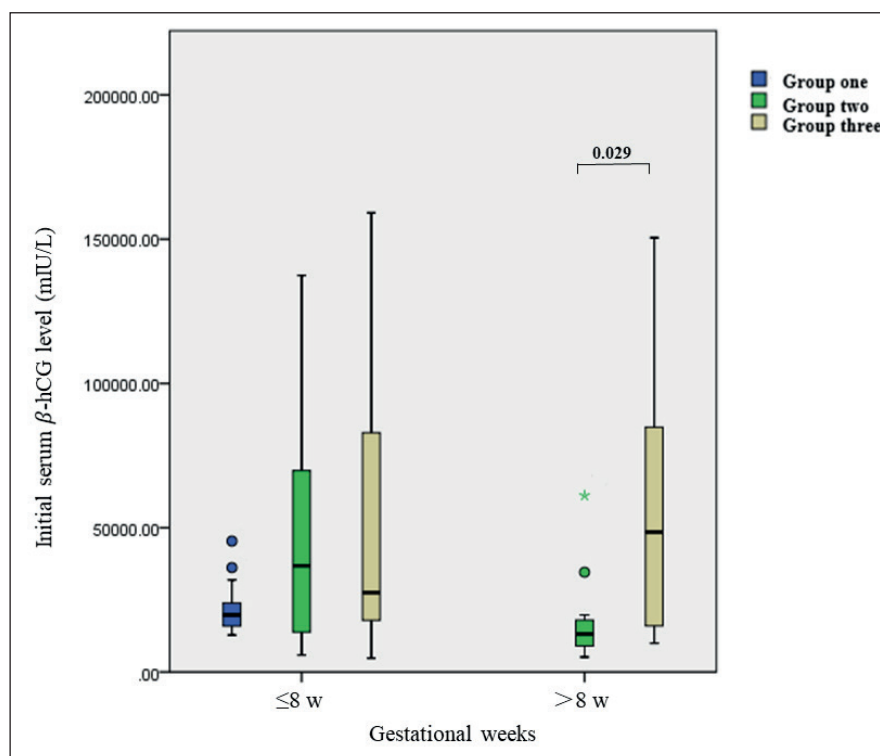


Figure 3. Comparison of initial serum β -hCG level between treatment's groups at different gestational weeks. Gestational weeks, ≤ 8 w, Less than or equal to eight weeks, > 8 w, more than eight weeks; β hCG, human chorionic gonadotropin; W, weeks

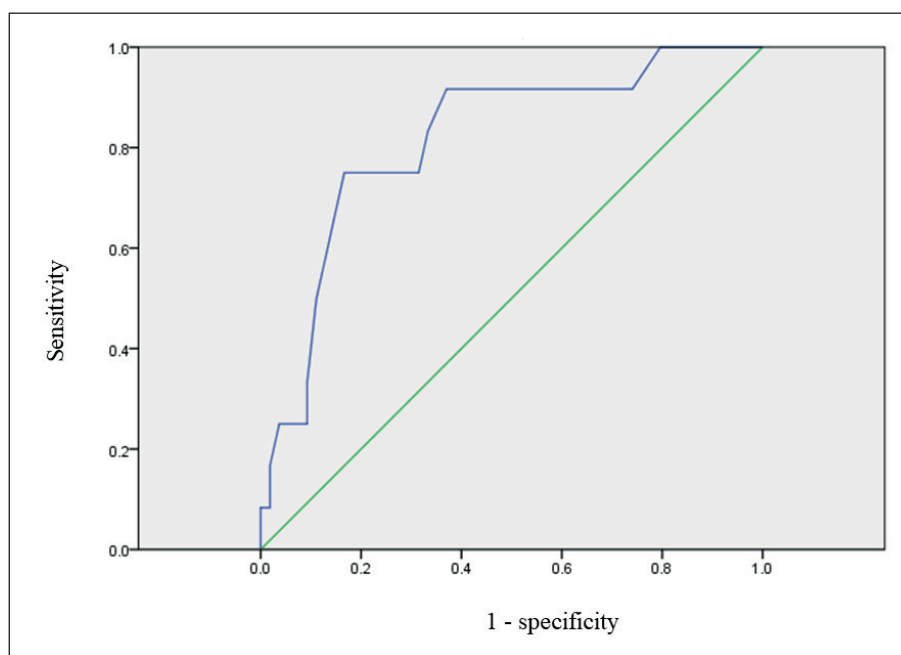


Figure 4. Receiver operating characteristic (ROC) curve analysis of risk factor for additional treatment of CSP. The AUC for mean sac diameter.

needed additional treatment had a significantly higher mean sac diameter and belonged to different treatment groups ($p < 0.05$). In the binary logistic regression model, only mean sac diameter was a significant risk factor for additional treatment after initial intervention failure, with an odds ratio of 1.113 (CI 95%: 1.036-1.196, $p = 0.003 < 0.05$). The ROC curve analysis was used to evaluate risk factors capable of predicting additional treatment. The area under the curve (AUC) for the mean sac diameter was 0.816 (CI 95%: 0.684-0.949, $p = 0.001$) (Figure 4). For the mean sac diameter, a cut-off of 22.75 mm was the preferable indicator.

Discussion

Various treatment strategies, including expectant, medical and surgical methods, are performed for CSP, but unfortunately, its optimal management remains to be determined¹⁷. A previous study⁶ found approximately 31 primary treatment methods for 751 CSP patients, and the highest number of complications were those involving the use of MTX alone (62%) with D&S (62%). Due to the high complications and long treatment period of using the pharmacological approach alone, our centre has mainly carried out pharmacological approaches combined with embryo removal, including D&S, hysteroscopy and laparotomic

hysterotomy, for the treatment of CSP. The first phase of the pharmacological approach includes mifepristone only, MTX only, and mifepristone combined with MTX.

The clinical features of CSP differ among different types. Previous studies^{18,19} have shown that more than half of patients experience vaginal bleeding as an early symptom of CSP. In terms of clinical symptoms, our study was consistent with previous reports and showed no significant difference between treatment groups. Our study also showed that there was no difference in the average gestational age among the three groups, but that after grouping by eight gestational weeks, there were more cases diagnosed in Group two and Group three. However, Group one had shorter hospitalization days and a lower hospitalization cost. Based on these reports and our results, we strongly recommended paying more attention to patients after caesarean section. Early detection of CSP is critical to optimizing the therapeutic protocol and shortening the hospital stay. The ultrasonographic findings of CSP in our study showed significant differences between treatment groups ($p < 0.05$). Group one showed a thicker myometrium, smaller mean sac diameter, and a lower proportion of cardiac activity in the gestational sac. This implied that ultrasonographic findings not only played a very important role in the early diagnosis of CSP but also might contribute to the choice of treatment

Table I. Demographic characteristics (n=66).

	Group one	Group two	Group three	<i>p</i>
Case number (n)	14	29	23	
General information				
Age* (mean±SD)	33.64±5.61	32.59±4.75	32.74±3.97	0.778
Gestational age* (wks) (mean±SD)	6.58±0.84	7.58±1.48	7.59±1.43	0.057
Gestational age>8 wks [§] (n,%)	0	11 (37.93%)	8 (34.78%)	0.015
Internal from prior cesarean section (months)* (mean±SD)	74.57±53.70	63.28±52.70	63.52±51.46	0.779
Number of prior cesarean sections* (mean±SD)	1.43±0.51	1.41±0.50	1.35±0.49	0.857
Number of prior dilatation and curettage* (mean±SD)	1.07±0.92	0.72±1.19	0.61±0.89	0.417
Number of prior CSP (n)	0	0	1	
Operations (n)				
No	14	29	21	
Uterine rupture and surgical repair	0	0	1	
Surgical resection of CSP with repair of CS	0	0	1	
Hospitalization days [†] (median, range)	7.0 (4.0-13.0)	14.0 (6.0-25.0)	15.0 (7.0-28.0)	<0.001
Hospitalization cost (yuan)* (mean±SD)	6098.79±2436.05	10439.38±2254.64	11872.52±3123.73	<0.001
Symptoms of the patients at presentations[§] (n, %)				
Irregular vaginal bleeding	7 (50%)	18 (62%)	10 (43%)	0.397
Abdominal pain	3 (21.43%)	7 (24.14%)	7 (30.43%)	0.802
Ultrasonographic findings of CSP				
Myometrial thickness (mm)* (mean±SD)	5.21±1.20	3.15±0.93	2.75±0.81	<0.001
Cardiac activity in gestational sac (Yes/no) [§] (n, %)	2 (14.29%)	12 (41.38%)	13 (56.52%)	0.010
Mean sac diameter(mm) [†] (median, range)	15.0 (8.0-19.0)	14.5 (7.5-51.0)	13.5 (9.0-54.0)	0.017

n: number. wks: weeks. Range, min-max. *ANOVA test. §Chi-squared test. †Kruskal-Wallis test.

options. Timor-Tritsch et al²⁰ have suggested that detailed transvaginal ultrasonography for CSP, such as screening for aneuploidy, should be performed in pregnant women with a history of caesarean section at gestational weeks 5-7.

After mifepristone/MTX treatment, embryo removal was finally performed in all three groups according to the decline in serum β -hCG levels. Some studies reported^{3,21} that expectant management was not considered an appropriate approach because the histopathologic features of CSP prevented complete detachment of the gestational sac from the scar diverticulum, exposing the pregnant woman to a high-risk haemorrhagic event. In our study group, we had no expectant management in the study period. There was no significant difference noted in serum β -hCG resolution time after embryo removal and complication rate ($p>0.05$) among treatment groups. However, embryo removal modalities differed among treatment groups. More patients in Group one underwent

ultrasound-guided D&S, while more patients in Groups two and three underwent HSC. One patient in Group two and one patient in Group three underwent laparotomic hysterotomy. This may be related to the complexity of the patient's initial condition and ultrasonographic findings. A previous report¹⁵ showed that the thinner the myometrium between the gestational sac and the bladder, the more difficult the treatment is, and the more likely surgery is. The thickness of the uterine myometrium in the above two patients was very thin, measuring only 1.5 mm for the patient in Group two and 1.2 mm for the patient in Group three. Patients in Group one had fewer gestational weeks, smaller gestational sac diameters, and thicker myometriums, so there were more cases of ultrasound-guided D&S with low cost, less injury, and rapid recovery. More patients in Group two and Group three chose hysteroscopy as the option with better visualization, but which was relatively expensive. Hysteroscopic resections

could offer accurate diagnosis by observing the CSP gestational tissue at the implantation site and offering appropriate management by separating the gestational tissue from the uterine wall and coagulating the blood vessels directly²². Laparotomy could effectively remove the residual gestational tissue and repair the 'niche' simultaneously²³. However, laparotomy and uterine repair could become complicated by postoperative intra-abdominal adhesions and poor scar healing, which might have adverse effects on women's fertility. Therefore, laparotomy is usually only performed in emergency situations (such as uterine rupture or heavy bleeding) in the treatment of CSP. In our study, surgical management was performed in two women as a primary treatment, one due to severe abdominal pain and bleeding suggestive of scar rupture, and another with a history of surgical resection of CSP and heavy vaginal bleeding. On ultrasonographic findings, the GS bulged out and was covered only by the uterine serosa. Regardless of the drug treatment protocol, there was no significant difference in the time of serum β -hCG resolution among treatment groups. This indicated that as different methods of embryo removal, D&S, HSC, and laparotomic hysterotomy could all quickly reduce serum β -hCG levels according to the different initial conditions of patients.

Our data showed that there was no significant difference in initial serum β -hCG among treatment groups ($p>0.05$). After grouping according to eight weeks of gestational age, those who were less than eight gestational weeks were further compared among groups, and there was no significant difference found among groups. At more than eight gestational weeks, there was a significant difference between Group two and Group three ($p<0.05$) (Figure 3). This may be due to the doctors' preference for MTX combined with mifepristone as an initial medical treatment protocol for patients with relatively complicated conditions, such as higher gestational age and a high level of initial serum β -hCG. Methotrexate and mifepristone have different working mechanisms in preventing embryo development⁸. The combined use of the two drugs may play a stronger role in embryocidal effects. This also further showed that the use of mifepristone alone as initial medical treatment combined with embryo removal was not recommended for patients with gestational age greater than eight weeks and high initial serum β -hCG levels. For CSP cases with a larger gestational age and a high level of initial se-

rum β -hCG, MTX combined with mifepristone as the initial medical treatment was recommended.

Most published studies²⁴⁻²⁶ have explored the relationship between gestational sac diameter and the success rate of treating complications. Wang et al²⁴ reported that a gestational sac of >5 cm in CSP is an independent risk factor for the failure of conservative treatment. Our study focused on the relationship between gestational sac diameter and additional treatment after initial intervention failure and showed that the group that needed additional treatment had a significantly higher mean sac diameter and belonged to different initial treatment groups ($p<0.05$). As mentioned above, this may be related to the more complex condition of patients in Group three prior to treatment. In the further binary logistic regression model, only mean sac diameter was a significant risk factor for additional treatment after initial intervention failure, with an odds ratio of 1.113 (CI 95%: 1.036-1.196, $p=0.003\leq 0.05$). For the mean sac diameter, a cut-off of 22.75 mm was the preferable indicator evaluated by the ROC curve (AUC 0.816). This implied that gestational sac diameter in CSP is an independent risk factor for additional treatment after initial intervention failure.

A limitation of this study is that its retrospective nature may contain selection bias regarding the patients involved, and more prospective studies are needed. Another limitation of this study is that the population size of this study is not strong enough, the conclusions may be limited, and a much larger population is needed. In addition, our study population was Chinese, and our results may not be applicable to other ethnic groups.

Conclusions

Our study shows that MTX/mifepristone followed by embryo removal is a reliable way to treat caesarean scar pregnancy. Methotrexate alone or MTX combined with mifepristone is recommended as the first option for initial medical treatment for patients with large gestational weeks, thin myometrium, and high level of initial serum β -hCG, in conjunction with embryo removal. For CSP patients with MTX contraindications or an unwillingness to use MTX, when the gestational age is less than eight weeks, the uterine myometrium is not very thin and has a relatively low initial β -hCG level. Mifepristone alone can be considered in the initial medical treatment stage, followed by embryo removal. Mean sac diameter

was a significant risk factor for additional treatment after initial intervention failure, and a cut-off of 22.75 mm was the preferable indicator. The standard treatment to manage CSP patients has not yet been established. However, the personalized evaluation of the condition before treatment could support doctors in making better choices in terms of efficacy and safety.

Conflicts of interest

The authors declare that they have no conflicts of interest.

Funding

The present study was sponsored by the National Natural Science Foundation of China (Grant No. 82001843).

References

- 1) Qian ZD, Weng Y, Du YJ, Wang CF, Huang LL. Management of persistent caesarean scar pregnancy after curettage treatment failure. *BMC Pregnancy Childbirth* 2017; 17: 208.
- 2) Birch Petersen K, Hoffmann E, Rifbjerg Larsen C, Svarre Nielsen H. Cesarean scar pregnancy: a systematic review of treatment studies. *Fertil Steril* 2016; 105: 958-967.
- 3) Giampaolino P, De Rosa N, Morra I, Bertrando A, Di Spiezio Sardo A, Zizolfi B, Ferrara C, Della Corte L, Bifulco G. Management of Cesarean Scar Pregnancy: A Single-Institution Retrospective Review. *Biomed Res Int* 2018; 2018: 6486407.
- 4) Pekar-Zlotin M, Melcer Y, Levinsohn-Tavor O, Tovbin J, Vaknin Z, Maymon R. Cesarean Scar Pregnancy and Morbidly Adherent Placenta: Different or Similar? *Isr Med Assoc J* 2017; 19: 168-171.
- 5) Zosmer N, Fuller J, Shaikh H, Johns J, Ross JA. Natural history of early first-trimester pregnancies implanted in Cesarean scars. *Ultrasound Obstet Gynecol* 2015; 46: 367-375.
- 6) Timor-Tritsch IE, Monteagudo A. Unforeseen consequences of the increasing rate of cesarean deliveries: early placenta accreta and cesarean scar pregnancy. A review. *Am J Obstet Gynecol* 2012; 207: 14-29.
- 7) De Abreu CC, Rosa PC, Alves Bda C, Azzalis LA, Gehrke Fde S, Pereira EC, Junqueira VB, Perazzo FF, Fonseca FL. Development and validation of HPLC method to determination of Methotrexate in children oncologic patients. *Eur Rev Med Pharmacol Sci* 2015; 19: 1373-1380.
- 8) Li YY, Yin ZY, Li S, Xu H, Zhang XP, Cheng H, Du L, Zhou XY, Zhang B. Comparison of transvaginal surgery and methotrexate/mifepristone-combined transcervical resection in the treatment of cesarean scar pregnancy. *Eur Rev Med Pharmacol Sci* 2017; 21: 2957-2963.
- 9) Bayoglu Tekin Y, Mete Ural U, Balik G, Ustuner I, Kir Sahin F, Guvendag Guven ES. Management of cesarean scar pregnancy with suction curettage: a report of four cases and review of the literature. *Arch Gynecol Obstet* 2014; 289: 1171-1175.
- 10) Huang L, Du Y, Zhao C. High-intensity focused ultrasound combined with dilatation and curettage for Cesarean scar pregnancy. *Ultrasound Obstet Gynecol* 2014; 43: 98-101.
- 11) Wang CJ, Tsai F, Chen C, Chao A. Hysteroscopic management of heterotopic cesarean scar pregnancy. *Fertil Steril* 2010; 94: 1529 e1515-1529 e1518.
- 12) Wang G, Liu X, Bi F, Yin L, Sa R, Wang D, Yang Q. Evaluation of the efficacy of laparoscopic resection for the management of exogenous cesarean scar pregnancy. *Fertil Steril* 2014; 101: 1501-1507.
- 13) Casadio P, Ambrosio M, Verrelli L, Salucci P, Arena A, Seracchioli R. Conservative cesarean scar pregnancy treatment: local methotrexate injection followed by hysteroscopic removal with hysteroscopic tissue removal system. *Fertil Steril* 2021; 116: 1417-1419.
- 14) Zhang Y, Gu Y, Wang JM, Li Y. Analysis of cases with cesarean scar pregnancy. *J Obstet Gynaecol Res* 2013; 39: 195-202.
- 15) Lin SY, Hsieh CJ, Tu YA, Li YP, Lee CN, Hsu WW, Shih JC. New ultrasound grading system for cesarean scar pregnancy and its implications for management strategies: An observational cohort study. *PLoS One* 2018; 13: e0202020.
- 16) Kim YR, Moon MJ. Ultrasound-guided local injection of methotrexate and systemic intramuscular methotrexate in the treatment of cesarean scar pregnancy. *Obstet Gynecol Sci* 2018; 61: 147-153.
- 17) Tahaoglu AE, Dogan Y, Bakir MS, Bagli I, Peker N, Cavus Y, Togrul C, Tahaoglu Z. A single centre's experience of caesarean scar pregnancy and proposal of a management algorithm. *J Obstet Gynaecol* 2019; 39: 259-264.
- 18) Yin X, Huang S. Clinical characteristics and treatment of different types of cesarean scar pregnancy. *Ginekol Pol* 2020; 91: 406-411.
- 19) Luo L, Ruan X, Li C, Chen S, Hu Q, Mueck AO. Early clinical features and risk factors for cesarean scar pregnancy: a retrospective case-control study. *Gynecol Endocrinol* 2019; 35: 337-341.
- 20) Timor-Tritsch IE, D'Antonio F, Cali G, Palacios-Jarquemade J, Meyer J, Monteagudo A. Early first-trimester transvaginal ultrasound is indicated in pregnancy after previous Cesarean delivery: should it be mandatory? *Ultrasound Obstet Gynecol* 2019; 54: 156-163.
- 21) Jayaram P, Okunoye G, Al Ibrahim AA, Ghani R, Kalache K. Expectant management of caesarean scar ectopic pregnancy: a systematic review. *J Perinat Med* 2018; 46: 365-372.

- 22) Deans R, Abbott J. Hysteroscopic management of cesarean scar ectopic pregnancy. *Fertil Steril* 2010; 93: 1735-1740.
- 23) Ben Nagi J, Ofili-Yebovi D, Sawyer E, Aplin J, Jurkovic D. Successful treatment of a recurrent Cesarean scar ectopic pregnancy by surgical repair of the uterine defect. *Ultrasound Obstet Gynecol* 2006; 28: 855-856.
- 24) Wang M, Yang Z, Li Y, Chen B, Wang J, Ma X, Wang Y. Conservative management of cesarean scar pregnancies: a prospective randomized controlled trial at a single center. *Int J Clin Exp Med* 2015; 8: 18972-18980.
- 25) Ma Y, Shao M, Shao X. Analysis of risk factors for intraoperative hemorrhage of cesarean scar pregnancy. *Medicine (Baltimore)* 2017; 96: e7327.
- 26) Wu X, Xue X, Wu X, Lin R, Yuan Y, Wang Q, Xu C, He Y, Hu W. Combined laparoscopy and hysteroscopy vs. uterine curettage in the uterine artery embolization-based management of cesarean scar pregnancy: a cohort study. *Int J Clin Exp Med* 2014; 7: 2793-2803.