

# Hydroxyurea-induced interstitial pneumonitis: case report and review of the literature

M. INTERNULLO, V. GIANNELLI<sup>1</sup>, L. SARDO, C. ANTONAGLIA,  
T. VILLANI, E. ANGELICI, P. PALANGE

Department of Public Health and Infectious Diseases, "Sapienza" University of Rome, Rome, Italy

<sup>1</sup>Department of Gastroenterology, "Sapienza" University of Rome, Rome, Italy

**Abstract.** – Hydroxyurea is a cytotoxic agent widely used in the treatment of myeloproliferative disorders. It is considered a well-tolerated anti-neoplastic drug, with a dose-related bone marrow suppression as main adverse effect. This report describes a patient with essential thrombocytopenia who developed an interstitial pneumonitis and respiratory failure within 4 years from beginning therapy with hydroxyurea (HU). After discontinuing of HU, both clinical and radiological resolution of pneumonitis occurred. In conclusion, HU-induced pulmonary toxicity is a potentially life-threatening side effect.

*Key Words:*

Interstitial pneumonitis, Hydroxyurea, Pulmonary toxicity.

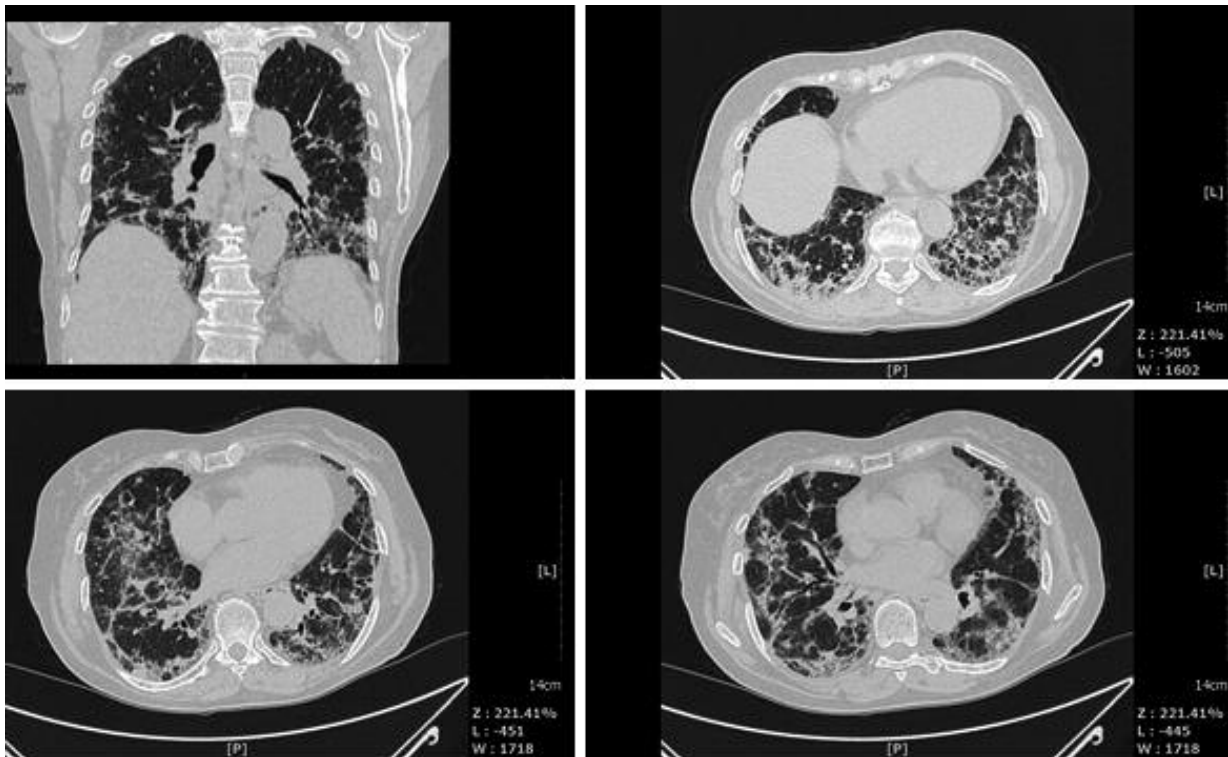
## Introduction

Several chemotherapy drugs have been associated with pulmonary toxicity including busulphan, bleomycine, chlorambucil, cyclophosphamide, cytosine arabinoside, melphalan, methotrexate, mitomycin and procarbazine<sup>1,2</sup>. Hydroxyurea (HU), a ribonucleotide reductase inhibitor, has been increasingly utilized, rather than busulphan, to control myeloproliferative disorders, mainly because of its relative lack of severe adverse effects<sup>3</sup>. Apart from dose-related bone marrow suppression, this antineoplastic agent is generally well tolerated. Fever and pulmonary side effects as hydroxyurea-induced acute alveolitis are extremely rare<sup>4,5</sup>. We report a case of interstitial pneumonitis in a patient treated with HU for essential thrombocytopenia.

## Case Report

A 77-year-old woman was admitted to our Hospital because of severe dyspnoea and respiratory failure. Her past medical history included pleurisy in young age and cholecystectomy due to sympto-

matic gallstones. Four years before admission, she was referred to a hematologist for increased platelet count (700,000/ml). After confirmation of high platelet count she underwent bone marrow biopsy, which demonstrated essential thrombocytopenia, according to Polycythemia Vera Study Group (PVSG) diagnostic criteria<sup>6</sup>. Investigation for JAK2 mutation showed positive results. After a first period of 1 year treatment with aspirin (100 mg/daily), platelet count started to rise progressively up to 1,000,000 mm<sup>3</sup>. Treatment with HU was then established at a dose of 500 mg/daily. In the following 3 weeks platelet count returned almost at normal values (425,000 mm<sup>3</sup>). One month before admission in our Hospital, the patient presented progressive dyspnoea and dry cough and was treated by the general practitioner with levofloxacin 750 mg/daily and prednisolone 40 mg/daily without clinical improvement. At admission, blood pressure and pulse rate were within the normal limits; the patient was afebrile. Chest examination revealed bilateral fine crackles at lung bases. Arterial blood gas analysis, on room air, showed type 1 respiratory failure (PaO<sub>2</sub> 59 mmHg, PaCO<sub>2</sub> 38 mmHg, pH 7.42, HCO<sub>3</sub><sup>-</sup> 24.6 mmol/l) and oxygen therapy was promptly started. Chest X-Ray showed multiple bilateral opacities, flowing together at both lung bases. Routine blood test, including serum autoimmunity screening, were negative. Cultures from blood and sputum were negative. Serological searches for viral infection (*Varicella-zoster*, *CMV*, *Herpes simplex 1*, *Herpes simplex 2*, *Adenovirus*) and for bacteria (*Legionella pneumophila*, *Mycoplasma pneumoniae*, *Chlamydia pneumoniae*) were negative. HRCT scan of the chest revealed fine honeycombing, more evident at lung bases and in the subpleuric zones, and small areas of ground-glass at the upper lobes (Figure 1). Lung function tests showed a restrictive pattern: TLC 3.62 l (72% predicted), DL<sub>CO</sub>/VA 51% predicted. Bronchoscopy



**Figure 1.** HRCT scan images (axial and coronal). Diffuse reticular opacities are present predominantly at the lung bases. At the same level, diffuse interstitial thickening more evident at the left lung.

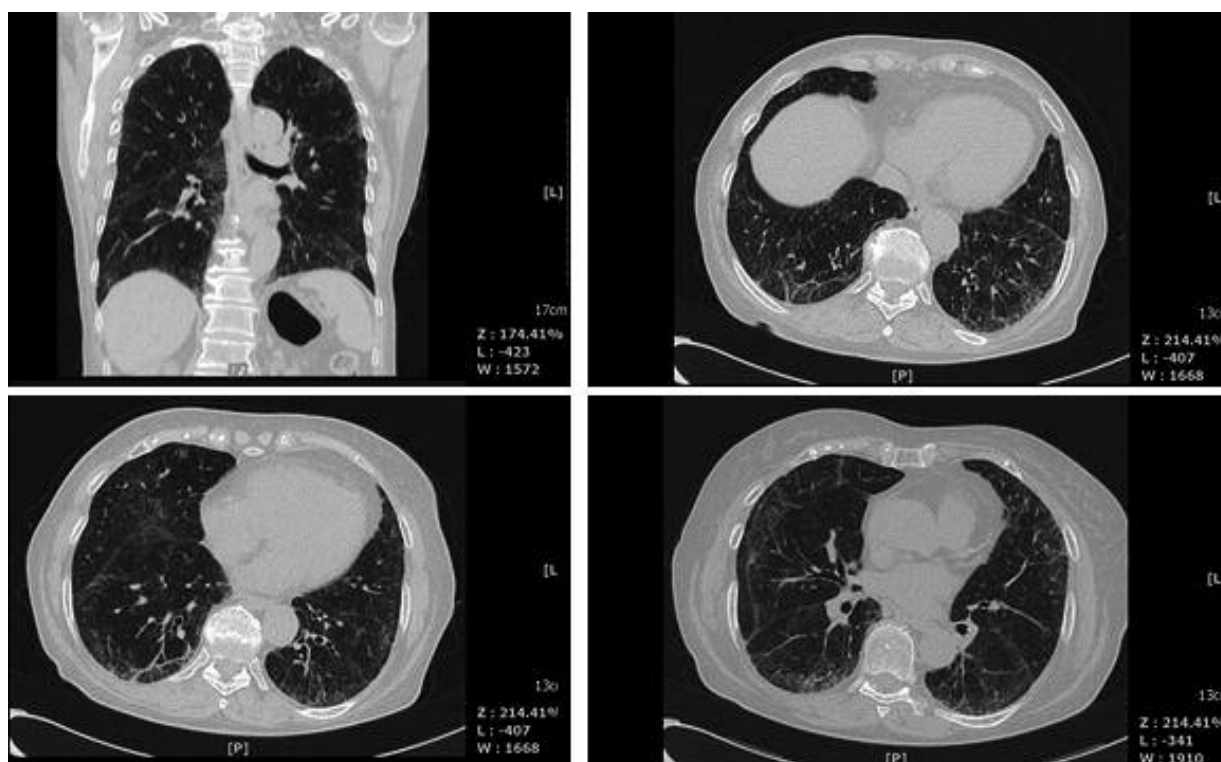with bronchoalveolar lavage fluid (BALF) was then performed. Analysis of BALF revealed: 350,000 cells  $\text{mm}^3$  (78% macrophages, 20% neutrophils, 2% eosinophils). Bacterioscopic and cultural tests for bacteria, fungi and *M. tuberculosis* on BALF were all negative. HU was discontinued and N-Acetyl-Cysteine was started (600 mg 3 times/day). Prednisone treatment was progressively tapered within 3 weeks. At two-months follow-up, a significant improvement in symptoms and HRCT scan findings (Figure 2) were observed. In addition, arterial blood gas analysis on room air showed a significant improvement:  $\text{PaO}_2$  78 mmHg,  $\text{PaCO}_2$  39 mmHg, pH 7.42,  $\text{HCO}_3^-$  25 mmol/l. Lung function tests improved as well: TLC 4.1 l (82% predicted),  $\text{DL}_{\text{CO}}/\text{VA}$  70% predicted. At one year follow-up, a further reduction in lung abnormalities at HRCT scan was noticed.

## Discussion

Wong et al<sup>7</sup> described a unique case of HU-induced pneumonitis after prolonged drug exposure; clinical symptoms and radiological signs of pulmonary toxicity developed after 2 years of

HU treatment. Only 6 other cases of HU-induced alveolitis or interstitial pneumonitis, with an acute or a subacute onset, have been reported in the literature<sup>4,5,8-11</sup>. To the best of our knowledge, this report represents the first case in which clinical symptoms and radiological signs developed 4 years from HU initial treatment. An infectious and/or an immunologic etiology of the interstitial pneumonitis was excluded, on the basis of the serologic and microbiological tests. The improvement in the clinical status and in the laboratory and instrumental findings associated to the discontinuation of HU treatment speaks in favor of a drug induced lung toxicity.

HU is a ribonucleotide reductase inhibitor. The mechanism of action is based on its reduction of production of deoxyribonucleotides via inhibition of the enzyme ribonucleotide reductase by scavenging tyrosyl free radicals as they are involved in the reduction of nucleoside diphosphates<sup>12</sup>. It is used principally in myeloproliferative disorders as polycythemia vera and essential thrombocytosis but also in sickle cell disease, associated with antiretroviral therapy in AIDS, and in psoriasis as second line therapy<sup>13-16</sup>. HU main side effect is a dose-related bone mar-



**Figure 2.** HRCT scan images (axial and coronal). One month after HU discontinuation, a significant reduction of pulmonary interstitial infiltrates is observed.

row suppression. Other side effects include gastrointestinal symptoms, stomatitis, impairment of renal tubular function, dysuria, transient elevation of hepatocellular enzymes, alopecia and rash<sup>3</sup>. HU-induced pulmonary toxicity is extremely rare: literature reported cases consists mainly of acute alveolitis or interstitial pneumonitis<sup>8</sup>. Interstitial lung disease may be related to infective or autoimmune diseases, environmental exposure, radiations, aspiration or idiopathic<sup>17</sup>. In our patient, HRCT findings were compatible with a diagnosis of interstitial pneumonitis, likely evolving into pulmonary fibrosis. An infectious cause was excluded, and an autoimmune nature was also ruled out. Also other possible causes of interstitial pneumonitis, such as environmental exposure or radiotherapy were excluded. The dramatic clinical and instrumental improvement after HU discontinuation and steroids tapering strongly support the diagnosis of drug induced lung injury. In the literature, previous cases of HU induced interstitial pneumonitis were also treated with HU cessation alone or with the addition of steroids, which can have a role in hastening resolution of ground-glass infiltrates associated with active inflammation<sup>18</sup>. In

our case, together with the discontinuation of HU therapy, steroids treatment was also discontinued to avoid possible confounding effects.

## Conclusions

Drug induced interstitial pneumonia should be considered in patients under HU and presenting with respiratory symptoms, such as exertional dyspnoea. HU-induced interstitial pneumonitis can occur even after several years from initial treatment. If not diagnosed, HU-induced interstitial pneumonitis may lead to respiratory failure and lung fibrosis.

## Conflict of Interest

The Authors declare that there are no conflicts of interest.

## References

- 1) TWOHIG KJ, MATTHAY RA. Pulmonary effects of cytotoxic agents other than bleomycin. *Clin Chest Med* 1990; 11: 31-54.
- 2) KREISMAN H, WOLKOVE N. Pulmonary toxicity of anti-neoplastic therapy. *Semin Oncol* 1992; 19: 508-520.

- 3) DORR RT, VON HOFF DD. Cancer chemotherapy handbook. 2<sup>nd</sup> ed. Norwalk, CT: Appleton & Lange 1994.
- 4) JACKSON GH, WALLIS J, LEDINGHAM J, LENNARD A, PROCTOR SJ. Hydroxyurea-induced acute alveolitis in a patient with chronic myeloid leukaemia. *Cancer Chemother Pharmacol* 1990; 27: 168-169.
- 5) HENNEMANN B, BROSS KJ, REICHEL A, ANDRESEN R. Acute alveolitis induced by hydroxyurea in a patient with myeloproliferative syndrome. *Ann Hematol* 1993; 67: 133-134.
- 6) MURPHY S, PETERSON P, ILAND H, LASZLO J. Experience of the Polycythemia Vera Study Group with essential thrombocythemia: a final report on diagnostic criteria, survival, and leukemic transition by treatment. *Semin Hematol* 1997; 34: 29-39.
- 7) WONG CC, BROWN D, HOWLING SJ, PARKER NE. Hydroxyurea-induced pneumonitis in a patient with chronic idiopathic myelofibrosis after prolonged drug exposure. *Eur J Haematol* 2003; 71: 388-390.
- 8) SANDHU HS, BARNES PJ, HERNANDEZ P. Hydroxyurea-induced hypersensitivity pneumonitis: A case report and literature review. *Can Respir J* 2000; 7: 491-495.
- 9) KAVURU MS, GADSEN T, LICHTIN A, GEPHARDT G. Hydroxyurea induced acute interstitial lung disease. *South Med J* 1994; 87: 767-769.
- 10) BLANC PL, JOASSON JM, HAMMOUD H, MATUSSIERE Y. Acute interstitial pneumopathy with fever caused by hydroxyurea. *Presse Med* 2000; 29: 242-245.
- 11) QUINTAS-CARDAMA A, PEREZ-ENCINAS M, GONZALEZ S, BENDANA A, BELLO JL. Hydroxyurea induced acute interstitial pneumonitis in a patient with essential thrombocythemia. *Ann Hematol* 1999; 78: 187-188.
- 12) PLATT OS. Hydroxyurea for the treatment of sickle cell anemia. *N Engl J Med*. 2008; 358: 1362-1369.
- 13) HARRISON CN, CAMPBELL PJ, BUCK G, WHEATLEY K, EAST CL, BAREFORD D, WILKINS BS, VAN DER WALT JD, REILLY JT, GRIGG AP, REVELL P, WOODCOCK BE, GREEN AR. Hydroxyurea compared with anagrelide in high-risk essential thrombocythemia. *N Engl J Med* 2005; 353: 33-45.
- 14) LANZKRON S, STROUSE JJ, WILSON R, BEACH MC, HAYWOOD C, PARK H, WITKOP C, BASS EB, SEGAL JB. Systematic review: Hydroxyurea for the treatment of adults with sickle cell disease. *Ann Intern Med* 2008; 148: 939-955.
- 15) FRANK I, BOSCH RJ, FISCUS S, VALENTINE F, FLEXNER C, SEGAL Y, RUAN P, GULICK R, WOOD K, ESTEP S, FOX L, NEVIN T, STEVENS M, ERON JJ JR. Activity, safety, and immunological effects of hydroxyurea added to didanosine in antiretroviral-naive and experienced HIV type 1-infected subjects: a randomized, placebo-controlled trial, ACTG 307. *AIDS Res Hum Retroviruses* 2004; 20: 916-926.
- 16) SHARMA VK, DUTTA B, RAMAM M. Hydroxyurea as an alternative therapy for psoriasis. *Indian J Dermatol Venereol Leprol* 2004; 70: 13-17.
- 17) HARRISON 17<sup>TH</sup> ED. Interstitial lung disease. Pp. 1595-1596. Mc Graw-Hill, 2009.
- 18) REMY-JARDIN M, GIRAUD F, REMY J, COPIN MC, GOSSELIN B, DUHAMEL A. Importance of ground-glass attenuation in chronic diffuse infiltrative lung disease: pathologic-CT correlation. *Radiology* 1993; 189: 693-698.