

# Botulinum toxin treatment in glaucomatous patients: a pilot study

A. LIBRANDO, V. RUSSO, M. TARALLO<sup>1</sup>, F. CRUCIANI,  
S.C. CARLESIMO, M. NEBBIOSO

Department of Sense Organs, and <sup>1</sup>Department of Plastic Surgery, "Sapienza" University of Rome, Faculty of Medicine and Odontology, Rome, Italy

**Abstract. – PURPOSE:** The purpose was to evaluate the efficacy of the treatment of iatrogenic entropion (IE), in patients affected by primary open angle glaucoma (POAG), by botulinum toxin injections (BTI).

**PATIENTS AND METHODS:** 20 patients of the "Glaucoma Center" of the Hospital "Umberto I" (Rome) were examined. These patients had POAG and used prostaglandin analogues (PA). Mean age was 75.5 years old (range 68-83); they had been suffering from PAOG since 10 years and were not affected by other relevant systemic diseases. One to three BTI were made into the lower orbicularis muscle using a 0.3 G needle (0.025 to 0.05 units for each injection site).

**RESULTS:** The results were particularly significant in 18 out of 20 patients. Two patients showed slight improvements. A rating scale ranging from 0 to 6 points (0 corresponded to 'no effect' and 6 to the 'complete' resolution of the entropion) was used to evaluate the goals of the treatment. The average rating was 5.37 points.

**CONCLUSIONS:** The entropion due to glaucoma therapy with PA can be successfully treated with BTI in the orbicularis muscle, despite offering temporary therapeutic effects.

*Key Words:*

Botulinum toxin, Entropion, Glaucoma, Prostaglandin analogues.

## Introduction

Entropion is the turning inward of the eyelid margin, which is more frequent in the lower eyelid than in the upper eyelid. This causes a constant rubbing of the eyelashes on the cornea, which can lead to irritation, punctate keratitis of the corneal epithelium, and in chronic cases it can lead to the ulceration of the cornea and the formation of corneal pannus. There are several types of entropion with different etiopathogeneses; the three main types are congenital, involutional, and cicatricial<sup>1</sup>. Involutional entropion is caused by age-related deterioration of the elastic fibrous tissue in-

side the eyelid. Temporary treatment involves the use of eye drops, application of a patch or therapeutic soft contact lens or chemical denervation of the orbicularis muscle by botulinum toxin injections (BTI). Instead the eyelid surgery can permanently fix the inward eyelid margin.

Patients affected by glaucoma treated with prostaglandin analogues (PA) may produce iatrogenic entropion (IE)<sup>1-4</sup>. As well known, one of the adverse side-effects of the substance, is the increase of conjunctival hyperemia and the growth and thickening of the eyelashes. Increased eyelash growth can develop into trichiasis, which increases the risk of entropion in patients taking this type of drug for a long time. Such long-term conditions lead to chronic hyperaemia, which can evolve into keratitis and corneal leukoma. In fact, a study carried out by Bearden et al (2004) also highlighted the correlation between the use of PA in patients affected by primary open angle glaucoma (POAG) and the development of trichiasis<sup>2</sup>.

Botulinum toxin (BT) is produced by bacteria. This toxin works by blocking nerve communication at the synapse, which degrades a protein called SNAP-25, involved in the release of neurotransmitters to nerve endings. The natural target for the toxin is neuromuscular synapsis and at this level, the toxin blocks acetylcholine release and this causes the paralysis of the muscle<sup>5</sup>.

*Clostridium botulinum* secretes one of the most toxic bacterial proteins, targeting the fusion proteins of synaptic vesicles, which causes cleavage through zinc metalloprotease activity<sup>6</sup>.

BT used for therapy began in the 1990s. It was particularly successful in the treatment of strabismus, blepharospasm, hemifacial spasm, entropion, and other diseases characterized by abnormal muscle contractions. In addition, it is particularly effective in the treatment of some types of pain and against different types of gastrointestinal infection.

Several drugs and diseases interfere with the neuromuscular junction and the effect of BT. To minimize the risk of resistance induced by antibodies that may develop as a reaction to the toxin, it is necessary to adopt certain measures. The dose used should be the least effective amount and the injections must be performed at intervals of more than 3 months. Side effects are rare, but they may include: ptosis, ectropion, diplopia, bruising, and headaches<sup>5-8</sup>.

Our purpose was to evaluate the efficacy of the treatment of entropion, iatrogenic related, through BTI to obtain temporary chemical denervation of the orbicularis muscle in POAG patients treated with PA.

### Patients and Methods

20 patients of the “Glaucoma Center” of “Umberto I” Hospital (Rome) were examined. Mean age was 75.5 years old (range 68-83); they had been suffering from POAG under therapeutic control with PA (one drop once a day in the evening) from at least 2 years. The study was conducted in full accordance with the Declaration of Helsinki. All subjects were informed and consented to the use of their data in this study. The protocol was approved by the Ethical Committee, Sapienza University, Rome, Italy.

The patients enrolled in the research were not affected by other relevant systemic diseases. Eyelids were disinfected; then from one to three injections of BT were made with a 0.3 G needle, into the lower orbicularis muscle, immediately below the eyelid margin, in the medial- lateral- and middle-third regions. One hundred units of type A “Botox” (Allergan Pharmaceuticals Ireland, Castlebar Road, Westport, County Mayo, Ireland) were injected. We diluted the soluble powder with a sterile sodium chloride solution 9 mg/ml (0.9%). An extra 2.5 ml of sodium chloride was then added, thus obtaining 6.25 total units of the medicine, to be used on our 20 sample patients. The dose of the drug varied from 0.025 to 0.05 units for each injection site, therefore it was much lower than the dose recommended in the medical leaflet for treating blepharospasm, which in fact prescribes 1.25-2.5 units for each injection site.

To evaluate the difference between the stage of the disease before and after the treatment a rating scale ranging from 0 to 6 points was used; 0 corresponded to ‘no effect’ and 6 to the ‘complete’ res-

olution of the entropion. The score was measured before (t0) and 24 hours after the injection (t1).

### Statistical Analysis

The software used was R-project. With Kolmogorov-Smirnov test we assumed that the distribution is reasonably close to a normal one. So we used the Student’s *t* test to estimate the range of variability of the population average.  $p < 0.05$  was considered statistically significant.

### Results

The patients were re-examined 24 hours, 15 days and 2 months after the treatment. There was a further check-up depending on the clinical conditions of each patient. The results were particularly significant in 18 out of 20 patients. Two patients showed slight improvements. The mean score before the treatment (t0) was 3.4 ( $\pm 0.8$ ) points. The range of variability of the population average after BTI (t1) was from 4.8 to 5 points. The confidence level was 95% (Figure 1). In the patients treated with BT the test values were statistically significant when compared with the test values before of the treatment ( $p < 0.05$ ). These values suggested the importance of BT in examined patients (Figure 2A/B).

The maximum effects were observable after 15 days. The average duration of the effect was about three months. The patients were monitored by photographs and slit-lamp biomicroscopy to

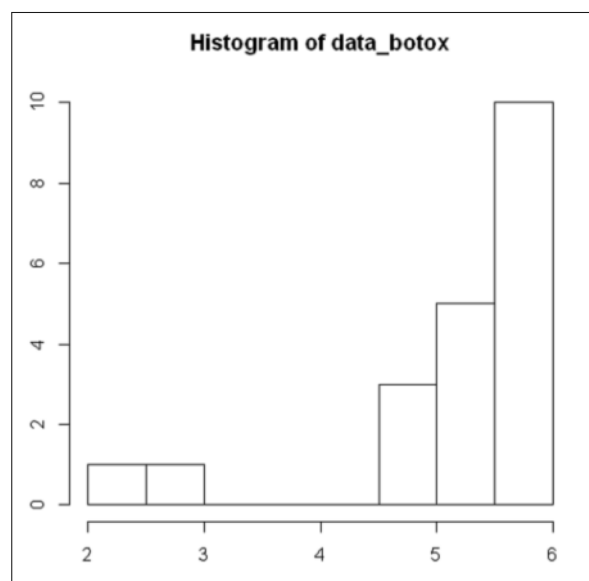
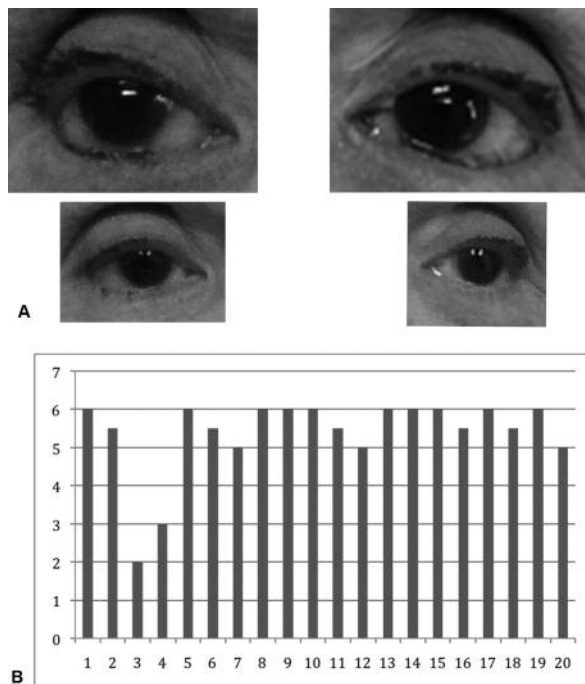


Figure 1. Histogram of data in relationship with frequency.



**Figure 2.** Photographs before and after treatment with botulinum (A). Rating scale from 0 to 6 where 0 corresponded to “no effect” and 6 to the ‘complete’ resolution of entropion (B).

assess the evolution of their clinical condition (Figure 2A/B). The dose of drug used was effective and reduced the risk of ectropion and other side effects.

## Discussion

We have focused on the effectiveness of entropion treatment by BTI into the orbicularis muscle, in patients affected by POAG undergoing PA therapy.

In 1988 Clarke et al<sup>9</sup> carried out a study using BT to treat senile entropion in 12 patients. The patients underwent BTI in the preseptal part of the orbicularis muscle. There were notable effects of a temporary improvement of the symptoms in 10 patients. On average the effects lasted 14.8 weeks, while in our experiment we report a lasting effect of 12 weeks. Clarke et al. conclude that in the sample selection of patients, BT not only offers a good resolution to the clinical problem, it also offers a treatment which can be performed easily. However it is necessary to point out that surgery provides the longest-lasting results.

Deka et al<sup>10</sup>, in a prospective study, evaluated the efficiency of BT as temporary treatment for senile entropion and congenital lower lid entropi-

on. Twenty patients were examined: 17 had senile entropion and 3 children had congenital entropion. The patients were treated with BTI in the preseptal portion of the lower eyelid orbicularis muscle, resulting in a visible improvement of their condition within 8-26 weeks. The authors claimed the procedure was simple to perform, which we confirm from our own experience. The treatment proved effective for both types of entropion.

More recently<sup>11</sup> Winterhoff et al. reported a case study of treatment on a 74 year old man suffering from dementia who had spastic entropion. The patient was successfully treated with BTI to the lower eyelid, in this way avoiding surgery. Similarly to our own experience, the authors acknowledge the importance of symptomatic treatment, comprising BT, as an alternative therapy to surgery in patients at risk.

Two medical research groups assessed the effect of BT in two famous products: Botox<sup>®</sup> and Dysport<sup>®</sup>. Badamy et al<sup>12</sup> observed the effectiveness of Dysport<sup>®</sup> in patients treated with Botox<sup>®</sup> for blepharospasm and hemifacial spasm, but which had no effect. They claimed the ineffectiveness was due to the formation of specific antibodies against BT, which occurs more frequently in long-term therapies. Botox<sup>®</sup> and Dysport<sup>®</sup> are both serotype A BTs, but they seem to have different biological activity.

Whereas, Bentivoglio et al<sup>13</sup> compared the clinical conditions and long-term results of 128 patients with blepharospasm treated with the most widely used brands of BT, namely Botox<sup>®</sup> and Dysport<sup>®</sup> in the last 15 years. They treated 1341 patients, 1009 of whom were injected with Botox<sup>®</sup> and 332 with Dysport<sup>®</sup>. The Botox<sup>®</sup> dosage was 0.40 units, whereas the Dysport<sup>®</sup> one was 0.16. These quantities were increased over time. Both drugs proved effective and safe in the treatment of blepharospasm.

However, on the contrary, in our study we were able to obtain satisfactory results with very small quantities of Botox<sup>®</sup> (a maximum of 0.15 units per patient).

In contrast Arat et al<sup>14</sup>, in their study claimed that the reduction of tear production caused by BTI, with the aesthetic aim of removing periocular wrinkles, is a possible complication. The BT dosage used was two injections of 10 units for each side.

For this reason, it is important that patients should be informed about the possible consequences of this type of treatment, even though they are rare and often temporary.

The disadvantage of the treatment using BT is its temporary nature, lacking any definite resolution, implying life-long therapy for the patients. Such conditions are undesirable, both for the patient and for the very high costs incurred by the public health system. BT is considered safe and effective. However, it is crucial to understand its mechanism of action and the way it interacts with other substances in order to standardize the application techniques, optimize the effects and maximize its therapeutic potential.

### Conclusions

The entropion due to glaucoma therapy with PA seems to be successfully treated by BTI in the orbicularis muscle with the minimum effective dosage. However, it seems to offer temporary therapeutic effects.

---

#### Declaration of Interest

The authors report no conflicts of interest. The authors alone are responsible for the content and writing of the paper.

---

#### Conflict of Interest

None to declare.

### References

- 1) KANSKY JJ. Orbita. In: Kansky JJ. *Oftalmologia Clinica* 2004; pp. 145-147.
- 2) BEARDEN W, ANDERSON R. Trichiasis associated with prostaglandin analog use. *Ophtal Plast Reconstr Surg* 2004; 20: 320-322.
- 3) NEBBIOSO M, EVANGELISTA M, LIBRANDO A, DI BLASIO D, PESCOLIDIO N. Fixed topical combinations in glaucomatous patients and ocular discomfort. *Expert Opin Pharmacother* 2012; 13: 1829-1835.
- 4) NEBBIOSO M, GREGORIO FD, PRENCIPE L, PECORELLA I. Psychophysical and electrophysiological testing in ocular hypertension. *Optom Vis Sci* 2011; 88: E928-939.
- 5) CALEO M, SCHIAVO G. Central effects of tetanus and botulinum neurotoxins. *Toxicon*. 2009; 54: 593-599.
- 6) LEBRUN I, MARQUES- PORTO R, PEREIRA AS, PEREIRA A, PERPETUO EA. Bacterial toxins: an overview on bacterial proteases and their action as virulence factors. *Mini Rev Med Chem* 2009; 9: 820-828.
- 7) CARRUTHERS J, CARRUTHERS. Botox: beyond wrinkles. *Clin Dermatol* 2004; 22: 89-93.
- 8) HUANG W, FOSTER JA, ROGACHEFSKY AS. Pharmacology of botulinum toxin. *J Am Acad Dermatol* 2000; 43: 249-259.
- 9) CLARKE KR, SPALTON DJ. Treatment of senile entropion with botulinum toxin. *Br J Ophthalmol* 1988; 72: 361-362.
- 10) DEKA A, SAIKIA SP. Botulinum toxin for lower lid entropion correction. *Orbit* 2011; 30: 40-42
- 11) WINTERHOFF J, KOLER S, LASKAWI R. Botulinum toxin for the treatment of spastic entropion: Case report. *HNO* 2012 Dec 19. [Epub ahead of print]
- 12) BADARNY S, SUSEL Z, HONIGMAN S. Effectivity of Dysport in patients with blepharospasm and hemifacial spasm who experienced failure with Botox. *Isr Med Assoc J*; 2008; 10: 520-522.
- 13) BENTIVOGLIO AR, FASANO A, IALONGO T, SOLETI F, LO FERMO S, ALBANESE A. Fifteen-year experience in treating blepharospasm with Botox or Dysport: same toxin, two drugs. *Neurotox Res* 2009; 15: 224- 231.
- 14) ARAT YO, YEN MT. Effect of botulinum toxin type a on tear production after treatment of lateral canthal rhytids. *Ophtal Plast Reconstr Surg* 2007; 23: 22-24.