

Osteoblastoma of cervical spine causing an unusual neck pain

M. UCCELLO, M. VACANTE, M. GIORDANO, M. MALAGUARNERA,
A. BIONDI*, F. BASILE*, G. MALAGUARNERA, M. PENNISI, M. MOTTA

Research Center The Great Senescence, School of Medicine, University of Catania, Catania, Italy

*Department of Surgery, School of Medicine, University of Catania, Catania, Italy

Abstract. – Osteoblastoma is a rare benign tumor of bone that accounts for approximately 1% of primary skeletal neoplasms, with around 90% of cases diagnosed in the second and third decades of life. Cervical spine is an usual localization of osteoblastoma. The main clinical manifestation in case of cervical spine location is a progressive and resistant pain, possibly accompanied by stiffness, scoliosis or other ailments, including severe neurological deficits. Owing to a non-specific clinical presentation of osteoblastoma, the delay in diagnosis is common. Osteoblastomas may have an aggressive behavior, tend to enlarge and damage the bone and adjacent structures. The treatment of choice is, therefore, a wide and complete surgical excision of the lesion in order to achieve full recovery and prevent recurrence or, in some cases, malignant transformation. In the case of persistent neck pain, not readily relieved by aspirin and possibly accompanied by stiffness, scoliosis or neurological deficits, especially in young subjects, osteoblastoma of cervical spine may be one of the diagnostic options to be considered, in order to avoid delay in diagnosis. We report the case of a 41-year-old male affected by cervical spine osteoblastoma causing a lasting neck pain.

Key Words:

Osteoblastoma, Bone neoplasms, Neck pain.

Introduction

Osteoblastoma, a rare benign tumor of bone composed of a hypervascular connective tissue stroma where there is active production of osteoid and primitive woven bone, was first and independently described in 1956 by Jaffe¹ and Lichtenstein². It accounts for approximately 1% of primary skeletal neoplasms, with around 90% of cases diagnosed in the second and third decades of life, although the range of age of the tumor manifestation is wide (6-75 years). There is a male predominance 2:1^{3,4}. Osteoblastoma is typically located in the *vertebrae* or in the long

bones of the limbs, though it may settle in any skeletal segment⁵⁻⁷. Spinal osteoblastoma most often originates in the posterior vertebral elements, although its extension into the vertebral body is also common^{4,8}. Osteoblastoma have not a specific clinical presentation. Sometimes osteoblastomas may be asymptomatic and are incidentally diagnosed⁹. The presentation of such tumors varies with the location and size and the main symptom is a progressive pain. Patients with vertebral column osteoblastoma may complain of stiffness, scoliosis, swelling, radiating pain, gait problems, tingling weakness and other neurologic symptoms, including paresthesias, paraparesis and even paraplegia^{5,10-12}. In radiological exams, osteoblastoma appears as a round or ovoid, often massive osteolytic area, with sharp demarcation. The osteolytic area may show ossified and calcified parts under itself, and may be surrounded by a reactive osteosclerosis¹³⁻¹⁵. Macroscopically, it appears as a reddish-brown, very bloody granular tissue for the presence of osteoid^{10,16,17}. Osteoblastoma is a benign entity but it sometimes displays an aggressive behaviour. However, the different location, the slow growth of osteoblastoma and the radiographic and histological features usually address the diagnosis in a correct way^{4,9,13,16}. The treatment of choice of this condition is surgical, involving a complete excision of the lesion^{18,19}. Of all vertebral osteoblastomas, 9-39% occur in the cervical spine^{20,21}. We report the case of a 41-year-old male with an osteoblastoma of cervical spine, causing a long-standing, unusual neck pain.

Case Report

Mr. D., a 41-year-old male, had complained of occasional neck pain episodes for many years. However, since October 2007 he had manifested a different kind of neck pain which was persistent, not readily relieved with aspirin or nonsteroidal anti-inflammatory medication, and

which radiated to the right shoulder and arm and was associated with torticollis and numbness of the upper limbs. He denied any trauma or recent strenuous activity. The symptoms manifested a progressive course overtime, with no worsening at night. His motor exam was moderately limited owing to the pain. Pulses, reflexes and laboratory findings were within the normal range. The patient was, therefore, subjected to various investigations, including CT scan (Figure 1) and MRI of cervical spine, which showed a large area of osteolysis goitered edges involving C4 metamer on its right portion and characterized by the presence of tissue that made the bone swell. The somatic cortex on its front and back side was broken, and the expansion also affected the ipsilateral conjugation foramen with radicular compression. It was later carried out an angiographic study of the vertebral, deep and ascending cervical arteries, bilaterally, that revealed the presence of pathological circle by the lesion. In August 2008, an experienced team proceeded with an intervention of incomplete excision of the osteolytic lesion with partial C4 corpectomy and stabilization with plaque, through microsurgical technique. In histological examination fragments of cartilage and connective tissue were found, mixed to minute fragments of benign bone formation and morphologically compatible with osteoblastoma. There was no evidence of nuclear atypia, hyperchromasia, high mitotic rate or infiltration into adjacent tissues while margins of the

host bone-tumor interface were sharp and well circumscribed. Thus, it was removed the suspicion of osteosarcoma. In December 2008, cervical spine MRI showed results of osteolytic lesion resection at the level of C4 vertebral body. Cervical spine CT scan revealed a lytic area in the right pedicle of C4, as the position of the plaque was right and unmodified. It was then carried out a surgical resection of C4 osteoblastoma using a posterior approach and consisting of hemilaminectomy. The histological examination showed bone fragments without significant structural changes and isolated tiny fragments consisting of connective and bone tissue, with marked artefactual crush changes (residual neoplastic focus?). The postoperative course was regular. There were found no other suspicious lesions neither in the CT scan performed three months later (Figure 2) nor in subsequent investigations. Nevertheless, two years after the second surgery, the patient was still complaining of serious functional limitation of the cervical spine, upper limbs numbness and other changes of prehensile function. The quality of life was also made poor by the onset of adaptation disorders, with anxiety and chronic depression. CT scan revealed that no signs of progressive disease were evident in a 24-month interval from the second surgery. The failure to achieve a definitive cure would be attributable to the aggressive behavior of the lesion and the diagnostic delay.

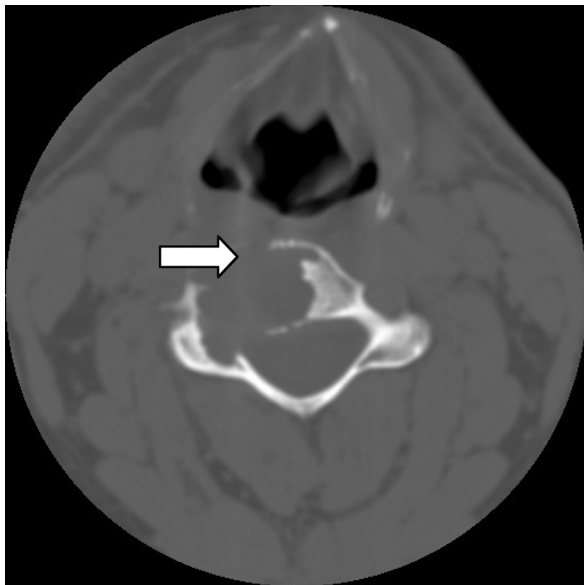


Figure 1. CT image with bone window that shows an osteolytic lesion involving C4 right portion.

Discussion

Osteoblastomas are benign and aggressive tumors. Their natural course, when not surgically excised, is to continue to enlarge and damage the bone and adjacent structures²². The most common affected site is the spine^{12,18}. The main symptoms in patients with spinal osteoblastoma are stiffness and a resistant pain localized in the spine²¹. Unlike other bony lesions, such as osteoid osteoma, the pain produced by osteoblastomas does not intensify at night, neither is it relieved by aspirin or nonsteroidal anti-inflammatory medication²³⁻²⁵. Several cases of osteoblastoma involving the cervical spine segment are already known in literature^{20,21,26}. When osteoblastoma affects cervical spine, the major symptom is obviously neck pain; painful scoliosis, torticollis, neurological deficits, radicular pain in the arm, or pain extending toward the shoulder can be also associated to such tumors^{5,12,21,27,28}. X-rays

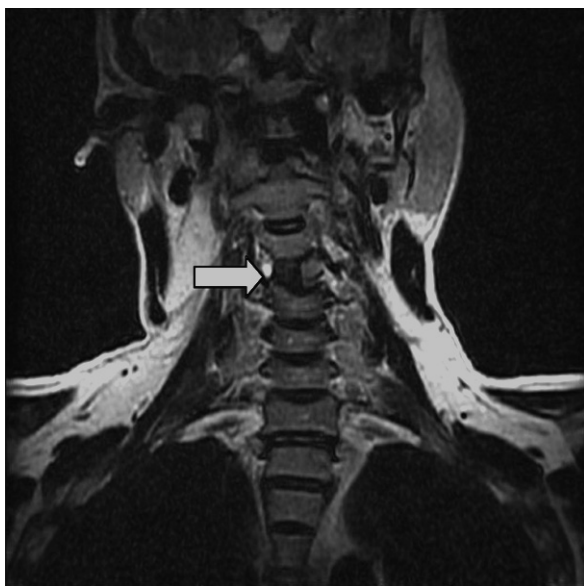

Figure 2. MR image, Fast Relaxation Fast Spin Echo sequence (FRFSE) T2-weighted (coronal). Results of C4 right hemilaminectomy.

probably are by themselves quite sensitive in the detection of osteoblastomas, but more thorough investigations such as CT scan and MRI are able to detect smaller lesions but with early symptoms, and also add important information for diagnosis and treatment^{8,11,27,29,30}. CT scans can provide useful information regarding the size, precise localization, and any soft tissue extension of the lesion³¹. MRI is helpful for depicting the effects of the tumor on the spinal canal and surrounding soft tissues^{30,31}. When doubts about the diagnosis persist, bone scintigraphy with technetium may be used, which is characterized by a greater sensitivity than the other techniques²⁷. The differential diagnoses of osteoblastoma are multiple and include different types of benign bone tumors and tumor-like lesions³². Anyway, the most important differential diagnosis is osteosarcoma, which demonstrates greater cytologic atypia, permeative growth pattern or metastasis or infiltration into adjacent bone and/or soft tissue, and high mitotic rate³. Sometimes it can be very difficult the distinction between osteoblastoma and osteoid osteoma. Nevertheless, osteoblastoma is larger (usually more than 1.5 cm), tends to be more aggressive and can undergo malignant transformation, whereas osteoid osteoma is smaller, benign and self-limited¹⁴. Osteoblastoma tends to aggressive behavior, it sometimes attacks the nearby structures and rarely degenerates into osteosarcoma³³⁻³⁵. More-

over, the atypical histological features that sometimes osteoblastoma may show, do not correlate with the clinical aggressiveness of the lesion^{3,4}. The treatment of choice is, therefore, a wide and complete surgical excision of the lesion in order to achieve full recovery and prevent recurrence or, in some cases, malignant transformation^{18,36,37}. In the case of large tumor masses it is difficult to act with a complete resection, so that a stabilization with intervertebral fusion should be performed^{38,39}. When complete surgical excision is not possible, radiotherapy and, in some cases, chemotherapy may be used as alternative treatment options^{28,40,41}.

In conclusion, in the case of neck pain, which is persistent and possibly accompanied by stiffness, scoliosis or neurological deficits, especially in young subjects, osteoblastoma of cervical spine may be one of the diagnostic options to be considered, in order to avoid delay in the diagnosis.

References

- 1) JAFFE HL. Benign osteoblastoma. *Bull Hosp Joint Dis* 1956; 17: 141-151.
- 2) LICHTENSTEIN L. Benign osteoblastoma; a category of osteoid-and bone-forming tumors other than classical osteoid osteoma, which may be mistaken for giant-cell tumor or osteogenic sarcoma. *Cancer* 1956; 9: 1044-1052.
- 3) DELLA ROCCA C, HUVOS AG. Osteoblastoma: varied histological presentations with a benign clinical course. An analysis of 55 cases. *Am J Surg Pathol* 1996; 20: 841-850.
- 4) LUCAS DR, UNNI KK, MCLEOD RA, O'CONNOR MI, SIM FH. Osteoblastoma: clinicopathologic study of 306 cases. *Hum Pathol* 1994; 25: 117-134.
- 5) MARSH BW, BONFIGLIO M, BRADY LP, ENNEKING WF. Benign osteoblastoma: range of manifestations. *J Bone Joint Surg* 1975; 57: 1-9.
- 6) GOLANT A, LOU JE, EROL B, GAYNOR JW, LOW DW, DORMANS JP. Pediatric osteoblastoma of the sternum: a new surgical technique for reconstruction after removal: case report and review of the literature. *J Pediatr Orthop* 2004; 24: 319-322.
- 7) VILLALOBOS CE, RYBAK LD, STEINER GC, WITTIG JC. Osteoblastoma of the sternum—case report and review of the literature. *Bull NYU Hosp Jt Dis* 2010; 68: 55-59.
- 8) KROON HM, SCHUMARS J. Osteoblastoma: clinical and radiological findings in 98 new cases. *Radiology* 1990; 175: 783-790.
- 9) MOON KS, JUNG S, LEE JH, JUNG TY, KIM IY, KIM SH, KANG SS. Benign osteoblastoma of the occipital bone: case report and literature review. *Neuropathology* 2006; 26: 141-146.

- 10) FRASSICA FJ, WALTRIP RL, SPONSELLER PD, MA LD, MCCARTHY EF JR. Clinicopathologic features and treatment of osteoid osteoma and osteoblastoma in children and adolescents. *Orthop Clin North Am* 1996; 27: 559-574.
- 11) BORIANI S, CAPANNA R, DONATI D, LEVINE A, PICCI P, SAVINI R. Osteoblastoma of the spine. *Clin Orthop Relat Res* 1992; 278: 37-45.
- 12) RASKAS DS, GRAZIANO GP, HERZENBERG JE, HEIDELBERGER KP, HENSINGER RN. Osteoid osteoma and osteoblastoma of the spine. *J Spinal Disord* 1992; 5: 204-211.
- 13) DORFMAN HD, WEISS SW. Borderline osteoblastic tumors: problems in the differential diagnosis of aggressive osteoblastoma and low-grade osteosarcoma. *Semin Diagn Pathol* 1984; 1: 215-234.
- 14) LUCAS DR. Osteoblastoma. *Arch Pathol Lab Med* 2010; 134: 1460-1466.
- 15) EISENBERG RL. Bubbly lesions of bone. *AJR Am J Roentgenol* 2009; 193: W79-94.
- 16) BERTONI F, UNNI KK, MCLEOD RA, DAHLIN DC. Osteosarcoma resembling osteoblastoma. *Cancer* 1985; 55: 416-426.
- 17) LICHTENSTEIN L, SAWYER WR. Benign osteoblastoma: further observations and report of twenty additional cases. *J Bone Joint Surg Am* 1964; 46: 755-765.
- 18) ZILELI M, CAGLI S, BASDEMIR G, ERSAHIN Y. Osteoid osteomas and osteoblastomas of the spine. *Neurosurg Focus* 2003; 15: E5.
- 19) MYLES ST, MACRAE ME. Benign osteoblastoma of the spine in childhood. *J Neurosurg* 1988; 68: 884-888.
- 20) FIELDING JW, KEIM HA, HAWKINS RJ, GABRIELIAN JC. Osteoid osteoma of the cervical spine. *Clin Orthop Relat Res* 1977; 128: 163-164.
- 21) KANER T, SASANI M, OKTENOGU T, AYDIN S, OZER AF. Osteoid osteoma and osteoblastoma of the cervical spine: the cause of unusual persistent neck pain. *Pain Physician* 2010; 13: 549-554.
- 22) SCHAJOWICZ F, LEMOS C. Malignant osteoblastoma. *J Bone Joint Surg Br* 1976; 58: 202-211.
- 23) BERRY M, MANKIN H, GEBHARDT M, ROSENBERG A, HORNICEK F. Osteoblastoma: a 30-year study of 99 cases. *J Surg Oncol* 2008; 98: 179-183.
- 24) KAN P, SCHMIDT MH. Osteoid osteoma and osteoblastoma of the spine. *Neurosurg Clin N Am* 2008; 19: 65-70.
- 25) SMITH JR, SAMDANI AF. An unusual cause of low back pain in an adolescent. *JAAPA* 2008; 21: 56-57.
- 26) NEMOTO O, MOSER RP JR, VAN DAM BE, AOKI J, Gilkey FW. Osteoblastoma of the spine. A review of 75 cases. *Spine* 1990; 15: 1272-1280.
- 27) PETTINE KA, KLASSEN RA. Osteoid-osteoma and osteoblastoma of the spine. *J Bone Joint Surg Am* 1986; 68: 354-361.
- 28) SHIKATA J, YAMAMURO T, IIDA H, KOTOURA Y. Benign osteoblastoma of the cervical vertebra. *Surg Neurol* 1987; 27: 381-385.
- 29) MCLEOD RA, DAHLIN DC, BEABOUT JW. The spectrum of osteoblastoma. *AJR Am J Roentgenol* 1976; 126: 321-325.
- 30) CERVONI L, INNOCENZI G, RAGUSO M, SALVATI M, CARUSO R. Osteoblastoma of the calvaria: report of two cases diagnosed with MRI and clinical review. *Neurosurg Rev* 1997; 20: 51-54.
- 31) OZKAL E, ERONGUN U, CAKIR B, ACAR O, UYGUN A, BITIK M. CT and MR imaging of vertebral osteoblastoma. A report of two cases. *Clin Imaging* 1996; 20: 37-41.
- 32) NIELSEN GP, ROSENBERG AE. Update on bone forming tumors of the head and neck. *Head Neck Pathol* 2007; 1: 87-93.
- 33) MAYER L. Malignant degeneration of so-called benign osteoblastoma. *Bull Hosp Joint Dis* 1967; 28: 4-13.
- 34) KUNZE E, ENDERLE A, RADIG K, SCHNEIDER-STOCK R. Aggressive osteoblastoma with focal malignant transformation and development of pulmonary metastases. A case report with a review of literature. *Gen Diagn Pathol* 1996; 141: 377-392.
- 35) SEKI T, FUKUDA H, ISHII Y, HANAOKA H, YATABE S. Malignant transformation of benign osteoblastoma. A case report. *J Bone Joint Surg Am* 1975; 57: 424-426.
- 36) SAMDANI A, TORRE-HEALY A, CHOU D, CAHILL AM, STORM PB. Treatment of osteoblastoma at C7: a multidisciplinary approach. A case report and review of the literature. *Eur Spine J* 2009; 18(Suppl 2): 196-200.
- 37) OZAKI T, LIJENOVIST U, HILLMANN A, HALM H, LINDNER N, GOSHEGER G, WINKELMANN W. Osteoid osteoma and osteoblastoma of the spine: experiences with 22 patients. *Clin Orthop Relat Res* 2002; 397: 394-402.
- 38) SCHNEIDER M, SABO D, GERNER HJ, BERND L. Destructive osteoblastoma of the cervical spine with complete neurologic recovery. *Spinal Cord* 2002; 40: 248-252.
- 39) COMBALIA ALEU A, POPESCU D, POMES J, PALACIN A. Long-standing pain in a 25-year-old patient with a non-diagnosed cervical osteoblastoma: a case report. *Arch Orthop Trauma Surg* 2008; 128: 567-571.
- 40) CAMITTA B, WELLS R, SEGURA A, UNNI KK, MURRAY K, DUNN D. Osteoblastoma response to chemotherapy. *Cancer* 1991; 68: 999-1003.
- 41) BERBEROGLU S, OGUZ A, ARIBAL E, ATAOGU O. Osteoblastoma response to radiotherapy and chemotherapy. *Med Pediatr Oncol* 1997; 28: 305-309.