

Assessment of serum endothelin-1 levels in rat appendicitis model and the effects of bosentan

S.B. SARSU¹, K. SAHIN², H. KILINCASLAN³, S.L. MIRAPOGLU⁴,
N. BUYUKPINARBASILI⁵, M.E. DUZ⁶, I. AYDOGDU⁴

¹Department of Pediatric Surgery, Cengiz Gokcek Obstetrics and Children Hospital, Gaziantep, Turkey

²Department of Pediatrics, Haseki Training and Research Hospital, Istanbul, Turkey

³Department of Pediatric Surgery, Avrasya Hospital, Istanbul, Turkey

⁴Department of Pediatric Surgery, Bezmialem Vakif University, Faculty of Medicine, Istanbul, Turkey

⁵Department of Pathology, Bezmialem Vakif University, Faculty of Medicine, Istanbul, Turkey

⁶Department of Medical Biochemistry, Haseki Training and Research Hospital, Istanbul, Turkey

Abstract. – OBJECTIVE: In this study, the diagnostic value of serum endothelin-1 (ET-1) levels and the therapeutic effects of bosentan have been investigated in an experimental appendicitis rat model.

MATERIALS AND METHODS: Twenty-one male Sprague-Dawley rats were chosen for the study. The rats were allocated into three groups as follows: Group 1 (control, n = 7), Group 2 (appendicitis, n = 7), and Group 3 (bosentan treatment, n = 7). At the 6th hour of the experiment, Groups 1 and 2 received 2 ml saline, and group 3 received 30 mg/kg bosentan intraperitoneally. At the 24th postoperative hour, all rats were sacrificed and evaluated histopathologically to score the severity of appendicitis. The plasma malondialdehyde, reduced and total glutathione levels, serum, and appendiceal tissue ET-1 levels were evaluated.

RESULTS: In this study, we found that the ET-1 levels were significantly increased with appendicitis ($p = 0.018$). The administration of bosentan can statistically significantly both decrease the histopathologic injury in the inflamed appendix and increase the serum total glutathione levels ($p = 0.002$).

CONCLUSIONS: The increase in plasma ET-1 levels may have a diagnostic value of acute appendicitis. We believe that manifestations that occur during the acute phase of appendicitis may be reduced with the administration of bosentan, which may also help prevent complications.

Key Words:

Endothelin 1, Bosentan, Appendicitis, Rat.

Introduction

Acute appendicitis (AA) remains the most frequent cause of acute abdominal pain in children¹. The condition is encountered in nearly 7% of the overall population², and appendectomy remains

the most common surgical emergency^{3,4}. The pathophysiology of this disease is not fully understood. Following luminal occlusion, inflammatory changes in the appendiceal tissue induce rapid distention of the vermiform appendix, which consequently increases the intraluminal pressure³. An increase in venous pressure leads to the development of mucosal ischemia, causes the inflammatory process to progress and increases the intraluminal pressure, resulting in necrosis of the appendiceal wall.

Endothelin-1 (ET-1) is a potent vasoconstrictive peptide consisting of 21 amino acids in many tissues, including those of the gastrointestinal system, and it is released from inflammatory cells⁵. The effects of ET-1 on inflammatory bowel diseases have been studied in detail⁶. ET-1 increases the superoxide anion products and cytokine release, which contribute to the development of the inflammatory process^{7,8}. It is one of the important mediators of the systemic inflammatory response and is involved in immune functions^{9,10}. Because of its vasoconstrictive effect, ET-1 is believed to play a role in the pathophysiology of AA¹¹. The inhibition of this agent can decrease morbidity by suppressing the development of intestinal injury. Bosentan is the first potent non-peptide endothelin (ET) receptor antagonist approved by the Food and Drug Administration¹². An increase in the endothelial tissue has been demonstrated in colitis-induced rats, and diminished ET-1 activity has been correlated with an improvement in colitis^{13,14}. The effects of bosentan in AA have not been investigated. In our study, the diagnostic value of ET-1 and the effectiveness of bosentan are investigated for the first time investigated in an experimental appendicitis rat model.

Materials and Methods

Materials

Experiments were conducted in accordance with the Guide for the Care and Use of Laboratory Animals. The experimental protocol was approved by the local Ethics Committee of the Animal Production and Research Laboratory of Bezmialem Vakif University. The study subjects included 21 male Sprague-Dawley rats weighing between 198 and 265 g. Rats were fed standard pellets and tap water and kept at room temperature and a humidity-controlled environment. The rats were randomly allocated to one of the three groups containing 7 rats each.

Surgical Procedure

Intraperitoneal ketamine hydrochloride (50 mg/kg) (Ketalar, 50 mg/ml, Eczacibasi, Istanbul, Turkey) and xylazine hydrochloride (15 mg/kg) (Rompun, 23.32 mg/ml, Bayer, Istanbul, Turkey) were used for the induction of anesthesia. Approximately 5 min before the operation, the abdominal regions of the rats were shaved, cleaned with 10% povidone-iodine solution and covered with sterile drapes. Using sterile instruments, a laparotomy was performed through a midline incision. The cecum, which typically measures approximately 1 cm in diameter and 2 cm in length, was identified. To create and mimic acute appendicitis in the rat model, a point nearly 5 cm proximal to the tip of the cecum was ligated with 3-0 silk sutures¹⁵.

Group 1 (Control): only laparotomy was performed, and the wound was closed primarily. At 6 h after surgery, 2 µl of saline were administered into the peritoneal cavity. The abdominal layers were then closed with 4/0 silk sutures.

Group 2 (Appendicitis): following a similar approach for laparotomy, the distal part of the cecum was ligated. At postoperative 6 h, 2 µl of saline were administered into the peritoneal cavity. An appendiceal resection was per-

formed through the re-laparotomy approach 24 h after the procedure.

Group 3 (Bosentan treatment): 6 h after the ligation of the distal cecum, 30 mg/kg bosentan were administered into the peritoneal cavity.

From all rats, 1 ml blood samples were drawn preoperatively and at the 24th hours following appendectomy to measure the plasma ET-1, malondialdehyde (MDA), and glutathione levels. All post-appendectomy tissue samples were analyzed to assess endothelin-1 levels.

The rats were sacrificed after 24 h, and their appendices were removed for biochemical and histological analyses. Tissue samples were vertically cut into two equal parts. One part was frozen for biochemical analysis at -80°C, and the other part was immersed in a 10% formaldehyde solution for histological examination.

Histopathological Evaluation

The tissue samples kept for histopathologic evaluation were fixed in neutral-buffered formalin for 24 h at room temperature. After dehydration and clarification, the tissues were embedded in paraffin wax, and 4-µm sections were collected on slides. After deparaffinization and rehydration, the sections were stained with hematoxylin and eosin (H&E) and mounted on glass slides. Sections were examined under light microscopy (X 400 magnification. Leica DM 1000; Leica Microsystems, Wetzlar, Germany), and photomicrographs were taken with a high-definition digital camera (Leica DFC 290 HD; Leica Microsystems, Heerbrugg, Switzerland). Histopathologic examination was performed by a pathologist blinded to the origin of the specimens. Inflammation was evaluated by a 4-point (0-3) semi-quantitative scale modified from Biert et al¹⁶ and Verhofstad et al^{17,18}. The degree of the necrosis and the extent of the lymphocyte, polymorphonuclear leukocyte, and macrophage infiltrations were scored from the lowest to the highest, and total scores were obtained accordingly (Table I).

Table I. Modified Biert-Verhofstad classification for histopathological evaluation.

Score	Necrosis	Polimorphonuclear Leukocyte	Lymphocytes	Macrophages
0	None	Normal number	Normal number	Normal number
1	Small patches	Slight increase	Slight increase	Slight increase
2	Some patches	Marked infiltration	Marked infiltration	Marked infiltration
3	Massive	Massive infiltration	Massive infiltration	Massive infiltration

Biochemical Analysis

Serum Preparation

Blood samples (1 ml) procured from the rats during the preoperative period and 24 h after surgery were placed in tubes with a gel separator, which did not contain any preservative substances. The samples were left at room temperature for coagulation and then centrifuged at 1000 rpm for 15 min to separate their serum portions. The separated sera were placed in Eppendorf tubes and stored in a deep freezer at -80°C until analysis. Serum samples were analyzed for their MDA levels, reduced and total glutathione, and ET-1 contents.

Tissue Preparation

Harvested tissue samples were first rinsed with distilled water and then allocated into 2 groups for histopathological examinations and biochemical tests. Samples retrieved for histopathological examination were immediately placed in 10% formaldehyde solution and sent to a pathology laboratory. The tissue samples assigned for biochemical analyses were immediately placed in a freezer (-80°C) until analysis. At the time of analysis, the samples were thawed and transferred into biochemistry tubes. Tissue samples weighing 100 mg were left in 10 ml 5% PBS buffer solution. Then, the cell membranes disintegrated, and the tissues were homogenized mechanically. The resulting homogenates were centrifuged at 5000 rpm for 5 min, and their supernatants were separated. Supernatant portions of the samples were transferred into Eppendorf tubes and used for further biochemical analyses.

Analysis of the Serum Samples and Tissue Specimens

The tissue MDA levels were measured using a manual method and Biovision (Milpitas, CA, USA) brand colorimetric commercial kits (K 739-100). The total and reduced tissue glutathione levels were measured using a manual method and Biovision (Milpitas, CA, USA) brand colorimetric commercial kits (K 261-100). The spectrophotometric analysis of these tissue samples was completed using a Pharmacia LKB Ultrospec III Spectrophotometer (Houston, TX, USA).

Serum and tissue ET-1 values were analyzed using a commercial Cusabio brand ELISA kit Cusabio (Wuhan, Hubei, China) and ELISA reader Biotek ELX800 (Winooski, VT, USA).

The results of the tissue analysis were expressed per g of tissue. 20 mg of bosentan (Actelion, Tracleer, Ro 470203-courtesy of Dr. Martine Clozel, F. Hoffman-La Roche Ltd, Basel, Switzerland) were dissolved in 20 ml distilled water and added to 20 ml saline for a total of 40 ml and diluted to obtain 1 mg bosentan sodium in 2 ml. The dose selection was based on the results of the previous studies^{19,20}.

Statistical Analysis

Statistical analyses were performed with SPSS software for Windows (SPSS, Inc, Chicago, IL, USA). Values were expressed as the mean \pm SD. The Kruskal-Wallis test was used for the variance analyses, and the Mann-Whitney U test was used to calculate the differences between groups. The Bonferroni correction was performed. Intergroup rates of categorical variables (PNL, macrophage, lymphocyte) were tested using the χ^2 test. $p < 0.05$ was considered to be statistically significant.

Results

A total of 21 rats were included in this study. None of the animals had to be excluded from the experiment. The total histopathological scores were compared between the groups, and inflammatory changes in the appendicitis group were significantly more severe about the other two groups ($p < 0.05$). However, in the bosentan treatment group, these manifestations were statistically significantly lower ($p < 0.05$).

Pairwise comparisons between the groups revealed significant differences for all groups in polymorphonuclear leucocyte (PNL), lymphocyte, and macrophage infiltrations ($p < 0.05$). Histopathological sections and the comparison of total pathology scores are shown in Figure 1 and Figure 2, respectively.

Intergroup comparisons of all biochemical data were performed for all groups. The tissue reduced glutathione value (GSH) levels did not demonstrate significant changes in the appendicitis group ($p = 0.848$), while the administration of bosentan increased the GSH levels significantly ($p = 0.013$). The tissue total glutathione values decreased significantly in the appendicitis group ($p = 0.004$), while the administration of bosentan significantly increased this value ($p = 0.002$) (Figure 3A-B). However, a statistically significant intergroup difference was not detected in the tissue MDA (Figure 4), tissue ET-1, or preopera-

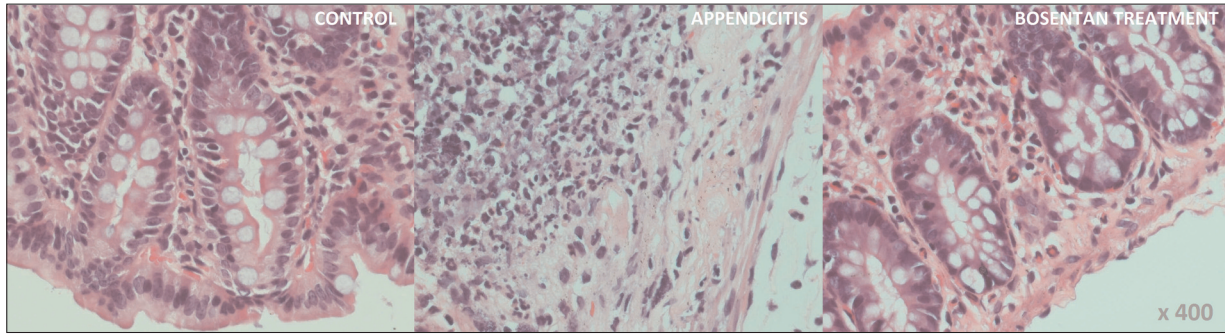


Figure 1. A. Intense polymorphonuclear leukocytes in the appendicitis group, rare polymorphonuclear leukocytes in the control group and mild polymorphonuclear leukocytes in the bosentan group are observed (H-E \times 400).

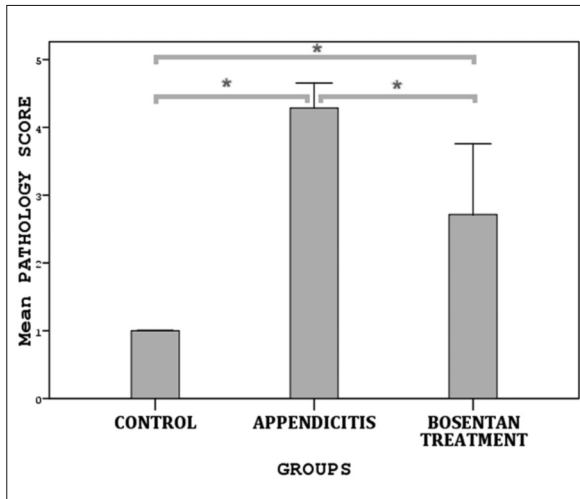


Figure 2. The comparison of total pathology damage scores; * $p < 0.017$, in intergroup comparisons

tive serum ET-1 values ($p > 0.05$). In contrast, the postoperative serum ET-1 values were statistically significantly higher only in the appendicitis group ($p = 0.025$). When the preoperative and 24 h postoperative serum ET-1 values were compared, significant increases in the postoperative serum ET-1 values were detected in the appendicitis group ($p = 0.018$). A statistically significant difference was not found in the comparisons of the same parameters in the control groups ($p = 0.50$). In the bosentan treatment group, a significant increase in the serum ET-1 values was detected 24 h after surgery ($p = 0.018$) (Figure 5A-B).

The histopathological findings and biochemical values for all groups are shown in Table II. The comparison of p -values among all groups is shown in Table III.

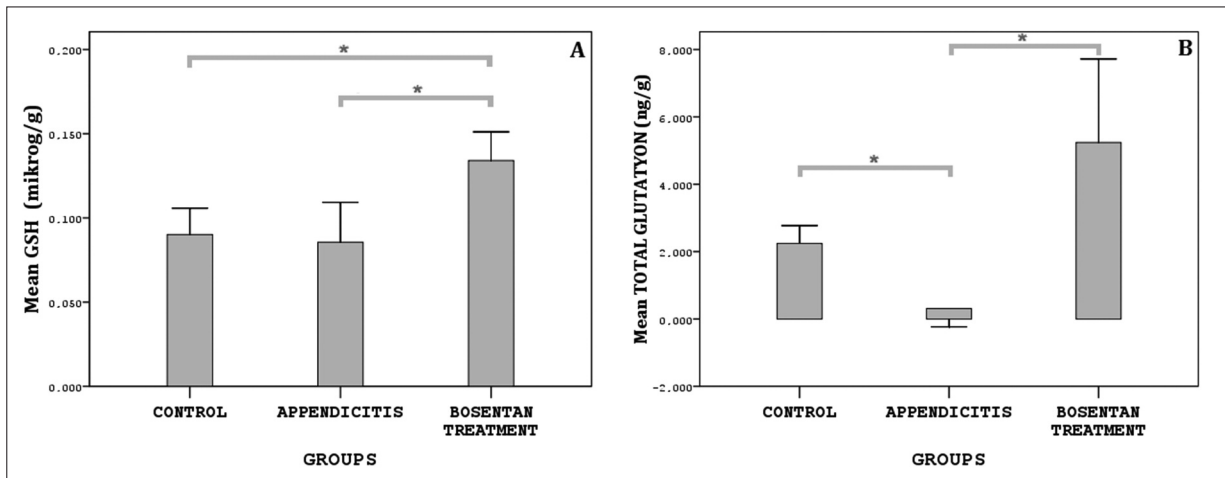


Figure 3. A-B, The comparison of reduced Glutathione (GSH) and total Glutathione levels; * $p < 0.017$, in intergroup comparisons.

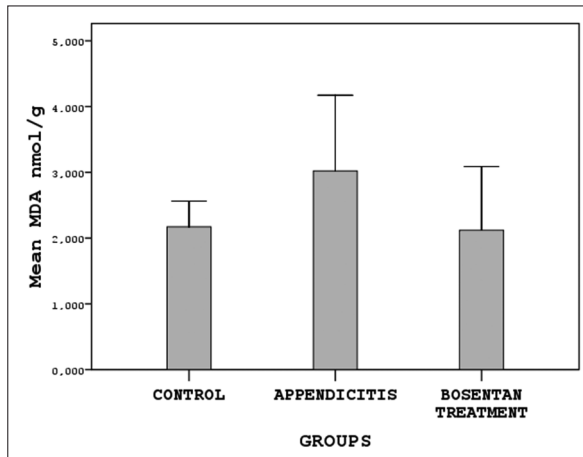


Figure 4. The comparison of MDA levels.

Discussion

Despite the many diagnostic methods used for AA, difficulties in the diagnosis of acute appen-

dicitis still exist, especially in small children, young girls, pregnant women, and the elderly, and the related negative outcomes of emergency appendectomies and perforations are considerably high^{21,22}. To date, no single diagnostic tool that establishes the diagnosis of acute appendicitis *per se* during the preoperative period has been introduced into clinical practice. In literature reviews, most of the tests performed with the intention to diagnose acute appendicitis have been only recommended because of their inapplicability in clinical practice. Furthermore, a panacea to be used for the treatment of acute appendicitis is not available²³. Apart from the conventional inflammatory biomarkers of white blood cell counts and C-reactive protein, many biomarkers, including 5-Hydroxyindoleacetic acid, procalcitonin, interleukins, leptin, lipopolysaccharide binding protein, calprotectin, lactoferrin, mean platelet volume, and neutrophil gelatinase-associated lipocalin, have been used for the diagnosis of appendicitis. However, the diagnosis of acute ap-

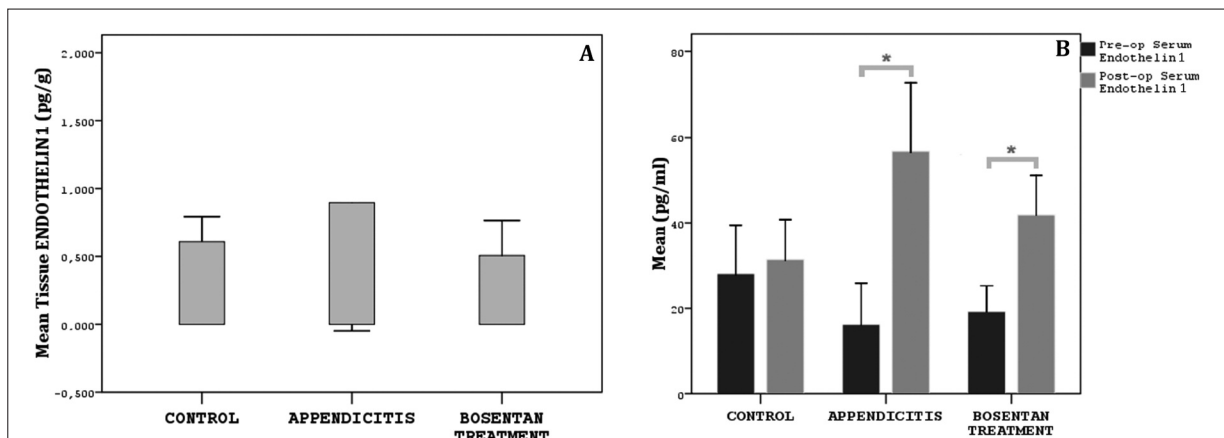


Figure 5. **A**, The comparison of tissue Endothelin-1 levels. **B**, The comparison of pre-op and post-op serum Endothelin-1 levels. * $p < 0.05$.

Table II. Histopathological findings and biochemical values of all of the groups (value \pm SD).

	Control	Appendicitis	Bosentan treatment
Rat weight (g)	240.3 \pm 20.7	245.0 \pm 25.9	236.1 \pm 23.0
Mean histopathologic score	1.00 \pm 0.00	4.14 \pm 0.69	3.29 \pm 1.80
Reduced glutathione (μ g/g)	0.09 \pm 0.02	0.09 \pm 0.03	0.13 \pm 0.02
Total glutathione (ng/g)	2.24 \pm 0.70	0.31 \pm 0.72	5.24 \pm 3.28
Malondialdehyde (nmol/g)	2.17 \pm 0.52	3.02 \pm 1.52	2.12 \pm 1.28
Tissue endothelin-1 (pg/g)	0.61 \pm 0.24	0.90 \pm 1.25	0.51 \pm 0.34
Pre-op plasma endothelin-1 (pg/ml)	28.13 \pm 14.99	16.25 \pm 12.56	19.25 \pm 7.84
Post-op (24 th hours) plasma endothelin-1 (pg/ml)	31.40 \pm 12.37	56.67 \pm 21.35	41.84 \pm 12.30

g: gram; SD: Standart Deviation; ng: nano gram; nmol: nano mol; pg: picogram; ml: millilitre.

Table III. The comparison of p-values among all groups.

	Control group vs. Appendicitis group	Control group vs. Bosentan treatment group	Appendicitis group vs. Bosentan treatment group
Total pathology scores	0.001*	0.009*	0.016*
Necrosis	Not different	Not different	Not different
PNL	0.004	0.004	0.004
Lymphocytes	0.001	0.001	0.001
Macrophages	0.001	0.001	0.001
Reduced glutathione	0.848	0.006*	0.013*
Total glutathione	0.004*	0.064	0.002*
Malondialdehyde	0.259	0.259	0.259
Tissue endothelin	0.447	0.447	0.447
Serum endothelin (preop)	0.118	0.118	0.118
Serum endothelin (postop)	0.025	0.142	0.110

$p < 0.05$ is accepted for statistical significance; * $p < 0.017$ is accepted for statistical significance (Bonferroni correction).

pendicitis remains challenging for the clinician, and specific biochemical agents aimed at the diagnosis and treatment of AA is still needed.

Adequate mucosal microvascular blood flow is critical in establishing the continuum of mucosal integrity. This blood flow decreases in septic conditions, leading to bleeding and tissue damage. A potential pathogenetic role of ET-1 in intestinal mucosal damage has been reported. ET-1 exerts its effects by lowering mucosal microvascular perfusion. Local intra-arterial infusion of low doses of ET-1 leads to the hemorrhagic injury of the gastrointestinal mucosa and widespread ulcerations. In inflammatory bowel disease, increased levels of this peptide have been observed in the lamina propria and submucosa with resultant vasoconstriction and intestinal ischemia. Polymorphonuclear leukocytes are important mediators of ET-1-induced intestinal damage. Oktar et al²⁴ reported that ET-1 caused the aggregation of polymorphonuclear leukocytes, oxidative stress, and mucosal dysfunction in the murine guts. The local production of ET-1 in the neutrophils and other inflammatory cells may be a focal inflammatory manifestation of appendicitis. This finding suggests that ET-1 may be responsible for vasoconstriction-induced ischemia. In another study, ET-1 infused into the superior mesenteric artery resulted in the dysfunction of the intestinal mucosa. Some authors reported a clear correlation between plasma endothelin levels and mortality rates in patients with sepsis. An endothelin receptor blockade can partially eliminate these pathologic effects of ET-1 by significantly decreasing polymorphonuclear

infiltration and intestinal mucosal damage. Gonon et al²⁵ observed that the ET receptor blockade weakened the myeloperoxidase activity and decelerated the recruitment of neutrophils. The beneficial effects of ET-1 receptor antagonists manifested through this mechanism of action have been reported in many diseases.

Bosentan is an endothelin receptor antagonist and is initially used in the oral treatment of pulmonary hypertension²⁶⁻²⁸. Potential beneficial effects of bosentan in scleroderma, glaucoma, diabetic nephropathy, atherosclerosis, rheumatoid arthritis, ovarian ischemia, reperfusion damage, and sepsis have been reported. As demonstrated in various studies, it also facilitates the healing of anastomotic sites by preventing the development of adhesions^{29,30}.

In our work, a significant increase in serum ET-1 during the postoperative period in the appendicitis group was observed, suggesting that serum ET-1 can be used as a diagnostic parameter for AA. Bosentan significantly suppressed the histopathological findings of AA. Bosentan did not induce significant changes in the ET-1 ratios. This result might be attributed to the low number of experimental animals and/or a mechanism of bosentan on other endothelin receptors. Further studies should be conducted on this subject.

Conclusions

The measurement of plasma ET-1 levels will be useful in the diagnosis of AA. Bosentan has proven to exert favorable effects on the

histopathological changes in experimental AA. However, for the effective clinical application of ET receptor antagonists, further studies should be conducted to improve our understanding of the pathophysiology of this system.

Acknowledgements

We thank Seref Etker for his contributions to this study.

Conflict of Interest

The Authors declare that there are no conflicts of interest.

References

- 1) PERANTEAU WH, SMINK DS. Appendix, Meckel's and other small bowel diverticula. In: Zinner MJ, Ashley W. Stanley, editors. *Maingot's Abdominal Operation*. 12th ed. New York: The McGraw-Hill Companies; 2013: 623-640.
- 2) MAA J, KIRKWOOD KS. THE APPENDIX. IN: TOWNSEND CM, BEAUCHAMP RD, EVERS BM, MATTOX KL, EDITORS. *Sabiston Textbook of Surgery*. 19th ed., Vol. II. Philadelphia: Saunders Company, an Imprint of Elsevier Inc.; 2012: 1279-1291.
- 3) CHEN CY, CHEN YC, PU HN, TSAI CH, CHEN WT, LIN CH. Bacteriology of acute appendicitis and its implication for the use of prophylactic antibiotics. *Surg Infect* 2012; 13: 383-390.
- 4) TAKEDA M, HIGASHI Y, SHOJI T, HIRAIDE T, MARUO H. Necrotizing fasciitis caused by a primary appendicocutaneous fistula. *Surg Today* 2012; 42: 781-784.
- 5) WOOD JG, YAN ZY, ZHANG Q, CHEUNG LY. Ischemia-reperfusion increases gastric motility and endothelin-1-induced vasoconstriction. *Am J Physiol* 1995; 269: 524-531.
- 6) KANAZAWA S, TSUNODA T, ONUMA E, MAJIMA T, KAGIYAMA M, KIKUCHI K. VEGF, basic-FGF, and TGF-beta in Crohn's disease and ulcerative colitis: a novel mechanism of chronic intestinal inflammation. *Am J Gastroenterol* 2001; 96: 822-828.
- 7) KOHAN DE, BARTON M. Endothelin and endothelin antagonists in chronic kidney disease. *Kidney Int* 2014; 86: 896-904.
- 8) YANG LL, GROS R, KABIR MG, SADI A, GOTLIEB AI, HUSAIN M, STEWART DJ. Conditional cardiac overexpression of endothelin-1 induces inflammation and dilated cardiomyopathy in mice. *Circulation* 2004; 109: 255-261.
- 9) KOHAN DE, PRITCHETT Y, MOLTICH M, WEN S, GARIMELLA T, AUDHYA P, ANDRESS DL. Addition of atrasentan to renin-angiotensin system blockade reduces albuminuria in diabetic nephropathy. *J Am Soc Nephrol* 2011; 22: 763-772.
- 10) KOHAN DE, ROSSI NF, INSCHO EW, POLLOCK DM. Regulation of blood pressure and salt homeostasis by endothelin. *Physiol Rev* 2011; 91: 1-77.
- 11) MASSAI L, CARBOTTI P, CAMBIAGGI C, MENCARELLI M, MIGLIACCIO P, MUSCETTOLA M, GRASSO G. Prepro-endothelin-1 mRNA and its mature peptide in human appendix. *Am J Physiol Gastrointest Liver Physiol* 2003; 284: 340-348.
- 12) BOSENTAN. Drug Facts and Comparisons 4.0. Efacts [online]. 2011. Available from Wolters Kluwer Health, Inc. <https://med.virginia.edu/pediatrics/wp-content/.../201111.pdf>
- 13) SUEKANE T, IKURA Y, ARIMOTO J, NAKAGAWA M, KITABAYASHI C, NARUKO T, WATANABE T, FUJIWARA Y, OSHITANI N, MAEDA K, TANZAWA K, HIRAKAWA K, ARAKAWA T, UEDA M. Enhanced expressions of endothelin-converting enzyme and endothelin receptors in human colonic tissues of Crohn's disease. *J Clin Biochem Nutr* 2008; 42: 126-132.
- 14) ANGERIO AD, BUFALINO D, BRESNICK M, BELL C, BRILL S. Inflammatory bowel disease and endothelin-1. A Review. *Crit Care Nurs Q* 2005; 28: 208-213.
- 15) ELEMEN L, YAZIR Y, AKAY A, BOYACIO LU Z, CEYLAN B, CEYLAN S. Comparison of bipolar electro-surgical devices with ligatures and endoclips in the rat appendicitis model. *J Pediatr Surg* 2011; 46: 1923-1929.
- 16) BIERT J, SEIFERT WF, VERHOFSTAD AA, WOBES T, DE MAN BM, HOOGENHOUT J, HENDRIKS T. A semiquantitative histological analysis of repair of anastomoses in the rat colon after combined preoperative irradiation and local hyperthermia. *Radiat Res* 1998; 149: 372-377.
- 17) VERHOFSTAD MH, LANGE WP, VAN DER LAAK JA, VERHOFSTAD AA, HENDRIKS T. Microscopic analysis of anastomotic healing in the intestine of normal and diabetic rats. *Dis Colon Rectum* 2001; 44: 423-431.
- 18) ELEMEN L, YAZIR Y, TUGAY M, AKAY A, AYDIN S, YANAR K, CEYLAN S. LigaSure compared with ligatures and endoclips in experimental appendectomy: how safe is it? *Pediatr Surg Int* 2010; 26: 539-545.
- 19) FEVANG J, OVREBØ K, MYKING O, GRONG K, SVANES K. Role of endothelin in the circulatory changes associated with small bowel strangulation obstruction in the pigs: effects of the endothelin receptor antagonist bosentan. *J Surg Res* 2001; 96: 224-232.
- 20) ROUX S, BREU V, ERTEL SI, CLOZEL M. Endothelin antagonism with bosentan: a review of potential applications. *J Mol Med* 1999; 77: 364-376.
- 21) ELДАР S, NASH E, SABO E, MATTER I, KUNIN J, MOGILNER JG, ABRAHAMSON J. Delay of surgery in acute appendicitis. *Am J Surg* 1997; 173: 194-198.
- 22) BURD RS, WHALEN TV. Evaluation of the child with suspected appendicitis. *Pediatr Ann* 2001; 30: 720-725.
- 23) BACHMANN LM, BISCHOF DB, BISCHOFBERGER SA, BONANI MG, OSANN FM, STEURER J. Systematic

- quantitative overviews of the literature to determine the value of diagnostic tests for predicting acute appendicitis: study protocol. *BMC Surg* 2002; 2: 2.
- 24) OKTAR BK, CO KUN T, BOZKURT A, YEGEN BC, YÜKSEL M, HAKLAR G, BILSEL S, AKSUNGAR FB, CETINEL U, GRANGER DN, KURTEL H. Endothelin-1-induced PMN infiltration and mucosal dysfunction in the rat small intestine. *Am J Physiol Gastrointest Liver Physiol* 2000; 279: 483-491.
- 25) GONON AT, GOURINE AV, PERNOW J. Cardioprotection from ischemia and reperfusion injury by an endothelin A-receptor antagonist in relation to nitric oxide production. *J Cardiovasc Pharmacol* 2000; 36: 405-412.
- 26) DUPUIS J, HOEPER MM. Endothelin receptor antagonists in pulmonary arterial hypertension. *Eur Respir J* 2008; 31: 407-415.
- 27) MOTTE S, McENTEE K, NAEJE R. Endothelin receptor antagonists. *Pharmacol Ther* 2006; 110: 386-414.
- 28) GUO L, LIU YJ, XIE ZL. Safety and tolerability evaluation of oral bosentan in adult congenital heart disease associated pulmonary arterial hypertension: a systematic review and meta-analysis. *Eur Rev Med Pharmacol Sci* 2014; 18: 638-645.
- 29) COZZI F, PIGATTO E, RIZZO M, FAVARO M, ZANATTA E, CARDARELLI S, RIATO L, PUNZI L. Low occurrence of digital ulcers in scleroderma patients treated with bosentan for pulmonary arterial hypertension: a retrospective case-control study. *Clin Rheumatol* 2013; 32: 679-683.
- 30) COZZI F, MONTISCI R, MAROTTA H, BOBBO F, DURIGON N, RUSCAZIO M, SFRISO P, ILCETO S, TODESCO S. Bosentan therapy of pulmonary arterial hypertension in connective tissue diseases. *Eur J Clin Invest* 2006; 36 Suppl 3: 49-53.