

# Experience on biocompatible artificial hair implant

G. MOKTHAR<sup>1,2,3</sup>, C. CHAKER<sup>1-4</sup>, M. VADALÀ<sup>1,2</sup>, M. GIACOMELLO<sup>5</sup>,  
A. GRECO LUCCHINA<sup>6</sup>, A. SCARANO<sup>7</sup>

<sup>1</sup>“Medico Cura Te Stesso” Onlus, Modena, Italy

<sup>2</sup>Second Opinion Medical Network, Modena, Italy

<sup>3</sup>Shaker Center, Agouza, Giza, Egypt

<sup>4</sup>Shaker Center, Heliopolis, Egypt

<sup>5</sup>Department of Medicine and Surgery, University of Milan, Bicocca, Italy

<sup>6</sup>Research Laboratory in Regenerative Medicine and Tissue Engineering, Saint Camillus International University of Health Sciences, Rome, Italy

<sup>7</sup>Department of Innovative Technologies in Medicine and Dentistry, University of Chieti-Pescara, Chieti, Italy

**Abstract. – OBJECTIVE:** In Europe, a great number of investigations and studies followed up to develop safer techniques performed by physicians only. Successful dedicated medical protocols included the implant of single fibers with extractable root. The aim of our study was to evaluate the efficacy of biocompatible artificial hair implants in patients with androgenetic alopecia.

**PATIENTS AND METHODS:** 682 patients (488 males and 184 females) aged between 25 and 70 years old, with diagnosed AGA, requiring no invasive nor surgical hair restoration, with problems of baldness and refusing surgical options appealed to the Second Opinion Medical Consulting (Modena, Italy), and were included in the present protocol. Before the treatment, all patients underwent a test implant to rule out hypersensitivity by implanting 100 fibers on a selected skin spot. If no reaction was detected, five weeks later 500-1,200 fibers were further implanted per session at a minimum interval of 5 weeks until the required aesthetic result was achieved.

**RESULTS:** The average number of sessions for each patient was 5. The average number of implanted fibers was 2,100 (ranging from 800 to 12,000). The treated scalp area returned to normal appearance and tenderness in 3 days.

**CONCLUSIONS:** The socio-psychological benefit and the life quality improvement of our patients have been the focus of the study. On our side, the accurate selection, small hair units for each implant session, customized dermatological consultation and the use of highly biocompatible fibers have been the proper strategy to achieve the goal.

*Key Words:*

Artificial hair implant, Hair surgery, Alopecia, Biofibre®, Baldness, Hair restoration

## Introduction

Androgenetic alopecia (AGA) affects millions of men and women worldwide. More than 50% of the men over 50 years old have some degree of hair loss<sup>1</sup>. In women, the hair loss is more frequent in postmenopausal<sup>2</sup>. From the aesthetic point of view, it has a significant emotional and social involvement namely on the self-esteem<sup>3,4</sup>.

## History Remarks

The artificial hair implantation technique was patented by Aurel Popovics of Török-Kanizsa, Austria-Hungary, on April 22, 1913, in the United States (patent 1,059,631)<sup>5</sup>. During the '70s/'80s, in Japan, it was strongly promoted by local manufacturing facilities, then spread world widely in the western countries<sup>6</sup>. Unfortunately, the reckless implantation by professionals' hairdressers without a medical training, the use of unsuitable materials and the invasive technique of anchoring in a non-reversible approach bulk of fibers sewed under the scalp, caused some relevant dermatological troubles in many patients<sup>7-9</sup>; therefore, FDA banned this technique in the US in 1983<sup>10</sup>. In Europe, however, a great number of investigations and studies followed up to develop safer techniques performed by physicians only. Successful dedicated medical protocols included the implant of single fibers with extractable root<sup>11</sup>. In 1995, artificial hair was approved in UE and Australia as a medical device and submitted to CE and TGA standards<sup>12,13</sup>. The positive outcome of this technique could only be obtained strictly

complying with a protocol that includes a qualified trained physician operator, a suitable informed and motivated patient, and a standardized regular post-operative protocol. The indication to the procedure is basically to relieve the social and psychological discomfort of the self-image due to the premature or progressive baldness<sup>4,15</sup>, male and female androgenetic alopecia and progressive thickening<sup>16</sup>, or to traumatic lesions of the scalp, burns, scars<sup>17</sup>, and for people that are not eligible for autologous stem cell transplant<sup>18</sup>.

### Patients and Methods

Our clinical experience reported in this study is referred to the certified medical device prosthetic hair Biofibre4.0<sup>®</sup> developed between January 2019 and February 2020. Biofibre4.0<sup>®</sup> is a sterile, inert, UV resistant, highly bio-compatible, medical grade VI Polybutylene terephthalate fiber which is 0.08-0.09 mm and 160-460 mm long suitable. It is available in 13 colors and 4 different shapes: the open knot at one tip of the fiber is inserted into the scalp subdermal layer, inducing a collagenic fibrotic reaction. This knot can be reversely withdrawn without any foreign body left behind.

682 patients (488 males and 184 females), aged between 25 and 70 years, with diagnosed AGA, requiring not invasive, not surgical hair restoration, appealed to the Second Opinion Medical Consulting, from February 2020 to February 2021, with problem of baldness refusing surgical

options and were included in the present protocol. The Second Opinion Medical Network is a consultation referral web and medical office system enclosing a wide panel of specialists, to whom any patient with any illness or syndrome not adequately satisfied with diagnosis or therapy can ask for an individual clinical audit or specific counseling<sup>19-22</sup>. According to the principles of the Declaration of Helsinki, all patients signed an informed consent form about the artificial hair procedure pros and cons and were included on the basis of the following inclusion and exclusion criteria (Table I). A grade of AGA was assigned for men as per the Modified Norwood-Hamilton criteria, modified from the earlier Hamilton classification (Table II), consisting of seven broad groups and four specific variant types<sup>23,24</sup> and for female as per the three-point Ludwig scale<sup>25</sup> and the five-point Sinclair scale<sup>26</sup> (Tables III-IV). The majority of the 488 male enrolled patients were affected by AGA II according to Norwood-Hamilton scale. More in details, 9.08% of male patients was classified in group II and variant, the 23.97% in group III and variants, the 28.93% in group IV and variant, the 21.90% in group V and variants, the 12.19% in the group VI and the 3.93% of male patients was classified in group VII (Figure 1). The 184 female patients were classified according to the Ludwig's AGA scale as follows: 26.63% was included in group I, 53.26% was in group II and 20.11% in group III (Figure 2). The same group was classified also, according to the Sinclair's AGA scale, as following: 26.63% was included in group II, 29.89%

**Table I.** Inclusion and exclusion criteria of the participants to study.

Inclusion criteria	Exclusion criteria
<ul style="list-style-type: none"> <li>- Clinical diagnosis of androgenetic alopecia and grading with Hamilton scoring,</li> <li>- Patient with AGA grade I-V of modified Hamilton-Norwood or grade I-II of Ludwig scale</li> </ul>	<ul style="list-style-type: none"> <li>- Severe insulin dependent diabetes,</li> <li>- Dermatitis or any dermatosis of the scalp,</li> </ul>
<ul style="list-style-type: none"> <li>- Good general health without any other pathology of the scalp,</li> <li>- Patients willing to return for follow up,</li> <li>- Signed informed consent</li> </ul>	<ul style="list-style-type: none"> <li>- Other chronic metabolic and autoimmune diseases,</li> <li>- Severe cardiovascular and kidney insufficiency,</li> <li>- Cancer or chemotherapy or immunosuppressive drugs,</li> <li>- Psychiatric problems, trichotillomania, maniac depressive moods,</li> <li>- Skin problems, previous keloids in any area of the body surface, psoriasis, chronic skin eczema or chronic infectious inflammations, skin cancers,</li> <li>- Allergies,</li> <li>- Patient who has tendency to form keloid,</li> <li>- Pregnant women</li> </ul>

**Table II.** Modified Norwood-Hamilton classification.

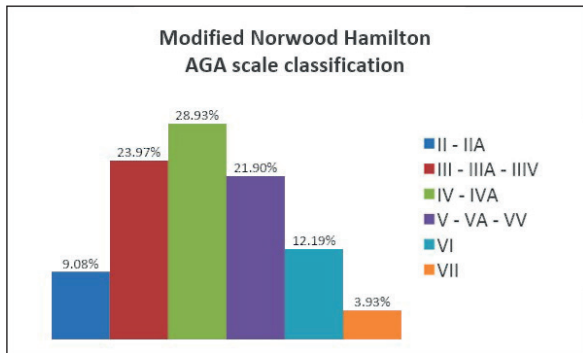
Type	Clinical definition
I	Minimal recession of the hairline along the anterior border in the frontotemporal (FT) region.
II	The anterior border of the hair in the FT region has triangular areas of recession that tend to be symmetrical. These areas extend no further posterior than approximately 2 cm anterior to a line drawn in a coronal plane between the external auditory meatus on both sides. Hair is either lost or sparse along the mid-frontal border of the scalp.
III	Characterized by deep FT hair recession, usually symmetrical and either bald or sparsely covered with hair. These areas of hair recession extend further posterior than a point that lies approximately 2 cm anterior to a line drawn in a coronal plane between the external auditory meatus on either side.
IIIv (vertex)	Hair is mainly lost in the vertex. There may be some frontal recession, but it does not exceed that seen in type III.
IV	The frontal and FT recession are more severe than in type III. There is also sparseness or absence of hair in the vertex area. These bald areas are wide, but separated from each other by a band of moderately dense hair that joins the fully haired fringe on each side of the head.
V	The hair loss over the vertex and FT areas is larger than in type IV and the band of hair between them is narrower and sparser.
VI	The hair loss over the FT and vertex regions is confluent and the bridge of hair that crosses the crown is absent.
VII	There is only a narrow horseshoe-shaped band of hair that begins laterally just anterior to the ear and extends posteriorly on the sides and fairly low on the occipital area.
Variants (Type variants-a)	Constitutes 3% of all cases of AGA: (i) the entire anterior border of the hairline progresses posteriorly without the normal island of hair in the mid-frontal region and (ii) there is no simultaneous development of a bald area on the vertex. Instead, the anterior recession just advances posterior to the vertex.
Ila	The entire anterior border of the hairline lies high on the forehead. The usual mid-frontal island of hair is represented by only few sparse hairs. The area of denudation extends no farther than 2 cm from the frontal line.
IIIa	The area of denudation reaches the mid-coronal line.
IVa	The area of denudation extends beyond the mid-coronal line and there may be considerable thinning of hair posterior to the actual hair line.
Va	Most advanced degree of alopecia; however, the bald area does not reach the vertex.

**Table III.** Ludwig's Scale for female AGA.

<b>Stage 1</b>	Thinning of hair is seen mainly over the anterior part of the crown with minimal widening of the parting width.
<b>Stage 2</b>	Thinning of the crown becomes more evident because of an increase in the number of thin and short hairs.
<b>Stage 3</b>	The crown becomes almost total bald. There is a significant widening of the parting width, but the frontal hairline is still maintained.

**Table IV.** Sinclair scale for female pattern AGA.

<b>Grade 1</b>	Is normal. This pattern is found in all girls prior to puberty but in only forty-five percent of women aged eighty or over.
<b>Grade 2</b>	Shows a widening of the central part.
<b>Grade 3</b>	Shows a widening of the central part and thinning of the hair on either side of the central part.
<b>Grade 4</b>	Reveals the emergence of a diffuse hair loss over the top of the scalp.
<b>Grade 5</b>	Indicates advanced hair loss.



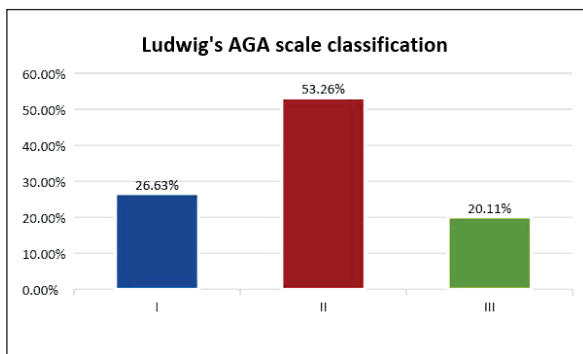
**Figure 1.** Modified Norwood Hamilton AGA scale classification.

was in group III, the 23.37% in the group IV and the 20.11% was in group V (Figure 3). The patients were addressed to Dr. G. Mokhtar and Dr. C. Chaker as qualified experts of Biofibre® hair implants, and they sent to our supervising Second Opinion Consulting office periodical notes about the individual procedures and about the clinical follow-up of each patient.

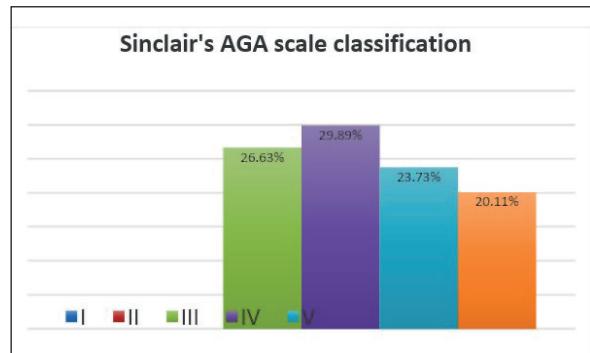
**Pre-Implantation Visit**

Scalp sebum concentration and hydration were carefully evaluated in order to state the proper follow-up schedule<sup>27</sup>. The patient was warned that the implants would have been performed in a low number of units through multiples sessions, preceded by an individual compatibility test of 100 fibers. The first postimplant visit was done after 5 weeks on average, but it was anticipated in case of any suspect adverse event.

Each implant following session could be performed with no more than 1,200 fibers in different scalp areas<sup>28,29</sup>. During the implant, the physician disinfected the implanted area with hydrogen peroxide without rubbing, in order to



**Figure 2.** Ludwig's AGA scale classification.



**Figure 3.** Sinclair's AGA scale classification.

avoid surfacing the fibers. To have a long-lasting result, the root of the fiber was placed in the galea capitis, to be held by the fibrous tissue avoiding any traction to reduce causes of premature fall of the fiber. Inclination degree of the implanter shall be around 45° and 60° with respect to the scalp and front-line implant shall be performed in staggered way.

**Description of the Procedure**

Minocycline oral antibiotic (100 Mg) was administered the day before the implant for 7 days. The patient was lying in a comfortable sitting on a professional chair. Povidone iodine and hydrogen peroxide 3% (10 vol.), were administered at the beginning of the procedure. The area to be implanted was then injected with lidocaine at 2% plus adrenaline 1:100,000, through a 3 ml syringe luer lock with a 30-gauges needle. The amount of injected anesthetic had to be just enough to create an ischemic white spot in the implantation area (nearly 1 cc. every 4-5 cm<sup>2</sup> of the scalp). We inserted the needle horizontally and slowly injected anesthetic on the surface and in the layers of the derma, in order to achieve greater vasoconstriction and duration of the anesthesia. After anesthesia and before implantation, the scalp was carefully further disinfected with chlorhexidine and dried with low temperature air spray for a couples of minutes. Before the treatment, all patients were submitted to a test implant to rule out hypersensitivity by implanting 100 fibers on a selected skin spot. If no reaction was detected, 500-1,200 fibers five weeks later were further implanted per session at a minimum interval of 5 weeks until the required aesthetic result was achieved. Each session was performed with maximum sterility and disinfection care as in the above protocol. A

straight automatic implanter needle was used to insert the knot of the fiber into a standard depth deep into the galea and then withdrawing the device. The fibers were inserted at 2 mm distance from each other, paying attention not to displace them with undue tractions. Inclination degree of the implanter had to be around 45° and 60° with respect to the scalp and front-line implant was performed in zig-zag way to get a more natural final result. At the end of the procedure, a sterile gauze was applied with ice pack for 5 minutes on the implanted area then disinfected with chlorhexidine. Topical (bacitracin, fusidic acid), as well as systemic antibiotic, were prescribed, and also an antiseptic shampoo each other day for a week. The first shampoo was prescribed to be used 2 days later with ketoconazole and with great care, because the implants were not steadily anchored yet to the galea by fibrous reaction. The first week after implant, the antibiotic therapy was pursued with daily chlorhexidine sprayed on the scalp. Neutral shampoo was prescribed twice a week for the first month, or even more often in selected cases. Ketoconazole shampoo once a week and chlorhexidine every 2 days were considered to be a good implant preservation policy. Dermatologic check-up was fixed after 5 weeks.

Clinical examination and scalp hygiene assessment were performed at each monthly session for the first year and every three months for the second year. Any adverse event was registered. Each patient filled in a short form of the medical outcome health survey questionnaire (SF-36) at baseline and after two years. The questionnaire measures health-related quality of life (QoL) in eight settings: vitality, general health perceptions, physical functioning, physical role func-

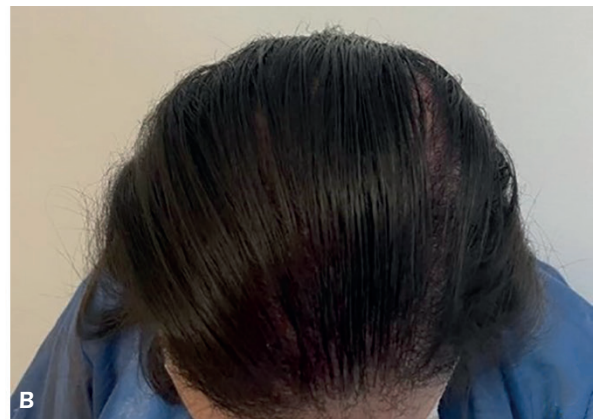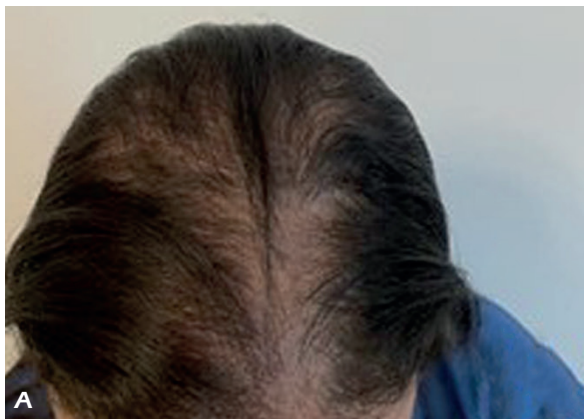tioning, emotional role functioning, social role functioning, bodily pain, and mental health. Each scale is scored using norm-based methods, with percentage scores ranging from 0% (lowest or worst response) to 100% (highest or best possible response)<sup>30</sup>.

### Statistical Analysis

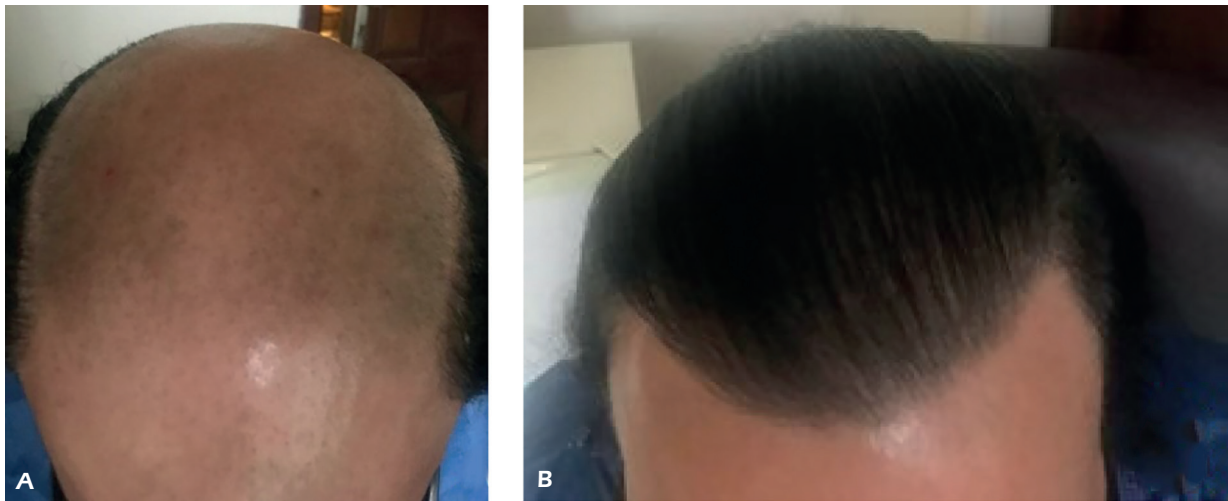The statistical analysis was performed using the statistical software package Graph Pad 8 (Prism Pad Software Inc., San Diego, CA, USA). The results were expressed as value ± standard deviation (DS). The groups of data were compared through the Student's *t*-test, considering a level of significance of  $p < 0.05$ .

### Results

The average number of sessions for each patient was 5. The average number of implanted fibers was 2,100 (ranging from 800 to 12,000). The treated scalp area returned to normal appearance and tenderness in 3 days. Analgesics were not ordinarily required after the procedure. No intraoperative or postoperative complications were observed. In the follow-up, 65% of patients attended the operative sessions only, without further control visits, while 35% underwent regular checks. In the following 6 months, a thorough cleaning of the pooled sebum around the implant shaft usually restores the integrity of the newly formed follicle. Our follow-up was done with periodic visits at the clinic, monthly for 6 months and then with telemedicine interviews and photos of the scalp (Figures 4-6). The sebum storage in the scalp has been our primary concern in terms of prophylaxis and patient education: in fact, the exceeding



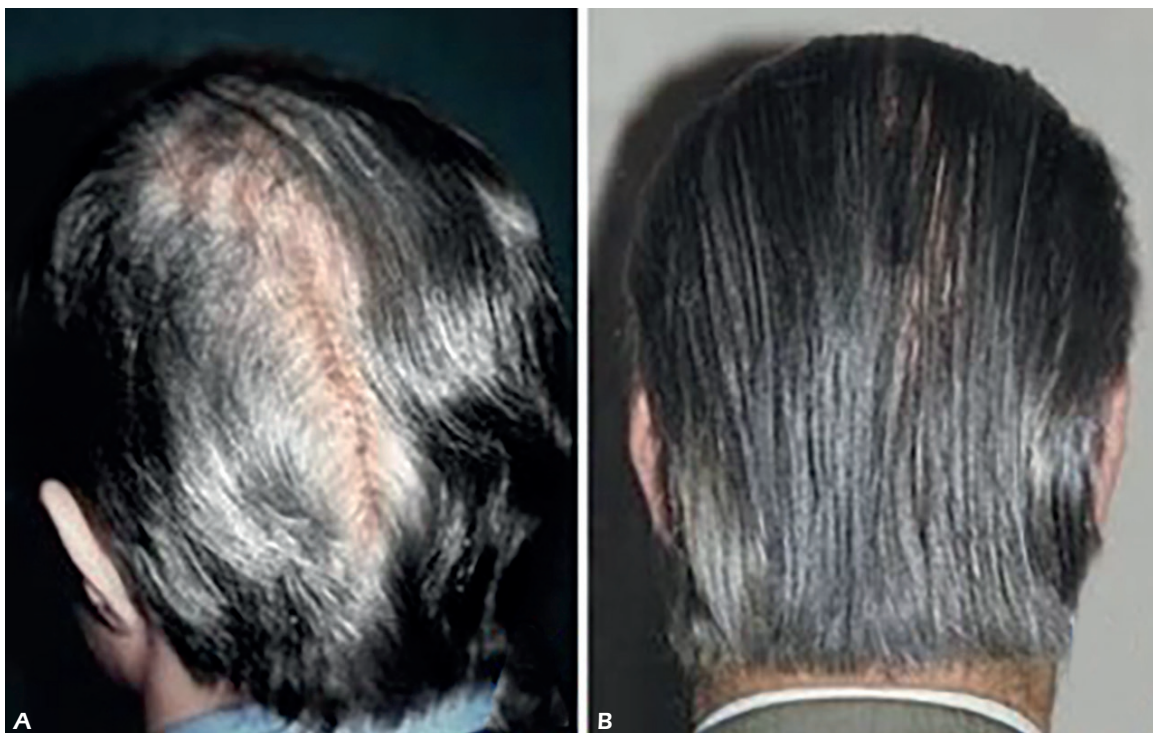**Figure 4.** A-B, Female patient treated with 2,000 Biofibre 4.0® in 3 sessions.



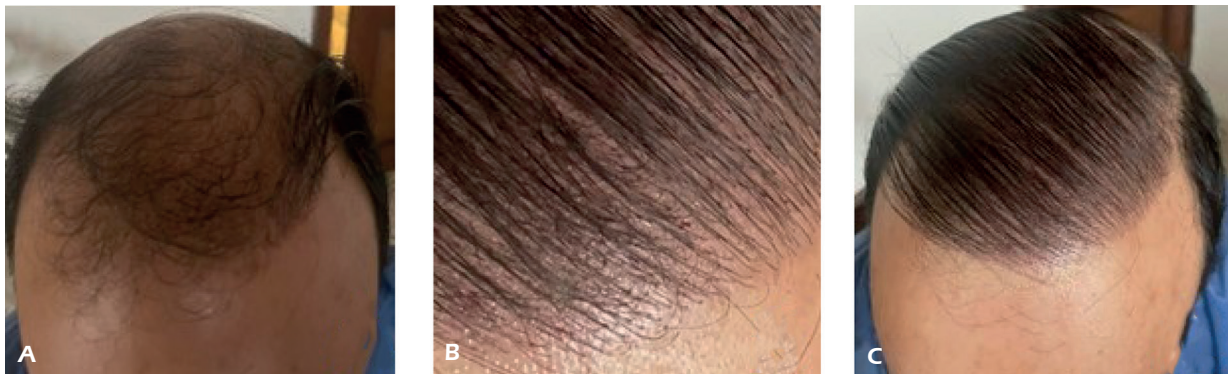
**Figure 5.** A-B, Male patient treated with 5,000 Biofibre 4.0® in 6 sessions.

sebum pools at the base of the implanted fibers causes a high percentage of implants drops. We observed sebum increase in the implanted area in 72 patients, but only 31 participants developed an infectious or inflammatory (24 mild, 7 medium) complications (Figures 7-8). All the 24 “mild” cases were successfully treated by a local therapy with fusidic acid plus hydrocortisone cream and chlorhexidine. The healing average time was 8

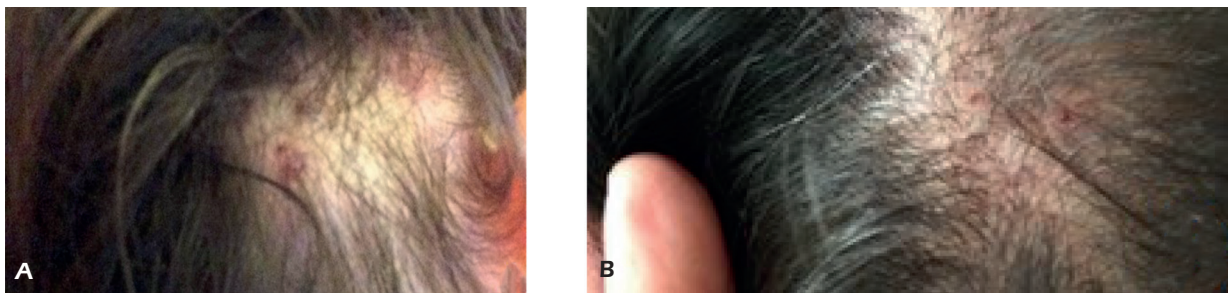
days. The 7 “medium” cases were treated by systemic antibiotic with ciprofloxacin 250 mg: 2x10 days and steroid prophylaxis with betamethasone 1 mg: 2x3 days, then 1x3 days, in addition to local therapy as before. The average time to heal was 3 weeks. Two of these cases got recurrent problems, so fibers extraction was provided. In 2 cases curling of some fibers was noticed and they are regularly replaced (Figure 9). In the group of



**Figure 6.** A-B, Scalp scars treated with 2,000 Biofibre 4.0® in 2 sessions.



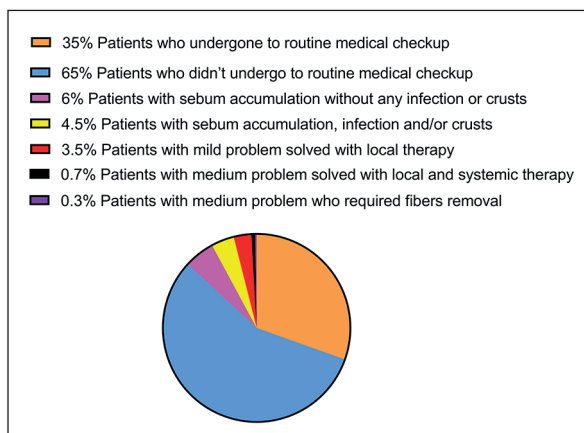
**Figure 7.** A-C, Sebum accumulation crusts before and after 1 week treatment.



**Figure 8.** A-B, Suitable and risky area for implant.

patients unable to attend correctly to their scalp hygiene, as recommended, we noticed almost 20% hair drop out in the follow-up compared to the 10% normal average standard<sup>31,32</sup>. The fibers loss had a purely economic impact, but it did not contraindicate their replacement, and the majority of the patients applied for restoration with further sessions, due to the psychological advantage acquainted. Sebum accumulation was removed at

the clinic, both mechanically and locally administering phosphatidylcholine and sodium deoxycholate. In 8 cases, local infiltration of organic silicious (monomethyltrisilanol salicylate) was required to smooth out the skin roughness caused by neglected sebum plugs. The overall patient's satisfaction registered was more than 95%. The main efficacy endpoints, as assessed by the SF-36 questionnaire, testify that significant improvements in the mental and physical role functioning score ( $p<0.02$ ), in general health, in social role relationships ( $p<0.02$ ), vitality ( $p<0.03$ ), and a higher threshold of body pain ( $p<0.03$ ) were achieved. Changes in role limitations ( $p=0.02$ ) or emotional state, with reduction of typical AGA symptoms including social anxiety, less self-esteem were observed (Figure 10).

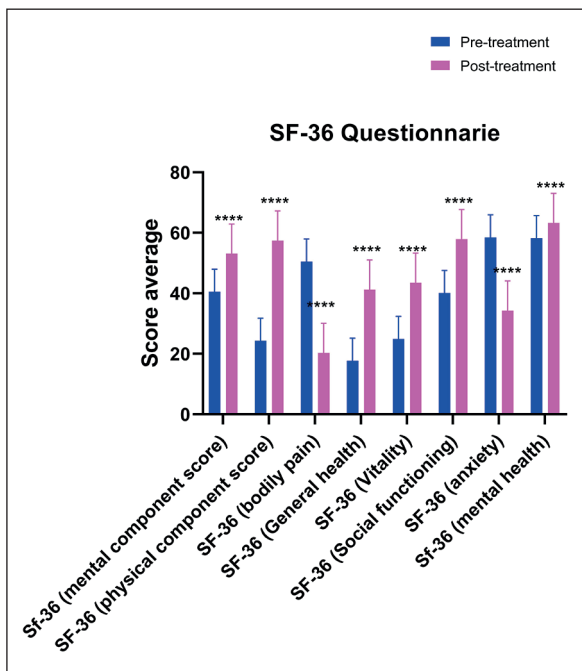


**Figure 9.** Clinical patterns of the implanted patients.

## Discussion

### **Recommendation for a Safe Implant Procedure**

Not all the scalp areas are suitable for the implant. Temporal area or low front line are risky areas for dropping, inflammatory and/or infec-



**Figure 10.** Graphical Representation of results SF36 questionnaire. Bar graphs showing the mean % SF-36 questionnaire results for the Pre-treatment (blue graphs) and Post-treatment (fuchsia graphs) group. The SF-36 values were already statistically better than those collected pre-treatment. \*\*\*\* $p < 0.0001$  pre- vs. post-treatment.

tious processes due to the thin or null galea layer and presence of muscle bands. It is mandatory to never implant two fibers in the same hole and, in case, remove one of them. Suggested distance between two implanted fibers is 2 mm to avoid possible grouping. The implant sessions are performed with a 5-weeks interval from each other. According to our experience, the limited number of implanted fibers (700 on average each time) has two main advantages: the patient's skin is not exceedingly stressed, so the scalp post-implant inflammatory reaction is always reduced and shortened, accelerating the skin healing. The implanted patient has to be aware that the lifespan of biocompatible artificial hair depends by himself. The health of his scalp and its regular hygiene are required for the best customer and mutual satisfaction. Each doctor, based on the geographical location and the different uses and habits of the patients, could face different problems. The most frequent problem regards sebum management. Patients living in certain areas might have more difficulties to undergo post-implantation check-ups and to abide to the aftercare protocol. Some patients may

develop a greater quantity of sebum that, in case of poor hair care, sticks at the base of the implanted fibers, causing unsightly blackspots and dilatation of the newly formed follicle with early loss of the fibers, crusts, and infection risk. The sebum can be removed directly in the clinic with appropriate procedure that includes use of a suitable forceps. Before this procedure, we recommend spraying a steam flow or to put a warmed wet towel over the scalp to open the pores for half an hour and subsequently to spray with chlorhexidine. As recent alternative to the mechanical comedos clearance, a solution of phosphatidylcholine and sodium deoxycholate can be locally applied to the scalp to get sebum more fluid and removable by a cotton swab. The PPC/DEOX preparation has a composition of 250/125 mg per vial (50-25 mg/mL in 5-mL vials). The DEOX preparation has a composition of 237.5 mg per vial (47.5 mg/mL in 5-mL vials). The sebum complications can be prevented with a daily neutral shampoo and a periodical application of light antiseptic spray, added with sebolytic and keratolytic formulae. A rotational manual cleaning once a month during the shampoo with a soft toothbrush is a simple but effective measure to remove the excess of sebum. It is important to consider that, in case of prolonged and massive accumulation, these sebum plugs can create roughness of the skin scalp, which can be reduced or erased by localized infiltrations of organic silicious (monomethyltrisilanol salicylate).

## Conclusions

The postoperative follow-up and its outcome are influenced by the individual genetic and psychological background and by external factors. The sebum management is the hardest topic to face. Sebum is a natural protective shield of the skin, but if exceeding into the newly formed follicles, it has to be cleared out regularly. Periodic and careful sebum removal is very important to preserve the long-standing turnover of the implants and to reduce the risk of inflammatory or septic untoward effects. The number and the degree of complications encountered in our clinical experience can be considered quite low, taking in account that part of the implanted patients did not fully comply with our maintenance recommendations. The socio-psychological benefit and the life quality improvement of our patients have been



the focus of the current study. On our side, the accurate selection, small hair units for each implant's session, customized dermatological consultation and the use of high biocompatible fibers have been the proper strategy to achieve the goal.

#### Conflict of Interest

The Authors declare that they have no conflict of interests.

#### Funding

This study did not receive any specific grant from funding agencies in the public, commercial, or not-for-profit sectors.

#### Availability of Data and Materials

All data generated or analyzed during this study are included in this published article.

#### Authors' Contribution

All authors were involved with the literature review and performance of the surgery. All authors read and approved the final manuscript.

#### Ethics Approval

The requirements of the Helsinki Declaration were observed, and the patient gave informed consent for all surgical procedures. This study was conducted in full accordance with ethical principles, including the World Medical Association Declaration of Helsinki (<https://www.wma.net/wp-content/uploads/2018/07/DoH-Oct2008.pdf>) and the additional requirements of Italian law.

#### Informed Consent

Written informed consent was obtained from the patient for publication of this case report and accompanying images.

#### ORCID ID

Mokthar Ghada: 0000-0001-7992-4828; Chaker Cherine: 0000-0001-6118-143X; Maria Vadalà: 0000-0001-7992-4828; Carmen Mortellaro: 0000-0002-1150-1906; Antonio Scarano: 0000-0003-1374-6146.

## References

- 1) Cranwell W, Sinclair R, Feingold KR, Anawalt B, Boyce A, Chrousos G, de Herder WW, Dhatariya K, Dungan K, Hershman JM, Hofland J, Kalra S, Kaltsas G, Koch C, Kopp P, Korbonits M, Kovacs CS, Kuohung W, Laferrère B, Levy M, McGee EA, McLachlan R, Morley JE, New M, Jonathan Purnell J, Sahay R, Singer F, Sperling MA, Stratakis CA, Trencle DL, Wilson DL, Male androgenetic alopecia. *Endotext*. South Dartmouth (MA): MD-Text.com, Inc.; 2000; 2016: 29.
- 2) Goluch-Koniuszy ZS. Nutrition of women with hair loss problem during the period of menopause. *Prz Menopauzalny* 2016; 56-61.
- 3) Davis DS, Callender VD. Review of quality-of-life studies in women with alopecia. *Int J Womens Dermatol* 2018; 4: 18-22.
- 4) Scarano A, Rapone B, Amuso D, Inchingolo F, Lorusso F. Hyaluronic Acid Fillers Enriched with Glycine and Proline in Eyebrow Augmentation Procedure. *Aesthetic Plast Surg* 2022. 46: 419-428.
- 5) Office, U.S.P., Patent #1,059, 63; 1913.
- 6) Fukuta K, Narita I, Jodo TA. New procedure of cosmetic prosthetic surgery for baldness. *J Plast Reconstr Surg* 1976; 19: 6.
- 7) Hanke CW. Fiber Implantation for Pattern Baldness. *JAMA* 1979; 241: 146.
- 8) Schwartz RS, Downham 2nd TF. Dangers of synthetic fiber implantation for male pattern baldness. *Cutis* 1980; 25: 491-492.
- 9) DiGregorio VR, Rauscher G. Experience with the Complications of Synthetic-Hair Implantations. *Plast Reconstr Surg* 1981; 68: 498-504.
- 10) Administration, F.a.D., Proceed Listing of banned devices, prosthetic hair fibres. *Code of Federal Regulations* 1983; 21: 101.
- 11) D'ugo A, Santiago M, Chaker C, Perez Rangel R, Saad Eddin U, Ramponi V. Safety of Biofibre® CE 0373/TGA artificial hair implants: importance of the scalp anchoring system. Chicago, USA: International Society of Hair Restoration Surgery, 10<sup>th</sup> Annual Meeting; 2002.
- 12) Directive 93/42/EEC of the Council concerning Medical Devices, 1993.
- 13) Universal Medical Device Nomenclature System, P, Hair, Universal Medical Device Code.
- 14) Ramos O, Tchernev G, Chokoeva AA, Wollina U, Maximov GK, Patterson JW, Fioranelli M, Rocchia MG, Ananiev J, Lotti T. Biofibre hair implant- impact on the quality of life. *J Biol Regul Homeost Agents* 2016; 30: 21-25.
- 15) Van Der Donk J, Hunfeld JA, Passchier J, Knegt-Junk KJ, Nieboer C. Quality of life and maladjustment associated with hair loss in women with alopecia androgenetica. *Soc Sci Med* 1994; 38: 159-163
- 16) D'ugo A. Follow-up study of 503 patients three years after surgical implantation of artificial fibres on the scalp. XXV Congreso Argentino Di Cirugia Plastica, Buenos Aires, Argentina, 1995.
- 17) Santiago M, Pérez-Rangel R, D'Ugo A, Griselli G, Garigin I, Martin IG, Nesheim GB, Eddin US, Smith G, Brady GW, Chaker C. Artificial Hair Fiber Restoration in the Treatment of Scalp Scars. *Dermatol Surg* 2007; 33: 35-43.
- 18) Brady G. Cases without Hope—Innovative Solutions in Difficult Cases. In: International Society of Hair Restoration Surgery, 13th Annual Meeting, Sydney, Australia 2005.

- 19) Palmieri B, Capone S, Fistetto G. Second opinion consultation: is Babel-web syndrome curable? *Recenti Prog Med* 2011; 102: 43.
- 20) Palmieri B, Laurino C, Vadalà M. The "second opinion medical network." *Int J Pathol Clin Res* 2017; 3: 1-7.
- 21) Palmieri B, Manenti A, Di Cerbo A, Imperiale G, Iannitti T. A place for a second opinion in the field of surgery. Ed. *Minerva Medica-Chirurgia* 2013; 26: 447-449.
- 22) Di Cerbo A, Palmieri B. The economic impact of second opinion in pathology. *Saudi Med J* 2012; 33: 1051-1052.
- 23) Hamilton JB. Patterned loss of hair in man: types and incidence. *Ann N Y Acad Sci* 1951; 53: 708-728.
- 24) Norwood OT. Male pattern baldness: classification and incidence: *South Med J* 1975; 68: 1359-1365.
- 25) Ludwig E. Classification of the types of androgenetic alopecia (common baldness) occurring in the female sex. *Br J Dermatol* 1977; 97: 247-254.
- 26) Sinclair R, Jolley D, Mallari R, Magee J. The reliability of horizontally sectioned scalp biopsies in the diagnosis of chronic diffuse telogen hair loss in women. *J Am Acad Dermatol* 2004; 51: 189-199.
- 27) Palmieri B, Griselli G, D'ugo A, Palmieri G, Salti G. Evaluation of polyamide synthetic hair. A long-term clinical study. *Panminerva Med* 2000; 42: 49-53.
- 28) González MM. Biofibre hair replacement. In: *ASAPS 35 Th Anniversary Meeting, Las Vegas, NV, USA, 2002.*
- 29) Rateb Said AAH, Albzour BM, Santiago M, Agrawal M, Rovesti M, Satolli F, Wollina U, Tchernev G, Lotti J, Lotti T. Automatic Artificial Hair Implant: Safety and Efficacy in Androgenetic Alopecia. A Prospective Study with a Highly Biocompatible Fiber. *Open Access Maced J Med Sci* 2017; 6: 38-42.
- 30) Ware JE, Sherbourne CD. The MOS 36-Item Short-Form Health Survey (SF-36): I. Conceptual Framework and Item Selection. *Med Care* 1992; 30: 473-483.
- 31) Roccia M, França K, Castillo D, Tchernev G, Wollina U, Tirant M, Valle Y, Guarneri C, Fioranelli M, Lotti T. Artificial Hair: By the Dawn to Automatic Biofibre® Hair Implant. *Open Access Maced J Med Sci* 2017; 6: 156-162.
- 32) Agrawal M, Lotti J, França K, Fioranelli M, Roccia MG, Lotti T. The evolution of artificial hair implantation. *J Biol Regul Homeost Agents* 2017; 31: 169-177.