

Scaphoid nonunion reconstructed with vascularized bone-grafting pedicled on 1,2 intercompartmental supraretinacular artery and external fixation

K. LIANG, Z. KE, L. CHEN, M. NIE, Y. CHENG, Z. DENG

Orthopaedic Department, the Second Affiliated Hospital, Chongqing Medical University, Chongqing, P.R. China

Abstract. – BACKGROUND: Vascularized bone-grafting pedicled on 1,2 intercompartmental supraretinacular artery (1,2 ICSRA) has been recommended as a treatment alternative for established scaphoid nonunion complicated with proximal pole avascular necrosis (AVN). Previous reports focused the studies on the union rate and the revascularization of the transferred graft. However, the postoperative wrist stiffness still a challenging problem and remaining to be solved. The purpose of our study was to determine whether the combination of vascularized bone-grafting pedicled on 1,2 ICSRA and wrist external fixator immobilization provides a more effective strategy for treating established scaphoid nonunion complicated with AVN and improving postoperative range of motion (ROM) of the injured wrist.

PATIENTS AND METHODS: We retrospectively reviewed a consecutive series of 11 patients who had cases of established scaphoid nonunion involving AVN of the proximal pole were treated with vascularized bone-grafting pedicled on 1,2 ICSRA, internal fixation, and wrist external fixator immobilization. Procedure of wrist arthrolysis was performed before vascularized bone graft transferring. Preoperative and postoperative evaluation included measurement of clinical (wrist ROM and grip strength), radiographic (intrasaphoid angle, scapholunate angle) and functional (Mayo wrist score) parameters.

RESULTS: Osseous union was achieved in all of the 11 cases within an average period of 11.4 weeks. On an average 6.1 years follow-up, there were three excellent, six good and two fair results. Significant improvements were found for Mayo wrist score, wrist ROM, and grip strength ($p < 0.01$). Intrasaphoid angle and scapholunate angle were significantly improved postoperatively, and there was no significant difference between the postoperative values and the values at the last follow-up. Early functional rehabilitation of the injured wrist under the protection of the fixator did not result in displacement of the transferred graft.

CONCLUSIONS: The results of the present investigation support the use of the vascularized bone graft pedicled on 1,2 ICSRA in the treatment of scaphoid nonunion complicated with proximal pole AVN. Procedures of wrist arthrolysis and early institution of wrist functional rehabilitation under the protection of the external fixator play important role in the restoration of range of motion of the injured wrist.

Key Words:

Scaphoid nonunion, Avascular necrosis, Vascularized bone grafts, Wrist external fixator.

Introduction

The scaphoid is the most commonly fractured carpal bone. Poor reduction or inadequate stabilization may lead to nonunion or avascular necrosis (AVN) of the proximal fragment¹⁻⁴. The conventional Russe bone grafting procedure could achieve satisfactory result in the treatment of normal scaphoid nonunion without proximal pole AVN^{3,4}. The application of interpositional wedge grafting or Maltese cross bone grafting has been suggested in the situation of humpback deformity⁵. However, when scaphoid nonunion complicated with proximal pole AVN, the application of vascularized bone grafting is strongly recommended⁶⁻⁸. Vascular bone-grafting pedicled on the 1,2 intercompartmental supraretinacular artery (1,2 ICSRA) has been employed to treat recalcitrant scaphoid nonunion associated with proximal pole AVN and achieved satisfactory union rate⁹⁻¹². However, the previous studies focused mostly on the union rate and the revascularization of the proximal pole, and did not ade-

quately handle the problem of wrist stiffness which often associated with scaphoid nonunion⁹⁻¹². Moreover, in most of the previous reports, the wrist had to be immobilized for 6-20 weeks in plaster after the vascularized bone-grafting procedure⁹⁻¹². The long periods of postoperative immobilization in plaster inhibited functional rehabilitation of the injured wrist and had an adverse effect on the restoration of wrist range of motion (ROM) postoperatively¹³.

Wrist external fixator has been used in the treatment of distal radius fractures and complex carpal fracture-dislocations^{13,14}. One of the advantages of the application of external fixator is that early functional rehabilitation of the wrist could be instituted. The early functional rehabilitation of the injured wrist under the protection of the external fixator could result in significant improvement in the restoration of wrist ROM^{14,15}. The purpose of our study was to determine whether the combination of vascularized bone-grafting pedicled on 1,2 ICSRA and wrist external fixator immobilization could provide a more effective strategy for treating established scaphoid nonunion and improving postoperative wrist ROM, to assess the risk of the early wrist mobilization under the protection of wrist external fixator, and to provide an alternative method of postoperative immobilization after internal fixation of the scaphoid nonunion.

Patients and Methods

From September 2001 to January 2006, 28 established scaphoid nonunion with or without proximal pole AVN were treated in our Hospital. Initially all patients had evidence of scaphoid nonunion on radiographic studies, but for the diagnosis of proximal pole AVN and included in this study (11 patients, 7 manual labour workers and 4 office workers), absence of punctuate bleeding within the proximal pole had to be confirmed intraoperatively¹⁶. For these 11 cases, procedures of vascularized bone-grafting pedicled on 1,2 ICSRA, internal fixation and wrist external fixator immobilization were performed by one surgeon. There were 10 men and 1 woman, and the average age was 28 years (range, 21 to 38 years). One patient had chronic transscaphoid perilunate fracture dislocation (case 1), 10 had displaced scaphoid nonunion. The intervals between the initial injury and the vascularized bone-grafting were more than 8 months (average,

2.4 years). No systematic inflammatory disease or idiopathic avascular necrosis was detected in this group of patients. The cause of injury included a motor vehicle accident in 9 patients and a sport injury in 2 patients, and the mechanism of injury mostly was a fall on an outstretched hand.

Preoperative Evaluation

The Mayo wrist scoring system was used for preoperative clinical evaluation¹⁷. Visual analogue was used for pain evaluation. Wrist motion in terms of flexion, extension, radial and ulnar deviation was carefully documented. Radiographic examination of both wrists was performed (posteroanterior, lateral, and scaphoid axial views) (Figure 1, A).

Surgical Procedure

With the patient lying in the supine position, general anesthesia was administered. The upper extremity of the operative side was elevated before inflating the tourniquet. The 1,2 ICSRA was identified under 5 × loupe magnification. A curvilinear dorsoradial incision centered on the first and second dorsal compartments was used. The 1,2 ICSRA was visualized on the surface of the extensor retinaculum once the subcutaneous tissues were gently raised. The artery and venae comitantes were dissected gently toward their distal anastomosis and an interval was developed between the first and second dorsal compartments. Before the graft was raised, the scaphoid nonunion site was prepared. Low-speed power bur and small curettes were used to refresh the scaphoid nonunion site. After preparation of the nonunion site, manipulation of the distal radioulnar joint was performed to improve wrist pronation/supination. Then, radiocarpal and midcarpal joint space was exposed. The scar tissues, loose bodies inside the joint spaces were removed. This procedure was frequently sufficient to improve wrist ROM. When needed, the volar or dorsal radiocarpal ligaments could be partially resected from the border of the radius to improve wrist ROM. However, it was very important to remember that the volar and dorsal ulnar ligaments should not be damaged. A trough snapping the nonunion for the vascularized bone graft inlay was prepared. The graft containing the vessels and the cuff of the retinaculum was elevated about 1.5 cm proximal to the radiocarpal joint. The tourniquet was deflated to detect the punctuate bleeding of the proximal pole and assess the vascularity of the bone graft. The absence of punctuate bleeding confirmed the diagnosis of AVN.

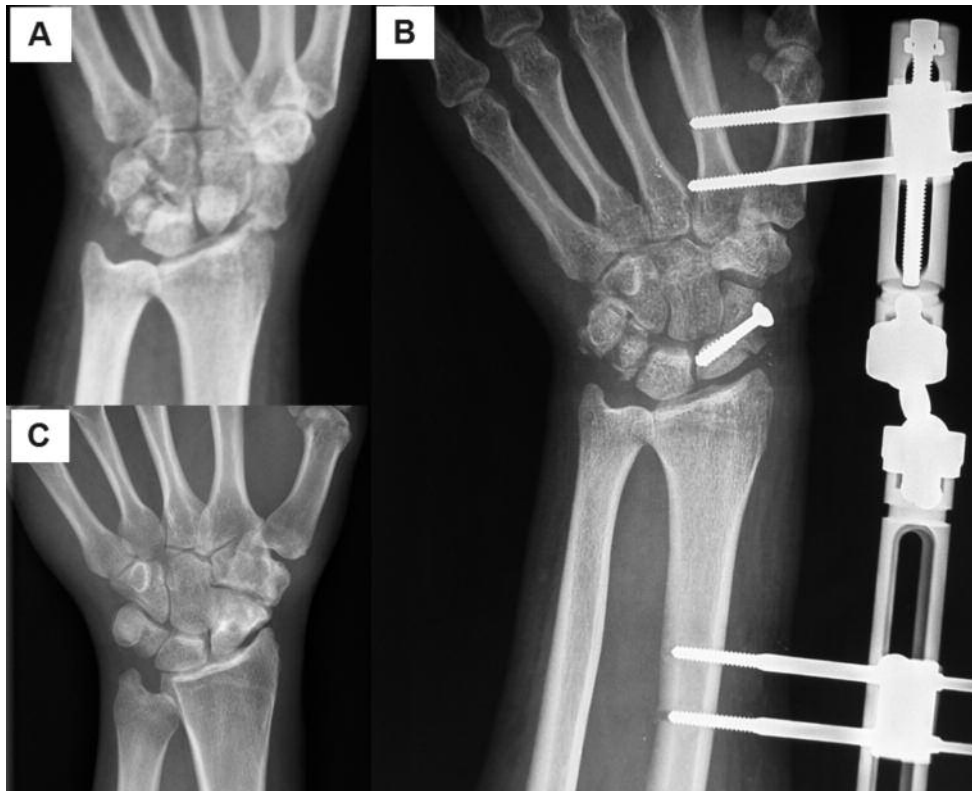


Figure 1. A 24 year-old male patient with scaphoid nonunion (case 2). The interval between injury and operation was 12 months and proximal pole AVN was confirmed intraoperatively. Posteroanterior radiograph showed a wide gap between fracture fragments (**A**). After the reduction of the nonunion and the transfer of the vascularized bone graft based on 1,2- ICSRA, a cannulated screw was used to stabilize the nonunion, then the wrist external fixator was applied to immobilize the injured wrist. Radiograph taken in the fourth postoperative week revealed no loss of reduction (**B**). At the last follow-up (3.6 years postoperatively), the graft was fully united with both the distal and proximal segments of the scaphoid (**C**).

After re-inflation of the tourniquet, the graft was transposed to reach the nonunion site where it was gently impacted into position and placed as a dorsal inlay. The remaining gaps in the scaphoid nonunion site were filled flush with cancellous bone chips from the same distal radius site. Depending on the size of the proximal fragment, One screw (Herbert screw or cannulated screw) or two smooth K-wires were used to stabilize the nonunion. Screw was used if the proximal pole was large enough. If the proximal pole was too small to be stabilized by screw, K-wires were employed.

After completing the grafting and internal fixation, the wrist external fixator (Pennig wrist fixator, Orthofix Srl, Italy) was applied in a slightly distraction mode with the wrist in the functional position (Figure 1, B). After the distraction, the radiocarpal joint space should be increased to about 1 mm. This simple unilateral dorsoradial frame fixator was inserted into the distal radius and the second metacarpal. The proximal ball

joint of the external fixator was adjusted to the radiocarpal joint space and the distal ball joint was set to the so-called centre of rotation of the wrist joint (between capitate and lunate). At the end of surgery, wrist manipulation was performed to evaluate its ROM.

Postoperative Regimen and Evaluation

The external fixator was continued for 8-15 weeks depending on the evidence of radiological union determined by the bridging trabeculae. The fixator was changed to being applied in neutralizing mode after being applied in slightly distraction mode in the first 3 weeks. Rehabilitation was instituted in the third postoperative day. A pain-reducing pharmaceutical was frequently required for the postoperative pain control. Active and passive flexion-extension, radial-ulnar deviation and pronation-supination range of motion exercises were instituted since the third postoperative day, gradually increasing the number of repetitions. The range of motion was began with 30°

dorsiflexion, 30° palmar flexion, 10° radial deviation, and 15° ulnar deviation and the motion range was gradually increased. Strengthening was not added to the regimen until evidence of radiological union obtained. Strenuous manual labor and sports activities were not permitted until 6 months after the surgery.

Patients were asked to return every 4 weeks and repeated radiographs (included posteroanterior, lateral, and scaphoid axial views) were obtained. Union was considered to be present when no gap was seen at the site of the former nonunion and bridging trabeculae were seen on all radiographs (Figure 1, C). The severity of humpback deformity and intracarpal instability was assessed based on intrascaphoid (IS) angle and scapholunate (SL) angle, respectively. Both of preoperative and postoperative radiographic measurements were comparatively studied.

The Mayo wrist scoring system was used to evaluate the functional outcome (Table I). Pain rating, active range of motion of the wrist, grip strength (measured on the hand dynamometer), and work status were measured. Range of motion was reported as the absolute measurement (Figure 2, A and B). Maximal grip strength on the operative side was measured and was reported as a percentage of maximal strength on the contralateral side. Each item was scored on a 25-point scale, with a total possible score of 100 points, where 90 to 100 points was defined as an excellent result, 80 to 89 points as a good result, 65 to 79 points as a fair result, and score less than 65 points as a poor result.

Statistical Analysis

The results were presented by mean, range, and SD values. Paired t test was used to compared the preoperative and postoperative values (SPSS version 17.0; SPSS Inc., Chicago, IL, USA). The level of significance was set at $p < 0.05$.

Results

The average follow-up was 5.3 (range, 3.5 to 9.1) years. The union time averaged 11.4 (range, 10 to 15) weeks. Mean IS angle was 35.6 (range, 27 to 48) degrees preoperatively and 24.5 (range, 21 to 28) degrees postoperatively (Table II). The mean IS angle of radiographs taken at the final follow-up examination was 25.4 (range, 22 to 29) degrees. The correction of angulation represented the restoration of scaphoid alignment and averaged 11.1 (range, 3 to 14) degrees. No significant loss of reduction was noted at the latest follow-up examination (paired t test, $p = 0.30$). Mean SL angle was 62.6 (range, 55 to 70) degrees preoperatively and 50.2 (range, 45 to 58) degrees postoperatively. Correction of angulation averaged 12.4 (range, 3 to 21) degrees. The mean SL angle of radiographs taken at the final follow-up examination was 51.5 (range, 47 to 56) degrees. There was no statistically significant loss of reduction noted at the final follow-up examinations (paired t test, $p = 0.23$).

According to the Mayo wrist scoring system, there were three excellent, six good, and two fair results at the last follow-up. The average score increased significantly from 50 preoperatively to 85 at the final follow-up ($p < 0.01$). Residual

Table I. The Data of the 11 patients with scaphoid nonunion complicated with AVN.

Case No	Age	Sex	Intervals between injury and operation (months)	Union time (weeks)	Last follow-up (years)	Mayo score (preo/posto)	Outcome*
1	23	M	14	10	3.6	50/85	Good
2	27	M	12	9	4.2	60/90	Excellent
3	32	M	8	12	4.1	45/85	Good
4	38	M	26	11	5.3	50/70	Fair
5	42	F	32	16	6.5	35/70	Fair
6	21	M	44	10	7.4	45/85	Good
7	29	M	8	9	9.1	50/80	Good
8	34	M	38	11	3.5	55/85	Good
9	36	M	22	13	6.6	45/85	Good
10	24	M	11	8	3.8	50/95	Excellent
11	26	M	18	10	4.5	60/95	Excellent

*Excellent, ≥ 90 points; Good, ≥ 80 points; Fair ≥ 65 points; Poor < 65 points.

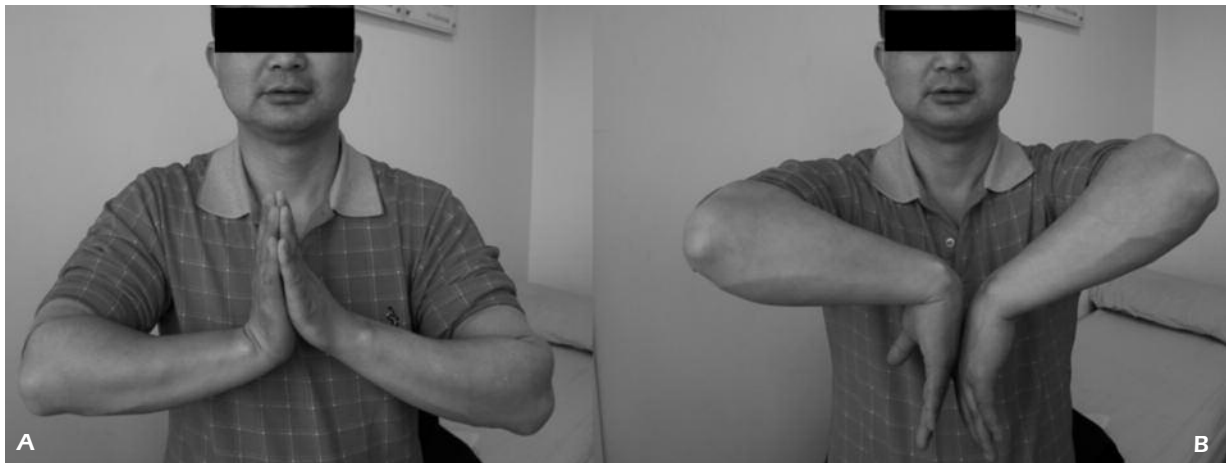

Figure 2. At the last follow up (case 2), the range of motion of the injured wrist was satisfactory (A, B).

pain was the most common cause of less satisfactory outcome. The flexion-extension arc at last follow-up was 129.8 ± 27.0 degrees which was significantly better than the preoperative value (87.8 ± 15.7 degrees) ($p < 0.01$) (Table III). The postoperative radial-ular deviation arc also improved significantly (54.7 ± 6.9 degrees, 34.4 ± 6.2 degrees, respectively) ($p < 0.01$). Grip strength was 90% of that of the normal hand at last follow-up and was better than the preoperative value (60%) ($p < 0.01$).

Discussion

The treatment of scaphoid nonunion complicated with AVN of the proximal pole remains a

formidable challenge for hand surgeon as conventional bone grafting has a high failure rate [6,8]. In the situation of proximal pole AVN as confirmed by the absence of punctuate bleeding within the proximal pole at surgery, Green¹⁸ reported that all the five cases failed to unite, and Shah et al¹⁹ observed that only five of the 15 cases united. The treatment alternative that has been reported to improve the chances of achieving union is the application of vascularized bone grafts⁹⁻¹². A systematic review reported in 2002 evaluated 64 patients with scaphoid nonunions associated proximal pole AVN in 7 studies reported that an 88% union rate was achieved when vascularized bone graft with internal fixation was applied and the union rate was 47% if the nonunion was treated with conventional bone

Table II. Summary of radiographic studies.

Case No.	Preoperative		Postoperative		Last follow-up	
	SL* angle	IS* angle	SL angle	IS angle	SL angle	IS angle
1	65	38	52	24	50	25
2	62	42	45	28	47	29
3	55	33	52	24	53	22
4	70	36	58	26	55	28
5	66	32	52	21	56	22
6	56	40	48	23	52	25
7	64	48	50	31	51	28
8	63	28	45	22	48	28
9	68	27	47	24	52	22
10	58	32	55	23	50	24
11	62	36	48	24	52	26

SL*: scapholunate. IS*: intrascaphoid.

Table III. Measurement of range of motion and grip strength.

Case No	Range of motion (pre/postop*, degrees)				Grip strength* (pre/postop*)
	Volar flexion	Dorsi flexion	Radial deviation	Ulnar deviation	
1	33/62	42/77	7/18	21/32	62/87
2	44/76	53/81	9/22	26/37	71/98
3	41/62	48/72	14/18	23/33	54/92
4	32/47	41/58	8/15	22/36	65/87
5	27/31	42/61	9/14	19/39	53/79
6	32/55	41/63	11/15	17/29	57/92
7	52/62	63/81	16/21	25/42	52/84
8	37/64	57/86	6/17	20/38	48/83
9	32/44	43/51	11/15	21/33	67/88
10	44/70	56/83	17/22	25/40	63/101
11	45/70	61/92	19/25	22/41	64/103

*Pre/postop: preoperative/postoperative; *Grip strength is expressed as the percentage of the contralateral side.

graft and internal fixation²⁰. Another systematic review of the literature from 1928 to 2003 reported that vascularized bone-grafting techniques with or without internal fixation achieved 91% union rate in the treatment of scaphoid nonunion complicated with proximal pole AVN²¹. Studies have confirmed that vascularized bone graft remains viable after being transferred to the recipient site²²⁻²⁴. It unites with the recipient bone directly without necessity of revascularization or replacement by creeping substitution. It also aid in the revascularization of the avascular bone segment by providing vascular osteogenic tissue which sprouts new outgrowths to revascularize avascular recipient bone tissue. In several studies, vascularized bone graft pedicled on 1,2 ICSRA achieved satisfactory union rate in the treatment of scaphoid nonunion complicated with proximal pole AVN⁹⁻¹². This technique is technically straightforward and facilitates treatment through one incision. In this study, the union rate was 100% which was consisted with previous studies⁹⁻¹².

However, the previous reported studies focused on the union rate and seldom discussed the problem of the associated wrist stiffness which could adversely affect the functional outcome. Several studies reported that, there was no improvement in the range of motion in the injured wrist^{9,11,12}. In this study, the postoperative flexion-extension arc improved significantly when compared with that of the preoperative values (87.8±15.7 degrees and 129.8±27.0 degrees, respectively, $p < 0.01$). The results indicated that effective wrist arthrolysis and early institution of

wrist functional rehabilitation under the protection of the external fixator played important role in the restoration of wrist ROM in this study. Moreover, with the fixator in slightly distracted mode, the reformation of fibrous tissue and the contraction of the wrist capsule were limited and, therefore, prevented the development of postoperative wrist stiffness. At surgery, before bone grafting and internal fixation, the stiff wrist was released until satisfactory wrist ROM achieved. Any fibrous tissues in the nonunion, the mid-carpal joints, and the radiocarpal joint were thoroughly removed and the dorsal contracted soft tissue was carefully released. It is necessary to point out that the pedicle of the graft and the dorsal intercarpal arc which provide anatomic connections for the 1,2 ICSRA⁸ should be carefully protected. In order to protect the delicate nutrient vessels of the graft, we performed the arthrolysis procedures after the vascular bone graft had been raised. Therefore, the risks of damaging the nutrient vessels of the graft when performing the arthrolysis procedures were greatly reduced.

The functional rehabilitation of the wrist including flexion and extension, radial and ulnar deviation was instituted in the third postoperative day. One point to consider is that whether the early institution of functional rehabilitation of the wrist could result in the lost of reduction of the nonunion and the displacement of the graft. In this study, however, the wrist was stabilized by the wrist external fixator in slightly distracted mode in the first three postoperative weeks. The radiocarpal joint space was increased to about 1 mm, and that the proximal ball joint of the exter-

nal fixator was adjusted to the radiocarpal joint space and the distal ball joint was set to the rotation centre of the wrist joint. Therefore, under the protection of the fixator, range motion of the injured wrist could be strictly restricted in the radiocarpal joint with little force exerting on the nonunion and the graft. Moreover, with fixator in slightly distracted mode, the collapse of the scaphoid nonunion was prevented when gripping the hand. In the present study, there was no significance difference between the postoperative and the last follow-up SL angle and RL angle (SL angle: 24.5 and 25.4 degrees, $p = 0.30$; RL angle: 50.2 and 51.5 degrees, $p = 0.23$). The results indicated that, under the protection of the external fixator, there was no significant loss of reduction of the nonunion during the early functional rehabilitation of the injured wrist. The union time averaged 11.4 weeks which was consistent with the results reported by previous studies and postoperative radiographs showed no displacement of the grafts. The results indicated that, early institution of wrist functional rehabilitation under the protection of the external fixator did not result in graft displacement and union failure in the present study.

In the present study, there were 82% percent of patients achieving excellent or good outcome. This finding was comparable to previous investigations⁹⁻¹². All patients returned to their previous level of activities and work status (7 manual labour and 4 desk jobs). Pain was significantly relieved and grip strength was satisfactorily restored postoperatively. Grip strength compared with the contralateral side was improved from 60% preoperatively to 90% postoperatively. The range of improvement was similar to those reported by Thanapong et al¹¹ and greater than those reported by Boyer et al²⁵ and Uerpaiojkit et al²⁶.

We know that the number of selected patients included in the series is relatively small and that magnetic resonance (MR) imaging was not used in the diagnoses of proximal pole AVN preoperatively. The criteria of patient selection in the present study was the absence of punctuate bleeding within the proximal pole. Patients without the confirmation of intraoperative finding were excluded from this study. Moreover, this study did not compare the vascularized bone-grafting procedure with the established conventional bone grafting techniques in the treatment of scaphoid nonunion complicated with proximal pole AVN. Some previous studies reported that the vascularized bone-grafting procedure

could improve union rate⁹⁻¹². This study, however, focus not only on the union rate, but also on exploring methods to restore the range of motion of the injured wrist.

Conclusions

The results of the present investigation support the use of the vascularized bone graft pedicled on 1,2 ICSRA in the treatment of scaphoid nonunion complicated with proximal pole AVN. Effective wrist arthrolysis and early institution of wrist functional rehabilitation under the protection of the external fixator play important role in the restoration of wrist ROM. The pedicle of the graft and the dorsal intercarpal arc which provide anastomic connections for the 1,2 ICSRA should be carefully protected during arthrolysis procedures. Under the protection of the external fixator, early institution of functional rehabilitation of the wrist does not result in loss reduction of the nonunion and displacement of the graft.

Conflict of Interest

None to declare.

References

- 1) COONEY WP, LINSCHIED RL, DOBYNS JH. Scaphoid fractures. Problems associated with nonunion and avascular necrosis. *Orthop Clin N Am* 1984; 15: 381-391.
- 2) COONEY WP, LINSCHIED RL, DOBYNS JH, WOOD MB. Scaphoid nonunion: role of anterior interpositional bone grafts. *J Hand Surg Am* 1988; 13: 635-650.
- 3) RUSSE O. Fracture of the carpal navicular: diagnosis, nonoperative nonoperative treatment, and operative treatment. *J Bone Joint Surg Am* 1960; 42: 759-768.
- 4) STARK A, BROSTROM LA, SVARTENGREN G. Scaphoid nonunion treated with the Matti-Russe technique. Longterm results. *Clin Orthop* 1987; 214: 175-180.
- 5) SMITH BS, COONEY WP. Revision of failed bone grafting for nonunion of the scaphoid. Treatment options and results. *Clin Orthop* 1996; 327: 98-109.
- 6) VICTORIA SP, JAMES C. Scaphoid nonunion: Diagnosis and treatment. *Plast Reconstr Surg* 2003; 112: 1666-1676.
- 7) POKORNY JJ, DAVIDS H, MONEIM MS. Vascularized bone graft for scaphoid nonunion. *Techn Hand Up Extrem Surg* 2003; 7: 32-36.

- 8) SHIN AY, BISHOP AT. Pedicled vascularized bone grafts for disorders of the carpus: scaphoid nonunion and Kienböck's disease. *J Am Acad Orthop Surg* 2002; 10: 210-216.
- 9) STEINMANN SP, BISHOP AT, BERGER RA. Use of the 1,2 intercompartmental suprarotational artery as a vascularized pedicle bone graft for difficult scaphoid nonunion. *J Hand Surg* 2002; 27: 391-401.
- 10) CHEN AC, CHAO EK, TU YK, UENG SW. Scaphoid nonunion treated with vascular bone grafts pedicled on the dorsal supra-retinacular artery of the distal radius. *J Trauma*. 2006; 61: 1192-1197.
- 11) WAITAYAWINYU T, MCCALLISTER WV, KATOLIK LJ, SCHLENKER JD, TRUMBLE TE. Outcome after vascularized bone grafting of scaphoid nonunions with avascular necrosis. *J Hand Surg* 2009; 34: 387-394.
- 12) MALIZOS KN, ZACHOS V, DAILIANA ZH, ZALAVRAS C, VARITIMIDIS S, HANTES M, KARANTANAS A. Scaphoid Nonunions: Management with vascularized bone grafts from the distal radius: A clinical and functional outcome study. *Plast Reconstr Surg* 2007; 119: 1513-1525.
- 13) INOUE G, IMAEDA T. Management of trans-scaphoid perilunate dislocations. *Arch Orthop Trauma Surg* 1997; 116: 338-340.
- 14) FERNANDEZ DL, MADER K. The treatment of complex carpal dislocations by external fixation. *Injury* 2000; 31: 92-101.
- 15) MURRAY PM, TRIGG SD. Treatment of distal radius fractures with external fixation: Technical considerations for rehabilitation. *Techn Hand Up Extrem Surg* 2002; 6: 213-218.
- 16) SAKUMA M, NAKAMURA R, IMAEDA T. Analysis of proximal fragment sclerosis and surgical outcome of scaphoid nonunion by magnetic resonance imaging. *J Hand Surg Br* 1995; 20: 201-205.
- 17) HERZBERG G, COMTET JJ, LINSCHIED RL, AMADIO PC, COONEY WP, STALDER J. Perilunate dislocations and fracture-dislocations: A multicenter study. *J Hand Surg Am* 1993; 18: 768-779.
- 18) GREEN DP. The effect of avascular necrosis on Russe bone grafting for scaphoid nonunion. *J Hand Surg Am* 1985; 10: 597-605.
- 19) SHAH J, JONES WA. Factors affecting the outcome in 50 cases of scaphoid nonunion treated with Herbert screw fixation. *J Hand Surg* 1998; 23: 680-685.
- 20) MERRELL GA, WOLFE SW, SLADE JF 3RD. Treatment of scaphoid nonunions: quantitative meta-analysis of the literature. *J Hand Surg* 2002; 27: 685-691.
- 21) MUNK B, LARSEN CF. Bone grafting the scaphoid nonunion: a systematic review of 147 publications including 5,246 cases of scaphoid nonunion. *Acta Orthop Scand* 2004; 75: 618-629.
- 22) SUNAGAWA T, BISHOP AT, MURAMATSU K. Role of Conventional and vascularized bone grafts in scaphoid nonunion with avascular necrosis: A canine experimental study. *J Hand Surg Am* 2000; 25: 849-859.
- 23) ANDERSON SE, STEINBACH LS, TSCHERING-VOGEL D, MARTIN M, NAGY L. MR imaging of avascular scaphoid nonunion before and after vascularized bone grafting. *Skeletal Radiol* 2005; 34: 314-320.
- 24) DAILIANA ZH, ZACHOS V, VARITIMIDIS S, PAPANAGIOTOU P, KARANTANAS A, MALIZOS KN. Scaphoid nonunions treated with vascularised bone grafts: MRI assessment. *Eur J Radiol* 2004; 50: 217-224.
- 25) BOYER MI, VON SCHROEDER HP, AXELROD TS. Scaphoid nonunion with avascular necrosis of the proximal pole: treatment with a vascularized bone graft from the dorsum of the distal radius. *J Hand Surg* 1998; 23: 686-690.
- 26) UERPAIROJKIT C, LEECHAVENGVONGS S, WITOONCHART K. Primary vascularized distal radius bone graft for nonunion of the scaphoid. *J Hand Surg* 2000; 25: 266-270.