

# Minimally invasive management of hepatic cysts: indications and complications

D. VARDAKOSTAS<sup>1</sup>, C. DAMASKOS<sup>1,2</sup>, N. GARMPIIS<sup>1</sup>, E.A. ANTONIOU<sup>1</sup>,  
K. KONTZOGLIOU<sup>1</sup>, G. KOURAKLIS<sup>1</sup>, D. DIMITROULIS<sup>1</sup>

<sup>1</sup>Second Department of Propedeutic Surgery, Laiko General Hospital, Medical School, National and Kapodistrian University of Athens, Athens, Greece

<sup>2</sup>N.S. Christeas Laboratory of Experimental Surgery and Surgical Research, Medical School, National and Kapodistrian University of Athens, Athens, Greece

*Dimitrios Vardakostas and Christos Damaskos contributed equally to this study*

**Abstract. – OBJECTIVE:** Liver cysts are divided into congenital and acquired. Congenital cystic lesions include polycystic liver disease, simple cysts, duct related and ciliated hepatic foregut cysts. Acquired cystic lesions are divided into infectious and non-infectious. The infectious cysts are the hydatid cyst, the amoebic abscess, and the pyogenic abscess, whereas the non-infectious cysts are neoplastic cysts and false cysts. While modern medicine provides a lot of minimally invasive therapeutic modalities, there has emerged a pressing need for understanding the various types of liver cysts, the possible minimal therapeutic options along with their indications and complications. We aim is to clarify the role of minimally invasive techniques in the management of hepatic cysts.

**MATERIALS AND METHODS:** A literature review was performed using the MEDLINE database. The search terms were: liver cyst, minimally invasive, laparoscopic, percutaneous, drainage and fenestration. We reviewed 82 English language publications articles, published until October 2017.

**RESULTS:** Minimally invasive management of liver LC is an emerging field including many therapeutic modalities ranging from the percutaneous aspiration of pyogenic abscesses to laparoscopic hepatectomy for hepatic cystadenomas. The most used techniques are percutaneous drainage, laparoscopic fenestration, and laparoscopic hepatectomy.

**CONCLUSIONS:** The application of the various minimally invasive approaches, as well as their indication and complications, depend on the type of the cystic lesion, its size and its position in the liver. Percutaneous drainage is mostly used in simple cysts, hydatid cysts, pyogenic abscesses and bilomas. Laparoscopic fenestration is mostly used in simple cysts and polycystic liver disease. Finally, laparoscopic hepatectomy is mostly used in polycystic liver disease, hydatid cysts, and cystadenomas.

## Key Words:

Liver, Cyst, Minimally, Invasive, Laparoscopic, Percutaneous, Drainage, Fenestration.

## Introduction

Nowadays, technological advances, lower cost, and increasing medical experience have led to a widespread use of imaging modalities, especially of ultrasonography. Not only are they used for abdominal symptoms screening but also for preventive and follow up purposes. As a result, cystic lesions of the liver are diagnosed more frequently and inevitably, posing questions about their differential diagnosis and their appropriate management. Moreover, in the setting of modern medicine where minimally invasive techniques are evolving, the choice of the most effective management is much more in question. Liver cysts (LC) consist of a heterogeneous group of disorders differing in etiology, prevalence, management and clinical manifestations. Yet, a consensus has not been achieved on the definition and classification of hepatic cystic lesions, and considerable controversy exists concerning the best treatment.

Hepatic cystic lesions are divided into two main categories: congenital and acquired. Congenital cystic lesions of the liver include Polycystic Liver Disease (PCLD), simple cysts, duct related and ciliated hepatic foregut cysts. Acquired hepatic cysts are further divided into infectious and non-infectious. There are two kinds of infectious cysts, the parasitic ones (hydatid cysts and amoebic abscesses) and non-parasitic, in other words, pyogenic liver abscesses. The non-infectious group consists of neoplastic (primary and second-

dary) cysts and false cysts. Cystadenoma (CA) and cystadenocarcinoma (CAC) are classified into primary neoplastic cysts. The overall hepatic cystic lesion classification can be seen in Figure 1.

## Congenital Cysts

### Simple Hepatic Cysts

Ultrasound and computed tomography reveal LC in 2.5% to 5% of the population. Only 15% of these cysts are symptomatic when they are predominantly large (>4 cm). They are usually found in the right lobe and are more common in women and older patients (Figure 2). Asymptomatic simple cysts do not require any treatment or follow-up. Large cysts bigger than 4 cm are advised to be serially checked with imaging modalities and ensure stability. Enlarging cysts become symptomatic due to mass effect, infection, rupture or hemorrhage. In some occasions, there may be more than one cyst, called several solitary cysts. Symptomatic or enlarging cysts require excluding of other diagnoses, especially malignancies. Simple hepatic

cysts are treated minimally with laparoscopic unroofing or percutaneous sclerotherapy. Both of these treatments are demonstrated to be equally effective, although percutaneous therapy presents the lower occurrence of complications<sup>1</sup>.

Better results can be achieved with a wide excision of the cystic wall and use of argon beam coagulation<sup>2-6</sup>. Recurrence is estimated from 0% to 20% with morbidity in 0% to 25%<sup>2-5,7</sup>. Good candidates for laparoscopic fenestration are thought to be patients without previous open surgical intervention in the abdomen and have large, symptomatic, superficial, anteriorly seated cysts<sup>8</sup>. Wound infection, bile leak, chest infection, subphrenic hematoma and prolonged drainage have all been reported as post laparoscopic complications<sup>9</sup>.

In selected cases, before the laparoscopy, aspiration under US or CT guidance can be performed in order to assess whether symptoms are really referred to the cyst. Sclerosis is less invasive and associated with lower rates of complications, but first, it is crucial to exclude biliary communication to avoid irreversible sclerosing cholangitis<sup>10,11</sup>. On the other hand, laparoscopy is effective and provi-

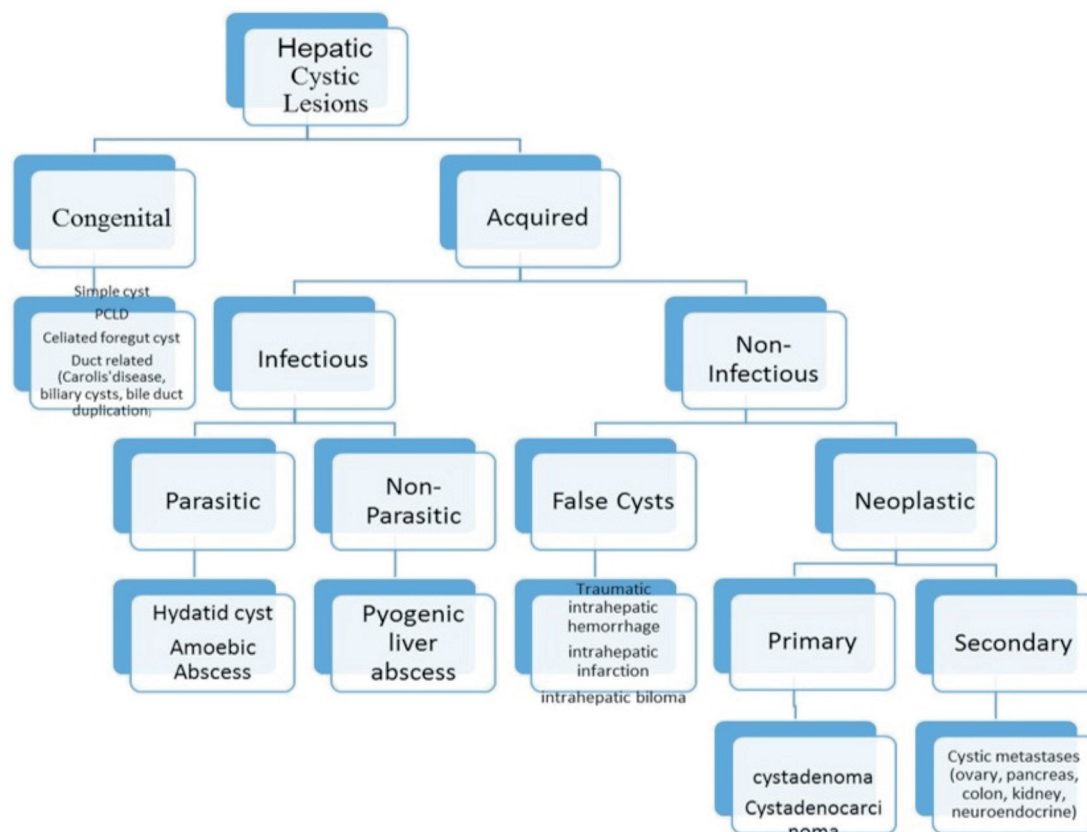
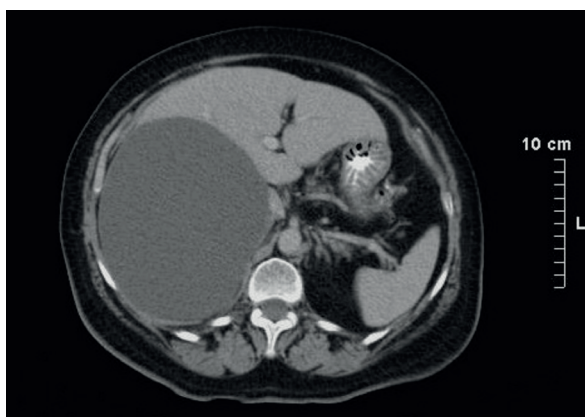


Figure 1. Categorization of hepatic cystic lesions.



**Figure 2.** Computed tomography (CT) describing a large simple hepatic cyst of a 64-year-old woman.

des the opportunity to directly examine the interior of the cyst, thus ruling out other etiologies<sup>1,12</sup>.

### **Polycystic Liver Disease**

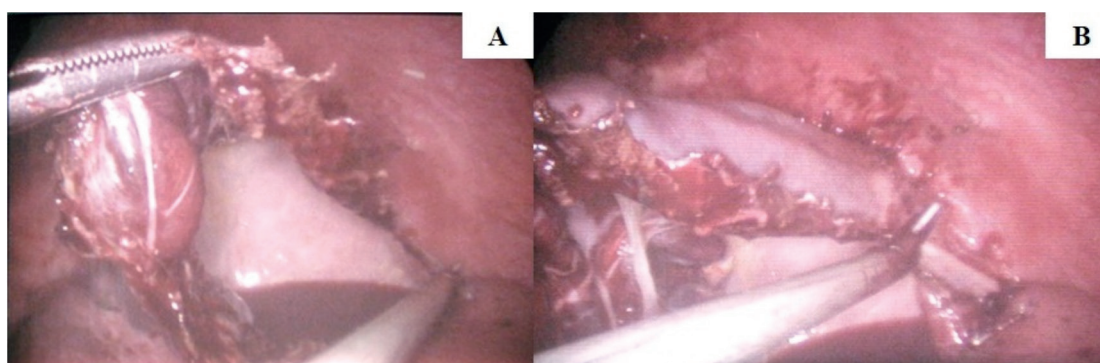
The polycystic liver disease is an inherited autosomal dominant disease. Most patients are asymptomatic. Symptomatic PCLD patients should be offered a tailored surgical therapy in relation with the extent of disease (laparoscopic or open fenestration, hepatic resection or orthotopic liver transplantation). Interventional therapy aims to reduce the volume of the polycystic liver offering a long-term relief of symptoms without compromising hepatic function. Gigot et al<sup>13</sup> have suggested a classification system for polycystic liver disease (Table I) based on pre-operative CT imaging offering a good platform to decide the appropriate therapy. Que et al<sup>14</sup> and Chen et al<sup>15</sup> reported the symptoms and complications that are the indications for interventional therapy.

These indications include early satiety, abdominal distention and pain, supine dyspnea, fatigue, infected cysts, bile duct obstruction, ascites, dialysis hypotension and uterine prolapse. Barahona-Garrido et al<sup>16</sup> support that occurrence of symptoms is not associated to the cyst diameter but to the number of cysts and the liver volume occupied by them. After studying liver function variables, they observed a significant correlation between elevated ALP (>132 mg/dL) and requirement of intervention.

Reports of laparoscopic fenestration of PCLD steadily increase in number demonstrating that when applied in the appropriate population, it has about the same mortality and morbidity as the open fenestration<sup>4,13,17-22</sup>. According to Morino et al<sup>19</sup>, polycystic livers, with a relatively limited number of large cysts seated in the anterior segments and in the left lobe, are ideal for laparoscopic fenestration. Occasions with difficulties in the adequate fenestration of all cysts, such as deeply seated cysts or cysts in segments VI, VII,

**Table I.** Gigot's classification for polycystic liver disease.

Type	Description
I	Presence of less than 10 large hepatic cysts measuring more than 10cm in maximum diameter
II	Diffuse involvement of liver parenchyma by multiple cysts with remaining large areas of non- cystic liver parenchyma
III	Presence of diffuse involvement of liver parenchyma by small and medium- sized liver cysts with only a few areas of normal liver parenchyma



**Figure 3.** The laparoscopic approach for managing a liver cyst. *A-B*, Laparoscopic pericystectomy for a 10 cm simple hepatic cyst of a 41-year-old woman.

and VIII, tend to have a higher recurrence rate after laparoscopic fenestration<sup>19,20,22</sup>. Koperna et al<sup>18</sup> concluded that laparoscopic fenestration could safely replace open fenestration given that in the appropriate PCLD patients it has similar rates of success along with similar overall recurrence (open vs. lap: 13% and 11%, respectively), similar morbidity and mortality rates. The most common morbidity was post-operative ascites. In other case series recurrence rates were reported from 0% to 71%<sup>16,17,20,23-25</sup> and morbidity from 0% to 54%<sup>17,25</sup>. Percutaneous aspiration and sclerosis of cysts is a wise option in high-risk patients with a large dominant cyst. However, it is associated with higher recurrence rates and probably does not provide definitive therapy<sup>26-29</sup>.

### Duct Related Cysts

Caroli disease is a rare disorder with multiple segmental intrahepatic cystic dilatations which communicate with the biliary tree. Recurrent cholangitis, intrahepatic lithiasis, and cholelithiasis are common clinical presentations. Peribiliary cysts are located along common bile duct or within portal tracts. They arise from cystic enlargement of peribiliary glands, and they are usually small and asymptomatic.

Ciliated hepatic foregut cysts come from the foregut since the embryonic period. For all these diseases, no minimally invasive therapy has been reported.

### Acquired Cysts

#### Infectious Cysts

##### Parasitic cysts

##### HYDATID CYSTS

**Laparoscopic approach.** The laparoscopic approach for managing Liver Hydatid Cysts (LHC) was first reported in 1992<sup>30</sup>. Since then, laparoscopy has been combined with different surgical techniques, such as partial cystectomy, cystectomy, marsupialization, puncture with evacuation and hepatectomy. Some of these techniques are thought to be radical and the rest conservative.

Radical treatment refers to pericystectomy and liver resection. Reduced occurrence of local or distal recurrence, no need of protoscolicidals postoperatively, better management of cystobiliary communications and cavity-related complications are the advantages of radical laparoscopic methods. Among these, total pericystectomy re-

mains the treatment of choice due to the fact that there is no hepatic tissue resection to compromise the liver function. Laparoscopic hepatectomy requires a highly experienced team, and cysts bigger than 5 cm are not technically suitable<sup>31</sup>. Moreover, increased morbidity and mortality are related with radical methods, and their use is questionable in a benign disease<sup>32,33</sup>.

Conservative techniques, including simple drainage and laparoscopic partial pericystectomy with evacuation, sterilization or omentoplasty, are suitable for almost every LHC<sup>34</sup>. These procedures are technically less demanding but require the use of drug therapy along with protoscolicidals.

The laparoscopic approach is indicated for all LHC except patients with deep intraparenchymal cysts, dense adhesions covering the cyst, inaccessible posterior cyst, more than three cysts, disease insulting other organs, calcified irremovable cyst, secondary hydatidosis and huge Gharbi III, IV, and V cysts (Table II)<sup>35,36</sup>. LHC located anteriorly bear the best indication for laparoscopic evacuation or radical excision, usually without complications.

Difficult location of the cyst and bleeding were the main reasons for converting laparoscopy to open surgery. Conversion percentages range from 0-66.66% (4.92% is the percentage of all conversions totally). The main cause of conversion to open was inaccessible locations/anatomical limitations (35.56% of conversions, 1.75% of all patients). Other reported causes included hemorrhage, adhesions, inappropriate cystic stage, inability to identify the cyst, inadequate evacuation, close proximity to the major vessels, risk of rupture, iatrogenic liver injury or hematoma. The complication rate is referred between 0 to 16%<sup>37-41</sup>. A recurrence rate of 3.6% was reported by Khoury et al<sup>38</sup> after performing marsupialization. Surgical complications include port-site infection, hernia, subphrenic abscess and small bowel perforation. General complications include fever of undetermined origin, subcutaneous hematoma, pneumonia, pleural effusion/empyema, atelectasis,

**Table II.** Classification by Gharbi et al for hydatid cysts.

Type	Description
I	Pure fluid collection (similar to simple liver cyst)
II	Fluid collection with a detached membrane
III	Fluid collection with multiple septa and/or daughter cysts
IV	Hyperechoic with internal echoes
V	Cyst with reflecting, calcified, thick wall

**Table III.** Minimal interventions.

Cyst	Possible minimal intervention
Simple cyst	Laparoscopic fenestration, percutaneous sclerotherapy
Polycystic Liver Disease	Laparoscopic fenestration, percutaneous sclerotherapy
Duct related cyst	No option
Hydatid cyst	Laparoscopic partial cystectomy, cystectomy, marsupialization, evacuation, hepatectomy, PAIR
Amebic abscess	US/CT guided aspiration
Non-parasitic Infectious cyst	Percutaneous needle aspiration, percutaneous catheter, laparoscopic drainage, ERCP guided drainage
False cyst	Percutaneous drainage
Cystadenoma	Laparoscopic liver resection
Cystadenocarcinoma	No option
Cystic metastases	No option

PAIR: percutaneous aspiration, injection, reaspiration; US: ultrasound; CT: computed tomography; ERCP: endoscopic retrograde cholangiopancreatography.

drug-induced fever. Complications happen more frequently after laparoscopic cystectomy compared to radical liver resections and pericystectomy.

The most troublesome complication is intrabiliary rupture<sup>42,43</sup>, and the reported occurrence of CBCs varies from 2.6% to 28.6%<sup>44,45</sup>. Most cases of postoperative bile leakage healed spontaneously, and the rest were further managed with endobiliary stenting and sphincterotomy<sup>46-49</sup>. When infection of residual cystic cavity or abscess was reported, it was mainly managed with percutaneous drainage and/or antibiotics and rarely with laparotomy<sup>38,50</sup>.

So far, perioperative mortality after laparoscopic treatment is almost 0%. Shorter hospital stay along with lower incidence of wound infection and less postoperative pain are the advantages of laparoscopic approach over open surgery. The disadvantages are limitations in accessing cysts in difficult locations, an increased risk of spillage into the peritoneal cavity with cyst content and difficulty in aspirating the viscous cystic contents<sup>51</sup>. Unfortunately, there is no randomized study to evaluate the laparoscopic treatment of LHC while most of the published studies are non-comparative. The most important studies concerning laparoscopy of LHC conclude that a laparoscopic approach is safe<sup>41</sup>, with proven low conversion rates and no mortality.

**Percutaneous aspiration, injection, re-aspiration.** Mueller et al<sup>52</sup> first described the minimally invasive method of percutaneous aspiration, injection, re-aspiration (PAIR). Candidates for this technique include patients with hypoechoic, not calcified and with no biliary communication hepa-

tic cysts in order to avoid sclerosing cholangitis and anaphylaxis<sup>53</sup>. Percutaneous treatment is indicated for cysts type I and II, some groups of type III with drainable solid content, subtypes of type IV (Table II), suspected fluid collections and infected hydatid cysts. Percutaneous treatment should also be suggested to patients at high surgical risk, pregnant patients, and patients with multiple or disseminated cysts. The World Health Organization Informal Working Group on Echinococcosis reported a large multicenter study demonstrating that the method is very effective. 765 patients were primarily submitted for PAIR with a complication rate of 14.7% while the recurrence rate was 1.57% (54). The perioperative mortality varies from 0% to 0.9%<sup>53,55</sup>. Two non-comparative prospective studies<sup>56,57</sup> of 34 and 87 patients percutaneously drained showed that the treatment is safe and effective and that can be used in occasions with contraindications to surgery and for types I-III, according to Gharbi et al<sup>58</sup>. PAIR is a promising treatment but more sufficient evidence derived from well-designed clinical trials are needed to support its use as a standard procedure for uncomplicated cysts<sup>59</sup>.

#### AMEBIC ABSCESS

An amebic liver abscess is the most common extraintestinal manifestation of amebiasis, an infection caused by the protozoan *Entamoeba histolytica*. In developed countries, it is presented mainly on travelers returning from an endemic area who complaint for upper quadrant pain, abdominal symptoms, and fever. Basically, amebic liver abscess is managed with antibiotics, a tissue

agent, and a luminal agent. US or CT guided aspiration is not routinely required but it can be used at high risk of rupture (particularly in the left lobe), in cases with no response to empiric therapy and for therapeutic or diagnostic purposes<sup>60</sup>.

#### *Non Parasitic Infectious Cysts*

A pyogenic liver abscess is a potentially lethal disease. The main therapy is the intravenous administration of antimicrobial drugs. When the disease resists a four-weeks treatment or the abscess is bigger than 5cm, then a kind of drainage is required. Drainage can be done via percutaneous needle aspiration, percutaneous catheter, open or laparoscopic approach.

Percutaneous needle aspiration allows smaller and multiple lesions to be sampled for culture and avoids the catheter placement under circumstances with difficulties. Percutaneous Catheter Drainage (PCD) offers controlled drainage of large abscesses over a period of time with minimal hemodynamic and physiological stress to the patient. It has been established as the first line drainage modality due to being safe, tolerable, and successful. In addition, there is less morbidity and have comparable results (mortality rates) with surgical drainage<sup>61-65</sup>. Reported complications include inadvertent injuries of intraabdominal organs and surrounding vascular structures, intraperitoneal bleeding, hepatovenous fistula, and needle tract infection<sup>66</sup>. Unfortunately, the failure of PCD can lead to uncontrolled sepsis. Size and multiloculation seem to be predictors for failure of PCD. In such cases and those associated with concomitant biliary pathology, laparoscopic drainage may be useful, not to mention that offers the advantages of minimal stress. Reported complications were associated with general anesthesia (myocardial infarctions) and bile leakage<sup>67</sup>.

An alternative technique, endoscopic retrograde cholangiopancreatography-guided drainage of hepatic abscesses has been proposed by Dull et al<sup>68</sup>. The method is technically challenging and only suitable where there is possible communication of the abscess with the biliary tree. Failure of antibiotic therapy or PCD approach and transluminal accessibility are indications for the method. The left lobe of liver (segments II and III) and the caudate lobe usually lie in close proximity to the stomach or duodenum. No procedure-related complications or failure have been reported, probably due to the fact that when a new procedure is attempted, only technically and clinically successful cases are published.

#### *Non-Infectious Cysts*

##### *False Cysts*

False cysts (traumatic intrahepatic hemorrhage, intrahepatic infarction, intrahepatic biloma) are benign lesions without epithelium. Liver infarction is a rare complication because of its double blood perfusion by the hepatic artery and the portal vein. There is no a widely accepted therapeutic strategy of hepatic infarction. Since hepatic infarction becomes infected, percutaneous or surgical drainage is considered necessary<sup>69</sup>. Stewart et al<sup>70</sup> reported that 11 of 12 patients (92%) with infected hepatic infarctions responded well to percutaneous drainage and survived.

Bile, blood or pus may rupture into or extend to the hepatic subcapsular space. The prevalence of subcapsular collections increases not only due to blunt liver traumas, but also to the increasing use of invasive diagnostic or therapeutic techniques. Such of them are endoscopic retrograde cholangiopancreatography (ERCP), hepatic artery infusion of chemotherapy, microwave coagulation, and high-frequency radioablation of hepatic tumors. Nonsurgical care in stable patients with a limited subcapsular fluid collection is the first option. Invasive measures are indicated in case of fluid expansion or uncontrolled infection<sup>71</sup>. For bilomas, percutaneous drainage is the treatment of choice.

Injury to the biliary tract with biloma formation is unusual in blunt abdominal trauma. Deep parenchymal lacerations resulting in intrahepatic bile duct injury and biloma formation can be dealt with CT-guided percutaneous drainage following hepatorrhaphy. Provided that there is no extrahepatic bile duct obstruction, bile leakage stops spontaneously without further surgery<sup>72</sup>. Alternatively, in a few reported cases<sup>73,74</sup>, patients with blunt abdominal trauma and bile duct injuries underwent endobiliary stenting.

Finally, cases reporting hemorrhage within a hepatic cyst have been published<sup>75</sup>. The therapeutic options, except simple observation, include percutaneous transhepatic drainage (with or without sclerosing agent), open/laparoscopic unroofing (marsupialization), cyst enucleation, and hepatic resection. Laparoscopic unroofing is getting more widely accepted as it provides a tissue sample for biopsy, relief of symptoms, minimal morbidity, a short hospital stay and low recurrence rates<sup>76</sup>.

Certainly, there is need for further clinical studies so as indications and complications of invasive treatments to be established.

## **Neoplastic Cysts**

### *Primary Cysts: Cystadenoma and Cystadenocarcinoma*

Despite the progress in imaging technology and increasing recognition of biliary CA and CAC, preoperative diagnosis is doubtful. Cystic neoplasms are estimated to be about 5% of cystic liver lesions and 5% of them are malignant. The overall incidence of malignant hepatic tumors is lower than 0.41%<sup>77,78</sup>. The histogenesis of CA remains undefined but either a congenital origin or a reactive process to some focal injury is assumed.

Pathological characteristics of CA include stratified or pseudo stratified non-ciliated columnar or cuboidal epithelium with mucous-producing cells, papillary infolding, hypercellular mesenchyme and often ovarian like cells. The pre-malignant progression of CA is characterized histologically by the presence of intestinal metaplasia and numerous goblet cells. CAC can be recognized when epithelial nuclear stratification is lost, and a tubulo-papillary architecture, nuclear pleomorphism, and atypia prevail. Invasion of the stroma confirms the diagnosis of CAC.

Most of the CA remain silent and are discovered incidentally or they appear causing tumor compression abdominal symptoms<sup>77</sup>. The rate of malignant transformation is low (5%-10%), nevertheless all suspected CA must be excised and a liver resection with clear margins, open or laparoscopically, protects from the possibility of synchronous presence of CAC at the borders of the cyst<sup>79,80</sup>. Veroux et al<sup>81</sup> reported occasions of incidental finding of biliary CA after laparoscopic fenestration of a cystic hepatic lesion. They stated that when a complete laparoscopic enucleation of the cyst may be ensured, a strict clinical, biochemical, and imaging follow-up evaluation should be considered as the definitive treatment.

In the era of less invasive surgery, a laparoscopic biopsy of the cyst wall is feasible but frozen sections cannot surely exclude or confirm the diagnosis of CA, especially of CAC. The current treatment modality is open or laparoscopic liver resection due to the risk of malignancy in all suspected CA<sup>78,82</sup>. In hepatic CAC there is no place for laparoscopic methods, with formal hepatic resection being the only suggested therapy.

### *Secondary Cysts: Cystic Metastases*

Many kinds of malignant tumors may metastasize to the liver. The list is long including tumors from ovaries, pancreas, colon, kidneys, Gastroin-

testinal Stromal Tumor (GIST), etc. Metastatic lesions from sarcomas, melanomas or neuroendocrine tumors are rapidly growing hypervascular tumors and appear cystic because of necrosis and degeneration. There is no place for minimally invasive methods in such cases.

## **Discussion**

As we have mentioned before, LC is divided into congenital and acquired. Congenital cystic lesions include PCLD, simple cysts, duct related and ciliated hepatic foregut cysts, while acquired cystic lesion is divided into infectious and non-infectious. The infectious cysts are the LHC, the amoebic abscess, and the pyogenic abscess, whereas the non-infectious cysts are neoplastic cysts and false cysts. Minimally invasive management of LC is an emerging field including many therapeutic modalities ranging from the percutaneous aspiration of pyogenic abscesses to laparoscopic hepatectomy for hepatic CA (Table III). The application of the various minimally invasive approaches depends on the type of the cystic lesion, its size and its position in the liver.

Concerning congenital LC, minimally invasive techniques have been applied mostly in cases of simple cysts and PCLD. Simple liver LC are treated when they are enlarged and symptomatic. The preferred methods are the laparoscopic unroofing and the percutaneous sclerotherapy, which are equally effective, but percutaneous sclerotherapy has fewer complications<sup>1</sup>. Cysts that are large, superficial and anteriorly seated are the best candidates for laparoscopic fenestration<sup>8</sup>. Laparoscopic unroofing has also been applied in cases of PCLD, particular in cases of few large cysts located in the anterior segments of the liver<sup>19</sup>. Percutaneous aspiration and sclerotherapy have also been applied in high-risk patients with PCLD and a large dominant cyst, but with high recurrence rates<sup>26-29</sup>.

Regarding acquired LC, many studies have been conducted on the application of minimally invasive techniques to hydatid cysts. There is a wide range of treatment modalities. Laparoscopic hepatectomy and pericystectomy are more radical forms of treatment, but are applied usually for cysts larger than 5 cm in diameter<sup>31</sup>.

Conservative approaches, such as simple drainage and laparoscopic partial pericystectomy can be applied in almost all hydatid LC<sup>35</sup>. However, laparoscopic operations are associated with an increased risk of spillage of cyst content into the peri-

toneal cavity. PAIR is another promising treatment for hydatid cysts that is applied in cysts without calcifications or biliary communications<sup>53</sup>. In regard to other acquired LC, percutaneous drainage is the treatment of choice for pyogenic liver abscesses that are larger than 5 cm in diameter or resistant to antimicrobial drugs<sup>61-65</sup> and for bilomas<sup>71,72</sup>. On the other hand, laparoscopic or open hepatectomy is preferred in all suspected CA<sup>78,82</sup>.

## Conclusions

Minimally invasive techniques are feasible and safe alternatives to the open approaches for treating LC. The most used techniques are percutaneous drainage, laparoscopic fenestration, and laparoscopic hepatectomy. However, the exact method that is preferred in each occasion depends on the type of the cystic lesion, its size and its position in the liver. More studies are needed in order to better determine the exact indications and complications of minimally invasive modalities when they are applied in LC.

## Conflict of Interest

The Authors declare that they have no conflict of interest.

## References

- 1) MOORTHY K, MIHSSIN N, HOUGHTON PW. The management of simple hepatic cysts: sclerotherapy or laparoscopic fenestration. *Ann R Coll Surg Engl* 2001; 83: 409-414.
- 2) ZACHERL J, SCHEUBA C, IMHOF M, JAKESZ R, FÜGGER R. Long-term results after laparoscopic unroofing of solitary symptomatic congenital liver cysts. *Surg Endosc* 2000; 14: 59-62.
- 3) REGEV A, REDDY KR, BERHO M, SLEEMAN D, LEVI JU, LIVINGSTONE AS, LEVI D, ALI U, MOLINA EG, SCHIFF ER. Large cystic lesions of the liver in adults: a 15-year experience in a tertiary center. *J Am Coll Surg* 2001; 193: 36-45.
- 4) FIAMINGO P, TEDESCHI U, VEROUX M, CILLO U, BROLESE A, DA ROLD A, MADIA C, ZANUS G, D'AMICO DF. Laparoscopic treatment of simple hepatic cysts and polycystic liver disease. *Surg Endosc Other Interv Tech* 2003; 17: 623-626.
- 5) TAGAYA N, NEMOTO T, KUBOTA K. Long-term results of laparoscopic unroofing of symptomatic solitary nonparasitic hepatic cysts. *Surg Laparosc Endosc Percutan Tech* 2003; 13: 76-79.
- 6) GIGOT JF, METAIRIE S, ETIENNE J, HORSMANS Y, VAN BEERS BE, SEMPoux C, DEPREZ P, MATERNE R, GEUBEL A, GLINEUR D, GIANELLO P. The surgical management of congenital liver cysts. *Surg Endosc* 2001; 15: 357-363.
- 7) DIEZ J, DECOUD J, GUTIERREZ L, SUHL A, MERELLO J. Laparoscopic treatment of symptomatic cysts of the liver. *Br J Surg* 1998; 85: 25-27.
- 8) GIGOT JF, LEGRAND M, HUBENS G, DE CANNIERE L, WIBIN E, DEWEER F, DRUART ML, BERTRAND C, DEVRIENDT H, DROISSART R, TUGILIMANA M, HAUTERS P, VEREECKEN L. Laparoscopic treatment of nonparasitic liver cysts: Adequate selection of patients and surgical technique. *World J Surg* 1996; 20: 556-561.
- 9) REGEV A, REDDY KR. Benign solid and cystic tumors of the liver. Volume 3: Hepatobiliary tract and pancreas. In: *Benign solid and cystic tumors of the liver. Volume 3: Hepatobiliary tract and pancreas*. Mosby, 2004; pp. 189-214.
- 10) LAI EC, WONG J. Symptomatic nonparasitic cysts of the liver. *World J Surg* 1990; 14: 452-456.
- 11) VANSONNENBERG E, WROBLICKA JT, DIAGOSTINO HB, MATHIESON JR, CASOLA G, OILAOIDE R, COOPERBERG PL. Symptomatic hepatic cysts: percutaneous drainage and sclerosis. *Radiology* 1994; 190: 387-392.
- 12) KATKHOUDA N, MAVOR E. Laparoscopic management of benign liver disease. *Surg Clin North Am* 2000; 80: 1203-1211.
- 13) BAI XL, LIANG TB, YU J, WANG WL, SHEN Y, ZHANG M, ZHENG S SEN. Long-term results of laparoscopic fenestration for patients with congenital liver cysts. *Hepatobiliary Pancreat Dis Int* 2007; 6: 600-603.
- 14) QUE F, NAGORNEY DM, GROSS JB, TORRES VE. Liver resection and cyst fenestration in the treatment of severe polycystic liver disease. *Gastroenterology* 1995; 108: 487-494.
- 15) CHEN MF. Surgery for adult polycystic liver disease. *J Gastroenterol Hepatol* 2000; 15: 1239-1242.
- 16) BARAHONA-GARRIDO J, CAMACHO-ESCOBEDO J, CERDA-CONTRERAS E, HERNANDEZ-CALLEROS J, YAMAMOTO-FURUSHO JK, TORRE A, URIBE M. Factors that influence outcome in non-invasive and invasive treatment in polycystic liver disease patients. *World J Gastroenterol* 2008; 14: 3195-3200.
- 17) KABBEJ M, SAUVANET A, CHAUVEAU D, FARGES O, BELGHITI J. Laparoscopic fenestration in polycystic liver disease. *Br J Surg* 1996; 83: 1697-1701.
- 18) KOPERNA T, VOGL S, SATZINGER U, SCHULZ F. Nonparasitic cysts of the liver: results and options of surgical treatment. *World J Surg* 1997; 21: 850-855.
- 19) MORINO M, DE GIULI M, FESTA V, GARRONE C. Laparoscopic management of symptomatic nonparasitic cysts of the liver. Indications and results. *Ann Surg* 1994; 219: 157-164.
- 20) MARTIN IJ, MCKINLEY AJ, CURRIE EJ, HOLMES P, GARDEN OJ. Tailoring the management of nonparasitic liver cysts. *Ann Surg* 1998; 228: 167-172.
- 21) KATKHOUDA N, HURWITZ M, GUGENHEIM J, MAVOR E, MASON RJ, WALDREP DJ, RIVERA RT, CHANDRA M, CAMPOS GM, OFFERMAN S, TRUSSLER A, FABIANI P, MOUIEL J. Laparoscopic management of benign solid and cystic lesions of the liver. *Ann Surg* 1999; 229: 460-466.



- 22) MARKS J, MOUIEL J, KATKHOUDA N, GUGENHEIM J, FABIANI P. Laparoscopic liver surgery. A report on 28 patients. *Surg Endosc* 1998; 12: 331-334.
- 23) PALANIVELU C, RANGARAJAN M, SENTHILKUMAR R, MADANKUMAR MV. Laparoscopic management of symptomatic multiple hepatic cysts: a combination of deroofting and radical excision. *JLS* 2007; 11: 466-469.
- 24) GARCEA G, PATTENDEN CJ, STEPHENSON J, DENNISON AR, BERRY DP. Nine-year single-center experience with nonparasitic liver cysts: diagnosis and management. *Dig Dis Sci* 2007; 52: 185-191.
- 25) GIGOT JF, JADOUL P, QUE F, VAN BEERS BE, ETIENNE J, HORMANS Y, COLLARD A, GEUBEL A, PRINGOT J, KESTENS PJ. Adult polycystic liver disease: is fenestration the most adequate operation for long-term management? *Ann Surg* 1997; 225: 286-294.
- 26) ANDERSSON R, JEPSSON B, LUNDERQUIST A, BENGMARK S. Alcohol sclerotherapy of non-parasitic cysts of the liver. *Br J Surg* 1989; 76: 254-255.
- 27) SAINI S, MUELLER PR, FERRUCCI JT, SIMEONE JF, WITTENBERG J, BUTCH RJ. Percutaneous aspiration of hepatic cysts does not provide definitive therapy. *Am J Roentgenol* 1983; 141: 559-560.
- 28) KAIRALUOMA MI, LEINONEN A, STÄHLBERG M, PÄIVÄNSALO M, KIVINIEMI H, SINILUOTO T. Percutaneous aspiration and alcohol sclerotherapy for symptomatic hepatic cysts. An alternative to surgical intervention. *Ann Surg* 1989; 210: 208-215.
- 29) TIKKAKOSKI T, MAKELA JT, LEINONEN S, PÄIVÄNSALO M, MERIKANTO J, KARTTUNEN A, SINILUOTO T, KAIRALUOMA MI. Treatment of symptomatic congenital hepatic cysts with single-session percutaneous drainage and ethanol sclerotherapy: technique and outcome. *J Vasc Interv Radiol* 1996; 7: 235-239.
- 30) KATKHOUDA N, FABIANI P, BENIZRI E, MOUIEL J. Laser resection of a liver hydatid cyst under videolaparoscopy. *Br J Surg* 1992; 79: 560-561.
- 31) BUSIĆ Z, LEMAC D, STIPANČIĆ I, BUSIĆ V, CAVKA M, MARTIĆ K. Surgical treatment of liver echinococcosis--the role of laparoscopy. *Acta Chir Belg* 2006; 106: 688-691.
- 32) WHO/OIE. Manual on Echinococcosis in Humans and Animals: A Public Health Problem of Global Concern. *Vet Parasitol* 2002; 104: 357.
- 33) AVGERINOS ED, PAVLAKIS E, STATHOULOPOULOS A, MANOUKAS E, SKARPAS G, TSATSOLIS P. Clinical presentations and surgical management of liver hydatidosis: our 20 year experience. *HPB (Oxford)* 2006; 8: 189-193.
- 34) KAYAALP C. Hydatid cyst of the liver. *Surg Liver, Biliary Tract, Pancreas* 2007; 4: 952-970.
- 35) MILICEVIC M. Echinococcal cysts: cause, diagnosis, complications and medical and surgical treatment. *Mastery Surgery 5th ed Philadelphia Lippincott Williams Wilkins* 2008; 1043-1068.
- 36) KEONG B, WILKIE B, SUTHERLAND T, FOX A. Hepatic cystic echinococcosis in Australia: an update on diagnosis and management. *ANZ J Surg* 2018; 88: 26-31.
- 37) EMELIANOV SI, KHAMIDOV MA. [Laparoscopic treatment of hydatid liver cysts]. *Khirurgiia (Sofia)* 2000; 32-34.
- 38) KHOURY G, ABIAD F, GEAGEA T, NABOUT G, JABBOUR S. Laparoscopic treatment of hydatid cysts of the liver and spleen. *Surg Endosc* 2000; 14: 243-245.
- 39) BICKEL A, LOBERANT N, SINGER-JORDAN J, GOLDFELD M, DAUD G, EITAN A. The Laparoscopic Approach to Abdominal Hydatid Cysts. *Arch Surg* 2001; 136: 789-795.
- 40) POLAT FR. Hydatid cyst: open or laparoscopic approach? A retrospective analysis. *Surg Laparosc Endosc Percutan Tech* 2012; 22: 264-266.
- 41) ZAHARIE F, BARTOS D, MOCAN L, ZAHARIE R, IANCU C, TOMUS C. Open or laparoscopic treatment for hydatid disease of the liver? A 10-year single-institution experience. *Surg Endosc* 2013; 27: 2110-2116.
- 42) ISCAN M, DUREN M. Endoscopic sphincterotomy in the management of postoperative complications of hepatic hydatid disease. *Endoscopy* 1991; 23: 282-283.
- 43) YILMAZ E, GÖKOK N. Hydatid disease of the liver: current surgical management. *Br J Clin Pract* 1990; 44: 612-615.
- 44) LANGER JC, ROSE DB, KEYSTONE JS, TAYLOR BR, LANGER B. Diagnosis and management of hydatid disease of the liver. A 15-year North American experience. *Ann Surg* 1984; 199: 412-417.
- 45) OZMEN V, IGCI A, KEBUDI A, KECER M, BOZFAKIOGLU Y, PARLAK M. Surgical treatment of hepatic hydatid disease. *Can J Surg* 1992; 35: 423-427.
- 46) ZENGİN K, UNAL E, KARABİÇAK I, APAYDIN B, TASKIN M. A new instrument, the éperfore-aspiratori for laparoscopic treatment of hydatid cysts of the liver. *Surg Laparosc Endosc Percutan Tech* 2003; 13: 80-82.
- 47) SEVEN R, BERBER E, MERCAN S, EMİNOĞLU L, BUDAK D. Laparoscopic treatment of hepatic hydatid cysts. *Surgery* 2000; 128: 36-40.
- 48) ERTEM M, KARAHASANOGU T, YAVUZ N, ERGUNEY S. Laparoscopically treated liver hydatid cysts. *Arch Surg* 2002; 137: 1170-1173.
- 49) GEORGESCU SO, DUBEI L, TARCOVEANU E, BRADEA C, LAZESCU D, CRUMPEI F, STRATAN I. Minimally invasive treatment of hepatic hydatid cysts. *Rom J Gastroenterol* 2005; 14: 249-252.
- 50) ALPER A, EMRE A, HAZAR H, ÖZDEN D, BİLGE O, ACARLI K, ARLOĞDUL O. Laparoscopic surgery of hepatic hydatid disease: initial results and early follow-up of 16 patients. *World J Surg* 1995; 19: 725-728.
- 51) DZIRI C, HAOUET K, FINGERHUT A. Treatment of hydatid cyst of the liver: where is the evidence? *World J Surg* 2004; 28: 731-736.
- 52) MUELLER PR, DAWSON SL, FERRUCCI JT, NARDI GL. Hepatic echinococcal cyst: successful percutaneous drainage. *Radiology*. 1985; 155: 627-628.
- 53) AKHAN O, OZMEN MN, DİNÇER A, SAYEK I, GÖÇMEN A. Liver hydatid disease: long-term results of percutaneous treatment. *Radiology* 1996; 198: 259-264.
- 54) VUITTON DA, MESLIN F, MACPHERSON C, BRUNETTI E, FILICE C. World Health Organization Informal Working

- Group on echinococcosis. PAIR: an option for the treatment of cystic echinococcosis. *Bull World Heal Organ*, 2002.
- 55) GIORGIO A, DE STEFANO G, ESPOSITO V, LIORRE G, DI SARNO A, GIORGIO V, SANGIOVANNI V, IANNECE MD, MARINIELLO N. Long-term results of percutaneous treatment of hydatid liver cysts: a single center 17 years experience. *Infection* 2008; 36: 256-261.
- 56) ORMECI N, SOYKAN I, BEKTAS A, SANOĐLU M, PALABIYIKOĐLU M, HADI YASA M, DÖKMECI A, UZUNALIMOĐLU O. A new percutaneous approach for the treatment of hydatid cysts of the liver. *Am J Gastroenterol* 2001; 96: 2225-2230.
- 57) PELÁEZ V, KUGLER C, CORREA D, DEL CARPIO M, GUANGIROLI M, MOLINA J, MARCOS B, LOPEZ E. PAIR as percutaneous treatment of hydatid liver cysts. *Acta Trop* 2000; 75: 197-202.
- 58) GHARBI HA, HASSINE W, BRAUNER MW, DUPUCH K. Ultrasound examination of the hydatid liver. *Radiology* 1981; 139: 459-463.
- 59) NASSERI-MOGHADDAM S, ABRISHAMI A, TAEFI A, MALEKZADEH R. Percutaneous needle aspiration, injection, and re-aspiration with or without benzimidazole coverage for uncomplicated hepatic hydatid cysts. In: Nasser-Moghaddam S. *Cochrane Database of Systematic Reviews*. Chichester, UK: John Wiley & Sons, Ltd; 2011.
- 60) KHANNA S, CHAUDHARY D, KUMAR A, VIJ JC. Experience with aspiration in cases of amebic liver abscess in an endemic area. *Eur J Clin Microbiol Infect Dis* 2005; 24: 428-430.
- 61) CHOU FF, SHEEN-CHEN SM, CHEN YS, CHEN MC, CHEN FC, TAI DI. Prognostic factors for pyogenic abscess of the liver. *J Am Coll Surg* 1994; 179: 727-732.
- 62) CHU KM, FAN ST, LAI EC, LO CM, WONG J. Pyogenic liver abscess. An audit of experience over the past decade. *Arch Surg* 1996; 131: 148-152.
- 63) SEETO RK, ROCKEY DC. Pyogenic liver abscess. Changes in etiology, management, and outcome. *Medicine (Baltimore)* 1996; 75: 99-113.
- 64) BARAKATE MS, STEPHEN MS, WAUGH RC, GALLAGHER PJ, SOLOMON MJ, STOREY DW, SHELDON DM. Pyogenic liver abscess: a review of 10 years' experience in management. *Aust N Z J Surg* 1999; 69: 205-209.
- 65) HUANG CJ, PITT HA, LIPSETT PA, OSTERMAN FA, LILLEMOR KD, CAMERON JL, ZUIDEMA GD. Pyogenic hepatic abscess. Changing trends over 42 years. *Ann Surg* 1996; 223: 600-607; discussion 607-609.
- 66) CHUNG YFA, TAY KH, TAN BS, HTOO AMM, THING CH, CHOW PKH, OOI LLPJ, LAU TN. Percutaneous drainage of liver abscess complicated by hepato-venous fistula. *Singapore Med J* 2003; 44: 299-301.
- 67) TAN L, ZHOU HJ, HARTMAN M, GANPATHI IS, MADHAVAN K, CHANG S. Laparoscopic drainage of cryptogenic liver abscess. *Surg Endosc Other Interv Tech* 2013; 27: 3308-3314.
- 68) DULL JS, TOPA L, BALGHA V, PAP A. Non-surgical treatment of biliary liver abscesses: efficacy of endoscopic drainage and local antibiotic lavage with nasobiliary catheter. *Gastrointest Endosc* 2000; 51: 55-59.
- 69) HOLBERT BL, BARON RL, DODD GD. Hepatic infarction caused by arterial insufficiency: Spectrum and evolution of CT findings. *Am J Roentgenol* 1996; 166: 815-820.
- 70) STEWART BG, GERVAIS DA, O'NEILL MJ, BOLAND GW, HAHN PF, MUELLER PR. Imaging and percutaneous treatment of secondarily infected hepatic infarctions. *Am J Roentgenol* 2008; 190: 601-607.
- 71) CHEN CJ, CHANG WH, SHIH SC, WANG TE, CHANG CW, CHEN MJ. Clinical presentation and outcome of hepatic subcapsular fluid collections. *J Formos Med Assoc* 2009; 108: 61-68.
- 72) HOWDIESHELL TR, PURVIS J, BATES WB, TEESLINK CR. Biloma and biliary fistula following hepatorrhaphy for liver trauma: incidence, natural history, and management. *Am Surg* 1995; 61: 165-168.
- 73) GERNDT SJ, SEIDEL SP, TAHERI PA, RODRIGUEZ JL. Biliary tract injury following blunt abdominal trauma: case reports. *J Trauma* 1995; 39: 612-615.
- 74) JENKINS MA, PONSKY JL. Endoscopic retrograde cholangiopancreatography and endobiliary stenting in the treatment of biliary injury resulting from liver trauma. *Surg Laparosc Endosc* 1995; 5: 118-120.
- 75) FONG ZV, WOLF AM, DORIA C, BERGER AC, ROSATO EL, PALAZZO F. Hemorrhagic Hepatic Cyst: Report of a Case and Review of the Literature with Emphasis on Clinical Approach and Management. *J Gastrointest Surg* 2012; 16: 1782-1789.
- 76) AMMORI BJ, JENKINS BL, LIM PCM, PRASAD KR, POLLARD SG, LODGE JPA. Surgical strategy for cystic diseases of the liver in a western hepatobiliary center. *World J Surg* 2002; 26: 462-469.
- 77) HAI S, HIROHASHI K, UENISHI T, YAMAMOTO T, SHUTO T, TANAKA H, KUBO S, TANAKA S, KINOSHITA H. Surgical management of cystic hepatic neoplasms. *J Gastroenterol* 2003; 38: 759-764.
- 78) VOGT DP, HENDERSON JM, CHMIELEWSKI E. Cystadenoma and cystadenocarcinoma of the liver: A single center experience. *J. Am. Coll. Surg.* 2005; 200: 727-733.
- 79) THOMAS KT, WELCH D, TRUEBLOOD A, SULUR P, WISE P, GORDEN DL, CHARI RS, WRIGHT JK, WASHINGTON K, PINSON CW. Effective treatment of biliary cystadenoma. *Ann Surg* 2005; 241: 769-773; discussion 773-775.
- 80) FIAMINGO P, VEROUX M, CILLO U, BASSO S, BUFFONE A, DIAMICO DF. Incidental cystadenoma after laparoscopic treatment of hepatic cysts: which strategy? *Surg Laparosc Endosc Percutan Tech* 2004; 14: 282-284.
- 81) VEROUX M, FIAMINGO P, CILLO U, TEDESCHI U, BROLESE A, VEROUX P, BASSO S, BUFFONE A, DIAMICO DF. Cystadenoma and laparoscopic surgery for hepatic cystic disease: A need for laparotomy? *Surg Endosc Other Interv Tech* 2005; 19: 1077-1081.
- 82) KOFFRON A, RAO S, FERRARIO M, ABECASSIS M. Intrahepatic biliary cystadenoma: role of cyst fluid analysis and surgical management in the laparoscopic era. *Surgery* 2004; 136: 926-936.