

The effect of Amifostine (Ethyol) on intestinal anastomosis in *rats* with radiation enteritis

C.S. OZDEMIR¹, K.M. BURGAZLI², E. BEKEN-OZDEMIR³, H. AKDERE⁴,
M. MERICLILER², M.F. OZCELIK⁵

¹General Surgery Department, Elazig Teaching and Research Hospital, Elazig, Turkey

²Department of Internal Medicine, Wuppertal Research and Medical Center, Wuppertal, Germany

³General Surgery Department, Elazig Harput State Hospital, Elazig, Turkey

⁴Department of Urology, Trakya University Medical Faculty, Edirne, Turkey

⁵Department of General Surgery, Istanbul University Cerrahpasa Medical Faculty, Istanbul, Turkey

Abstract. – **BACKGROUND:** Preoperative radiotherapy in colorectal cancers is being used as an adjuvant therapy with increasing frequency. Postoperative complications in early and late periods in various ratios are reported. It has also been shown that radiation has a delaying effect on wound healing and this effect is dose-dependent.

AIM: This study investigated the effects of the Amifostine on healing of the irradiated colonic anastomosis.

MATERIALS AND METHODS: 30 female Wistar rats were divided randomly into three groups equally (n=10). Colonic anastomosis were performed to all rats. Group I served as a control. 800 rad abdominopelvic irradiation on the 5th day of preoperation was given to group II and III. Rats in the group III, prior to radiation, were given Amifostine at a dose of 200 mg/kg. On the 5th postoperative day all the rats were sacrificed and the healing of anastomosis was measured with bursting pressure, hydroxyproline levels and histopathological evaluations. Statistical analyses were expressed by analysis of variance (ANOVA) test and $p < 0.05$ was regarded as significant.

RESULTS: In group II, all parameters were found lower compared with control group and Amifostine+Radiation group. As compared with hydroxyproline values and the anastomotic wound healing scores, except group II, no significantly difference were determined between the two other groups. In bursting pressure levels, Group I and III were higher than group II, but not statistically significant ($p > 0.05$). In group III (Amifostine+Radiation group), the hydroxyproline levels and anastomotic wound healing scores were found significantly higher than group II ($p < 0.05$), and no significant difference were found between the control group.

CONCLUSIONS: It is determined that radiation given on the 5th preoperative day has a negative effect on anastomotic wound healing and administered Amifostine prevent this negative effect. In the light of these data, the Amifostine may have a positive effect on preoperative irradiated

colonic anastomosis and may play an important role in future on the supporting of the colonic anastomosis.

Key Words:

Amifostine, Intestinal anastomosis, Radiation, Wound healing, Preoperative radiotherapy.

Introduction

Healing process in colonic anastomosis occurs according to the same healing principles. Edema and inflammation is predominant in first four days. After first 24-48 hours, widespread inflammatory response is seen in invaginated mucosa and submucosa and necrotic regions start to fall into the lumen. Therefore, healing after anastomosis is affected by excessive invagination. Healing is defined with formation of bridging fibrous tissue and durability of the collagen tissue^{1,2}. Due to the substantial decrement of collagenase in the tissues, 1st days of postoperation remains as the most critical time for the integrity of wound^{2,3}. This balance causing postoperative complications is effected by certain internal and external factors.

Compared with other gastrointestinal canal healing processes, colonic anastomosis healing is relatively slower and accompanied with more complications. Wound complications involve half of the complications seen in postoperative period and results in mortality and morbidity. Both local and systemic factors affect the wound healing which are mentioned in Table I⁴⁻⁶.

Evaluation of the anastomotic healing is generally done by biomechanical, biochemical and histopathological methods. Biomechanical methods consist of burst pressure and tensile strength

Table I. Local and systemic factors effecting the healing of anastomosis.

Local Factors	Systemic factors
Blood flow	Old age
Hematoma	Anemia
Venous insufficiency	Malnutrition
Trauma	Malignancy
Infection	Jaundice
Radiation	Obesity
Surgical technique	Uremia
Hyperthermia	Diabetes mellitus
Drainage	Chemotherapy
Colon cleansing	Corticosteroids
	Anti-inflammatory drugs
	Alcoholism
	Hereditary connective tissue disorders
	Infections
	Trauma
	Hypovolemia
	Hypoxia
	Avitaminosis
	Sepsis

techniques^{7,8}. Burst pressure represents the wall resistance against to the increasing intraluminal pressure. The lowest values are seen on the 2nd and 3rd postoperative day and gradually increase⁹. Bursting pressure reflects more accurately the pathophysiology of wound dehiscence and anastomotic healing in early postoperative period⁹. On the other hand, tensile strength is gained by collagen resynthesis; thus, it is used in late-stage healing^{9,10}. Biochemical methods (hydroxyproline), microscopy and radioactive labeling method are also currently being used.

Radiation enteritis is a functional disorder of the large and small bowel that occurs during or after a course of radiation therapy to the abdomen, pelvis or rectum. Among the complications of abdominal and pelvic radiotherapy, it is one of the most significant and serious complications¹¹. The increase in the occurrence of radiation enteritis is correlated with the combined use of chemotherapy and radiotherapy¹². Radiation enteritis is a progressive disease leads to intestinal fibrosis and obliterative endarteritis which causes high mortality and morbidity rates¹³. Intestinal mucosa is very sensitive to ionized radiation. Acute side effects such as nausea, vomiting, abdominal cramps, and diarrhea occur between 800-1000 cGy radiation¹⁴. Injuries clinically evident during the first course of radiation and up to 8 weeks later are considered acute¹⁵. Only 5% to 15% of persons treated with radia-

tion to the abdomen will develop chronic problems¹⁶. Radiotherapy acts cytotoxicity on epithelial cells with high proliferation rate. Histopathology of radiation enteritis is characterized by diffuse collagen deposition and progressive occlusive vasculitis. Ulceration, necrosis and perforation of intestinal wall can be seen¹¹. Treatment is generally symptomatic for dehydration, malabsorption and diarrhea.

Amifostine (Ethyol, MedImmune Oncology, Inc., West Conchohocken, PA, USA), has been developed for the U.S Army to protect military personal from radiation^{17,18}. It is a pro-drug and type of Thiophosphate. Active metabolite (Thiol) is formed after dephosphorylation by alkaline phosphatase in tissues. After a rapid uptake by tissues, free Thiol detoxifies reactive end products of radiation and cytotoxic agents. Distribution half-life of Amifostine is less than 1 minute and elimination half-life is nearly 8 minutes. It is used intravenously 15-30 minutes before the radiotherapy or chemotherapy. Studies didn't show any significant differences results between administration routes (SC or IV)¹⁹. Although most common side effects are hypotension, flushing and chilling, there is no need to stop the treatment^{18,20}. Amifostine selectively protects multiple organ systems from the toxic effects of ionized radiation and induces endothelial proliferation and neovascularization^{18,21,22,23,24}. Therefore, it accelerates the wound healing process.

Materials and Methods

Animals

Thirty female Wistar rats, with an average weight of 180-220 grams, were studied in Istanbul University Animal application and Research Center with the approval of Ethics Committee. All animals were fed with water and standardized rat food.

Experimental Procedure

Rats were divided randomly into three groups equally (n=10). Colonic anastomoses were performed to all rats. Group I served as a control. Group II consisted of rats that were given 800 rad abdominopelvic irradiation on the fifth preoperative day. Rats in the Group III were given Amifostine at a dose of 200 mg/kg prior to radiation. Simulated irradiation was applied on 2 rats to detect the target dose for radiation damage without leading mortality. After

intraperitoneal ketamine hydrochloride (50 ml/kg) anesthesia, 800 rad radiation (SSD: 80 cm) was given to rats in group II and III from 17 × 8 frame by Cirus (General Electric) Cobalt 60 teletherapy device.

Surgery performed with anesthesia to all groups after the 5th day of radiotherapy. After thorough shaving of the abdominal area up to the middle of the anterior surface of the thorax, the area was sterilized with the use of iodine solution. Operation was performed in clean conditions but not in sterile. The abdomen was opened from lower quadrant with 3 cm median laparotomy. A colonic segment, 5 mm length of, 3 cm proximal to descending colon was transected and re-anastomosed end-to-end using the 6-0 polypropylene (Figure 1). Abdominal wall was closed with 3-0 silk continuous sutures.

Rats in the Group 3 were given 200 ml/kg single dose intraperitoneal Amifostine 20 minutes prior to radiotherapy.

On the 5th postoperative day, all rats were sacrificed by cervical dislocation. Anastomosis line was resected from its 2 cm distal and 2 cm proximal parts by relaparotomy. Mechanical, biochemical and histopathological parameters were used in order to evaluate the healing of anastomosis. After the burst pressure of the resected colonic segment was measured, it was opened through its long axis. Resected part was minimized from its 0.5 cm proximal and 0.5 cm distal part and separated into two parts. One half was put into formaldehyde (10%) and saved for histopathological examination. Other part was wrapped with aluminum foil and stored in deep freezer at -40°C in order to state the hydroxyproline levels.

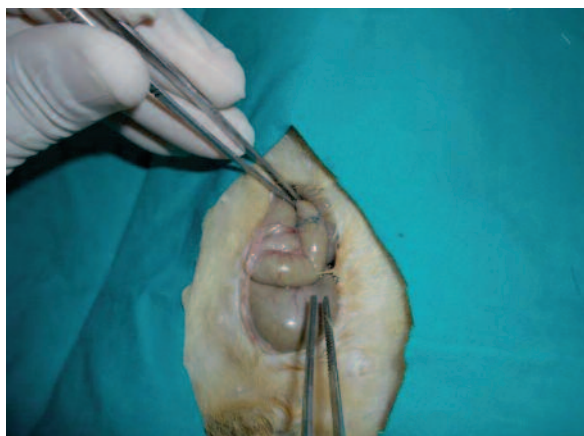

Figure 1. The colon segment from anastomosis application.

Burst Pressure Measurement

Burst pressure was measured *in situ* in the point where the anastomosis was applied. During the measurements a stable measurement pump (perfusor, Braun, Fairbanks, AK, USA) and manometer were used. The colon was tied with 3/0 silk suture from 2 cm distal and dissected from 2 cm proximal to the anastomosis. The fecal content was cleansed with physiological saline solution and the infusion pump was placed to the proximal open edge without causing any air leakage. Air (6 ml/min) was given under the water. The pressure at the point where the air bubbles were observed, was recorded as burst pressure.

Hydroxyproline Measurement

After the measurement of burst pressure, the colon was resected from 0.5 cm distal and 0.5 cm proximal to the anastomotic part and stored at -40°C until the examination day.

On the examination day, the tissue samples which are dissolved under the room temperature, were purified from the moisture by the drying paper. After weighed with assay balance, the tissue samples were homogenized with Potter type homogenizer (Heidolph-RZR 2021, Germany) in the physiologic saline solution, and the homogenates with the concentration of 20% (20 g/ml) were prepared. Afterwards, homogenates were centrifuged for 15 minutes with 1500 rpm. Obtained supernatants of the tissue samples were hydrolyzed for 16-18 hours by respectively adding equal amount of HCl²⁵. The study was maintained with hydroxyproline kit (Hypronisticon, Organon, Oss, Netherlands) which works with the principles described by Stegemann and Strandler²⁶. The absorbance of acquired colored component was evaluated as spectrophotometric parameters at 560 nm and the level of tissue hydroxyproline was calculated as microgram/mg wet tissue²⁷.

Histopathological Evaluation

The rats are sacrificed and the colon segments including the anastomosis region fixed in the formaldehyde solution (10%). After the routine follow-up examination, the sections from the tissue samples were embedded in paraffin. The sections from the paraffin blocks were stained with Hematoxylin & Eosin and observed with light microscope. The wound healing of the anastomosis region was evaluated with modified scoring system based on the inflammatory cells, neutrophils, neovascularization, fibroblasts and collagen fibers (Table II).

Table II. Modified scoring system of the wound healing.

Score (S)		The concentration of the inflammatory cells	PMNL Infiltration	Neovascularization	Fibroblastic Aactivity	Collagen fibers
1	Low	+++	+++	-/+	-	-
2		+++	+++	+ /+++	+ /++	-
3	High	++	+ /++	+++	+++	+
4		+ /++	- /+	+ /++	+ /+++	++
5		- /+	- /+	+	+ /++	+++

Statistical Analysis

The burst pressure, hydroxyproline levels and the histopathological values of all groups were expressed with mean and standard deviations. The comparison of the burst pressure and hydroxyproline levels among the groups were done with One-way ANOVA tests. Significantly different results were dually compared with *post-hoc* comparison by Bonferron test and Dunnet-*t* test. For the pathological scoring, non-parametric Kruskal-Wallis one-way ANOVA and Dunn's Multiple Comparisons tests were used. The analysis among the groups was done with one-way ANOVA variant analysis.

Results

Five rats died during the surgery, 1 from group I, 1 from group II and 3 from group III. Deaths were thought to be the result of hypothermia or anesthesia. None of them were a consequence of radiation therapy. New rats were added to the groups instead of the dead ones. Wound infection observed only in one rat that in the control group. No anastomotic leakage leading to generalized peritonitis was detected macroscopically. Anastomosis lines were surrounded by peripheral tis-

sues and attached with omentum. Tissues were separable by blunt dissection. During the burst measurement, all explosions tested at the anastomosis line.

Average burst pressure level (mmHg) for group I (Control group) was 85 ± 7.11 SD, group II was 67.30 ± 5.83 and while for group III was 77.80 ± 4.84 (Table III, Figure 2). Burst pressure values in group I were significantly higher than other groups ($p < 0.05$) and in Group II were significantly lower than others ($p < 0.05$). Pressure levels in group III were found to be significantly higher than group II, in contrast, significantly lower than group I ($p < 0.05$). No statistically significant difference was found between group I and group III ($p > 0.05$).

Average hydroxyproline level (mcg/mg) for group I was 2.80 ± 0.72 SD, group II was 2.49 ± 0.65 and for group II was 2.96 ± 0.54 (Table IV, Figure 3). In terms of hydroxyproline levels, rats in group I and group III had significantly higher levels than rats in group II ($p < 0.05$). No statistically significant difference was found between group I and group III ($p > 0.05$).

Histopathological Findings

Neovascularization, fibroblastic activity and the amount of collagen fibers in anastomosis re-

Table III. Burst pressure levels (mmHg).

Rat number	Group I (control)	Group II (RT)	Group III (AMF+RT)
1	85	64	74
2	80	80	80
3	90	65	76
4	77	67	74
5	82	58	80
6	100	66	78
7	88	64	84
8	80	67	70
9	78	72	76
10	90	70	86
Mean \pm SD (mmHg)	85 ± 7.11	67.30 ± 5.83	77.80 ± 4.84

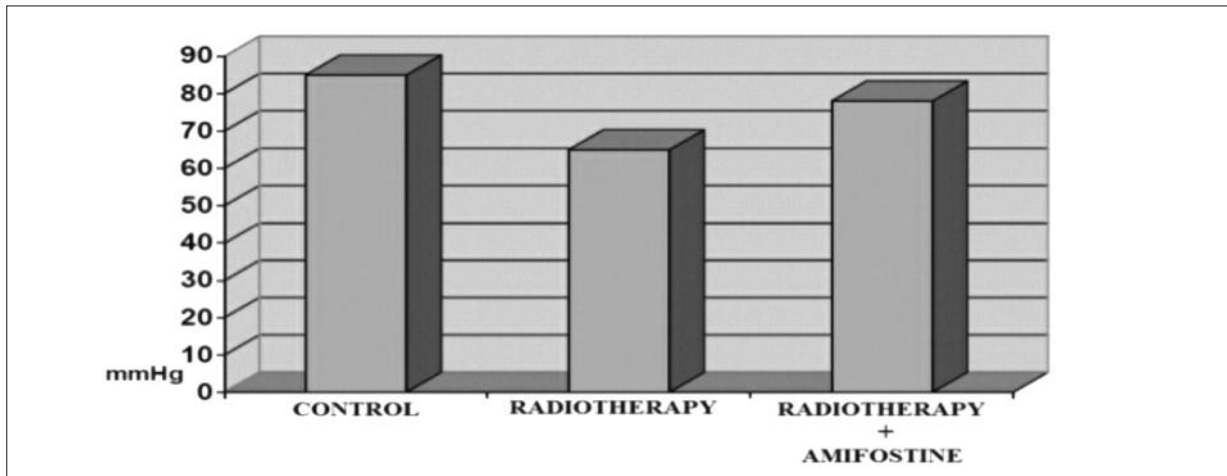


Figure 2. Comparison of burst pressure levels.

Table IV. Hydroxyproline levels (mcg/mg).

Rat number	Group I (control)	Group II (RT)	Group III (AMF+RT)
1	3.96	1.69	2.39
2	1.75	2.15	3.62
3	2.86	3.72	1.87
4	3.28	2.69	3.08
5	3.14	1.87	2.75
6	2.38	2.62	3.39
7	2.27	2.48	2.88
8	2.49	3.25	3.64
9	3.75	1.76	3.17
10	2.15	2.69	2.84
Mean \pm SD	2.80 \pm 0.72	2.49 \pm 0.65	2.96 \pm 0.54

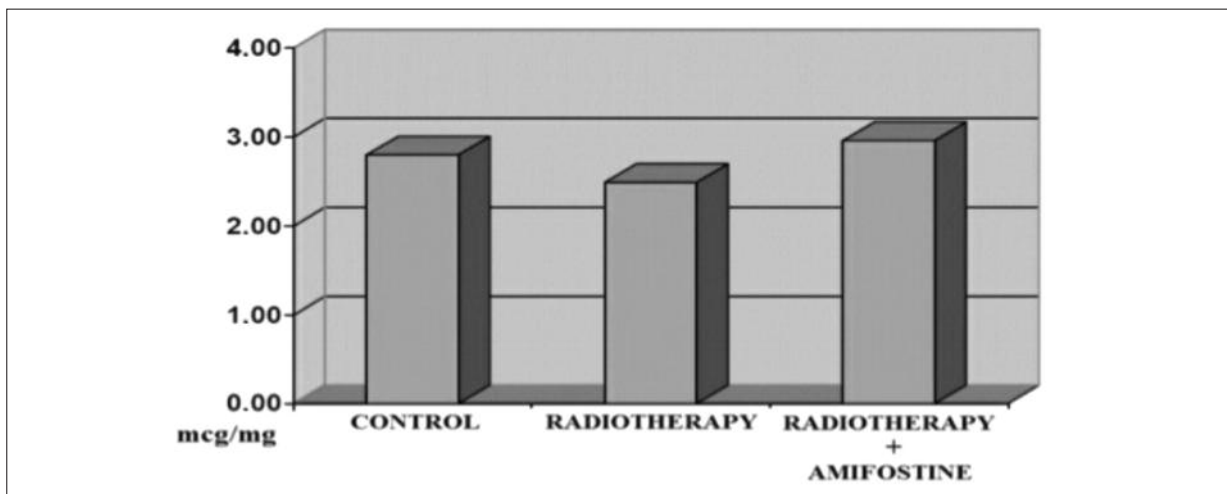


Figure 3. Comparison of hydroxyproline levels.

gion for Control Group (Group I) was similar to Amifostine + Radiotherapy Group (Group III) and no statistically significant difference was found between them ($p > 0.05$). However, rats in group I had higher values of these three parameters than radiotherapy group (Group II), which was found as significant ($p < 0.05$). The mean wound healing score for Group I was found 19.

The inflammatory cell infiltration in radiotherapy group (Group II) was found significantly higher than other two groups (Group I and III) ($p < 0.05$). Neovascularization, fibroblastic activity, and the amount of collagen fibers (Figure 4) in Group II were found significantly lower than other two group ($p < 0.05$). The wound healing score for Group II was found 7.3.

In Amifostine + radiotherapy group (Group III), inflammatory cell infiltration was significantly lower than Group II ($p < 0.05$) and not a significant difference with control group was observed ($p < 0.05$). Neovascularization and the amount of collagen fibers were higher in Group III than Group I; however, the difference between them was not statistically significant ($p < 0.05$). On the other side, the difference of these two parameters between Group III and Group II was found statistically significant ($p < 0.05$). The fibroblastic activity in Group III was statistically higher than Group II ($p < 0.05$). Although this parameter was found lower in Group III than in Group I, no statistically significant difference was found ($p < 0.05$). The mean wound healing score was found 20.2.

The comparison of the wound healing scores among the groups showed that the lowest score was belonged to Group II ($p < 0.05$). While the

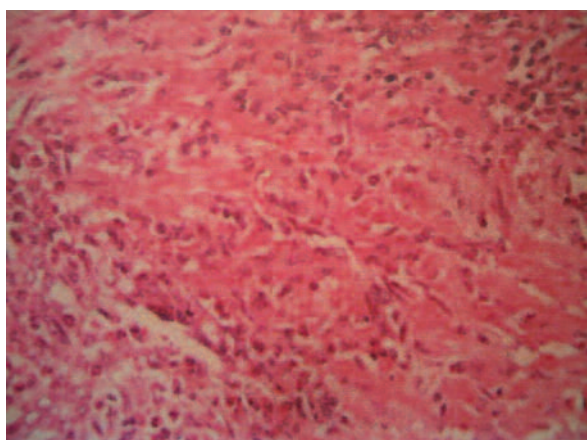


Figure 4. Collagen granulation tissue in anastomosis region (H&E, $\times 200$).

score of Group I was found significantly higher than Group II ($p < 0.05$), it was similar to Group III which was statistically insignificant ($p > 0.05$). The score of Group III was significantly higher than Group II ($p < 0.05$).

Discussion

In gastrointestinal surgery, most important complications causing mortality and morbidity are anastomosis leakages which are mostly seen in colon^{4,28,29}.

Preoperative radiotherapy for rectum cancers has taken a place in the recent treatment protocols^{30,31}. Some studies have showed that preoperative radiotherapy increases the resectability of rectum tumors and decreases lymph node metastasis^{30,32-34}. Radiation induced enteritis occurs in 5-25% of patients receiving pelvic radiotherapy and it is considered as one of the most harming complication^{11,35}.

Anderson et al³⁶ investigated the late-term complications of radiotherapy on 16 dogs and detected colitis in 9 of them. Among 9 colitis cases, 5 were severe and 3 had perforation. Stevens et al³⁷ compared preoperative radiotherapy group prior to anterior resection and control group without radiotherapy and as a result, anastomosis leakage was found significantly higher in group receiving radiotherapy. Pleskovic et al³⁸ applied combined radiotherapy and chemotherapy on 20 dogs and, enterocyte and lymphocyte loss in early stage, loss of integrity in mucosal barrier and malabsorption syndromes were observed. Moreover, a research found no significant difference in anastomosis leakage between different anastomosis technique applied groups³⁹. Winsey et al⁴⁰ observed a significant decline in burst pressure and hydroxyproline levels on the 7th postoperative day in irradiated rats. Consequently, studies about this subject showed the effects of radiation on healing of intestinal anastomosis in a dose-dependent manner.

In our study, we gave 800 rad single dose abdominopelvic irradiation 5 days before the anastomosis. According to the 5th postoperative day measurements, burst pressure and hydroxyproline levels were lower than control group ($p > 0.05$). Combined Amifostine and radiotherapy applied group had higher levels of hydroxyproline compared to control group and had same values of burst pressures with control group. As a result of this measurements and histopathological

findings, we found that single and low dose radiation therapy given on 5th postoperative day impairs the healing process. Our results were compatible with the literature.

On the other hand, some reports propound that radiation don't effects the healing process^{32,33,41}. Weiber et al³³ made a colonic anastomosis in rats 4 days after a preoperative radiotherapy (1000+1000 rad) and failed to show negative effects of radiation on healing in early postoperative period³³. On behalf of a clinical research done by Friedman et al³², it was established that 4-6 weeks later than 4500 rad pelvic irradiation, the anastomosis leakage which was the result of anterior resection, was similar to control group and showed prophylactic colostomy was unnecessary. Muhammet El-Malt et al⁴¹ study was including application of combined radiochemotherapy (41.6 Gy + 5-FU) to rats and they stated that radiochemotherapy had no negative effect on colonic anastomosis.

The general view about the impairment of anastomosis healing due to the preoperative radiotherapy has led researchers to investigate a preventive method for the effects of radiation. For this purpose, many studies have been done such as administration of vitamin A and glutamine in total parenteral nutrition treatment, supporting of anastomosis line with adhesive fibrin and colostomy to proximal anastomosis line^{32,33,40}.

Amifostine (Ethyol) substance which was investigated for the effect in colon anastomosis in rats with preoperative radiotherapy was firstly developed by American army for protection of American employees from the radiation in 1950^{17,42}. In the USA, the use of Amifostine for the prevention of Cysplatin treatment related nephrotoxicity in advanced ovarian cancer and non small lung cancer was approved¹⁸. Moreover, the use of Amifostine was confirmed for prevention of xerostomia which occurs after postoperative radiotherapy for head and neck cancers²⁰. It was shown in different studies that Amifostine protects various cells from the radiation damages^{43,44}. Amifostine prevents cell damage due to the radiation and chemotherapy by removing oxygen radicals and detoxifying the reactive metabolites of cytotoxic agents⁴⁵. Furthermore, Amifostine induces endothelial cell proliferation and following neovascularization which is an important stage for wound healing^{23,34}.

In the experimental study of Aydın et al⁴⁶ a single dose of Amifostine had an positive impact on flap healing of the pigs having preoperative

radiotherapy however didn't effect the flap survival. Carroll et al⁴⁷ investigated the effectiveness of cytoprotective agents on the colon anastomosis after radiotherapy. Although Ribo-cystein and Amifostine applied group founded to have much more burst pressure values than control group, the difference was statistically insignificant ($p > 0.05$).

In our study, while the burst pressure of Amifostine + radiotherapy group was lower than that of control group, at the aspect of hydroxyproline values and histopathological scoring these two groups were found familiar and no statistically significant difference was found ($p > 0.05$). hydroxyproline and values and histopathological scoring of the Amifostine + radiotherapy was found significantly higher than those of radiotherapy group. Although the burst pressure of the Amifostine + radiotherapy group was higher than those of radiotherapy group, the difference between two was not statistically significant ($p > 0.05$).

Amifostine is an effective radioprotectant present in tissues and does not have a negative effect on anti-tumoral activity of radiation therapy. Endothelial cell proliferation and neovascularization were shown at the wound line being compatible with the literature. According to our knowledge, the subject of Amifostine effect on the healing of colonic anastomosis in the rats with radiation enteritis has not been studied yet. We established that in rats applied preoperative radiotherapy Amifostine did not increase the burst pressure of the colonic anastomosis but did increase the hydroxyproline levels. This difference can be explained by that the hydroxyproline showed the amount of collagen rather than the quality of the collagen⁴⁶. Based on these findings, it can be concerned that in the rats with preoperative radiation therapy, Amifostine can strengthen the colonic anastomosis. However, further studies are needed to determine the exact place of Amifostine in the colonic anastomosis in the rats applied preoperative radiation therapy.

Conclusions

In our study we have identified a negative impact of radiotherapy on healing of anastomosis. By using hydroxyproline values and histopathological methods, positive effect of Amifostine on the healing of anastomosis was found. In terms of burst pressure values and histopathological

scores, Amifostine + Radiotherapy group compared with radiotherapy group found to be significantly higher ($p > 0.05$). However, both compared with control group, the difference was not statistically significant ($p > 0.05$).

In conclusion, Amifostine can support anastomosis healing after preoperative or postoperative radiotherapy, especially in colorectal surgery. However, further studies are needed on this issue.

Conflict of Interest

None to declare.

References

- 1) GRAHAM MF, BLOMQUIST P, ZEDERFELDT B. The alimentary canal. In: Cohen IK, Digelman RF. Wound healing. Biochemical and clinical aspects. Philadelphia, WB Saunders Company, 1992, 1st ed, pp. 433-449.
- 2) IRVIN TT, HUNT TK. Reappraisal of the healing process of anastomosis of the colon. Surg Gynecol Obstet 1974; 138: 741-746.
- 3) HESP F, HENDRIKS T. Wound healing in the intestinal wall. A comparison between experimental ileal and colonic anastomoses. Dis Col Rect 1984; 27: 99-104.
- 4) BRASKEN P. Healing of experimental colon anastomosis. Eur J Surg Suppl 1991; 566: 1-51.
- 5) KHOURY GA, WAXMAN BP. Large bowel anastomoses. The healing process and sutured anastomoses. A review. Br J Surg 1983; 70: 61-63.
- 6) IRVIN TT, GOLIGHER JC. Aetiology of disruption of intestinal anastomoses. Br J Surg 1973; 60: 461-464.
- 7) JIBORN H, AHONEN J, ZEDERFELDT B. Healing of experimental colonic anastomosis. I. Bursting strength of the colon after left colon resection and anastomosis. Am J Surg 1978; 136: 587-594.
- 8) JIBORN H, AHONEN J, ZEDERFELDT B. Healing of experimental colonic anastomosis. II. Breaking strength of the colon after left colon resection and anastomosis. Am J Surg 1978; 136: 595-599.
- 9) HAWLEY, PR. The aetiology of colonic anastomotic leaks with special reference to the role of collagenase. M.Sc. Thesis, University of London, 1969.
- 10) CARRICO TJ, MENHRHOF AJ, COHEN IK. Biology of wound healing. Surg Clin North Am 1984; 64: 721-733.
- 11) NGUYEN NP, ANTOINE JE, DUTTA S. Current concepts in radiation enteritis and implications for future clinical trials. Cancer 2002; 95: 1151-1163.
- 12) OOI BS, TJANDRA JJ, GREEN MD. Morbidities of adjuvant chemotherapy and radiotherapy for resectable rectal cancer: an overview. Dis Col Rectum 1999; 42: 403-418.
- 13) CROSS MJ, FRAZEE RC. Surgical treatment or radiation enteritis. Am Surg 1992; 58: 132-135.
- 14) PEREZ CA, BRADY LW. Principles and Practice of Radiation Oncology. 3rd ed. Philadelphia, Lippincott-Raven Publisher, 1998.
- 15) O'BRIEN PH, JENRETTE JM 3RD, GARVIN AJ. Radiation enteritis. Am Surg 1987; 53: 501-504.
- 16) YEOH EK, HOROWITZ M. Radiation enteritis. Surg 1987; 165: 373-379.
- 17) DAVIDSON DE, GREANAN MM, SWEENEY TR. Biological characteristics of some improved radioprotectors. In: Brady LW (Editor), Radiation Sensitizers: their use in clinical management of cancer. Masson, New York, 1980; 309-320.
- 18) KEMP G, ROSE P, LURAIN J, BERMAN M, MANETTA A, ROULLET B, HOMESLEY H, BELPOMME D, GLICK J. Amifostine pretreatment for protection against cyclophosphamide-induced and cisplatin-induced toxicities: results of a randomized control trial in patients with advanced ovarian cancer. J Clin Oncol 1996; 14: 2101-2112.
- 19) CASSAT DR, FAZENBAKER CA, KIFLE G, BACHY CM. Effects of dose and schedule on the efficacy of ethylol: pre-clinical studies. Semin Oncol 2003; 30: 31-39.
- 20) BRIZEL DM, WASSERMAN TH, HENKE M, STRNAD V, RUDAT V, MONNIER A, ESCHWEGE F, ZHANG J, RUSSELL L, OSTER W, SAUER R. Phase III randomized trial of amifostine as a radioprotector in head and neck cancer. J Clin Oncol 2000; 18: 3339-3345.
- 21) CAPIZZI RL. Clinical status and optimal use of amifostine. Oncology (Williston park) 1999; 13: 47-59; Discussion 63, 67.
- 22) MEHTA MP. Amifostine and combined-modality therapeutic approaches. Semin Oncol 1999; 26: 95-101.
- 23) PLASSWILM L, HANJALIC A, HOEPER J. Microvessel density and endothelial cell proliferation after amifostine (Ethylol) administration in vivo. Anticancer Res 1999; 19: 4241-4245.
- 24) GIANNOPOULOU E, KATSORIS P, PARTHYMOU A, KARDAMAKIS D, PAPADIMITRIOU E. Amifostine protects blood vessels from the effects of ionizing radiation. Anticancer Res 2002; 22: 2821-2826.
- 25) KIVIRIKKO K, LAITINEN O, PROCKOP DJ. Modifications of a specific assay for hydroxyproline in urine. Anal Biochem 1967; 19: 249-255.
- 26) STEGEMANN H, STADLER K. Determination of hydroxyproline. Clin Chim Acta 1967; 18: 267-273.
- 27) PROCKOP DJ, KIVIRIKKO KI. Relationship of hydroxyproline excretion in urine to collagen metabolism. Ann Int Med 1967; 66: 1243-1266.
- 28) FIELDING LP, BROWN SS, BLESOVSKY L, KEARNEY G. Anastomotic integrity after operations for large bowel cancer: multicentre study. Br Med J 1980; 281: 411-414.
- 29) MATHESON NA, IRVING AD. Single layer anastomosis in the gastrointestinal tract. Surg Gynecol Obstet 1976; 143: 619-624.
- 30) CUMMINGS BJ. Adjuvant radiation therapy for colorectal cancer. Cancer 1992; 70: 1372-1383.

- 31) HIGGINS GA, CONN JH, JORDAN PH JR, HUMPHREY EW, ROSWIT B, KEEHN RJ. Preoperative radiotherapy for colorectal cancer. *Ann Surg* 1975; 181: 624-631.
- 32) FRIEDMAN P, GARB JL, McCABE DP, CHABOT JR, PARK WC, STARK A, COE NP, PAGE DW. Intestinal anastomosis after preoperative radiation therapy for carcinoma of the rectum. *Surg Gynecol Obstet* 1987; 164: 257-260.
- 33) WEIBER S, JIBORN H, ZEDERFELDT B. Preoperative irradiation and colonic healing. *Eur J Surg* 1994; 160: 47-51.
- 34) DE LANGE EE, FECHNER RE, SPAULDING CA, EDGE SB. Rectal carcinoma treated by preoperative irradiation: MR imaging and histopathologic correlation. *Am J Surg* 1992; 158: 287-292.
- 35) EARNEST DL, TRIER JS. Radiation enteritis and colitis. In Slesenger MH and Fordthan JS (eds). *Gastrointestinal Disease Ph*. Saunders, Philadelphia 1989; pp. 1369-1382.
- 36) ANDERSON CR, McNIEL EA, GILLETTE EL, POWERS BE, LARUE SM. Late complications of pelvic irradiation in 16 dogs. *Vet Radiol Ultrasound* 2002; 43: 187-192.
- 37) STEVENS KR JR, FLETCHER WS, ALLEN CV. Anterior resection and primary anastomosis following high dose preoperative irradiation for adenocarcinoma of the recto-sigmoid. *Cancer* 1978; 41: 2065-2071.
- 38) PLESKOVIC A, ZORC-PLESKOVIC R, VRASPIR-PORENTA O, ZORC M, PETROVIC D. Colon mucosal cells after combined radiotherapy and chemotherapy. *Folia Biol (Praha)* 2001; 47: 156-162.
- 39) BLAKE DP, BUBRICK MP, KOCHSIEK GG, FEENEY DA, JOHNSTON GR, STROM RL, HITCHCOCK CR. Low anterior anastomotic dehiscence following preoperative irradiation with 6000 rads. *Dis Colon Rectum* 1984; 27: 176-181.
- 40) WINSEY K, SIMON RJ, LEVENSON SM, SEIFTER E, DEMETRIOU AA. Effect of supplemental vitamin A on colon anastomotic healing in rats given preoperative irradiation. *Am J Surg* 1987; 153: 153-156.
- 41) EL-MALT M, CEELLEN W, DE MEERLEER G, VERSTRAETE A, BOTERBERG T, VAN BELLE S, DE HEMPTINNE B, DE NEVE W, PATTYN P. Influence of preoperative combined radiochemotherapy on surgical outcome and colonic anastomotic healing: experimental study in rats. *Int J Rad Oncol Biol Phys* 2001; 50: 1073-1078.
- 42) GRDINA DJ, KATAOKA Y, MURLEY JS. Amifostine: mechanisms of action underlying cytoprotection and chemoprevention. *Drug Metabol Drug Interact* 2000; 16: 237-279.
- 43) CALABRO-JONES PM, AGUILERA JA, WARD JF, SMOLUK GD, FAHEY RC. Uptake of WR-2721 derivatives by cells in culture: identification of the transported form of the drug. *Cancer Res* 1988; 48: 3634-3640.
- 44) SMOLUK GD, FAHEY RC, CALABRO-JONES PM. Radioprotection of cells in culture by WR-2721 and derivatives: form of the drug responsible protection. *Cancer Res* 1988; 48: 3641-3647.
- 45) PETERS GJ, VAN DER VIJGH WJ. Protection of normal tissues from the cytotoxic effects of chemotherapy and radiation by amifostine (WR-2721) preclinical aspects. *Eur J Cancer* 1995; 31A(Suppl 1): S1-7.
- 46) AYDIN A, OZDEN BC, MEZDE I A, KURUL S, MERAL R, SOLAKO LU S. Effects of amifostine on healing of microvascular anastomoses, flap survival and nerve regeneration with preoperative or postoperative irradiation. *Microsurgery* 2004; 24: 392-399.
- 47) CARROLL MP, ZERA RT, ROBERTS JC, SCHLAFMANN SE, FEENEY DA, JOHNSTON GR, WEST MA, BUBRICK MP. Efficacy of radioprotective agents in preventing small and larger bowel radiation injury. *Dis Colon Rectum* 1995; 38: 716-722.