

Elderly man with rapidly enlarging axillary mass

C.M. REID, P. SWEET III¹

Department of Surgery, University of California San Diego, San Diego, CA, USA

¹Department of Pathology, University of California San Diego, San Diego, CA, USA

Abstract. – Melanoma has long been known to be a malignancy that can present in a plethora of forms. This often makes diagnosing it a challenge, but lends support to the concept of frequently keeping it in the clinician's differential. We present the unique case of a rapidly enlarging axillary mass in an elderly man that initially did not appear concerning for malignancy. Pathologic diagnosis was particularly difficult due to the cystic nature of the mass, and the uncommon histochemical staining pattern of this malignant melanoma. We discuss the variety of therapies directed at symptom relief and control when discovered in advanced stages. This was a rare presentation of a malignant melanoma that highlights the need to maintain a suspicion for the disease in uncertain clinical situations.

Key Words:

Melanoma, Axillary mass.

Introduction

Pathologies arising in the axilla are vast and related to a number of different organ systems. This complex anatomical region contains major nervous, vascular, lymphatic, and musculoskeletal structures, covered by a complex dermis. Masses found in this region may be secondary to derangements that are congenital^{1,2}, iatrogenic³, infectious^{4,5} or proliferative⁶⁻⁹. Often times the clinician will need to employ not only an exhaustive history and physical exam but also call for imaging and often biopsy.

Melanoma has long been known as a malignancy that can present in many different forms and in many different locations^{1,10-12}. As a result, a long held dogma is that the clinician should include it in their differential diagnosis frequently.

Case Report

An 85 year-old man with advanced Parkinson's disease was transferred to our Hospital

from skilled nursing facility with a recent history of a rapidly enlarging, erythematous and painful right axillary mass (Figure 1). He had become aware of the mass 3 months prior to presentation. He was on Coumadin for atrial fibrillation. He had an MRI, which showed an 11.7 cm complex fluid collection with differential diagnosis of hematoma or abscess. Incidentally, imaging also noted a remote right humeral neck fracture. He was started on a 10 days course of trimethoprim/sulfamethoxazole, did not respond and was transferred to the hospital.

On exam he had a 15 cm, tense, warm and mobile mass in the right axilla, with skin ecchymosis and signs of peripheral venous congestion (Figure 1). There was no appreciable local lymphadenopathy. The remainder of the right upper extremity was non-edematous and the neuro-vascular exam was normal. His only abnormal blood test was an INR of 2.2. Repeat MRI showed a 15 cm mass with central cystic component, encompassed by a thick lobulated rind of soft tissue. Computed tomography of the chest revealed local lymphadenopathy and a 1cm, non-calcified nodule in the right middle lobe of the lung. Under ultrasound guidance approximately 0.5 liters of turbid, yellow fluid was aspirated and sent for cytology. This showed extensive inflammation, coagulative-type necrosis and scant cells that labeled positive for microphthalmia-associated transcription factor (MITF) (Figure 2).

Given the concern for the viability of the overlying skin, an attempt at fine needle aspiration was preferred over incision. Although infection was a possibility, there was a definite concern for malignancy. No organisms were identified and histochemical stains for acid-fast bacilli and fungi were negative. The few cells that were obtained were identified as malignant. As part of staging, a PET scan was obtained displaying avid uptake in several discrete areas of soft tissue, lung, and the axial skeleton. A repeat attempt,

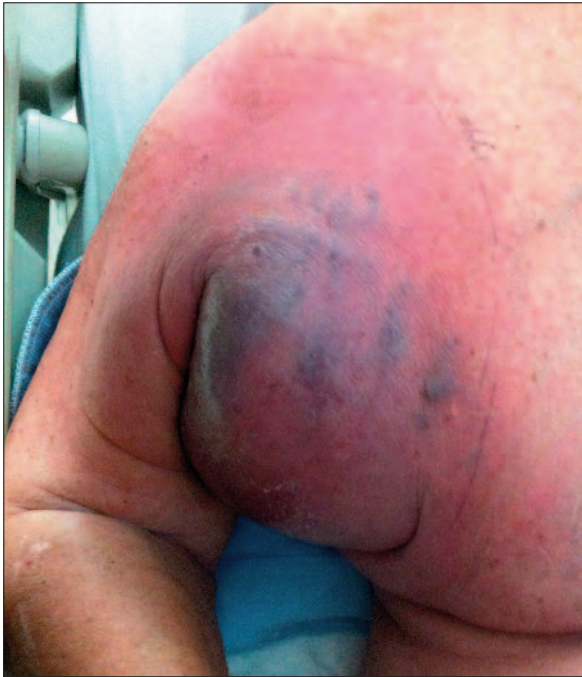

Figure 1. Erythematous and painful right axillary mass.

with core biopsy directed at the rind of the mass, yielded ample tissue that was sent for immunohistochemical staining, confirming the diagnosis of malignant melanoma.

Discussion

Melanoma continues to be a diagnostic challenge in medicine, pathology, radiology and

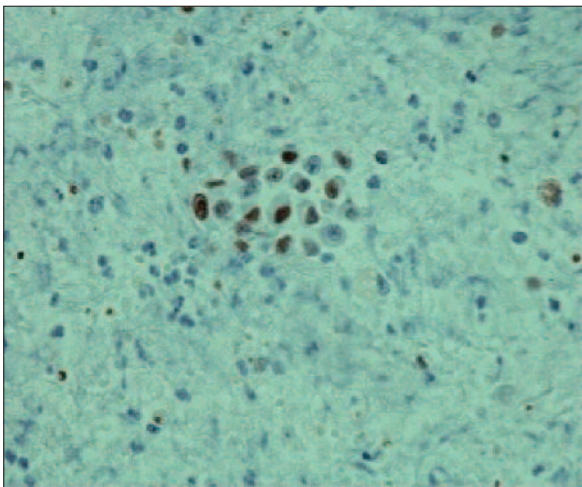


Figure 2. Aspirated cells stained for microphthalmia-associated transcription factor (MITF).

surgery. As seen in this case, this malignancy is capable of assuming many different macroscopic and histologic guises, including that of an abscess. Numerous phenotypes exist and range from desmoplastic to clear cell and melanoma notoriously can mimic other neoplasms. Helpful clues to diagnosis include, intracytoplasmic melanin pigment as well as intranuclear cherry-red nucleoli. Although the melanin was scanty in this case, there were focal findings of characteristic nucleoli. This case exemplifies the fact that the diagnosis of melanoma usually involves selective immunohistochemistry (IHC) testing¹³.

MITF is purportedly a very sensitive nuclear stain for melanoma but in some studies it had poor specificity¹⁴. In our case, the suspicion for melanoma was confirmed when the specimen stained strongly for the more specific cytoplasmic antibody HMB45¹⁵. Typically, malignant melanomas also do not label for cytokeratins or pan-lymphocyte common antigen, findings that were also seen in this case¹⁵.

Melanoma is most commonly diagnosed as a primary cutaneous lesion, and the recommended diagnostic maneuver is full thickness excisional biopsy¹⁶. The mainstay for metastatic disease is medical therapy¹². However, there is a role for surgical resection if disease is limited to one organ. Further, neoadjuvant therapy should be evaluated in this setting¹⁷. In particular, if metastatic disease resection can improve quality of life it should be considered¹⁸. If metastatic foci are not amendable to excision, radiation therapy has been shown to be effective for local control and symptom improvement^{19,20}.

At the time of presentation, our patient's functional status was poor, (Eastern Cooperative Oncology Group functional status of 4), and he had evidence of extensive metastatic burden. Discussions at our Tumor Board, yielded the recommendation for radiation therapy, as we did not believe that the patient would tolerate either medical therapy or surgical resection.

Conflict of Interest

None. There was no funding associated with this study.

References

- 1) CHARLOT M, BEATRIX O, CHATEAU F, DUBUISSON J, GOLFIER F, VALETTE PJ, RETY F. Pathologies of the male breast. *Diagn Interv Imaging* 2013; 94: 26-37.

- 2) MASOOD SN, MASOOD MF. Case report of fetal axillo-thoraco-abdominal cystic hygroma. *Arch Gynecol Obstet* 2010; 28: 111-115.
- 3) GONG DJ, YUAN HJ, ZHANG ZH. Axillary arteriovenous fistula after axillary plexus block. *J Anesth* 2013 Feb 26. [Epub ahead of print]
- 4) ZANGENEH M, AMERION M, SIADAT SD, ALJANI M. Primary hydatid cyst of the axillary region: A case report. *Case Rep Med* 2012; 2012: 362610.
- 5) ZHANG C, XIONG J, QUDDUS MR, OU JJ, HANSEN K, SUNG CJ. A rapidly enlarging squamous inclusion cyst in an axillary lymph node following core needle biopsy. *Case Rep Pathol* 2012; 2012: 418070.
- 6) YAMAMURA J, MASUDA N, KODAMA Y, YASOJIMA H, MIZUTANI M, KURIYAMA K, MANO M, NAKAMORI S, Sekimoto M. Male breast cancer originating in an accessory mammary gland in the axilla: A case report. *Case Rep Med* 2012; 2012: 286210.
- 7) SANCHEZ-GARCIA S, MANZANARES-CAMPILLO C, Menezes-Sanchez P, Munoz-Atienza V, Martin-Fernandez J. Merkel cell carcinoma: Case report and literature review. *Cir Cir* 2012; 80: 63-66.
- 8) MIRANDA BH, MALAHIAS M, EL-SAID TF, FAHMY FS. Axillary skin malignancy: A rare breast cancer presentation. *Ann Plast Surg* 2012 Dec 13. [Epub ahead of print]
- 9) LEE M, COOPER B, BECKER D. Keeping abreast of axillary masses. *Lancet* 2012; 380(9852): 1530.
- 10) THOMAS S, MENG YX, PATEL VG, STRAYHORN G. A rare form of melanoma masquerading as a diabetic foot ulcer: A case report. *Case Report Endocrinol* 2012; 2012: 502806.
- 11) LI YJ, ZHU SJ, YAN H, HAN J, WANG D, XU S. Primary malignant melanoma of the lacrimal sac. *BMJ Case Rep* 2012; 2012: 10.1136/bcr.2012-006349.
- 12) DUMMER R, HAUSCHILD A, GUGGENHEIM M, JOST L, PENTHEROUDAKIS G, ESMO Guidelines Working Group. Melanoma: ESMO clinical practice guidelines for diagnosis, treatment and follow-up. *Ann Oncol* 2010; 21(Suppl 5): v194-197.
- 13) DABBS D. *Diagnostic Immunohistochemistry*. Second ed. Churchill-Livingston Elsevier; 2006.
- 14) BUSAM KJ, IVERSEN K, COPLAN KC, JUNGBLUTH AA. Analysis of microphthalmia transcription factor expression in normal tissues and tumors, and comparison of its expression with S-100 protein, gp100, and tyrosinase in desmoplastic malignant melanoma. *Am J Surg Pathol* 2001; 25: 197-204.
- 15) BUSAM KJ, KUCUKGOL D, SATO E, FROSINA D, TERUYA-FELDSTEIN J, JUNGBLUTH AA. Immunohistochemical analysis of novel monoclonal antibody PNL2 and comparison with other melanocyte differentiation markers. *Am J Surg Pathol* 2005; 29: 400-406.
- 16) BICHAKJIAN CK, HALPERN AC, JOHNSON TM, FOOTE HOOD A, GRICHNIK JM, SWETTER SM, TSAO H, BARBOSA VH, CHUANG TY, DUVIC M, HO VC, SOBER AJ, BEUTNER KR, BHUSHAN R, SMITH BEGOLKA W, American Academy of Dermatology. Guidelines of care for the management of primary cutaneous melanoma. *american academy of dermatology. J Am Acad Dermatol* 2011; 65: 1032-1047.
- 17) LEO F, CAGINI L, ROCMANS P, CAPPELLO M, GEEL AN, MAGGI G, GOLDSTRAW P, PASTORINO U. Lung metastases from melanoma: When is surgical treatment warranted? *Br J Cancer* 2000; 83: 569-572.
- 18) GARBE C, HAUSCHILD A, VOLKENANDT M, SCHADENDORF D, STOLZ W, REINHOLD U, KORTMANN RD, KETTELHACK C, FRERICH B, KEILHOLZ U, DUMMER R, SEBASTIAN G, TILGEN W, SCHULER G, MACKENSEN A, KAUFMANN R. Evidence and interdisciplinary consensus-based german guidelines: Surgical treatment and radiotherapy of melanoma. *Melanoma Res* 2008; 18: 61-67.
- 19) COOPER JS, CHANG WS, ORATZ R, SHAPIRO RL, ROSES DF. Elective radiation therapy for high-risk malignant melanomas. *Cancer J* 2001; 7: 498-502.
- 20) SEEGENSCHMIEDT MH, KEILHOLZ L, ALTENDORF-HOFMANN A, URBAN A, SCHELL H, HOHENBERGER W, SAUER R. Palliative radiotherapy for recurrent and metastatic malignant melanoma: Prognostic factors for tumor response and long-term outcome: A 20-year experience. *Int J Radiat Oncol Biol Phys* 1999; 44: 607-618.