

# Volumetric evaluations of the maxillary sinus before and post regenerative surgery

A. SCARANO<sup>1,2</sup>, C. CAPPUCCI<sup>1</sup>, B. RAPONE<sup>3</sup>, C. BUGEÀ<sup>1</sup>, F. LORUSSO<sup>1</sup>,  
P. SERRA<sup>1</sup>, M.S. DI CARMINE<sup>1</sup>

<sup>1</sup>Department of Innovative Technologies in Medicine and Dentistry, University of Chieti-Pescara, Chieti-Pescara, Italy

<sup>2</sup>Department of Oral Implantology, Dental Research Division, Colledge Ingà, UNINGÁ, Cachoeiro de Itapemirim, Espírito Santo, Brazil

<sup>3</sup>Interdisciplinary Department of Medicine, "Aldo Moro" University of Bari, Bari, Italy

**Abstract. – OBJECTIVE:** The purpose of this study was to investigate possible differences in the filling of the various recesses of the maxillary sinus after the procedure of sinus floor elevation in relation with the initial volume of the same and if the sinus volume can influence long-term graft dimensions, by using cone beam computed tomography (CBCT) as diagnostic analysis device.

**PATIENTS AND METHODS:** This study included 32 sinuses corresponding to 16 patients referred for bilateral maxillary sinus augmentation procedures needing to increase the volume of the surgical site with the porcine cortical bone for dental implant placement in the posterior maxilla. The sinuses were analyzed by preoperative and postoperative (15 days and 6 months after sinus surgery) cone beam computed tomography.

**RESULTS:** No statistically significant relations were observed between initial sinus dimensions and the entity of the contraction of the graft between T1 (15 days after surgery) and T2 (180 days after surgery). The behavior was the same either for the large sinus (> 15.65 cm<sup>3</sup>) and for the small one (< 15.65 cm<sup>3</sup>). Instead, about the filling of the various sinus recesses, a linear regression model was used to explain the difference between the mean preoperative and postoperative surgical spaces; in most of the samples, the filling of the anterior recess was ~15% of the total volume of the graft, i.e., the minor one among the main recesses.

**CONCLUSIONS:** Our findings suggest that: (1) in the procedure of sinus floor augmentation by a lateral approach with deproteinized porcine bone there are no relations between the initial dimensions of the sinus and the long-term dimensional changes of the graft, and (2) that, among the main recesses of the sinus, the anterior one is generally the less filled.

*Key Words:*

Cone Beam computed tomography, Sinus floor elevations, Dental implants.

## Introduction

The severe atrophy of the posterior area of the maxilla – which is a common consequence of a prolonged condition of edentulous, or rather of a history of trauma or pathology – may preclude the possibility of dental implants placement. Besides, the size of the maxillary sinus increases further, often extending in a large part of the alveolar process, leaving sometimes only an extremely thin bone wall on the lateral and occlusal sides<sup>1</sup>. Many different surgical protocols have been developed to reconstruct the posterior maxilla when bone volume is insufficient. For some decades, sinus augmentation protocol performed using several bone substitutes has been proposed soft<sup>2</sup> and hard tissues augmentation<sup>3-6</sup>. Nowadays several hard tissues augmentation procedures are available to create the ideal surgery space to an implant rehabilitation of these areas, and among these the more predictable and well documented is surely the sinus floor elevation technique<sup>1,7-9</sup>, with a lateral or trans-alveolar approach; the first one is preferred in all cases where the residual alveolar bone height is less than 5/6 mm in the maxillary posterior area<sup>10</sup>.

A surgery approach on the posterior maxilla requires, besides high skills, an accurate study of the sinus anatomy and of the details of the case (for example the septa), in order to avoid complications and high postoperative morbidity<sup>11-13</sup>. According to the literature, it is strongly recommended an analysis of the sinus using computed tomography images, which only can supply the most information about the anatomy and possible pathologic conditions of the maxillary sinus and of the other paranasal sinuses. For this purpose, it is essential to require high coronal sections, which allow visualizing the ostium and its pa-

tency<sup>14</sup>. In particular, in the last decade a new technique, the CBCT, has been proposed as an excellent and low-cost tool, also for its far less radiation compared to a standard CT scan<sup>15-18</sup>. The high definition acquired images are indispensable in a study like this where there are millimeter and submillimeter reference values. The software associated can produce images on three orthogonal planes (axial, coronal, and sagittal), and ortho-panoramic-like sections and 3D reconstructions, which is essential in an implantology study.

For this analysis CBCT images were used for a retrospective evaluation; the aim was to assess the volume of the sinus before and post sinus floor elevation by a lateral access, to establish if the initial volume of the cavity can influence the healing and the integration, and so the contraction overtime, of the graft, and if there are differences of filling among the withdrawals of the sinus. Until now, few studies<sup>19,20</sup> inquired the correlation between dimensions of the sinus and healing process of the graft. Among these, Kolerman et al<sup>19</sup> and Soardi et al<sup>20</sup>, while nobody has investigated the non-uniform filling among the recesses of the sinus after its floor elevation. Comuzzi et al<sup>21</sup> shows that in maxillary sinus augmentation with a lateral approach, xenogeneic bone substitutes of porcine origin, combined or not with alloplastic graft materials, undergo a resorption pattern consisting of an early remodeling, followed by a phase of stability.

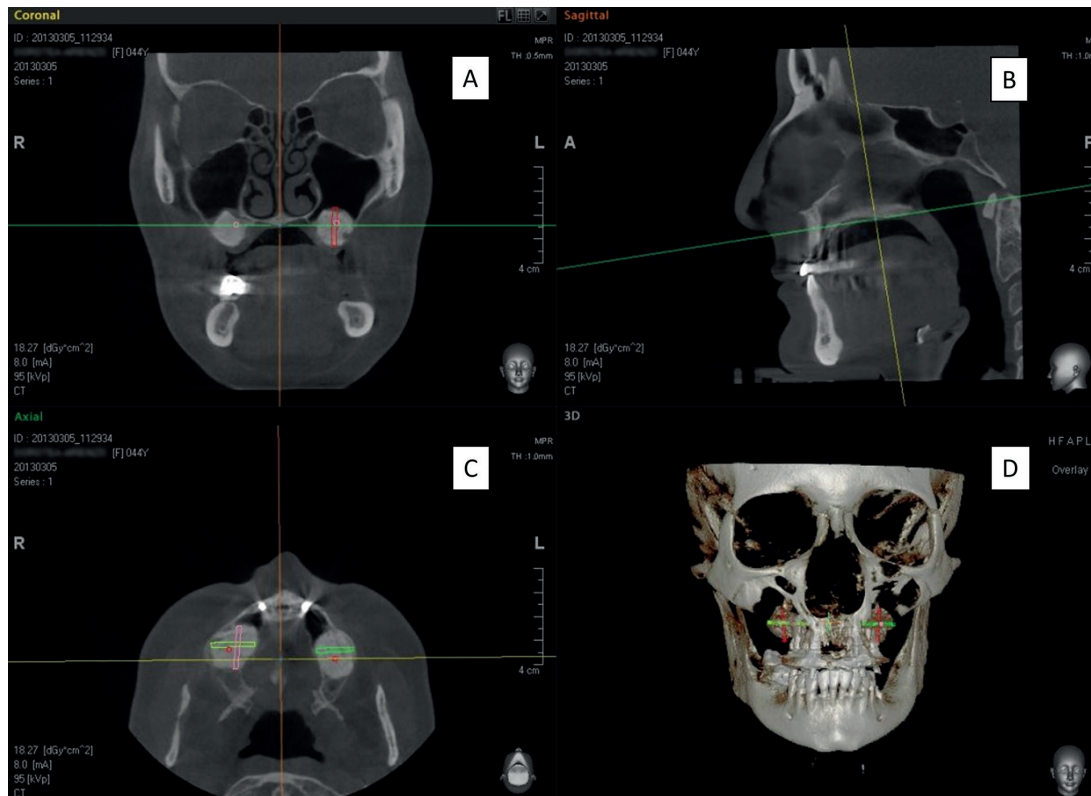
## Patients and Methods

The present study has been conducted in accordance with the principles and guidelines of the Declaration of Helsinki. The informed consent was obtained from all participants included in the study. Sixteen adult patients needing a bilateral sinus floor elevation for implant placement were enrolled in the study, for a total of 32 sinuses treated. They had precise characteristics: non-smokers, with not relevant medical history, without parodontal diseases, and above all, with neither acute nor chronic sinus and nasal pathologies. Their preoperative pharmacologic therapy was: amoxicillina 875 mg and clavulanic acid 125 mg twice/day for 5 days, Argotone<sup>®</sup> nasal drops 3-4 drops/day and Desametasone 0.75 mg 2 cpr/day both for 4 days from 2 days before surgery. Before surgery patients made a CBCT. All the surgical procedures were made under plexus anesthesia with articaine 1:100.000. The sinus floor eleva-

tion was performed as described by Tatum<sup>7</sup>, with a lateral bone anrostomy, removing the access bone traps. The graft material used was porcine cortical particulate bone with particle sizes of 600  $\mu\text{m}$  - 1,000  $\mu\text{m}$  (OsteoBiol<sup>®</sup> Apatos<sup>®</sup>, TecnoSS<sup>®</sup>, Giaveno, Italy) mixed with venous blood of the patient or with sterile saline. In all cases a resorbable collagen membrane (Membrane Evolution<sup>®</sup>, TecnoSS, Giaveno, Italy) was placed on the bone window and a no strain silk 3/0 suture of the edges was realized. Then the subjects continued an antibiotic therapy (amoxicillina and clauvulanic acid 1 g twice/day for 5 days), cortisonic therapy (desametasone 0.75 mg 2 cpr/day for 4 days) and analgesic therapy (nimesulide 100 mg if necessary). Argotone for 2 days after surgery, and an antibacterial mouthwash for oral hygiene. After 15 and 180 days the patients were sent to make another CBCT. Multislice CT images of the maxillary sinus were obtained by the software Syngo CT 2011 (Siemens, Munich, Germany) A VOLUME, measuring the total volume of the sinus and the dimensional changes of the graft material after 6 months. The method for the count of the sequential images was the sum of the areas. This method requires a hand boundary of the perimeter of the graft, using a mouse, on each of the image sections. This procedure was performed by an expert radiologist, calibrated with a Kappa index (k) of 0.79. For each slice, the software calculates the volume in the interested area in  $\text{cm}^3$ , considering the thickness of the slice (Figure 1-3). The single volume of each slice is added to the one of the previous sections. When the graft is completely marked, the volumetric function of the software was activated, and the final result equals the total volume of the graft<sup>15</sup>. These procedures were realized for all the examinations from the first measurement of the sinus volume (T0) to those of the 15<sup>th</sup> (T1) and 180<sup>th</sup> days (T2) (Figure 2, 3).

## Statistical Analysis

The statistical analysis to control the correlation coefficient between the variables amount of the filling of the recesses on one hand, and the sinus volume on the other one was made by the use of the Graph Pad Prism 5 (Graph Pad Software Inc., San Diego, USA). The results were expressed as value  $\pm$  standard deviation (DS). The groups of data were compared through the Two-way ANOVA analysis, followed by the multiple comparison through the Tukey's test.  $p \leq 0.05$  was considered statistically significant.

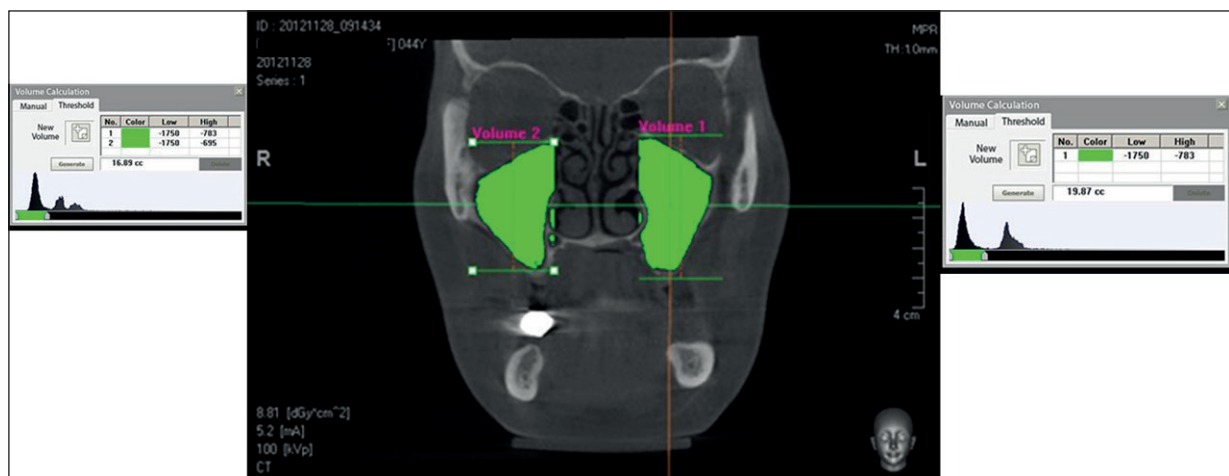


**Figure 1.** CT images of the maxillary sinus after regenerative procedure. **A**, coronal projection, **(B)** sagittal projection, **(C)** axial projection, **(D)** 3D reconstruction.

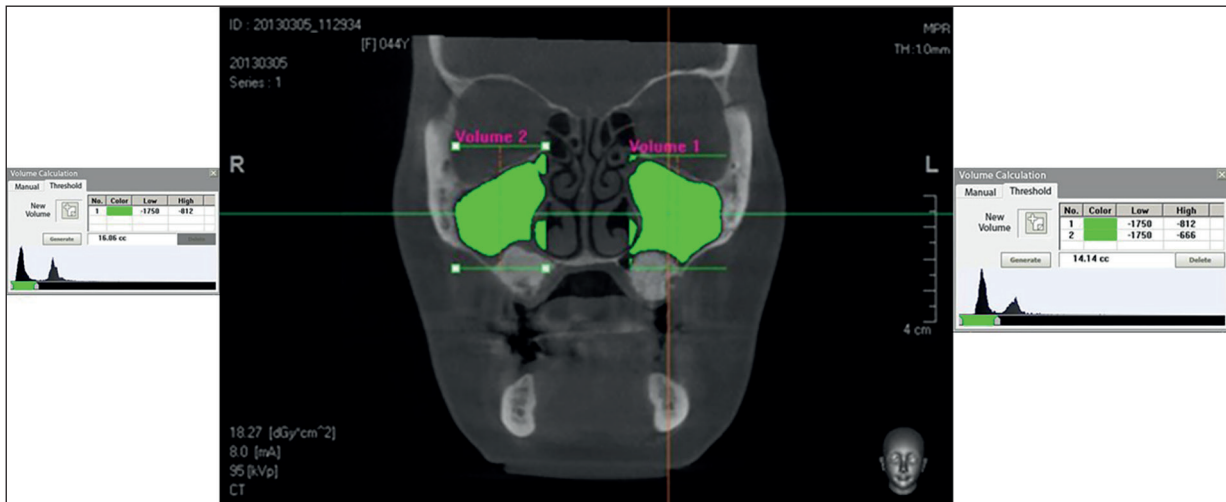
## Results

The data obtained from the samples (32 sinus) were employed to assess (1) the correlation between the volume of the sinus and the osteogenic

potential of the walls of the cavity (so the dimensional changes of the graft overtime), and (2) the differences of filling of the various recesses of the maxillary sinus after sinus floor elevation, and precisely the amount of filling of the anterior



**Figure 2.** Multislice CT images of the maxillary sinus was obtained by the software Syngo CT 2011 A VOLUME, measuring the total volume of the sinus before sinus lifting.



**Figure 3.** Multislice CT images of the maxillary sinus was obtained by the software Syngo CT 2011 A VOLUME, measuring the total volume of the sinus after sinus lifting.

recess in regard to the total volume of the graft. The statistical analysis used was based on the student *t*-test with linear regression and the correlation of Pearson, regardless of age or gender.

The dependent variables were the average of the total volume of the sinus at the (T0) vs. the average of the filling volume of the sinus with the graft at the (T1), precisely of its anterior recess, and after the filling at the (T2) compared to with of the (T1) to assess the contraction of the graft. The average of the sinus volume was 15.65 cm<sup>3</sup> ( $\sigma \pm 3.44$  cm<sup>3</sup>). The smallest sinus volume was 9.59 cm<sup>3</sup>, and the largest one 19.87 cm<sup>3</sup>.

### **I Part**

About the differences of filling with cortical bone among the various recesses of the 32 sinuses analyzed, this study revealed statistically significant results.

In particular, the filling volume of the anterior recess was ~15% compared to the total volume of the graft; instead, the filling defect in the other areas, like the nasal and the lower area, has never been observed.

### **II Part**

About the relation between the initial volume of the sinuses (small and large) and the dimensional changes of the graft noticed by the CBCT at day 180<sup>th</sup> after the surgery compared with that one of day 15<sup>th</sup> after surgery, no statistically results were assessed; so it isn't possible to state an influence of the dimensions of the sinus on the osteogenic

potential of the same (and so on the contraction of the graft material overtime) (Figures 1-3).

## **Discussion**

The results observed in this study can be compared with the results of a few other studies which analyzed the volume of the maxillary sinus filling after sinus floor elevation, and the distribution of this filling in the various recesses of this anatomical cavity in this surgery. Obviously, to be able to assess a study like this, as in all the maxillo-facial surgeries based on the use of the bone graft, it's vital to count on a reliable and accurate method of analysis, like the CBCT able to ensure a good correlation between real measurements of the grafts' volume and those of the software's images. The study made by Kolerman et al<sup>19</sup> found, in a 17% of the samples, a poor osteogenesis which was correlated to very large sinuses, either in medio-lateral and in bucco-palatal extension; in particular, it was suggested that probably, largest sinus could show a lower osteogenic potential, because of the excessive distance between the source of the osteogenic cells and the peripheral angiogenesis. Accordingly, they state that a bigger volume of the sinus corresponds to a major contraction of the graft material overtime, and to a slower new bone formation.

Also, Soardi et al<sup>20</sup> found a correlation between the dimensions of the sinus cavity and the results obtained on histological evaluation on mineral-



ized bone graft used in the sinus floor elevation (in ridge < 2 mm); they used 15 mm distance between the bone ridge and the bucco-palatal walls as references; small sinus had 15 mm distance, while those large one a distance >15 mm. The results were that among the 15 sinuses classified as large, 2 of them required a longer integration time to be able to form an ideal amount of bone formation.

Despite many studies<sup>7,20,22-27</sup> were achieved in relation of the bone grafts' stability used for the sinus floor elevation procedure, it is not yet well defined the role of the total volume of the sinus on the dimensional changes and on the characteristics taken by the graft material overtime.

In particular, in this study the initial volume of 32 sinuses was compared to the volume of the graft material used in the sinus floor elevation procedure: the analysis aimed (1) to find a correlation between the initial dimension of the sinus and the new bone formation of the graft material, and (2) to state the volume of the filling of the anterior recess compared with the filling of the others. The volume of the sinus taken as reference was 15.65 cm<sup>3</sup> ( $\sigma \pm 3.44$ ). The grafts radiographical aspect appeared uniform between right and left side.

The analysis of the samples showed statistically significant results concerning the differences in the recesses' filling; in detail, the filling volume of the anterior recess corresponds to 15% of the total volume of the graft; instead, no defects of filling were ever observed in the nasal and inferior area of the sinus. It was noticed that clinically the phase of the sinus membrane detachment was simple in all areas of the sinus cavity, so that the minor filling of the anterior recess cannot be related to defects or errors of the detachment of the sinus membrane in this area, but rather to the extreme anatomical variability of the anterior recess and to its related difficult surgery management.

Instead, regarding the sinus initial volume influence on the contraction amount of the bone graft, this study produced results opposite to those of other authors previously mentioned; there is no evidence of this correlation.

## Conclusions

There is no clinical evidence that assesses a real correlation between the volume of the sinus and the dimensional changes of the bone graft overtime. Instead, it was found that there are

effective filling differences among the sinus recesses after the procedure of sinus floor elevation. This could be related to the major difficulty to the surgery access in the anterior recess. There are usually no defects or errors in the detachment of the sinus membrane, so the minor filling of the anterior recess can't be related to a surgical recess difficulty but rather to its extreme anatomical variability.

---

### Conflict of Interest

The Authors declare that they have no conflict of interests.

---

### Acknowledgements

None.

---

### Funding

This study did not receive any specific grant from funding agencies in the public, commercial, or not-for-profit sectors.

---

### Availability of Data and Materials

All data generated or analyzed during this study are included in this article.

---

### Authors' Contribution

All authors participated in the literature review and in the surgery's performance. All authors read and approved the final manuscript.

---

### Ethics Approval

This study was conducted in full accordance with ethical principles, including the World Medical Association Declaration of Helsinki (<https://www.wma.net/wp-content/uploads/2018/07/DoH-Oct2008.pdf>) and the additional requirements of Italian law. The study was approved by the Biomedical Research Ethics Committee of the Provinces of Chieti and Pescara, No. 1881.

---

### Informed Consent

Written informed consent was obtained from the patients enrolled in the study.

---

### ORCID ID

A. Scarano: 0000-0003-1374-6146; M.S. Di Carmine: 0000-0003-4849-9982; B. Rapone: 0000-0002-0062-6594; C. Bugea: 0000-0002-9960-9830; F. Lorusso: 0000-0002-2660-9231.

## References

- 1) Boyne PJ, James RA. Grafting of the maxillary sinus floor with autogenous marrow and bone. *J Oral Surg* 1980; 38: 613-616.
- 2) Scarano A, Barros RRM, Iezzi G, Piattelli A, Novaes AB. Acellular dermal matrix graft for gingival augmentation: a preliminary clinical, histologic, and ultrastructural evaluation. *J Periodontol* 2009; 80: 253-259.
- 3) Scarano A, Piattelli A, Polimeni A, Di Iorio D, Carinci F. Bacterial adhesion on commercially pure titanium and anatase-coated titanium healing screws: an in vivo human study. *J Periodontol* 2010; 8: 1466-1471.
- 4) Borges FL, Dias RO, Piattelli A, Onuma T, Gouveia Cardoso LA, Salomão M, Scarano A, Ayub E, Shibli JA. Simultaneous sinus membrane elevation and dental implant placement without bone graft: a 6-month follow-up study. *J Periodontol* 2011; 82: 403-412.
- 5) Rapone B, Inchingolo AD, Trasarti S, Ferrara E, Qorri E, Mancini A, Montemurro N, Scarano A, Inchingolo AM, Dipalma G, Inchingolo F. Long-Term Outcomes of Implants Placed in Maxillary Sinus Floor Augmentation with Porous Fluorohydroxyapatite (Algipore® FRIOS®) in Comparison with Anorganic Bovine Bone (Bio-Oss®) and Platelet Rich Plasma (PRP): A Retrospective Study. *J Clin Med* 2022; 11: 2491.
- 6) Wang X, Sun L, Wang L, Shi S, Zhang S, Song Y. Predictors of peri-implant bone remodeling outcomes after the osteotome sinus floor elevation: a retrospective study. *BMC Oral Health* 2022; 22: 622.
- 7) Tatum H. Maxillary and Sinus Implant Reconstructions. *Dent Clin North Am* 1986; 30: 207-29.
- 8) Misch CE. Maxillary sinus augmentation for endosteal implants: organized alternative treatment plans. *Int J Oral Implantol* 1987; 4: 49-58.
- 9) Scarano A, de Oliveira PS, Traini T, Lorusso F. Sinus Membrane Elevation with Heterologous Cortical Lamina: A Randomized Study of a New Surgical Technique for Maxillary Sinus Floor Augmentation without Bone Graft. *Materials* 2018; 11: 1457.
- 10) Pjetursson BE, Tan WC, Zwahlen M, Lang NP. A systematic review of the success of sinus floor elevation and survival of implants inserted in combination with sinus floor elevation. *J Clin Periodontol* 2008; 35: 216-240.
- 11) Chanavaz M. Maxillary sinus: anatomy, physiology, surgery, and bone grafting related to implantology--eleven years of surgical experience (1979-1990). *J Oral Implantol* 1990; 16: 199-209.
- 12) Ulm CW, Solar P, Krennmair G, Matejka M, Watzek G. Incidence and suggested surgical management of septa in sinus-lift procedures. *Int J Oral Maxillofac Implants* 1995; 10: 462-465.
- 13) Scarano A, Carinci F, Lorusso F, Festa F, Bevilacqua L, Santos de Oliveira P, Maglione M. Ultrasonic vs Drill Implant Site Preparation: Post-Operative Pain Measurement Through VAS, Swelling and Crestal Bone Remodeling: A Randomized Clinical Study. *Materials* 2018; 11: 2516.
- 14) Scarano A, Lorusso F, Arcangelo M, D'Arcangelo C, Celletti R, de Oliveira PS. Lateral Sinus Floor Elevation Performed with Trapezoidal and Modified Triangular Flap Designs: A Randomized Pilot Study of Post-Operative Pain Using Thermal Infrared Imaging. *Int J Environ Res Public Health* 2018; 15: 1277.
- 15) Liang X, Jacobs R, Hassan B, Li L, Pauwels R, Corpas L, Souza PC, Martens W. A comparative evaluation of Cone Beam Computed Tomography (CBCT) and Multi-Slice CT (MSCT) Part I. On subjective image quality. *Eur J Radiol* 2010; 75: 265-269.
- 16) Loubele M, Bogaerts R, Van Dijk E, Pauwels R, Vanheusden S, Suetens P, Marchal G, Sanderink G, Jacobs R. Comparison between effective radiation dose of CBCT and MSCT scanners for dentomaxillofacial applications. *Eur J Radiol* 2009; 71: 461-468.
- 17) Ludlow JB, Davies-Ludlow LE, Brooks SL, Howerton WB. Dosimetry of 3 CBCT devices for oral and maxillofacial radiology: CB Mercuray, NewTom 3G and i-CAT. *Dent Radiol* 2006; 35: 219-226.
- 18) Ludlow JB, Ivanovic M. Comparative dosimetry of dental CBCT devices and 64-slice CT for oral and maxillofacial radiology. *Oral Surg Oral Med Oral Pathol Oral Radiol Endod* 2008; 106:1 06-114.
- 19) Kolerman R, Tal H, Moses O. Histomorphometric Analysis of Newly Formed Bone After Maxillary Sinus Floor Augmentation Using Ground Cortical Bone Allograft and Internal Collagen Membrane. *J Periodontol* 2008; 79: 2104-2111.
- 20) Maria Soardi C, Spinato S, Zaffe D, Wang HL. Atrophic maxillary floor augmentation by mineralized human bone allograft in sinuses of different size: a histologic and histomorphometric analysis: Mineralized human bone allograft for sinus augmentation. *Clin Oral Impl Res* 2011; 22: 560-566.
- 21) Comuzzi L, Tumedei M, Piattelli A, Tartaglia G, Del Fabbro M. Radiographic Analysis of Graft Dimensional Changes after Lateral Maxillary Sinus Augmentation with Heterologous Materials and Simultaneous Implant Placement: A Retrospective Study in 18 Patients. *Materials* 2022; 15: 3056.
- 22) Uchida Y, Goto M, Katsuki T, Akiyoshi T. Measurement of the maxilla and zygoma as an aid in installing zygomatic implants *J Oral Maxillofac Surg* 2001; 59: 1193-1198.
- 23) Wanschitz F, Figl M, Wagner A, Rolf E. Measurement of volume changes after sinus floor augmentation with a phycogenic hydroxyapatite. *Int J Oral Maxillofac Implants* 2006; 21: 433-438.

- 24) Kirmeier R, Payer M, Wehrschoetz M, Jakse N, Platzer S, Lorenzoni M. Evaluation of three-dimensional changes after sinus floor augmentation with different grafting materials. *Clin Oral Implants Res* 2008; 19: 366-372.
- 25) Kim ES, Moon SY, Kim SG, Park HC, Oh JS. Three-dimensional volumetric analysis after sinus grafts. *Implant Dent* 2013; 22: 170-174.
- 26) Pesce P, Menini M, Canullo L, Khijmatgar S, Modenese L, Gallifante G, Del Fabbro M. Radiographic and Histomorphometric Evaluation of Biomaterials Used for Lateral Sinus Augmentation: A Systematic Review on the Effect of Residual Bone Height and Vertical Graft Size on New Bone Formation and Graft Shrinkage. *J Clin Med* 2021; 10: 4996.
- 27) Goker F, Beretta P, Baj A, Bolzoni AR, Maiorana C, Beltramini G, Russillo A, Greco Lucchina A, Rossi DS, Polo MRD, Del Fabbro M, Mortellaro C, Gianni AB. Oral rehabilitation of oncology patients with dental implants after reconstruction surgery with autogenous flaps. *Eur Rev Med Pharmacol Sci* 2022; 26 (3 Suppl): 51-61.