

Clinical application of solitaire AB stents in the embolization of intracranial aneurysms

Y.-F. CUI, H. XU, H.-T. LIU, Y. WANG

Department of Interventional Radiology, The Affiliated Hospital of Xuzhou Medical College, Xuzhou, China

Abstract. – OBJECTIVE: To evaluate the clinical value of Solitaire AB stents in the embolization of intracranial aneurysms.

PATIENTS AND METHODS: Solitaire AB stents were applied in treating 69 aneurysms in 65 patients. Among them, there were 67 “wide neck” aneurysms and two “narrow neck” aneurysms. Of the 69 aneurysms, there were 40 aneurysms in the posterior communicating artery, 13 in the ophthalmic artery segment, one in the cavernous segment of the internal carotid artery, three in the middle cerebral artery, one in the anterior communicating artery, eight in the vertebral artery, and three in the basilar artery. The treatment techniques used included transposition, parallel technique, post-release technique, and salvage stenting.

RESULTS: Immediate angiographic results showed complete thrombosis in 63 cases, residual aneurysm neck in two cases and partial embolism in four cases. Intraoperative aneurysm rupture was found in two cases, of which bleeding was stopped with continued filling. Postoperative hydrocephalus cerebrospinal fluid shunt was performed in one case. Coil shift was observed in two cases. No further bleeding cases occurred during the clinical follow-up. Of 14 patients who had undergone angiographic follow-up, three cases had recurrence and one case received re-embolization.

CONCLUSIONS: Solitaire AB stent is clinically feasible when applied for the embolization of intracranial aneurysms using multiple techniques and, thus, warrants clinical promotion.

Key Words:

Intracranial aneurysm, Stent, Embolization.

Introduction

With the development of science and surgical treatment techniques, coil embolization treatment has been proven to be effective and reliable for intracranial aneurysms. The use of stents does not only facilitate embolization but also promotes

healing of the aneurysm neck. With the application of the new electric detachable Solitaire AB stents, the embolization of intracranial aneurysms has been further promoted. We have been using Solitaire AB stents in the treatment of intracranial aneurysms since 2010, with satisfying results, which are summarized below.

Patients and Methods

General Data

A total of 65 patients with 69 aneurysms were treated, including 15 men and 50 women aged 22-81 years, with a mean age of 58.5 ± 11.3 years. Among them, there were 67 “wide neck” aneurysms (neck > 4 mm or aneurysm neck: aneurysm > 1: 2), and two “narrow neck” aneurysms.

Clinical Manifestations

Unruptured aneurysms were found in 16 cases, of which three cases showed oculomotor nerve palsy, and subarachnoid hemorrhage in 49 cases. For the 49 patients with subarachnoid hemorrhage, the Hunt-Hess grades I in 8 cases, Hunt-Hess grades II in 39 cases, and Hunt-Hess grades III in 2 cases.

Imaging Examinations

All patients underwent head computerized tomography (CT) scans. Of the 49 cases with subarachnoid hemorrhage, there were 20 subjects of Fisher grade 2, 27 of grade 3, and two of grade 4. All patients received digital subtraction angiogram to identify the spatial relationship between the aneurysms and the parent vessels and branches through three-dimensional reconstruction.

Aneurysm Sites

Of the 69 aneurysms, there were 40 aneurysms in the posterior communicating artery, 13 in the

ophthalmic artery segment, one in the cavernous segment of the internal carotid artery, three in the middle cerebral artery, one in the anterior communicating artery, eight in the vertebral artery, and three in the basilar artery.

Treatment

Patients with unruptured aneurysms received preoperative aspirin 100 mg/d and clopidogrel 75 mg/d for 3 days before surgery. Those with ruptured aneurysms received clopidogrel 300 mg through a gastric tube after anesthetized. The following techniques were used: transposition, where the stent was released first, and the microcatheter was inserted through the stent mesh for aneurysm embolization; parallel technique, where the stent microcatheter (Rebar-18, Rebar-27, EV3, Irvine, CA, USA) and the releasing microcatheter coil (Silverspeed-10, EV3, Irvine, CA, USA; Traxcess, MicroVention, Fujinomiya, Shizuoka, Japan) were placed at the same time, followed by partial release of the stent to cover the neck of the aneurysm, and the coils were then released for embolization before completely releasing and detaching the stent; post-release technique, where the microcatheter and the releasing microcatheter coil were placed at the same time, and one or more coils were inserted through the microcatheter before the release of the stent until satisfying embolization; and salvage stenting, where the stent was not intended to be used, though detachment or protrusion of coils to the parent artery made the placement necessary. Postoperative conventional treatment was prescribed to prevent vasospasm, in combination with symptomatic and supportive treatment with oral clopidogrel 75 mg/d for 6 weeks. Long-term aspirin 100 mg/d was administered.

Postoperative Evaluation and Follow-up

The surgery procedure, surgery-related complications, angiographic, and clinical follow-up results were evaluated. The immediate effect was graded using the modified Raymond system¹. The immediate postoperative angiography showed complete thrombosis: no contrast agent in the aneurysm sac; residual aneurysm neck: contrast agent in the neck; partial embolism: visible intraaneurysmal agent. The patients were recommended to receive digital subtraction angiography (DSA) follow up 6 months to 1 year after surgery. When angiographic follow-up showed a contrast agent filling increased by 10%, recanal-

ization was considered. A filling increase of < 10% was considered stable. Clinical follow-up was completed by telephone interviews. Prognostic classification was performed using the Modified Rankin Scale (mRS): 0 - No symptoms. 1 - No significant disability. Able to carry out all usual activities, despite some symptoms. 2 - Slight disability. Able to look after own affairs without assistance, but unable to carry out all previous activities. 3 - Moderate disability. Requires some help, but able to walk unassisted. 4 - Moderately severe disability. Unable to attend to own bodily needs without assistance, and unable to walk unassisted. 5 - Severe disability. Requires constant nursing care and attention, bedridden, incontinent. 6 - Dead.

Results

Therapeutic Effects and Complications

All 69 aneurysms were completely embolized. All stents were successfully placed in the necessary locations. Among them, six aneurysms were treated with the transposition technique, 49 with the parallel technique (Figure 1), five with the post-release technique (Figure 2), and nine with the salvage stenting technique (Figure 3), include narrow-necked aneurysms. Ten patients were treated with stents in a diameter of 4 mm, and 59 were treated with 6 mm stents. Immediate angiographic results showed complete thrombosis in 63 cases, residual aneurysm neck in two cases and partial embolism in four cases. Operation-related complications included intraoperative aneurysm rupture in two cases, of which bleeding was stopped with continued filling. Immediate postoperative CT scan showed a small amount of subarachnoid hemorrhage. Postoperative hydrocephalus cerebrospinal fluid shunt was performed in one case. Coil shift was observed in two cases, both being the last coil detached (diameter 1.5 mm) from the stent mesh into the supply artery, followed by drifting into the parent artery cortical branch. No treatment was given, and no neurological dysfunction was observed after surgery. One case of death was noted after surgery.

Prognostic Evaluation

All patients received clinical follow-up for 1-12 months. No further bleeding cases occurred. The mRS 0 in 50 cases, mRS 1 in 12 cases, mRS 2 in 1 cases, mRS 4 in 1 cases, mRS 6 in 1 cases.

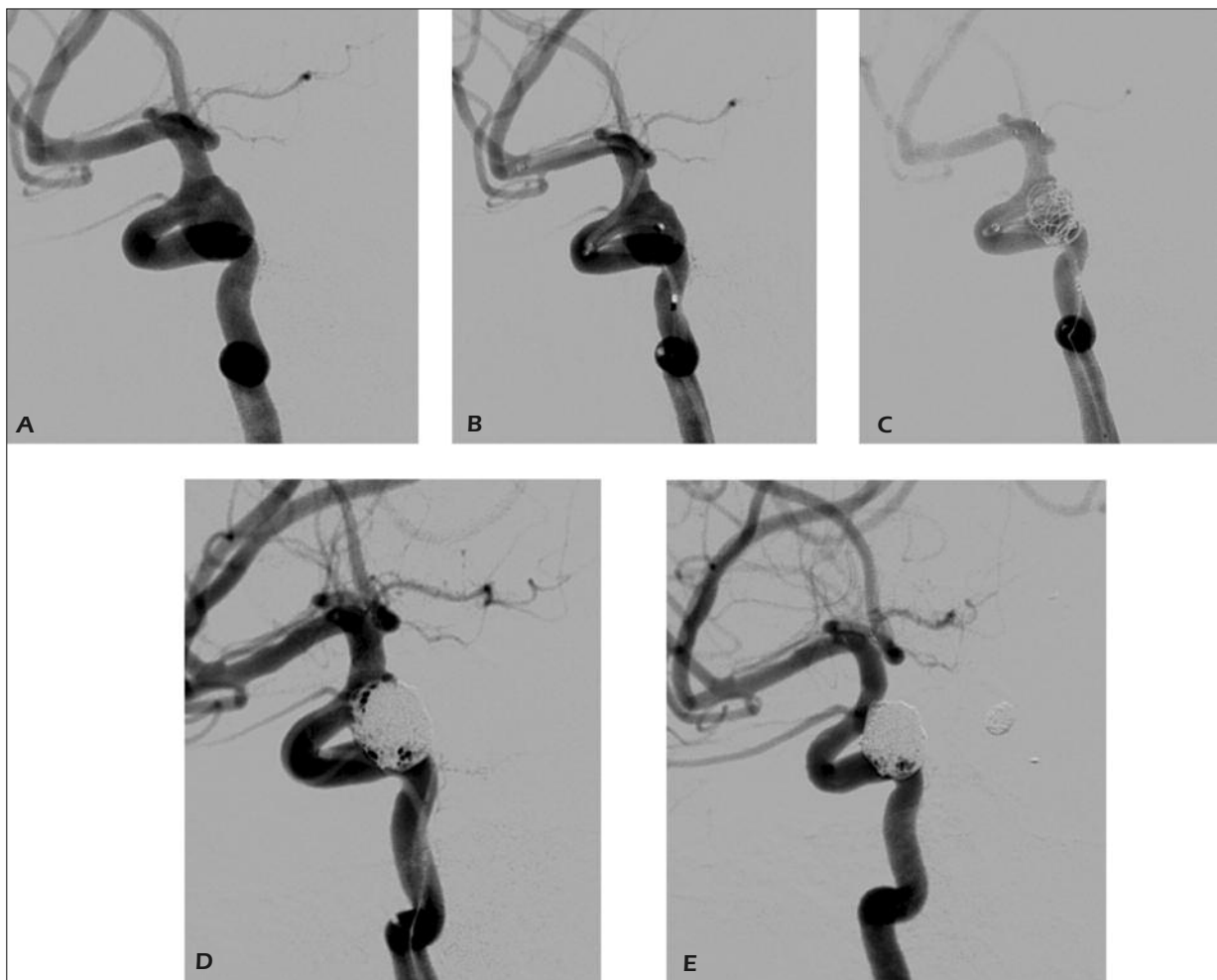


Figure 1. *A*, Pre-operative angiography shows a right posterior communicating artery aneurysm. *B*, Simultaneous placement of the stent and the microcatheter for embolization. *C*, Release of the stent, followed by the release of the coil. *D*, Post-operative angiography. *E*, Angiographic follow-up 6 months after the surgery.

Angiographic Follow-up Results

14 cases received DSA follow-up for 8.5 ± 4.6 months. Three cases had recurrence, including one case with aneurysm in the middle cerebral artery who received re-embolization. The other two cases were subject to continued follow-up.

Discussion

In 1997, Higashida et al² and Liu et al³ separately reported in the use of sphere expanding coronary stents combined with coil embolization for the treatment of intracranial fusiform aneurysms. After that, cranial aneurysm treatment entered a new era, followed by the emergence of a variety of intracranial stents, includ-

ing Neuroform stent (Boston Scientific/Target, Fremont, CA, USA), LEO stent (BALT, Montmorency, France), SOLO stent (EV3, Irvine, CA, USA) and Enterprise stent (Cordis Neurovascular, Miami, FL, USA), as well as the EV3's Solitaire AB stents in recent years. Stenting strategy has evolved from the early "microcatheter transposition stent technique (Mesh)" and "stent stable microcatheter technique (Jailing)"⁴ to a variety of new techniques, including simple stent technique⁵, stent parallel delivery technique⁶, salvage stenting technique, semi-releasing technique⁷, post-release technique⁸, "Y-shaped stenting technique"^{9,10} and "ice cream technique"¹¹. Among them, the semi-releasing and post-release techniques have been widely used.

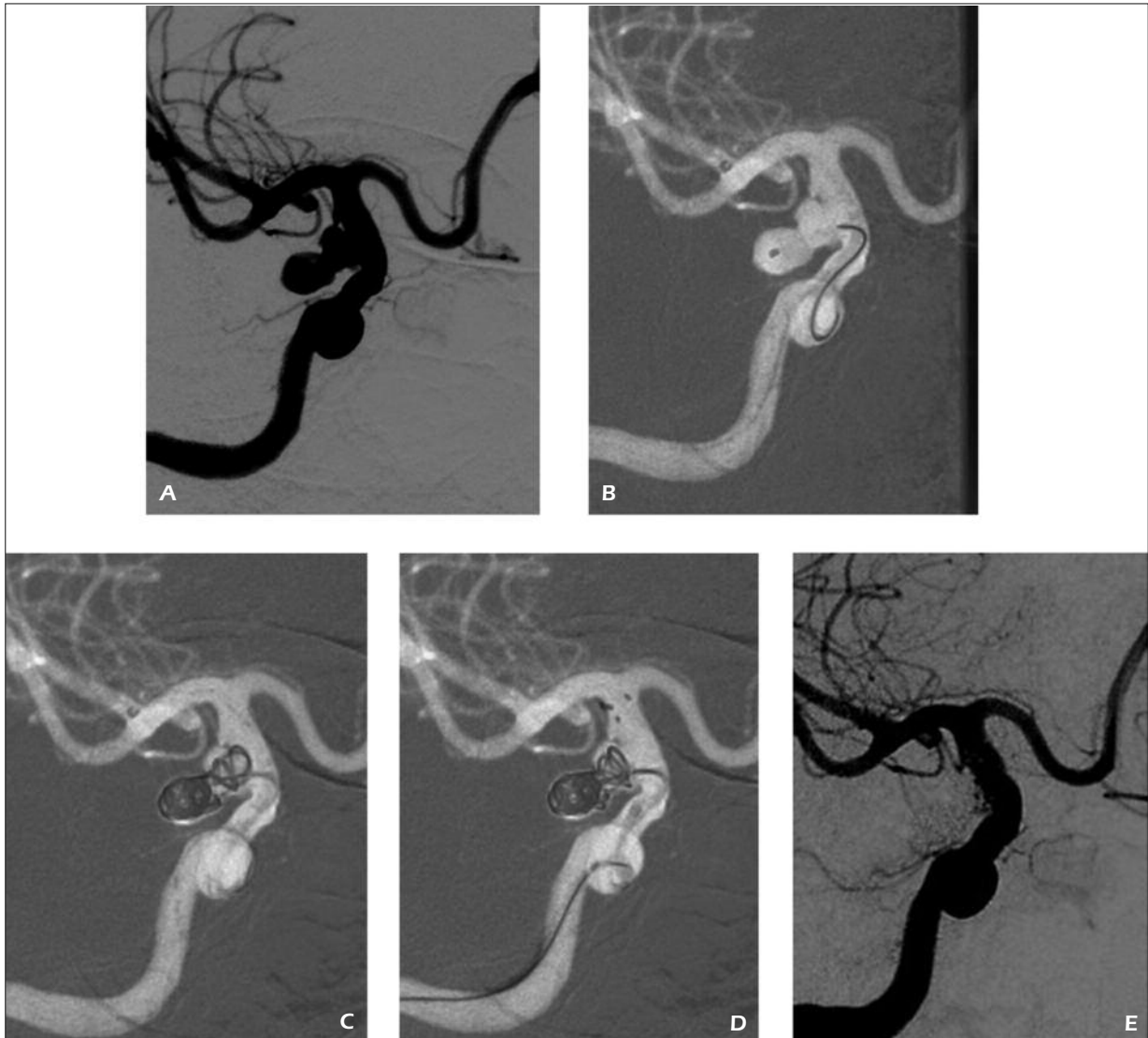


Figure 2. *A*, Pre-operative angiography shows a posterior communicating artery aneurysm. *B*, Placement of the stent microcatheter and the microcatheter for embolization. *C*, Protrusion of coils to the parent artery after the partial release of the coil. *D*, Release of the stent using the post-release technique. *E* Angiography following the complete embolization.

The Solitaire AB stent is a self-expanding stent with a single open end and closed mesh design. This design incorporates the advantages of both the closed mesh and open mesh. Due to the single-sided openness, it is easy to go through twisted vessels, while the closed mesh design empowers it with increased radial strength and durability. After the stent is fully released, it can be recovered twice before detachment for reselecting the location or choose the best location. There are three distal markers and one proximal marker on a 4-mm stent, or four distal markers and one proximal radiopaque marker on a 6-mm

stent, providing good visibility. The proximal 1 cm is a tapered, non-effective length. The 4-mm stent is pushed through a 0.016-inch guide wire through a 0.021-inch microcatheter. The 6-mm stent is pushed through a 0.016-inch guide wire through a 0.027-inch microcatheter. The release lever is pushed to retract the microcatheter, and when the microcatheter distal marker is below the stent proximal marker, complete release is indicated. After the release, the effective length of the stent is across the aneurysm neck, with 4 mm or more at both ends. The Solitaire AB stent employs the electric detachment technology using

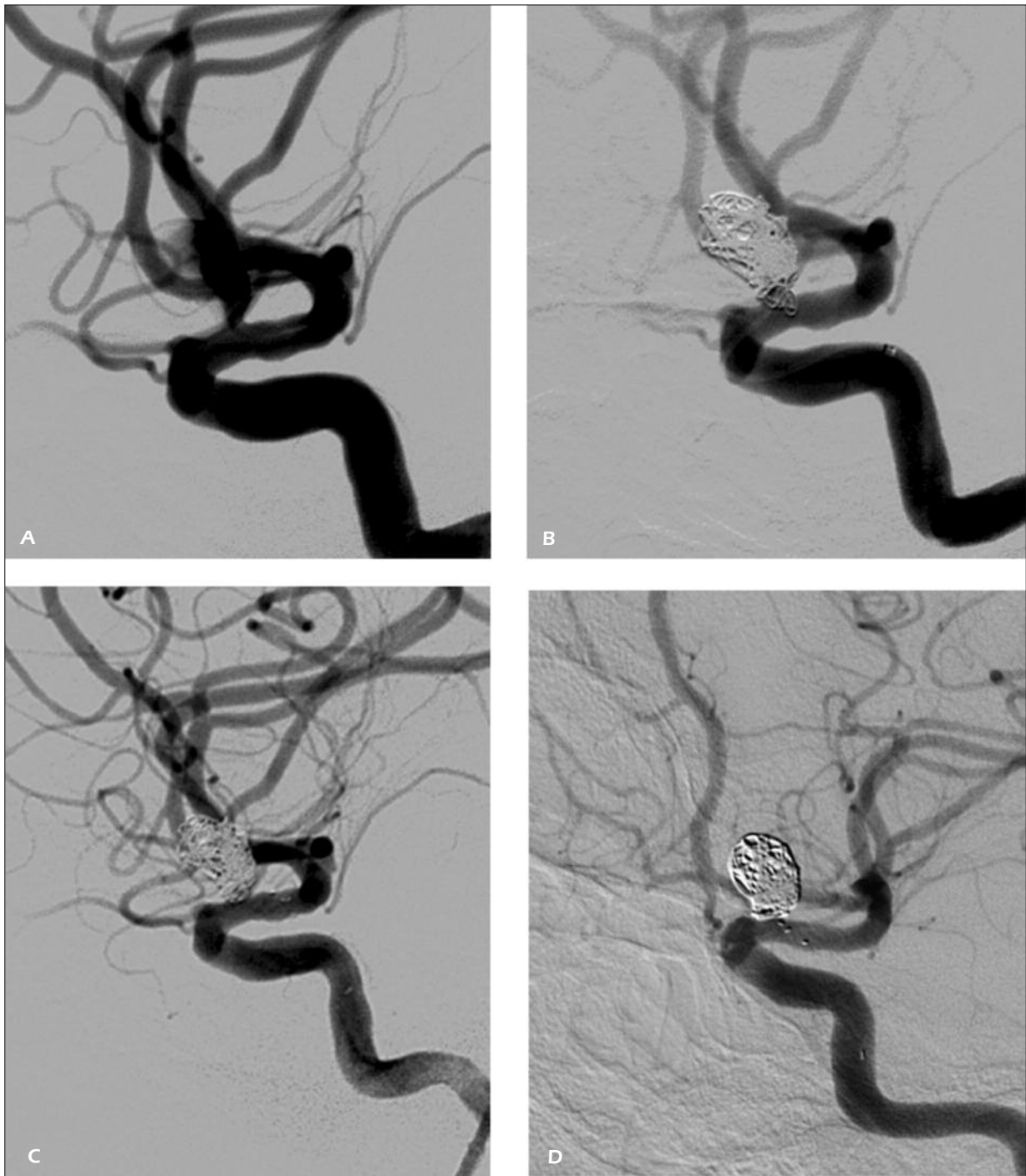

Figure 3. *A*, Pre-operative angiography shows a carotid-ophthalmic aneurysm. *B*, Intra-operative angiography shows the protrusion of coils to the parent artery. *C*, After the salvage stent placement. *D*, Angiographic follow-up 9 months after the surgery.

the NDS-2 professional detachment box, allowing for detachment both before and after the release of coils.

Currently, there are retrievable stents including Enterprise stents, Leo stents and Solitaire

AB stents. Leo stents are prone to shift in the semi-released state, and there are no recyclable positioning markers, making it difficult to determine the recoverable critical point during surgery. Meanwhile, its poor compliance makes

it unable to open in continuously curved vessels¹². Enterprise stents can be recovered once when they have not been released over 70%. Only Solitaire AB stents can be recovered multiple times after full release before detachment. This unique advantage of Solitaire AB stents enables us to control the degree and position of stent release during surgery. In the present cohort, six patients had their stents detached before delivery of coils because ease of placement of microcatheters. The remaining patients were treated with the parallel technique or post-release technique, in which microcatheters were in place at the same time with stent microcatheters, and the stents were released as soon as they covered the aneurysm neck before embolization. During aneurysm embolization, if the microcatheter mobility is found to be limited, the stent is partially retrieved to facilitate the motion of the microcatheter and avoid bursting of the aneurysm when the coil is released. If the microcatheter is found to drop from the aneurysm, the stent is also partially retrieved and the microcatheter is sent into the aneurysm or aneurysm neck again. It is reported that the semi-release technique will create a wedge-shaped space between the stent and the aneurysm, allowing for coils with a larger diameter or length during embolization. As the embolization reaches a certain density, the stent can be released gradually while further filling up the coil until it is fully released. In this way, the coil can be pressed into the aneurysm body, increasing the coil density at the aneurysm neck, helping to improve the aneurysm embolization density. However, since Solitaire AB stent itself is not visible under X-ray, and only the proximal and distal markers are radiopaque, it is technically difficult to achieve the similar procedure. Therefore, most patients were treated with parallel and post-release techniques. With the post-release technique, coils with a larger diameter or length can be used during embolization. As the embolization reaches a certain density, the stent can be released gradually while further filling up the coil until it is fully released. In this way, the coil protruding to the supply artery can be pressed into the aneurysm body, significantly increasing the coil density at the aneurysm neck, helping to improve the dense aneurysm embolization rate. Meanwhile, release of the stent after the aneurysm is partially or completely filled up can ensure that the coil is not protruded into the supply artery, and help forming a stable coil shape to reduce aneurysm

recurrence. Due to the large mesh of the Solitaire AB stent, for better neck embolization, placement of one or more three-dimensional coils can achieve both better coverage of the aneurysm neck and prevention of prolapse or escape of the coil. The two cases of coil shift in the study were mainly because the basket coils failed to form baskets well, and the little coils released at last also failed to wind well around the previous coils. Since the shifting coils are small and have drifted to the end of the cortical branches, no treatment was given.

Stent-assisted coil embolization of wide-necked aneurysms has three major roles: First, the stent is used as a support for the aneurysm neck, so that the coil is fixed in the aneurysm cavity without protruding inside. With the support of the stent, dense aneurysm embolization is easier to achieve¹³. Second, after the release of the stent, blood flow in the aneurysm sac is significantly slowed down, thereby, reducing the shear stress to the aneurysm wall, while also modifying the hemodynamic characteristics of the parent artery^{14,15}. Third, after placement of the stent and filling up with the coil, the stent mesh is damaged and embedded into the aneurysm wall to stimulate synthesis of fibroblasts within the arterial wall, which secrete collagen fibers to cover the stent, while thrombi in the aneurysm, and stent and coil wire at the opening become the scaffolding of collagen fibers. As the collagen fibers gradually grow toward the opening and climb to cover it along the mesh and coil, the latter two in turn facilitate the growth, which eventually close the aneurysm¹⁶.

The release technique for Solitaire AB stents is different from those for Neuroform stents, Leo stents and Enterprise stents, which are supported by supporting wires that facilitate the control of placement location. In contrast, without the support guide wire, Solitaire AB stents are not delivered until the accurate position is determined after the microcatheter is retreated, and the stent is released from the distal end, which slightly tilts forward and attach closely to the vascular wall. The selection of Solitaire AB stents is also different from the other brands. Due to its single-sided open design, when the stent diameter is greater than that of the vessel, the stent will partially overlap. Therefore, when choosing the stent, one with a diameter 1-2 mm larger than the vessel can be considered. Care should be given during release as the proximal 1 cm is tapered and non-effective length.

It is reported that Solitaire AB stents can be used to treat brain aneurysm due to coil displacement¹⁷. In the present cohort, since the coils drifted to the cortical artery, they were not removed.

Conclusions

The promotion of Solitaire AB stents has made stent-assisted coil aneurysm treatment easier to operate, safer, and more effective. Its long-term efficacy should be further confirmed in follow-up studies with a large sample.

Conflict of Interest

The Authors declare that there are no conflicts of interest.

References

- 1) DANIEL R, GENEVIÈVE M, JEAN R. Endovascular treatment of unruptured aneurysms. *Stroke* 2001; 32: 1998-2004.
- 2) HIGASHIDA RT, SMITH W, GRESS D, URWIN R, DOWD CF, BALOUSEK PA, HALBACH VV. Intravascular stent and endovascular coil placement for a ruptured fusiform aneurysm of the basilar artery. Case report and review of the literature. *J Neurosurg* 1997; 87: 944-949.
- 3) LIU JM, HONG B, XU Y, QIN YW, ZHAO WY, ZHOU XP, HUANG QH. Treatment of an intracranial fusiform vertebral artery aneurysm with endovascular stent and Guglielmi detachable coils. *Acad J Sec Mil Med Univ* 2000; 21: 1052-1054.
- 4) LIU JM, XU Y, HONG B, ZHAO R, HUANG QH, ZHANG L, ZHAO WY. Treatment of intracranial aneurysms with self-expanding stent and coils. *J Intervent Radiol* 2004; 13: 196-200.
- 5) ZENTENO MA, SANTOS-FRANCO JA, FREITAS-MODENESI JM, GÓMEZ C, MURILLO-BONILLA L, ABURTO-MURRIETA Y, DÍAZ-ROMERO R, NATHAL E, GÓMEZ-LLATA S, LEE A. Use of the solo stenting technique for the management of aneurysms in the posterior circulation in a prospective series of 20 patients. *J Neurosurg* 2008; 108: 1104-1118.
- 6) BENNDORF G, KLUCZNIK RP, MEYER D, STROTHER CM, MAWAD ME. "Cross-over" technique for horizontal stenting of an internal carotid bifurcation aneurysm using a new self-expandable stent: technical case report. *Neurosurgery* 2006; 58(1 Suppl): ONS-E172.
- 7) YANG PF, LIU JM, HONG B, YANG ZG, XU Y, ZHAO WY, HUANG QH. Stent semi-deploying technique for the treatment of complex intracranial aneurysms. *J Intervent Radiol* 2009; 18: 723-726.
- 8) HUANG QH, LIU JM, YANG PF, HONG B, XU Y. Endovascular treatment of intracranial aneurysm using stenting after coiling technique. *Chin J Cerebrovasc Disc (Electronic Edition)* 2009; 3: 208-213.
- 9) PEREZ-ARJONA E, FESSLER RD. Basilar artery to bilateral posterior cerebral artery "Y stenting" for endovascular reconstruction of wide neck basilar apex aneurysm: Report of three cases. *Neurol Res* 2004; 26: 276-281.
- 10) SANI S, LOPES DK. Treatment of a middle cerebral artery bifurcation aneurysm using a double neuroform stent Y configuration and coil embolization: technical case report. *Neurosurgery* 2005; 57(1 Suppl): E209.
- 11) HOROWITZ M, LEVY E, SAUVAGEAU E, GENEVRO J, GUTERMAN LR, HANEL R, WEHMAN C, GUPTA R, JOVIN T. Intra/extra-aneurysmal stent placement for management of complex and wide-necked-bifurcation aneurysms: eight cases using the waffle cone technique. *Neurosurgery* 2006; 58(4 Suppl 2): ONS-258-262.
- 12) YANG ZG, LIU JM, XU Y, HUANG QH, HONG B, ZHAO WY, ZHAO R. Application of a novel retrievable self-expanding stent in intracranial aneurysm treatment. *J Intervent Radiol* 2008; 17: 459-462.
- 13) BIONDI A, JANARDHAN V, KATZ JM, SALVAGGIO K, RIINA HA, GOBIN YP. Neuroform stent-assisted coil embolization of wide-neck intracranial aneurysms: strategies in stent deployment and midterm follow-up. *Neurosurgery* 2007; 61: 460-469.
- 14) LIEBER BB, GOUNIS MJ. The physics of endoluminal stenting in the treatment of cerebrovascular aneurysms. *Neurol Res* 2002; 24: 33-42.
- 15) CANTON G, LEVY, LASHERAS JC. Hemodynamic changes due to stent placement in bifurcating intracranial aneurysms. *J Neurosurg* 2005; 103: 146-155.
- 16) ZHANG X, LIU JM, ZHOU XP, XU Y, HONG B, HUANG QH, ZHANG L, SHE JG, ZHAO R. Histopathological study of aneurysm after treatment with stent and coil in a canine model. *Chin J Neurosurg* 2007; 23: 585-588.
- 17) WANG W, LI MH, GU BX. Solitaire AB stent management of coil migration associated with stent-assisted coiling of a cerebral aneurysm: report of one case. *J Intervent Radiol* 2010; 19: 804-806.