

Characteristics of pleomorphic adenomas, adenolymphomas, and malignant tumors of the salivary glands on color doppler ultrasonography and contrast enhanced ultrasonography

L.-P. JIANG

Department of Ultrasonography, The First Affiliated Hospital of Nanchang University, Nanchang, China

Abstract. – **OBJECTIVE:** To provide a comprehensive description of the quantitative and qualitative characteristics of pleomorphic adenomas, adenolymphomas, and malignant tumors of the salivary glands on color doppler ultrasonography and contrast-enhanced ultrasonography (CEUS).

PATIENTS AND METHODS: 64 patients with 35 pleomorphic adenomas, 24 adenolymphomas, and 12 malignant tumors were enrolled in this study. All patients were examined by color doppler ultrasonography and CEUS before operation. In color Doppler ultrasonography, degree of vascularity, peak systolic velocity (PSV) and the vascular resistance index (RI) were obtained. In CEUS, type of enhancement, rim enhancement and area of enhancement were assessed. After the time-intensity curves (TIC) were drawn, the time to peak enhancement (TTP), peak intensity (PI) and the time from peak to one half (TFP) were calculated for the tumors and surrounding salivary parenchyma. Postoperatively, histopathologic examination of surgical specimens was used as the gold standard.

RESULTS: Color Doppler ultrasonography showed no significant differences in PSV between tumors, significantly less adenolymphomas had Grade 0-1 vascularity compared to pleomorphic adenomas, and the RI was significantly lower in adenolymphomas compared to pleomorphic adenomas and malignant tumors. CEUS had acceptable diagnostic sensitivity, specificity, and accuracy for differential diagnosis of pleomorphic adenomas and adenolymphomas based on the diagnostic criteria of rim enhancement and slow wash-out rate, respectively. The sensitivity, specificity, and accuracy for differential diagnosis of malignant tumors based on the diagnostic criteria of an ill-defined enhancement margin, an enlarged enhancement area or a fast wash-in rate were also satisfactory.

CONCLUSIONS: Accurate diagnosis of salivary gland tumors in clinical practice can be increased using color Doppler ultrasound and

CEUS in combination with a case history and other imaging.

Key Words:

Ultrasonography, Pleomorphic adenoma, Adenolymphoma, Malignant tumor.

Introduction

Salivary gland tumors are a group of complex neoplasms accounting for an estimated 3% of all head and neck tumors. Salivary gland tumors are mainly located in the parotid gland. Approximately 80% of salivary gland tumors are pleomorphic adenomas. Although these are benign cases, but recurrence rates of them can reach 40%¹. They also have the 3-4% potential for malignant transformation². Treatment for pleomorphic adenomas involves resection with a subtotal parotidectomy while preserving the facial nerve. Adenolymphomas are the second most common benign tumors of the salivary glands. Adenolymphomas arise from remnant lymphoid ducts and have little tendency to recur. They can be resected with a less aggressive surgical procedure, but patients with surgery contraindications, especially those who are elderly, can be treated conservatively³. Malignant tumors of the salivary glands are rare and have a complex pathology. They should be completely excised with glandular tissue and the possibility of facial nerve resection, followed by chemotherapy or radiation therapy.

HE staining and immunohistochemical staining in postoperative pathological examination are helpful to distinguish these types of salivary gland tumors. In immunohistochemistry, PLAG-1 was strongly positive in pleomorphic adenomas, negative in malignant tumors, SOX10 negative

in mucoepidermoid adenocarcinoma and ductal carcinoma, S-100 positive in adenoid cystic carcinoma and secretory carcinoma, and Myb negative in adenolymphomas. But an accurate preoperative diagnosis of pleomorphic adenomas, adenolymphomas, and malignant tumors of the salivary glands is still essential for treatment decision-making. Imaging plays an important role in the preoperative diagnosis of salivary gland tumors. Traditionally, ultrasonography was used for initial imaging, but qualitative features on conventional and color doppler ultrasonography are inadequate for the differential diagnosis of benign and malignant salivary gland tumors³⁻⁶. Furthermore, qualitative interpretation of color doppler ultrasonography mainly depends on the clinical experience of the radiologist rather than measurable evidence⁵. The use of CEUS for the differential diagnosis of pleomorphic adenomas, adenolymphomas, and malignant tumors of the salivary glands has been investigated, but, to the authors knowledge, a systematic assessment of the qualitative and quantitative features of these types of salivary gland tumors on CEUS has not been reported.

This study provides a comprehensive description of the qualitative and quantitative characteristics of pleomorphic adenomas, adenolymphomas, and malignant tumors of the salivary glands on color Doppler ultrasonography and CEUS.

Patients and Methods

Patients

64 patients (41 males and 23 females) with 35 pleomorphic adenomas, 24 adenolymphomas, and 12 malignant tumors were enrolled in this study. All patients have undergone surgical removal of solid tumors in the salivary glands in the Department of Oral Surgery at the First Affiliated Hospital of Nanchang University between August 2016 and July 2018. The mean age of patients was 53.7 ± 16.0 years (range, 19-88 years), the mean diameter of tumors was 24.5 ± 9.1 mm (range, 7-45 mm). Patients with serious allergies, cardiovascular or hematologic disease, diffuse disease of the salivary gland, such as Sjögren syndrome, or who had received chemotherapy and/or radiotherapy to the head and neck, were excluded. Written informed consent was obtained from all participants. This study was approved by the institutional review board with a waiver of informed consent due to the retrospective nature of the study.

Imaging

All patients were examined preoperatively using a Philips IU22 ultrasonography system equipped with a L12-5 linear array transducer (Philips Medical Systems, Inc., Bothell, WA, USA). Initially, patients were assessed with gray-scale ultrasonography in the supine position with the neck fully exposed. Images of salivary gland tumors were obtained in the longitudinal and transverse planes. Tumors were evaluated for location, size, and internal echo. Subsequently, patients underwent color doppler ultrasonography with medium flow velocity and a wall filter. Peak systolic velocity (PSV) and the vascular resistance index (RI) were measured after an optimal doppler signal was obtained. Each measurement was scored three times, and the mean was used for statistical analysis. Finally, CEUS was used to obtain images of the tumors as well as part of the normal adjacent gland. An image of a peripheral part of the tumor with rich blood flow and some normal adjacent tissue was obtained when the tumor was too large. Contrast pulse sequencing was applied, with a probe emission frequency of 3-9 MHz and mechanical index of 0.06. SonoVue[®] (59 mg lyophilized powder) (Bracco Imaging SpA, Milan, Italy), dissolved in 5 ml 0.9% sodium chloride, was used as the contrast agent. In each patient, 2.4 ml SonoVue[®] was injected as an intravenous bolus via an antecubital vein, immediately followed by 5 ml 0.9% sodium chloride. After injection of the contrast agent, the salivary gland and tumor were scanned with harmonic gray-scale CEUS for at least 90 sec, and dynamic images were recorded. The saving time and dose was according to the study of Fischer et al³. During image acquisition, patients were asked to breathe normally but refrain from other movements and talking.

Postoperatively, histopathologic examination of surgical samples was used as the gold standard for diagnosis of the salivary gland tumors.

Ultrasonography Imaging Analysis

For color doppler ultrasonography evaluations, vascularity was graded on a four-step analog scale ranging from 0 to 3 according to Martinoli et al⁵, where grade 0=no detectable color signal, grade 1=transient flow or only one vessel detectable inside the lesion, grade 2=continuous flow or presence of vessels penetrating the neoplasm and grade 3=rich blood supply in the neoplasm.

For CEUS evaluation, the type, margin, rim and area of enhancement of tumors were by observing the dynamic imaging. Type of enhance-

ment was categorized as homogenous or heterogeneous, margin enhancement was categorized as well-defined or ill-defined, rim enhancement was categorized as present or absent, area of enhancement was categorized as enlarged if the tumor area on CEUS was larger than on convention ultrasonography, or not enlarged. Then, the dynamic imaging was evaluated with QLAB software. Regions of interest (ROI) were approximately 0.5 cm² in size in areas which showed avid enhancement of the tumors and surrounding salivary parenchyma. ROI were not near perfusion defects, focal calcified areas, or tissues such as large vessels. After the time-intensity curves (TIC) were drawn, the time to peak enhancement (TTP), peak intensity (PI) and the time from peak to one half (TFP) were calculated for both the tumors and surrounding salivary parenchyma. The following CEUS enhancement features were assessed: (1) wash-in rate, defined as fast, identical, or slow determined by whether TTP was shorter, equal, or longer in the tumor compared to the surrounding salivary parenchyma; (2) wash-out rate, defined as fast, identical, or slow determined by whether the TFP was shorter, equal, or longer in the tumor compared to the surrounding salivary parenchyma; (3) degree of enhancement, categorized as hypo-enhancement, iso-enhancement, or hyper-enhancement, determined by whether the PI of the tumor was lower, equal, or higher than the surrounding salivary parenchyma. All evaluations were performed by one radiologist experienced in CEUS.

Statistical Analysis

Statistical analysis was conducted using SPSS version 23.0 software (IBM Corp., Armonk, NY, USA). Continuous variables are presented as the mean ± standard deviation. Comparisons between tumors and surrounding salivary parenchyma

were performed using Student’s *t*-test. Comparisons between pleomorphic adenomas, adenolymphomas, and malignant tumors were performed using the Fisher Exact Test (2xC) and one-way ANOVA, as appropriate. If these tests determined that a variable was significantly different between the three tumors, multiple comparisons for all tumors were performed with the Fisher Exact Test or LSD. *p*-values < 0.05 were considered statistically significant.

Results

Convention Ultrasonography

Conventional ultrasonography could not be used to distinguish between pleomorphic adenomas, adenolymphomas, and malignant tumors based on margins (5 patients had poorly define margins) or heterogeneity (8 tumors were heterogeneous, consisting of mixed solid and cystic components).

Color Doppler Ultrasonography Characteristics of Salivary Gland Tumors

Characteristics of pleomorphic adenomas, adenolymphomas, and malignant tumors on color Doppler ultrasonography are shown in Table I. There was a significant difference in vascularity between pleomorphic adenomas and adenolymphomas (*p*<0.016667). Compared to pleomorphic adenomas, there were significantly less adenolymphomas with Grade 0-1 vascularity. There were no significant differences in PSV between pleomorphic adenomas, adenolymphomas, and malignant tumors. The RI was significantly lower in adenolymphomas compared to pleomorphic adenomas (*p*<0.016667). The RI was significantly lower in adenolymphomas compared to malignant tumors too (*p*<0.016667) (Figure 1).

Table I. Characteristics of pleomorphic adenomas (PA), adenolymphomas (AL), and malignant tumors (MT) on color Doppler ultrasonography.

	Count	Location		PSV (cm/s)	RI	Vascularity	
		Parotid	Submandibular			0-1	2-3
PA	35	28	7	14.4±10.0	0.84±0.21	14	21
AL	24	24	0	18.4±15.5	0.67±0.12	2	22
MT	12	11	1	16.5±9.9	0.86±0.18	4	8
<i>p</i> -value			1.0*	.466	.001	.027	

Note: *, PA vs. MT

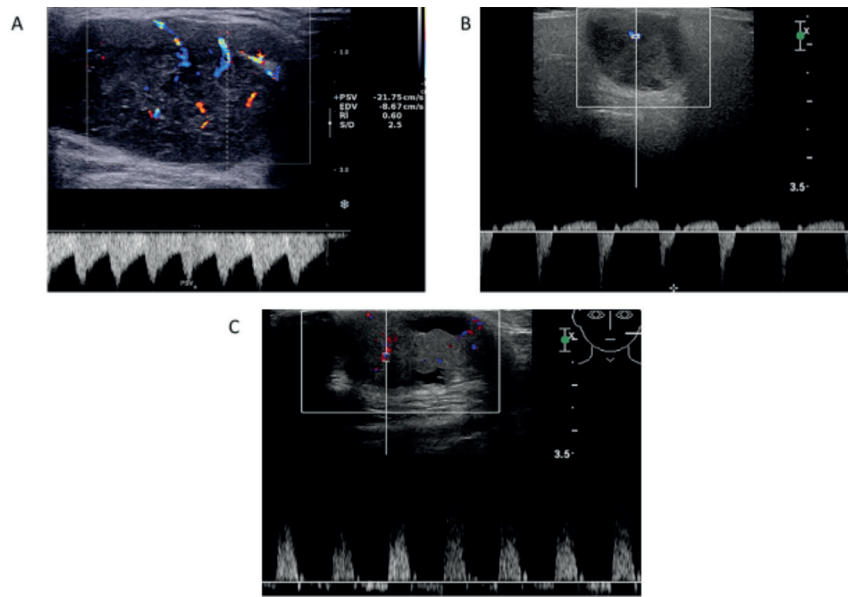


Figure 1. Vascularity and RI. **A**, adenolymphoma, Grade 3 vascularity; RI=0.6; **B**, pleomorphic adenoma, Grade 2 vascularity, RI=1.0; **C**, malignant tumor, Grade 3 vascularity, RI=1.0.

CEUS Characteristics of Salivary Gland

Qualitative CEUS parameters for pleomorphic adenomas, adenolymphomas, and malignant tumors are shown in Table II. Pleomorphic adenomas were significantly more heterogeneous than adenolymphomas ($p < 0.016667$), significantly more malignant tumors presented with ill-defined margins compared to pleomorphic adenomas and adenolymphomas ($p < 0.016667$), and significantly more pleomorphic adenomas showed rim enhancement compared to adenolymphomas and malignant tumors ($p < 0.016667$). The area of enhancement was enlarged in significantly more malignant tumors than pleomorphic adenomas or adenolymphomas ($p < 0.016667$) (Figure 2).

Quantitative CEUS parameters for pleomorphic adenomas, adenolymphomas, and malignant tumors are shown in Table III. In pleomorphic

adenomas, wash-in and wash-out rates were identical compared to the surrounding salivary parenchyma. Pleomorphic adenomas were well-defined and showed heterogeneous enhancement, hyper-enhancement, and rim enhancement. In adenolymphomas, wash-in rate was identical, but the wash-out rate was slower than the surrounding salivary parenchyma. Adenolymphomas were well-defined and showed homogeneous enhancement and evident hyper-enhancement. In malignant tumors, although both the wash-in rate and the wash-out rate were identical to the surrounding salivary parenchyma, the TTP of MT was shorter than the surrounding salivary parenchyma ($p = 0.052$). Malignant tumors were ill-defined and showed homogeneous or heterogeneous enhancement, hyper-enhancement and enlarged area of enhancement (Figure 3).

Table II. Qualitative CEUS parameters in pleomorphic adenomas (PA), adenolymphomas (AL), and malignant tumors (MT).

	Type of enhancement		Enhancement margin		Enhancement rim		Enhancement area	
	Homogenous	Heterogenous	Well-define	Ill-define	Present	Absent	Enlarge	Not
PA	7	28	33	2	32	3	1	34
AL	17	7	20	4	11	13	1	23
MT	5	7	3	9	2	10	8	4
<i>p</i> -value	.000		.000	.000	.000		.000	

The sensitivity, specificity, and accuracy of CEUS for the differential diagnosis of pleomorphic adenomas with diagnostic criterion of rim enhancement were 91.4% (32/35), 63.9% (23/36) and 77.5% (55/71), respectively. The sensitivity, specificity, and accuracy of CEUS for the differential diagnosis of adenolymphomas with diagnostic criterion of a slower wash-out rate compared to the surrounding salivary parenchyma were 87.5% (21/24), 70.2% (33/47), and 71.8% (51/71), respectively. The sensitivity, specificity, and accuracy of CEUS for the differential diagnosis of malignant tumors with ill-defined enhancement margin and enlarged enhancement area were 75% (9/12), 89.9% (53/59), 87.3% (62/71) and 66.7% (8/12), 96.6% (57/59), 91.5% (65/71).

Discussion

Color Doppler ultrasonography and CEUS provide the opportunity to improve the understanding of salivary diseases and may be particularly useful for differentiation of pleomorphic adenomas, adenolymphomas, and malignant tumors^{3,6,7}. Vascular patterns and blood flow vary between different types of tumor. Color Doppler ultrasonography can be used to examine macro-vascularity⁸, while CEUS has utility for observing micro-vascularity and for quantitative analysis of microvascular perfusion in solid tumors. In this retrospective study, we provide a comprehensive description of the qualitative and quantitative characteristics of pleomorphic adenomas, ade-

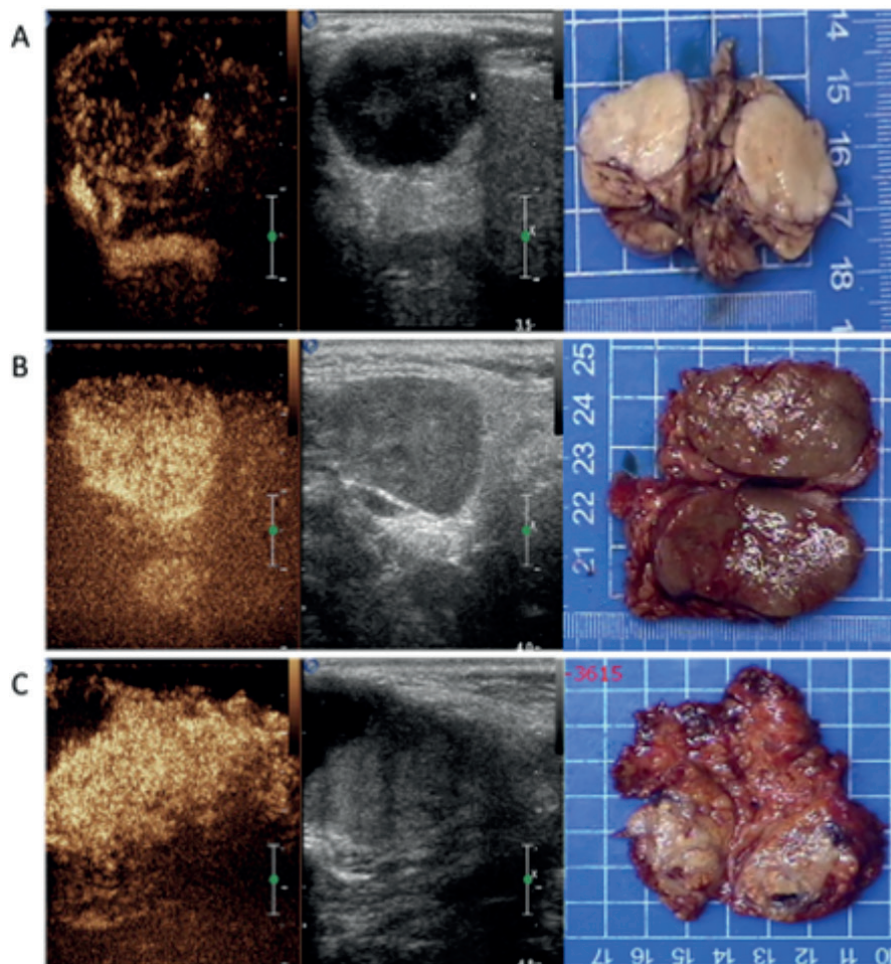


Figure 2. Qualitative CEUS parameters in pleomorphic adenomas, adenolymphomas, and malignant tumors and their surgical specimen. **A**, Pleomorphic adenoma showing a well-defined margin, heterogeneous enhancement, and rim enhancement; **B**, Adenolymphoma showing a well-defined margin and homogenous enhancement; **C**, Malignant tumor showing an ill-defined margin, heterogeneous enhancement, heterogeneous rim enhancement, and an enlarged enhancement area.

Table III. Quantitative CEUS parameters for pleomorphic adenomas (PA), adenolymphomas (AL), and malignant tumors (MT)
Note: SSP, surrounding salivary parenchyma.

	PA			AL			MT		
	TTP (s)	PI (dB)	TFP (s)	TTP (s)	PI (dB)	TFP (s)	TTP (s)	PI (dB)	TFP (s)
Tumor	15.69±6.94	7.90±2.30	38.73±12.48	17.12±6.19	9.26±2.03	48.97±12.81	15.36±4.87	6.85±2.30	35.60±10.79
SSP	15.09±5.40	6.78±2.36	40.45±14.02	17.28±6.55	6.47±2.34	37.29±10.42	18.20±6.43	5.12±1.44	42.85±12.83
<i>p</i> value	.595	.031	.637	.847	.000	.000	.052	.019	.140
Same Feature	hyper-enhancement			hyper-enhancement			hyper-enhancement		
Different Feature	identical in identical out			identical in slowly out			identical out		

nolymphomas, and malignant tumors of the salivary glands on color Doppler ultrasonography and CEUS, and these indicators are also the most commonly used in clinical practice. Therefore, this research will contribute significantly to the differential diagnosis of salivary gland tumors in clinical practice.

This study showed that conventional ultrasonography does not clearly distinguish between pleomorphic adenomas, adenolymphomas, and malignant tumors of the salivary glands. However, color Doppler ultrasonography showed a difference in the degree of vascularity between pleomorphic adenomas and adenolymphomas, but no

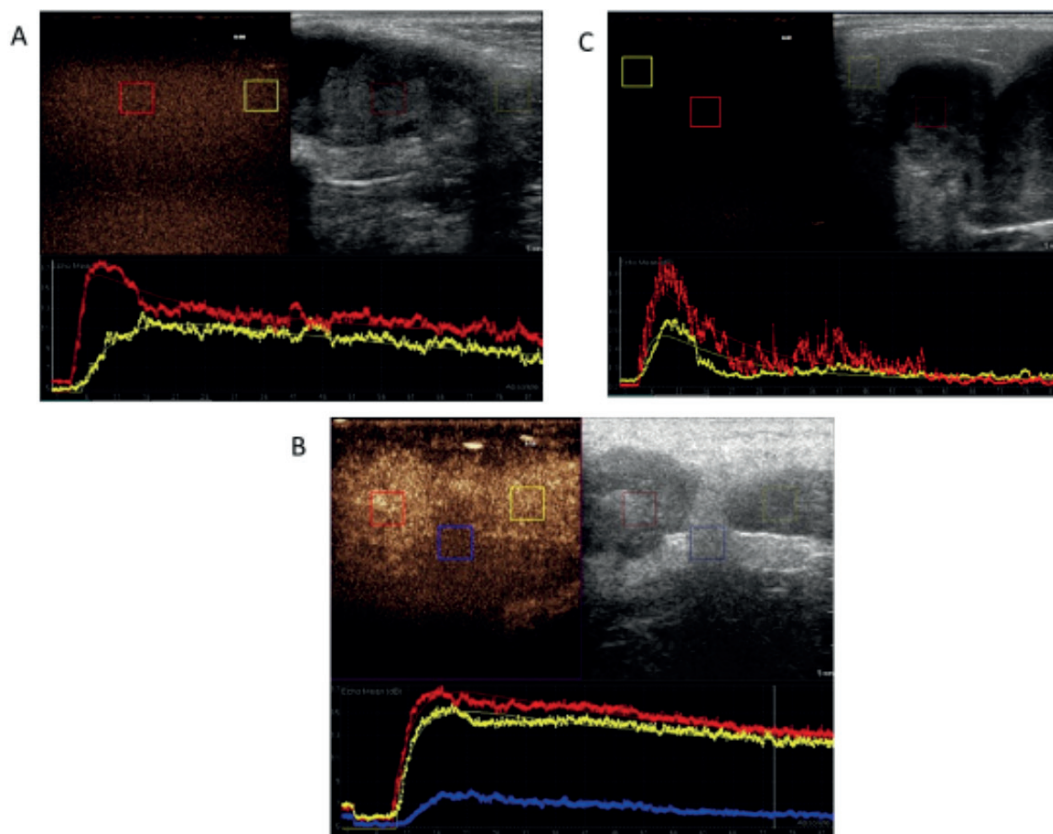


Figure 3. Time-intensity curves. **A**, Pleomorphic adenoma showing identical wash-in and wash-out rates compared to the surrounding salivary parenchyma and hyperenhancement; **B**, Two adenolymphomas, both showing identical wash-in and slower wash-out rates compared to the surrounding salivary parenchyma and hyperenhancement; **C**, Malignant tumor showing faster wash-in and identical wash-out rates compared to the surrounding salivary parenchyma and hyper-enhancement.

difference between pleomorphic adenomas or adenolymphomas and malignant tumors. Consistent with previous studies, the degree of vascularity in adenolymphomas was high^{4,5,9}. In contrast, only 40% of the pleomorphic adenomas examined in this study had poor blood flow compared to 81% in a previous study⁴. This discrepancy may be caused by using different methods for grading vascularity.

In this study, there were no significant differences in PSV between pleomorphic adenomas, adenolymphomas, and malignant tumors of the salivary glands. However, Aluffi et al¹⁰ reported that PSV >30 cm/s was a reminder of malignant tumors in parotid gland. The disparate findings between our study and those previous reports may be explained by the small number of malignant tumors in our sample and our inclusion of tumors of the submandibular gland. Furthermore, results may be confounded as the histological types of malignant tumors vary.

Assessment of the RI may distinguish benign from malignant tumors, with high RIs documented in malignant tumors. Our findings showed that the RI was significantly lower in adenolymphomas compared to pleomorphic adenomas and malignant tumors. However, Badea et al¹¹ found that the RI of pleomorphic adenomas was low, and the RI of malignant tumors was high.

Thus, our results with using color Doppler ultrasonography suggest that pleomorphic adenomas are poorly vascularized and showed a high RI, adenolymphomas are well vascularized and have a low RI.

On CEUS, pleomorphic adenomas showed a more heterogeneous enhancement than adenolymphomas, representing their more heterogeneous histopathological structure. Significantly more malignant tumors of the salivary glands presented with ill-defined margins compared to pleomorphic adenomas or adenolymphomas, as malignant tumors are usually characterized by spiculated margins on conventional ultrasonography¹², and they are invasive to surrounding tissue¹³. The area of enhancement was enlarged in significantly more malignant tumors than pleomorphic adenomas or adenolymphomas, which is similar to the report of Gou et al⁷. Consequently, the specificity and accuracy of CEUS for differential diagnosis of malignant tumors were 89.9%, 87.3% and 96.6%, 91.5% based on an ill-defined margin and an enlarged enhancement area, respectively.

Most of the pleomorphic adenomas and adenolymphomas were well-defined in our study, and in a previous report Zheng et al¹⁴ showed that benign

salivary gland tumors had clear well-defined margins on magnetic resonance imaging (MRI). Significantly more pleomorphic adenomas showed rim enhancement compared to adenolymphomas or malignant tumors. Enhancement rims are usually associated with a fibrous connective tissue capsule and surrounding compressed adjacent normal parenchyma¹⁵. In our study, 8 cases of pleomorphic adenomas had incomplete capsules on pathology, so 3 cases of pleomorphic adenomas did not show rim enhancement on subsequent CEUS, and 1 case of pleomorphic adenoma showed invasive biological behavior on pathology and an enlarged enhancement area on CEUS. 4 cases of adenolymphomas were ill-defined, and 1 case of adenolymphoma had an enlarged enhancement area. These anomalies may have been caused by enhancement of an adjacent vessel, lateral acoustic shadowing and tumors being too closed to the probe. Despite of this, CEUS had a high sensitivity of 91.4% when differential diagnosis of pleomorphic adenomas was based on rim enhancement.

CEUS can be used to quantitatively evaluate perfusion characteristics of salivary gland tumors, and has the potential to differentiate parotid gland lesions preoperatively^{16,17}. In this study, the PI of pleomorphic adenomas, adenolymphomas, and malignant tumors was significantly higher than the surrounding salivary parenchyma, all of them presented as hyper enhancing lesions. In contrast, previous studies^{7,9,18} suggest that the PI of adenolymphomas is higher than pleomorphic adenomas, and that adenolymphomas appear more vascularized than pleomorphic adenomas on CEUS^{19,20}. These dissimilar results may be explained by the different ROIs examined across studies.

Some reports^{3,7,9,11,17,21} have compared perfusion time in pleomorphic adenomas, adenolymphomas, and malignant tumors of the salivary glands, but to the author's knowledge, the present study is the first to compare perfusion time in pleomorphic adenomas, adenolymphomas, and malignant tumors to that of the surrounding salivary parenchyma and investigate wash-in and wash-out rates. Malignant tumors tended to fast wash-in compared to surrounding salivary parenchyma, these findings may be explained by the abnormal and chaotic vessel structure in malignant tumor tissue¹⁷. In adenolymphomas, the wash-out rate was significantly slower than the surrounding salivary parenchyma, possibly due to the rich vessel structure or dense capillaries in these lesions²². Based on a diagnostic criterion of slower wash-out rate compared to

surrounding salivary parenchyma, the sensitivity, specificity, and accuracy of CEUS for differential diagnosis of adenolymphomas were 87.5%, 70.2%, and 71.8%, respectively.

However, this study was associated with several limitations. First, the number of malignant tumors was small, due to a low incidence. A larger patient population is required to verify the characteristics of malignant tumors of the salivary glands on color Doppler ultrasonography and CEUS. Second, only one ROI in each tumor was examined. Multiple ROIs in the center and periphery of these tumors should be evaluated in further studies to understand the detailed perfusion characteristics and inform microbubble treatment in salivary gland tumors. Finally, the comparisons between tumors in parotid glands and submandibular glands were not performed.

Conclusions

Color Doppler ultrasonography may have utility in the differential diagnosis of pleomorphic adenomas from adenolymphomas but is limited in its ability to differentiate pleomorphic adenomas and adenolymphomas from malignant tumors. Qualitative and quantitative parameters of CEUS contribute to the differential diagnosis of pleomorphic adenomas, adenolymphomas, and malignant tumors of the salivary glands. These results suggest that diagnostic accuracy of pleomorphic adenomas, adenolymphomas and malignant tumors in salivary in clinical practice can be increased using color Doppler ultrasound and CEUS in combination with a case history and other imaging.

Conflict of Interest

The Authors declare that they have no conflict of interests.

Acknowledgment

The author would like to thank Qiang Zhang from the First Affiliated Hospital of Nanchang University for assistance and insightful comments.

References

- 1) TATAR IG, ERGUN O, KURT A, SAHIN M, HEKIMOLU B. The role of elastosonography in the differentiation of parotid gland lesions: report of three cases and review of the literature. *Pol J Radiol* 2014; 79: 398-401.
- 2) ASSILI S, KAZEROONI AF, AGHAGHAZVINI L, RAD HS, ISLAMAIN JP. Dynamic contrast magnetic resonance imaging (DCE-MRI) and diffusion weighted MR imaging (DWI) for differentiation between benign and malignant salivary gland tumors. *J Biomed Phys Eng* 2015; 5: 157-168.
- 3) FISCHER T, PASCHEN CF, SLOWINSKI T, ALKHAMERI A, BERL JC, KLINGEBIEL R, THOMAS, A. Differentiation of parotid gland tumors with contrast-enhanced ultrasonography. *RöFo-Fortschritte auf dem Gebiet der Röntgenstrahlen und der bildgebenden Verfahren*. © Georg Thieme Verlag KG Stuttgart-New York 2010; 182: 155-162.
- 4) RZEPAKOWSKA A, OSUCH WÓJCIEKIEWICZ E, SOBOL M, CRUZ R, SIELSKA BADUREK E, NIEMCZYK K. The differential diagnosis of parotid gland tumors with high-resolution ultrasonography in otolaryngological practice. *Eur Arch Otorhinolaryngol* 2017; 274: 3231-3240.
- 5) MARTINOLI C, DERCHI LE, SOLBIATI L, RIZZATTO G, SILVESTRI E, GIANNONI M. Color Doppler sonography of salivary glands. *AJR Am J Roentgenol* 1994; 163: 933-941.
- 6) MIAO LY, XUE H, GE HY, WANG JR, JIA JW, CUI LG. Differentiation of pleomorphic adenoma and Warthin's tumour of the salivary gland: is long-to-short diameter ratio a useful parameter?. *Clin Radiol* 2015; 70: 1212-1219.
- 7) GOU JM, CHEN Q, ZHOU Q, LIU YX. Quantitative diagnosis of salivary gland tumors with contrast-enhanced ultrasonography—a preliminary study. *Oral Surg Oral Med Oral Pathol Oral Radiol* 2013; 116: 784-790.
- 8) WU S, LIU G, CHEN R, GUAN Y. Role of ultrasonography in the assessment of benignity and malignancy of parotid masses. *Dentomaxillofac Radiol* 2012; 41: 131-135.
- 9) WEI X, LI Y, ZHANG S, LI XB, WANG HL, YONG X, WANG XO, LI X, GAO M. Evaluation of microvascularization in focal salivary gland lesions by contrast-enhanced ultrasonography (CEUS) and Color Doppler sonography. *Clin Hemorheol Microcirc* 2013; 54: 259-271.
- 10) ALUFFI P, FONIO N, GANDINI G, PIA F. Doppler-color ultrasonography in the diagnosis of parotid tumors. *Acta Otorhinolaryngol Ital* 1997; 17: 52-57.
- 11) BADEA AF, BRAN S, TAMAS SZORA A, FLOARES A, BADEA R, BACIUT G. Solid parotid tumors: an individual and integrative analysis of various ultrasonographic criteria. A prospective and observational study. *Med Ultrason* 2013; 15: 289-298.
- 12) HEŘMAN J, SEDLÁČKOVÁ Z, VACHUTKA J, FÜRST T, SALZMAN R, VOMÁČKA J, HEŘMAN M. Differential diagnosis of parotid gland tumors: role of shear wave elastography. *BioMed Res Int* 2017; 2017: 9234672.
- 13) DRUDI FM, CANTISANI V, GNECCHI M, MALPASSINI F, DI LEO N, DE FELICE C. Contrast-enhanced

- ultrasonography examination of the breast: a literature review. *Ultraschall Med* 2012; 33: E1-E7.
- 14) ZHENG N, LI R, LIU W, SHAO S, JIANG S. The diagnostic value of combining conventional, diffusion-weighted imaging and dynamic contrast-enhanced MRI for salivary gland tumors. *Br J Radiol* 2018; 91: 20170707.
 - 15) ROQUERO L, KRYVENKO ON, GUPTA NS, LEE MW. Characterization of fibromuscular pseudocapsule in renal cell carcinoma. *Int J Surg Pathol* 2015; 23: 359-363.
 - 16) KLOTZ LV, INGRISCH M, EICHHORN ME, NIEMOELLER O, SIEDEK V, GÜRKOV R, CLEVERT DA. Monitoring parotid gland tumors with a new perfusion software for contrast-enhanced ultrasonography. *Clin Hemorheol Microcirc* 2014; 58: 261-269.
 - 17) KLOTZ LV, GÜRKOV R, EICHHORN ME, SIEDEK V, KRAUSE E, JAUCH KW, REISER MF, CLEVERT DA. Perfusion characteristics of parotid gland tumors evaluated by contrast-enhanced ultrasonography. *Eur J Radiol* 2013; 82: 2227-2232.
 - 18) KNOFF A, MANSOUR N, CHAKER A, BAS M, STOCK K. Multimodal ultrasonographic characterisation of parotid gland lesions--a pilot study. *Eur J Radiol* 2012; 81: 3300-3305.
 - 19) GREIS C. Ultrasonography contrast agents as markers of vascularity and microcirculation. *Clin Hemorheol Microcirc* 2009; 43: 1-9.
 - 20) DAVID E, CANTISANI V, DE VINCENTIS M, SIDHU PS, GRECO A, TOMBOLINI M, DRUDI FM, MESSINEO D, GIGLI S, RUBINI A, FRESILLI D, FERRARI D, FLAMMIA F, D'AMBROSIO F. Contrast-enhanced ultrasonography in the evaluation of parotid gland lesions: an update of the literature. *Ultrasonography* 2016; 24: 104-110.
 - 21) SUMI M, VAN CAUTEREN M, SUMI T, OBARA M, ICHIKAWA Y, NAKAMURA T. Salivary gland tumors: use of intravoxel incoherent motion MR imaging for assessment of diffusion and perfusion for the differentiation of benign from malignant tumors. *Radiology* 2012; 263: 770-777.
 - 22) LE BIHAN D. Intravoxel incoherent motion perfusion MR imaging: a wake-up call. *Radiology* 2008; 249: 748-752.