

# Reduction of double chin without surgery using ascorbic acid and ascorbyl-palmitate solution: a clinical study

A. SCARANO<sup>1</sup>, R. AMORE<sup>1</sup>, A. GRECO LUCCHINA<sup>1</sup>, E. OORRI<sup>2</sup>,  
M. MARCHETTI<sup>3</sup>, M. DI CARMINE<sup>1</sup>, D. AMUSO<sup>1</sup>

<sup>1</sup>Department of Innovative Technology in Medicine and Dentistry, University of Chieti-Pescara, Chieti, Italy

<sup>2</sup>Faculty of Medical Sciences, Albanian University, Tirana, Albany

<sup>3</sup>School of Applied Medical-Surgical Sciences, University of Rome Tor Vergata, Rome, Italy

**Abstract. – OBJECTIVE:** The purpose of the present clinical study is to assess the effectiveness of a lipolytic solution containing sodium salt of ascorbic acid at 0.24% and a surfactant agent at 0.020% ascorbyl-palmitate (SAP) for the treatment of double chin.

**PATIENTS AND METHODS:** A total of 10 healthy adult subjects affected by double chin (8 female and 2 male) were evaluated in the present investigation. The patients were admitted to a total of 4 sessions, with biweekly procedures, without no other active agents addiction.

**RESULTS:** In all the subjects a reduction of the convexity of the chin after the treatment with SAP was observed. Improvement in submental appearance was achieved in 90% (9/10) of the patients. One patient did not see any improvement in submental appearance after two section treatments and withdrew from the treatment.

**CONCLUSIONS:** In conclusion, in the present study, a new adipocytolytic solution consisting of sodium ascorbate mixed with ascorbyl-palmitate was used with success as a surfactant agent for the treatment of double chin.

*Key Words:*

Double chin, Local adiposity, Body contouring, Injection lipolysis, Ascorbic acid, Ascorbyl-palmitate.

## Introduction

Double chin is an excess of fat accumulation of pre-platysmal and post-platysma which can manifest in different shapes and sizes. People who are thin can have a double chin, just as those who are affected by obesity<sup>1</sup>. This may be caused by genetics, or it may form later on in life as local adiposity. It can lead to a loss of mandibular definition, as well as giving the impression of

obesity or aging. A double chin can be formed by pockets of fat during aging through weight gain, during weight loss or during pregnancy, and can last even after giving birth. Also, skin loses collagen through aging and becomes laxer around the mouth, chin and neck. Whether genetic or acquired, double chins are fairly common. In some cases, a double chin can contribute to snoring and obstructive sleep apnea (OSA) because it puts pressure on the neck during sleep. Over time, snoring and sleep apnea can cause heart diseases and other problems due to a lack of oxygen supply during sleep. In the absence of apnea, the problems caused by a double chin are only aesthetic. Exercise can help tighten up and strengthen the muscles around the neck, chin and jaw, but do not necessarily reduce the fat there. Muscle and fat are different tissues, so it is possible, in exercise targeted areas, to build up muscle, but you cannot burn off fat specifically in the neck and chin area. In the perioral region there is no clear layered arrangement and there are no subcutaneous fat compartments. This aspect is the major difference between this region and all other facial regions<sup>2</sup> but simply, subcutaneous fat is deep fat<sup>3</sup>. Double chin is an aesthetical problem and since physical appearance is given great value, many feel disadvantaged as it negatively influences relationships with friends, family and the social environment. Different techniques have been proposed for the treatment of double chin such as liposuction and other surgical procedures. Today there is much interest and demand for minimally invasive facial aesthetic treatments including injectable lipolytic therapy for the treatment of excess fat in the abdominal area<sup>4</sup>, lower eyelid area<sup>5</sup> and excess submental fat<sup>6,7</sup> etc. Aesthetic treatments are in

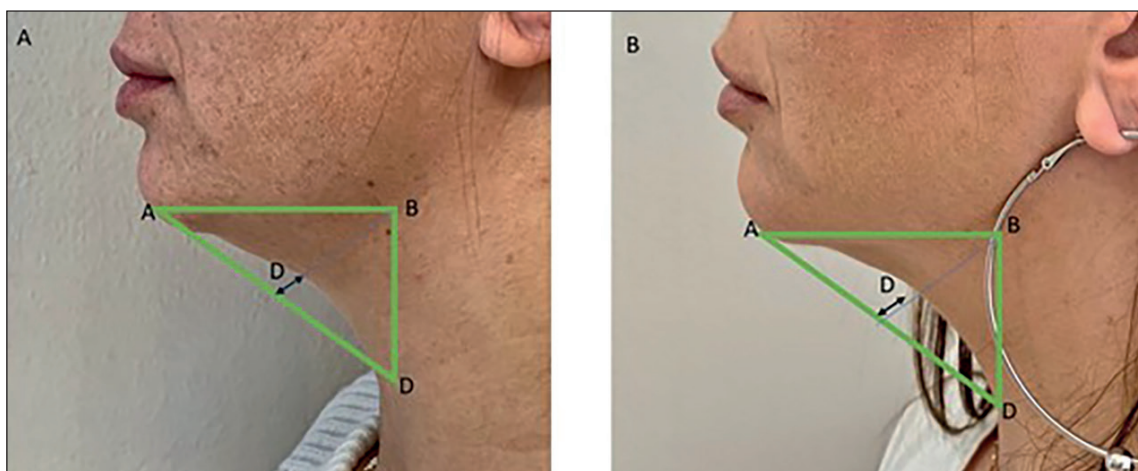
great demand for improving facial appearance and comprise the use of fillers<sup>8-10</sup>, peeling<sup>11</sup>, atmospheric plasma<sup>12,13</sup> etc. In this paper, we aimed to illustrate the efficacy of sodium ascorbate for the treatment of double chin. The aim of the present clinical study is to assess the effectiveness and the safety of an injectable solution containing sodium salt of ascorbic acid 0.24% and a surfactant agent at 0.020% ascorbyl-palmitate (SAP) for the treatment of double chin.

### Patients and Methods

The present investigation has been approved by the Ethics Committee of FMD University of Tirana Albania and conducted in accordance with the good clinical practice guidelines the laws for human research, and the ethical principles of the Declaration of Helsinki. The present research included a total of 10 healthy subjects, 8 females and 2 males, affected by double chin. The experimental treatment was conducted between February 2019 and January 2020. The population age ranged between 34 and 64 years old, and it was characterized by a body mass index (BMI) that ranged between 22 and 27. The patients were characterized by a normal weight or health slightly overweight. The signed informed consent was obtained for all subjects included in the present investigation. The inclusion criteria considered subjects characterized by adiposity excesses at the level of the submental area that accepted a nonsurgical procedure for its reduction. The study exclusion criteria were skin laxity, platysma diastasis, puerperium and lactation condition,

menstrual cycle, local infections, skin pathologies and eventual anticoagulant administration. The adipocytolytic agent applied was composed by an isotonic solution for sodium chloride in phosphate buffer with ascorbic acid 0.24% and 0.020% ascorbyl-palmitate (SAP) as surfactant, (Skin-Fat, Ital Farmacia, Rome, Italy). The agent was administered through a 5 mL syringe with 27-30 G and an 8 cm long needle. The injections depth was maintained at 0.5-1 cm. Each infiltration of 0.2 mL not diluted solution was performed through a retrograde and fanning infiltration at moderate extrusion speed. A quantity of 0.5 mL SAP solution was administered in bolus and the remaining solution of 1.5 mL was gradually released during the needle removal. No local analgesia was necessary for this procedure.

Immediately after the procedure, an icepack was compulsory applied for 15 minutes in order to avoid the post-treatment local edema and pain. No further local massages were performed after the SAP injection in order to avoid the unwanted solution displacements at the level of the surrounding structures. The included subjects were admitted for a cycle of 4 procedures, according to a biweekly administration. The aesthetic effectiveness was measured according to a pre-operative and post-operative photographs at 2 months follow-up. The study findings were measured by the operator through physical palpation of the treated area and its clinical appearance. The Figures 1A-B were obtained through a lateral projection, with a patient position looking frontally, with no hyperextension or head pull-down. The neck contours were assessed by a right-angle triangle with the two catheti that represent the



**Figure 1.** A, Before treatment. B, After treatment. The convexity reduction was achieved in the submental area.

**Table I.** Descriptive statistic of the submental area before and after the treatment.

	Before treatment	After Treatment
Range	7.09	5.54
Mean	10.83	18.8
Std. Deviation	2.66	1.61
95% CI of mean	(8.78-12.87)	(17.56-20.04)
Min-Max	7.77-14.86	16.63-22.17

mandibular and cervical parts. One cathetus was parallel to the maxillary occlusal plane the passing through the chin. The second cathetus was perpendicular to the first one passing through the neck lower point. Two different lines were considered: the mandibular segment AB (Gonion-Menton) and one cervical segment BC with an angle of 90°. The skin length was equal to or lower than the hypotenuse, then submental skin could be accommodated within hours external to the hypotenuse. The segment AB represented the mandibular prominence, and the segment BC was positioned at the hyoid bone notch. A line was drawn passing the two points A and C in order to form the hypotenuse. The distance between the chin and the hypotenuse, expressed in mm, was considered after a clinical examination and metric documentation with distance (letter D in Figure 1B).

### Statistical Analysis

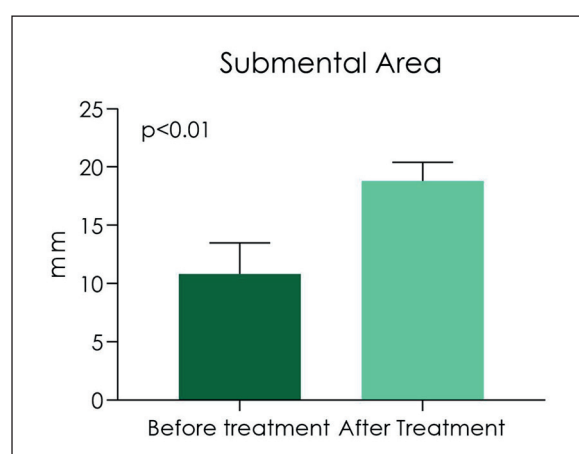
A calculation model was adopted for dichotomous variables (yes/no effect) by using the incidence effect designed to discern the reasons (85% for the test group and 15% for the control group), with  $\alpha = 0.1$  and power = 80%. The optimal number of samples for analysis was 10 patients per group.

The research findings have been statistically elaborated by the dedicated software package GraphPad 8 (Prism, San Diego, CA, USA). The normality of the experimental data has been measured by the Shapiro-Wilks test. The student's *t*-test has been conducted in order to compare the variables between each study groups. The level of significance was set for  $p < 0.05$ . Numerical results have been reported considering the means and standard deviations of all experiments.

## Results

Palpation and pinching were used to confirm the reduction of presence of subcutaneous fat.

Improvement in submental appearance was achieved by 90% (9/10) of the patients. One patient did not see good improvement in submental appearance after two section treatments and abandoned the treatment. In one patient prominent submandibular glands and postplatysmal fat with little digastric muscle hypertrophy were observed; at the same time, both can also contribute to submental fullness and would not be improved with SAP treatment. In one patient dermal blebbing was observed during administration because the injections were too superficial, and the needle was gently pushed deeper into the underlying fat. Localized swellings were reported in the submental region, but no patient reported severe erythema following the injections. All patients treated showed good results and were well satisfied with reductions in the submental area which were clinically documented (Figure 1A-B). Before treatment, the letter D in the Figure 1B was  $10.83 \pm 2.66$  mm (95% CI: 7.77-14.86) and after treatment D was  $18.8 \pm 1.61$  mm (95% CI: 16.63-22.17) (Table I, Figure 2). A statistically significant reduction of the submental area was detected comparing before and after the treatment measurements ( $p < 0.01$ ) (Table II).



**Figure 2.** Chart of the submental area before and after the treatment (Student's *t*-test;  $p < 0.01$ ).

**Table II.** Findings of the Student's *t*-test of the submental area before and after the treatment

Before treatment	After treatment
Paired <i>t</i> -test	
<i>p</i> -value	< 0.0001
<i>p</i> -value summary	****
Significantly different ( <i>p</i> < 0.05)?	Yes
One- or two-tailed <i>p</i> -value?	Two-tailed
<i>t</i> , df	<i>t</i> = 10,42, df = 8
Number of pairs	9

\**p* < 0.1; \*\**p* < 0.01; \*\*\**p* < 0.001; \*\*\*\**p* < 0.0001).

## Discussion

In the present study we observed an improvement in the skin distance from the hypotenuse line of the superimposed right triangle and a satisfactory improvement of the aesthetic appearance of the neck. The average distance augmentation after treatment was  $8.1 \pm 0.6$  showing a statistically significant submental area reduction determined by the procedure. The average distance augmentation after treatment was  $8.1 \pm 0.6$ . Patients reported a subjective improvement in the satisfaction of their aesthetic appearance regarding their necks and the size of their submental fat. A double chin, which commonly presents as excess submental fat (SMF) greatly impairs facial aesthetics and self-esteem, with relationship problems in both younger and older male and female patients. This aesthetical problem can also cause night breathing problems with apnea events. The fat in the submental area and neck circumference increases external loading pressure on the airway, leading to OSA<sup>14</sup>. In the case of a larger neck circumference with a big size adiposity, the upper airway can start to collapse, causing OSA disturbances<sup>15</sup>. No local analgesia was used because the studied treatment is painless. Submental fat is distributed in two layers, one under the skin (pre-platysma fat) and one deep post-platysma fat, which is where fat accumulation is more prevalent and thus accessible. In contrary, the subcutaneous fat is less prevalent, and an aggressive technique should be avoided. The submental area is situated between the mandibular border, the thyroid cartilage lump and the anterior sternocleidomastoid. This area has a pleasant and aesthetic appearance when there is a rounded sternocleidomastoid and a distinct inferior mandibular border<sup>16,17</sup>. In the case of a double chin, the area

to be treated by injection extends between the hyoid bone, anterior border of the sternocleidomastoid muscle, the digastric muscle and the inferior border of the mandible<sup>18</sup>. In this area there is no important structure. In fact, the facial artery and the facial nerve run along the inferior border of the mandible, away from the submental area<sup>19</sup>. To evaluate the presence of excess fat in the submental area, it is usual to pinch and palpate the submental area. Only patients with pre-platysmal fat, i.e., subcutaneous (no excess skin) were treated for lipolysis with the SAP technique. The lipolysis of fat in the submental area improves both perceived age, attractiveness and contributes significantly to the perceived body weight of individuals. Facial attractiveness generates psychosocial well-being and strongly improves perceptions of attractiveness and this can be enhanced by the morphology of the chin-neck region, independent, in many cases, of age or weight. Most subjects dislike the changes that facial aging entails, especially those of the submental region<sup>20</sup>. A submental-cervical angle between 90° and 105° is considered attractive<sup>21</sup>, while in the case of a double chin or "heavy neck" there is an angle greater than 120° with an average 126° in adult males and 121° in adult females<sup>22,23</sup>. The effectiveness of localized fat intralipotherapy fat treatment through a sodium ascorbate and ascorbyl-palmitate mixed solution has been investigated in a previous research<sup>4</sup>.

## Conclusions

In conclusion, in the present study, we used with success a new adipocytolytic solution consisting of sodium ascorbate mixed with ascorbyl-palmitate as a surfactant agent for the treatment of the double chin.

### Conflict of Interest

The Authors declare that they have no conflict of interests.

### Funding

This study did not receive any specific grant from funding agencies in the public, commercial, or not-for-profit sectors.

### Availability of Data and Materials

All data generated or analyzed during this study are included in this published article.



### Authors' Contribution

All authors were involved with the literature review and performance of the surgery. All authors read and approved the final manuscript.

### Ethics Approval

The present investigation has been approved by the Ethics Committee of FMD University of Tirana Albania, conducted in accordance with the good clinical practice guidelines for human research, the ethical principles of the Declaration of Helsinki, and the additional requirements of the Italian law.

### Informed Consent

Written informed consent was obtained from all the patients included in the study.

### ORCID ID

Antonio Scarano: 0000-0003-1374-6146; Roberto Amore: 0000-0002-1644-7902; Alberta Greco Lucchina: 0000-0002-1985-4263; Erda Qorri: 0000-0002-5079-6815; Biagio Rapone: 0000-0002-0062-6594; Francesco Inchingolo: 0000-0003-3797-5883; Domenico Amuso: 0000-0002-1841-5277.

## References

- McDiarmid J, Ruiz JB, Lee D, Lippert S, Hartisch C, Havlickova B. Results from a pooled analysis of two European, randomized, placebo-controlled, phase 3 studies of ATX-101 for the pharmacologic reduction of excess submental fat. *Aesthetic Plast Surg* 2014; 38: 849-860.
- Kruglikov I, Trujillo O, Kristen Q, Isac K, Zorko J, Fam M, et al. The Facial Adipose Tissue: A Revision. *Facial Plast Surg* 2016; 32: 671-682.
- Rohrich RJ, Pessa JE, Ristow B. The youthful cheek and the deep medial fat compartment. *Plast Reconstr Surg* 2008; 121:2 107-2112.
- Scarano A, Sbarbati A, Amore R, Iorio EL, Ferraro G, Amuso D. A New Treatment for Local Adiposity with Ascorbic Acid and Ascorbyl-Palmitate Solution: Clinical and Histological Study. *Aesthetic Plast Surg* 2020; 44: 1604-1612.
- Amore R, Sbarbati A, Amuso D, Leonardi V, Alsanafi S, Greco Lucchina A, Scarano A. Non-surgical treatment of lower eyelid fat pads with an injectable solution acid deoxycholic based. *J Biol Regul Homeost Agents* 2019; 33: 109-114.
- Jagdeo J. What Does the Data from the ATX-101 Phase I Safety and Pharmacokinetic Study Tell Us? *J Drugs Dermatol* 2015; 14: 544-545.
- Deoxycholic acid (Kybella) for double chin. *Med Lett Drugs Ther* 2015; 57:165-166.
- Scarano A, Carinci F, Piattelli A. Lip augmentation with a new filler (agarose gel): a 3-year follow-up study. *Oral Surg Oral Med Oral Pathol Oral Radiol Endod* 2009; 108: 11-15.
- Scarano A, Puglia F, Cassese R, Mordente I, Amore R, Ferraro G, Sbarbati A, Lo Russo F, Greco Lucchina A, Amuso D. Hyaluronic acid fillers in lip augmentation procedure: a clinical and histological study. *J Biol Regul Homeost Agents* 2019; 33: 103-108.
- Scarano A, Barros RRM, Iezzi G, Piattelli A, Novaes AB. Acellular dermal matrix graft for gingival augmentation: a preliminary clinical, histologic, and ultrastructural evaluation. *J Periodontol* 2009; 80: 253-159.
- Scarano A, Amodeo V, Leonardi V, Mortellaro C, Sbarbati A, Amuso D, Amore R, Pagnini D. Evaluation of the effectiveness and safety of peppermint peel (PMP) soft peeling for skin ageing. *J Biol Regul Homeost Agents* 2019; 33: 93-101.
- Scarano A, Carinci F, Candotto V, Lorusso F. Eradication of Benign Skin Lesions of the Face by Voltaic Arc Dermabrasion (Atmospheric Plasma): Postoperative Pain Assessment by Thermal Infrared Imaging. *Aesthetic Plast Surg* 2020; 44: 2277-2285.
- Scarano A, Petrini M, Inchingolo F, Lorusso F, Amuso D. A new technique for the treatment of nasal telangiectasia using atmospheric plasma (voltaic arc dermabrasion): Postoperative pain assessment by thermal infrared imaging. *J Cosmet Dermatol* 2020; 19: 2912-2918.
- Turnbull CD, Wang SH, Manuel AR, Keenan BT, McIntyre AG, Schwab RJ, Stradling JR. Relationships between MRI fat distributions and sleep apnea and obesity hypoventilation syndrome in very obese patients. *Sleep Breath* 2018; 22: 673-681.
- Kim AM, Keenan BT, Jackson N, Chan EL, Staley B, Poptani H, Torigian DA, Pack AI, Schwab RJ. Tongue fat and its relationship to obstructive sleep apnea. *Sleep* 2014; 37:1 639-1648.
- Farrior E, Eisler L, Wright HV. Techniques for rejuvenation of the neck platysma. *Facial Plast Surg Clin North Am* 2014; 22: 243-252.
- Rohrich RJ, Rios JL, Smith PD, Gutowski KA. Neck rejuvenation revisited. Plastic and reconstructive surgery 2006; 118: 1251-1263.
- Shamban AT. Noninvasive Submental Fat Compartment Treatment. *Plast Reconstr Surg Glob Open* 2016; 4: e1155.
- Batra APS, Mahajan A, Gupta K. Marginal mandibular branch of the facial nerve: An anatomical study. *Indian J Plast Surg* 2010; 43: 60-64.
- Sezgin B, Findikcioglu K, Kaya B, Sibar S, Yavuzer R. Mirror on the wall: a study of women's perception of facial features as they age. *Aesthet Surg J* 2012; 32: 421-425.
- Naini FB, Cobourne MT, McDonald F, Wertheim D. Submental-Cervical Angle: Perceived Attractiveness and Threshold Values of Desire for Surgery. *J Maxillofac Oral Surg* 2016; 15: 469-477.
- Sommerville JM, Sperry TP, BeGole EA. Morphology of the submental and neck region. *Int J Adult Orthodon Orthognath Surg* 1988; 3: 97-106.
- Moreno A, Bell WH, You ZH. Esthetic contour analysis of the submental cervical region: a study based on ideal subjects and surgical patients. *J Oral Maxillofac Surg* 1994; 52: 704-714.