

Zygomatic implant-guided rehabilitation based on inverted support technique: a pilot study

A.R. BOLZONI^{1,2}, F. ZINGARI³, F. GALLO³, F. GOKER¹, P. BERETTA¹,
M. DEL FABBRO^{1,2}, C. MORTELLARO⁴, F. GRECCHI³, A.B. GIANNI^{1,2}

¹University of Milano, Department of Biomedical, Surgical and Dental Sciences, Milan, Italy

²Dental and Maxillo-Facial Surgery Unit, Fondazione IRCCS Ca' Granda Ospedale Maggiore Policlinico, Milan, Italy

³IRCCS Orthopedic Institute Galeazzi, Milano, Italy

⁴Research Laboratory in Regenerative Medicine and Tissue Engineering, Saint Camillus International University of Health Sciences, Rome, Italy

Abstract. – OBJECTIVE: Zygomatic implant insertion surgery is a challenging operation. The primary aim of this pilot study was to assess the accuracy of EZgoma® “Inverted Support Technique” for the zygomatic implant-guided surgery. Secondly, any factors which may affect the surgical protocol results, such as implant-prosthetic virtual plan, surgical model matching, intra or post-operative complications, time rate between surgical procedure and prosthetic loading, zygomatic implant survival rate and implant success rate were analyzed.

PATIENTS AND METHODS: A total of 20 zygomatic implants were placed in atrophic maxillae of 5 patients. The final position of zygomatic implants after surgery was compared with the pre-operative digitally planned position. The analyzed parameters were zygomatic implants apex and base mean linear distance and zygomatic implants axis mean angular deviation.

RESULTS: The comparison was provided by a tridimensional imaging elaboration platform, provided by Geomagic, which allows the overlay of virtual plan STL data with post-operative control CT scan DICOM data. As a result, all the mean values regarding the 20 placed zygomatic implants respected the universally agreed values in guided zygomatic implant surgery: the mean linear distance of the implant platform and of the implant apex were 1.59 mm and 1.62 mm respectively, while the mean angular deviation of the implant axis was equal to 1.74°. One of the patients had mucositis as a post-operative complication. In one patient the anterior wall of the maxillary sinus fractured, and in one zygomatic implant primary stabilization was not achieved. No other complications occurred.

CONCLUSIONS: As a conclusion, data obtained from this study suggested that guided zygomatic implant rehabilitation may represent a reliable, efficient, rapid, ergonomic, and safe surgical protocol, however further investigations are needed.

Key Words:

Zygomatic implant, Implant-guided rehabilitation, Severe maxillary atrophy rehabilitation, Guided surgery.

Abbreviations

GBR: Guided Bone Regeneration; ZI: Zygomatic Implants; ZAGA: Zygomatic Anatomy-Guided Technique; CAD/CAM: Computer Aided Design/Computer Aided Manufacturing; CAS: Computer Aided Surgery; ISR: Zygomatic Implant Survival Rate; ISS: Implant Success Rate; CT: Computer Tomography; DICOM: Digital Imaging and Communications in Medicine; MUA: multi-unit abutments; STL: Standard Triangle Language.

Introduction

Oral rehabilitation of atrophic maxillae is currently supported by several advanced implant and prosthetic techniques, which were introduced and developed over the years. Today, mini-invasive options include tilted, short and pterygomaxillary implants¹⁻³. However, classical reconstructive approach is by maxillary sinus lift, bone autograft, and guided bone regeneration (GBR) or free bone flap rehabilitation techniques⁴⁻⁹. The main prognostic factor for each reconstructive procedure is the amount of residual bone at moment of surgical intervention and it is considered as a more predictive element than the chosen grafting material itself¹⁰. It is reported in literature that almost 30% of bone volume is lost at 10 years of follow-up, that was obtained by using bone grafting procedures^{11,12}. Furthermore, together with high rate of bone resorption, limitations in verti-

cal bone augmentation and in soft tissue coverage (with the consequent risk of bone exposure) and risk of morbidity at autogenous tissue harvesting site are some of the disadvantages of bone autografts¹³. As an alternative, zygomatic implants (ZI) were first described by Linkow in 1970¹⁴ and later were improved by Brånemark in 1988¹⁵⁻¹⁷. ZIs were originally proposed as an indication, in cases of severe bone loss consequent to oncological disease or congenital deficiencies. However, currently, they are considered as an alternative to bone augmentation and invasive surgery in the rehabilitation of severely atrophic maxilla, guaranteeing a limitation in bone grafting procedures and a reduction in surgical and treatment time¹⁸⁻²¹. Another advantage of ZI placement is its ability to support immediate loading, which results in an acceleration for the occlusal function recovery and a decrease in costs^{22,23}.

The original intra-sinusal placement technique for ZI insertions described by Brånemark was later replaced by an extra-sinus insertion process, which allowed a more anatomically and prosthetically guided approach²⁴. The reason was original protocol led to possible inflammatory side effects and to an excessive angulation in the palatal emergence of the implant head, making prosthetic treatment complicated^{17,25}. The extra-sinusal insertion procedure, which is currently mostly being used, minimizes the involvement of the maxillary sinus respiratory space, avoiding the creation of a slot or window in the lateral sinus wall and making membrane elevation unnecessary, and such conditions ensure a total preservation of the sinus function. Moreover, using the extra-sinusal technique, the implant head is placed at or near the top of the residual crest, giving the bridge framework an adequate extension^{26,27}.

As a guidance for the ZI placement, considering the inter-/ intra-individual anatomic differences, in 2011 Aparicio²⁸ introduced a new concept, which is called zygomatic anatomy-guided technique (ZAGA). In ZAGA technique, the implant insertion point is defined based on the vertical and horizontal resorption of the alveolar or basal process and on the anterior maxillary wall curvature. By this, ZIs are placed following specific anatomical, biochemical, and prosthetic parameters²⁹. Based on analysing the relationship between the zygomatic buttress and the intra-oral insertion point, the implant passage can vary from intra-sinus to fully extra-sinus, adapting to each maxillary specific anatomy^{30,31}.

Currently, additional to oncological patients, who underwent large jaw resections, and syndromic or malformed subjects^{32,33}, ZIs are utilized in individuals over the age of 60-65 affected by total edentulous and severely atrophic maxilla, with the aim of immediate implant-prosthetic rehabilitation. Furthermore, ZIs can also be considered as a second option in case of previous failure of bone augmentation procedures in patients older than age 65³⁴. Today, new approaches are available with advances in CAD/CAM (Computer Aided Design/Computer Aided Manufacturing) surgical techniques, such as Computer Aided Surgery (CAS). CAS was initially mostly employed in oral prosthetic surgery, and in the last decades, it is considered as one of the main tools to be considered for craniofacial reconstructions³⁵⁻³⁹.

Literature does not provide much study about surgical CAS accuracy in ZI placements, just few reports on cadavers⁴⁰⁻⁴² and reports on prosthetic accuracy with the aid of intra-surgical navigation systems⁴³. This lack of data might be explained by the effort required to position the surgical guides correctly for milling tools in the oral cavity; as a matter of fact, surgical tools in zygomatic implant surgery are quite different and bigger than the traditional ones. For this reason, the placement and fixation of surgical guides can be complex and challenging, especially in patients that have teeth in their lower jaw. The aim of this pilot study was to evaluate the accuracy and of novel guided ZI technique “Inverted Support Technique” (EZgoma[®], Noris Medical, Israel) which may provide a reliable and reproducible transfer from the virtual plan to the operating room. As secondary objectives, the factors which may affect the surgical technique results were assessed, such as implant-prosthetic virtual plan and surgical model matching, intra-/post-operative complications, time rate between surgical procedure and prosthetic loading, zygomatic implant survival rate (ISR) and implant success rate (ISS).

Patients and Methods

This study was designed as a retrospective clinical case series study to evaluate the outcomes. The study protocol followed the principles laid down in the Declaration of Helsinki on medical protocol and a signed informed consent agreement form was obtained from all the patients before the procedures. Patients were treated

between January 2019 and January 2022 at “Fondazione IRCCS Ca’ Granda Ospedale Maggiore Policlinico” or “Orthopedic Institute Galeazzi” which are the units of the Department of Oral Science and Maxillofacial surgery, University of Milan. Institutional review board approval of the Orthopedic Institute Galeazzi unit of University of Milan was obtained for retrospective studies on implants with number 2552377-L2058.

The study population consisted of patients that had edentulous severely atrophic maxillary bone that received zygomatic implants by a novel guided surgical protocol that is described in detail below.

Inclusion Criteria

Patients were included in this study only if they met the following inclusion criteria:

- ≥ 18 years old;
- Quad Zygomatic implants inserted with “Inverted Support Technique”;
- Non oncological patients;
- patients that had edentulous severely atrophic maxillary bone.

Exclusion Criteria

- Active infection in oral maxillofacial region;
- Immunocompromised, oncologic patients, organ failures, or HIV patients.

5 patients met the inclusion criteria and had 20 ZIs inserted with the surgical technique that is described below in details.

The surgical protocol “Inverted Support Technique” that is described in this pilot study aimed

at finding solutions to challenging situations for guided zygomatic implant surgery (by introducing a modified surgical guide and milling tools specific for zygomatic surgery, that can be used in narrow surgical fields, as the oral cavity) (Figure 1). In brief, the design of the surgical guide consisted of two titanium bone-fixed guides- with a slot (one for each side- left and right sides of the patients) and a concave section on the alveolar ridge and a convex section on the anterior wall of the maxillary sinus (Ezgomat[®], Noris Medical Ltd, Israel). Once fixed with specific screws on the maxillary bone, this new type of guide allowed the milling tools to slide in a sort of osseous tunnel (patient specific slot for each ZI), until all the maxillary-zygomatic bone was reached, enabling the placement of the ZIs. Furthermore, this procedure used a single prosthetic guide that made immediate loading possible.

Inverted Support Technique Guided Zygomatic Implant Surgery Flow-Chart

Step 1. preoperative phase

Pre-operative CT (Computer Tomography) scan plays a major role in the prosthetic rehabilitative course performed with guided zygomatic surgery. High Resolution CT scanning with slice thickness < 0.4 mm was performed with the patient wearing a barite denture prosthesis, to plan the correct implant position, considering the bony structure. Dental impressions were obtained with intra-oral scanner and were added to the CT files. DICOM data of preoperative CT scans and dental impressions (derived from intra-oral scan-

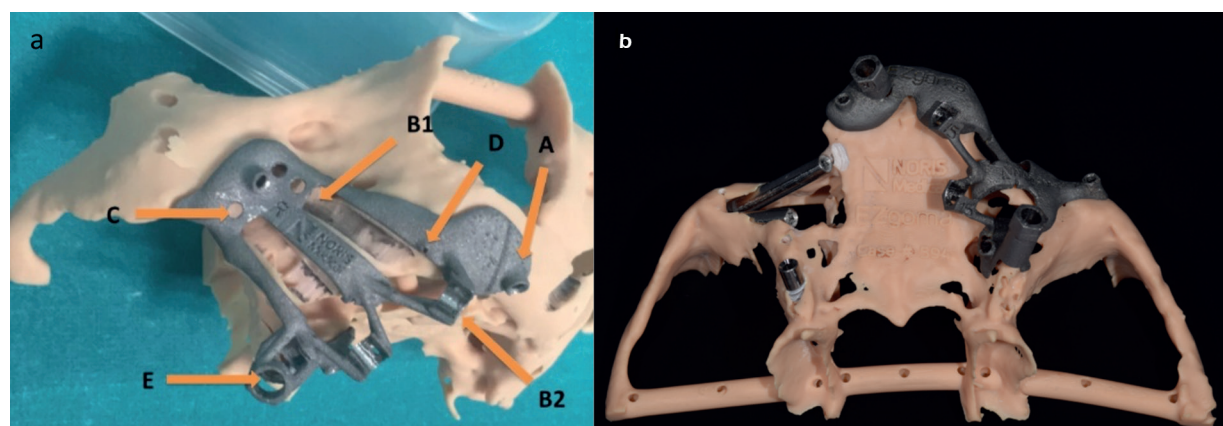


Figure 1. The design of the titanium guide for guided zygomatic implant surgery with inverted support technique. **a.** Fixation screw slot; **B1** and **B2.** Hemi-bushes (Zygomatic implant preparation site guidance slots); **C.** Irrigation holes; **D.** Implant platform stop line; **E.** Pterygomaxillary implant slot. **b.** The design of the titanium guide from occlusal view with 2 zygomatic implants and a pterygomaxillary implant inserted on the collateral side of the anatomic model.

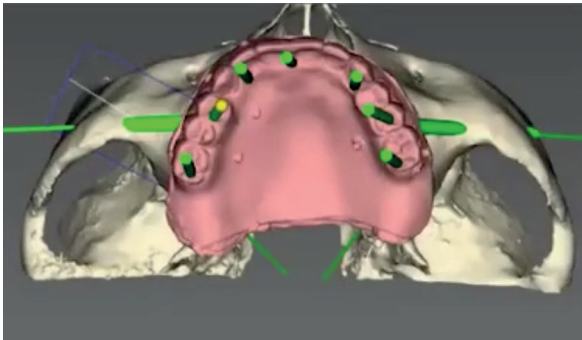


Figure 2. CT file and prosthetic project data transfer.

ner) were transferred through the TRUMATCH CMF solution ProPlan CMF Connect internet software platform (DePuy/Synthes in cooperation with Materialise, Belgium) to medical engineers, who check the quality of images (Figure 2). Low resolution CT scans were excluded and repeated, because of the higher risk of errors during the web meeting, condition that consequently leads to the malposition of surgical guides and zygomatic implants.

Prior to the web meeting data, preparatory work (segmentation of all the transferred data and 3D reconstruction of the relevant surgical anatomical structure) was completed by medical engineers. During the web meeting, both surgeon and medical engineer had the same view on their computer screen, so that the latter was able to implement surgeon's reconstructive/prosthetic re-

habilitation project. The real time planning guaranteed the possibility to face and directly modify any aspect of the project (the length and the bony position of the ZI, comparing the final parameters with the initial rehabilitative project sent). Once the web meeting is completed, the medical engineer assessed the surgical plan, sending the final report to the surgeon, who had the task of checking it up, and confirming its validity (Figure 3-4). At this point, the manufacturing of the anatomical models and surgical guides and plates required approximately 15 days to be completed.

Step 2. surgical procedure

Inverted Support Technique, involved the use of a set of specific initial milling tools kit, provided by the company (Noris Medical, Israel). However, since the operating field is the same as the traditional method, the final drill specific kit was the same with traditional zygomatic implant kit. The surgical guides were planned and placed observing the traditional anatomical landmarks proper to zygomatic dental implantology (taking into caution anatomical regions such as the piriform aperture, the infraorbital nerve, the tuber maxillae, and the zygomatic insertion of the masseter muscle).

Once a mid-crestal incision below the nasal spine and vertical releasing incisions along the posterior part of the infra-zygomatic crest were made (considering the emergence of Stensen's duct), a mucoperiosteal flap was raised. The elevation of the mucoperiosteal flap allowed the

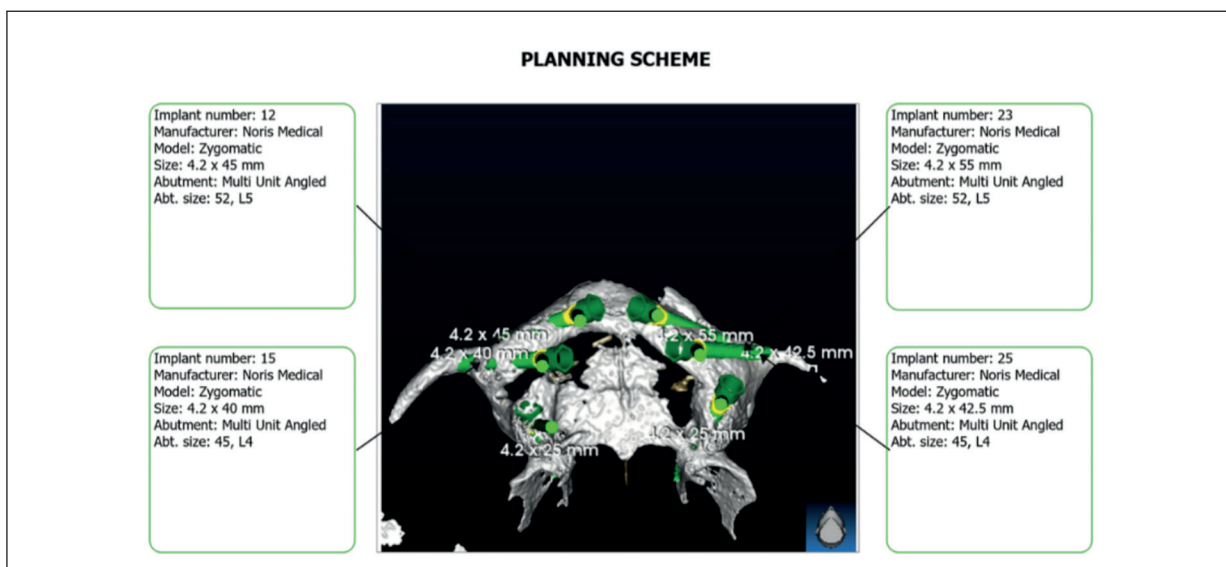


Figure 3. Pre-operative surgical planning.

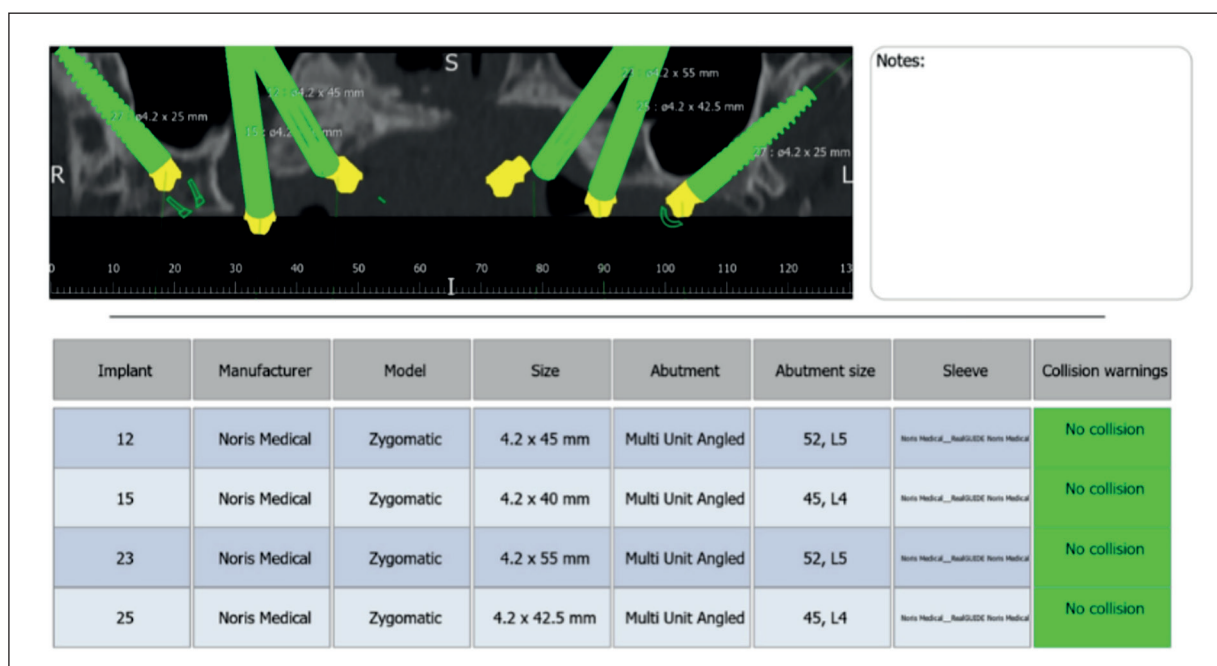


Figure 4. Pre-operative surgical planning showing details of the implants.

exposition of the central and posterior part of the zygomatic complex, the lateral wall of the maxillary sinus and the alveolar crest, to guarantee a correct surgical prosthetic guide placement. The use of a surgical guide helped to avoid the risk of the orbital cavity involvement and eliminated the need to control the subcutaneous exit of the ZI. During the whole surgery, the surgeons paid attention not to injure the emergence of the descending palatine artery, which, due to anatomical evolution of the atrophic maxilla, may arise in the alveolar crest.

The surgical prosthetic guide was fixed to the bone with at least 3 EZgoma[®] kit screws, which was performed with the aid of either contra-angled or straight handpiece, depending on the choice of the operator. The surgery continued with sequence of drills and burs, which were mounted on contra-angles handpiece, and in compliance with the instructions from the company. In brief, a round diamond bur (4 mm diameter) was placed (in the convex part of the titanium guide) on the anterior aspect of maxillary sinus, to create a groove, guaranteeing the placement of the second cylindrical diamond bur. At this point, the Schneiderian membrane became visible and depending on the surgeon choice and the situation, it was elevated or left without any elevations. The grinding of the groove was the next step us-

ing a cylindrical diamond bur with a non-working tip. The preparation of the implant site continued with drilling with a pilot drill (2.8 mm) by using with a blue sleeve support and drilling with drills increasing in dimensions accordingly to the ZI planned for the surgery. Implant length was measured using a specific tool and the anterior implant was placed first followed by the posterior implant insertion following the same steps with a minimum torque of 40 Ncm (in this work in all 19 ZIs primary stabilization was obtained except for one ZI). The multi-unit abutments (MUA) were placed using a shoulder preparation drill, avoiding bone disturbances which may compromise the correct screwing. At the end of the site preparation, the ZIs were placed with the aid of a positioning glide, which has the same length of the final shoulder preparation bur. The last phase involved the implant indexing: the prosthetic components parallelism was ensured by implant positioning glide. Attention must be paid during the phase of zygomatic implant screwing (with the aid of a straight extra-oral screwdriver, the hole passing through the positioning glide and the hole localized on the guide must match on the alveolar ridge; a control pin, passing through the two bores, must confirm the correct position and rotation of the ZI).

Figures 5 to 9 show representative pre-oper-

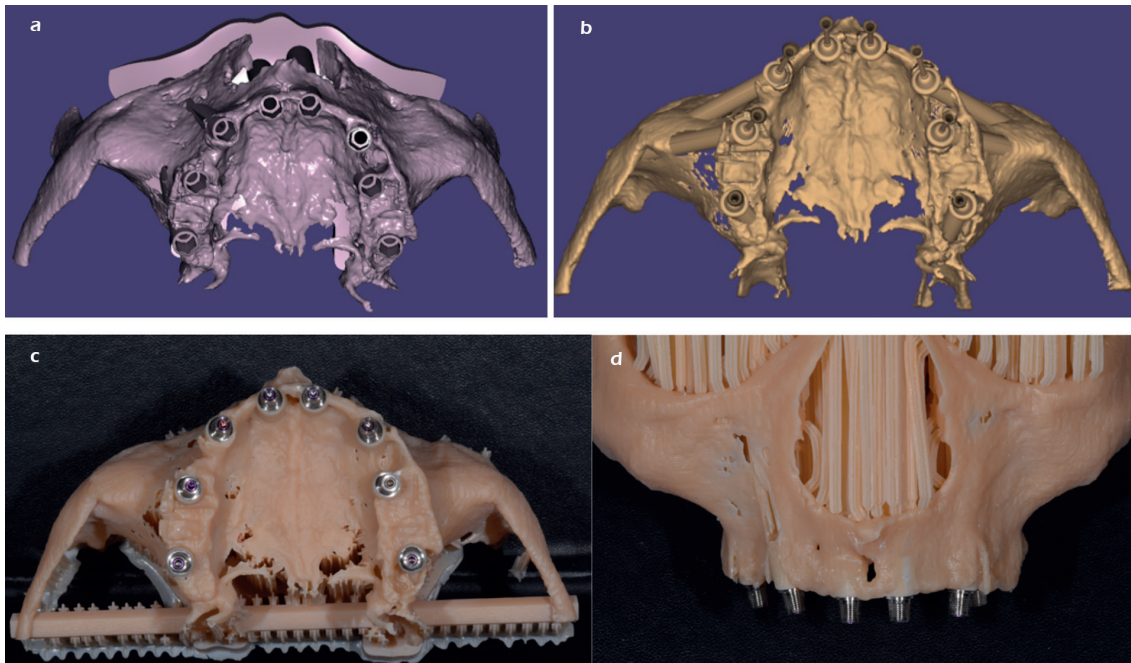


Figure 5. Figures a-d, show pre-operative planning of implant and mono-unit abutments of one patient.

ative planning and placement of implants, mono-unit abutments and final prosthesis of one the patients.

Step 3. accuracy evaluation

The main objective of this study was the evaluation of zygomatic implant final position

in terms of accuracy, considering the zygomatic final position that was firstly established during the virtual planning. The evaluation was performed with the aid of a tridimensional imaging elaboration platform, provided by Geomagic, which allows the overlay of virtual plan STL

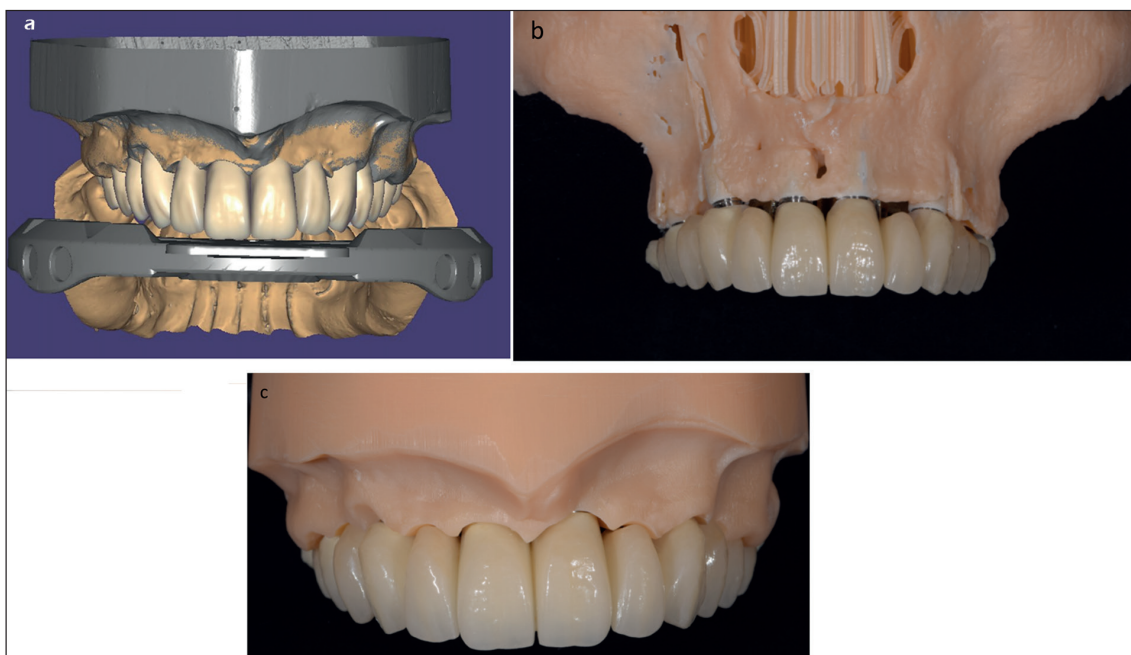


Figure 6. Figures a-c, show pre-operative planning of prosthesis in the same patient.

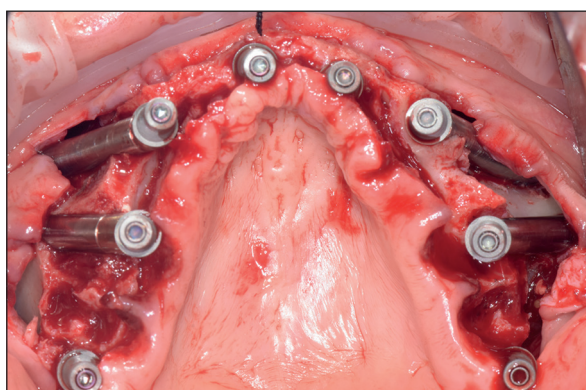


Figure 7. Intra-operative view of the same patient showing Quad zygomatic implants and two pterygoid implants in position.

data with post-operative control CT scan DICOM data. CT scan was performed on the first postoperative day.

Considering the facial skull as the main anatomical landmark, the key points used for comparison:

1. ZI apex;
2. ZI base (platform);
3. Implant axis.

The first two key points gave a linear millimetric value, analyzed in the X-Y-Z coordinate system, allowing the definition of the potential error in the anteroposterior, craniocaudal and mediolateral directions. The last one point, expressed in degrees, was analyzed in the three spatial planes too. For every key point a mean value was obtained from the included subjects. The selected sample was then divided in subgroups, considering:

- Implant site: anterior/posterior;
- Implant side: right/left;

- Implant length and average error correlation.

The results obtained by these subgroups were later compared with the mean value of every key point.

Literature described a mean difference of 2.5 mm for linear values and approximately of 3 degrees for angular value⁴². Accuracy evaluation required a double measurement, in order to evaluate the matching between the pre-operative virtual plan implant position and the implant final position at the end of the surgery: the first measure needed was a linear measurement, that represented the distance between two specific points of the same tridimensional image part; the second one derived from the distance analysis on XY-YZ-XZ spatial plane between two specific points. In order to obtain these measurements, the two previously mentioned STL files were mandatory: the virtual planning and the post-operative CT scan data.

In the former, the axis, the apex and the head mean point of every implant were identified; in the latter, the points were first recognized on a two-dimensional image, provided by post-operative CT scan. The points were then transferred in a tridimensional placed implant image, obtained by the conversion of the two-dimensional CT scan data, with the aid of Mimics software, using a HU (Hounsfield unit) threshold (min 2239; max 3071). The models and images were exported as STL and IGES format respectively. STL files were then uploaded in Geomagic software to be aligned and to perform deviation analyses. The virtual plan model was blocked in a standard position, in order to avoid any type of movement during the matching with the surgical result model: the final matching was then analyzed by the software.

After that, STL files were exported to perform a linear and absolute analyses with the aid of

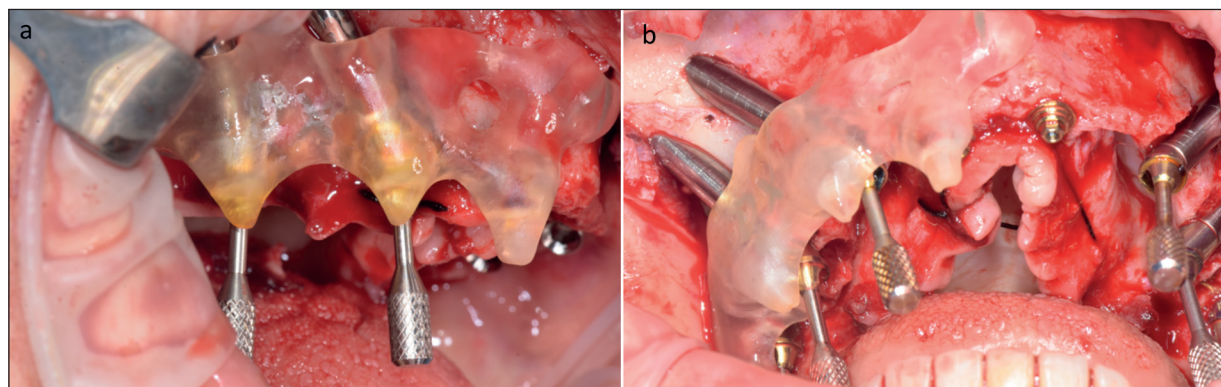


Figure 8. Figures a-b, show intra-operative view of the same patient showing abutments

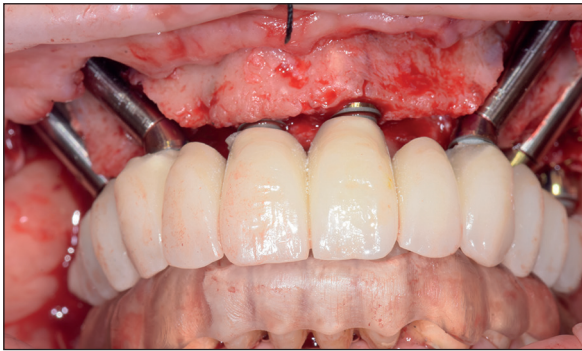


Figure 9. Intra-operative view of the same patient showing prosthesis trial which shall be immediately loaded.

CATIA V5. Once the matched file was uploaded, basal surfaces were highlighted through STL file specific mesh: at that point, it was possible to obtain the pre-operative virtual plan implant position. On the contrary, the key points of the surgical implant final position were identified through IGES file, provided by Mimics; the implant axis was obtained using the Geomagic surface recognition feature.

In the end, the geometrical landmarks were compared and measured.

Step 4. Evaluation of Secondary Objectives

Intra-Operative Complications:

The following complications were evaluated as described by Bedrossian et al⁴⁴ in 2018:

- Orbital cavity involvement,
- Intra-cranial involvement,
- Subcutaneous emergence of the zygomatic implant apex,
- Zygomatic fracture,
- Failure of zygomatic implant.

Post-Operative Complications:

The following complications were evaluated as described by Chrcanovic et al¹⁶ in a systematic review:

- Sinusitis,
- Paresthesia or sensibility alteration of v2,
- Mucositis,
- Oro-antral communication and fistula.

Surgical Procedure and Denture Prosthetic Placement Time Interval

A recent randomized controlled trial⁴⁵ highlighted that underlined that in ZI surgery, the prosthetic loading could be performed on post-operative day 1 to 3, considering as day 0 the surgical procedure date. In fact, the low time in-

terval between surgical procedure and prosthetic loading is one of the strengths of the zygomatic implant surgery, compared to conventional dental implant procedure, in severe atrophic maxillae. In this study the time interval for prosthetic denture loading were calculated and compared with the available literature data.

Implant Survival and Success Rate

Implant Survival Rate (ISR) represents the number of placed and osseointegrated implant fixture during the follow up time. ISR differs from the implant success rate, which represents the number of placed, osseointegrated and suitable for prosthetic denture loading implant fixture during the follow up time. In this study, both of them were expressed as percentage value, and were calculated and compared with literature data.

Statistical Analysis

Quantitative data were summarized using mean values and standard deviation for normally distributed data. Normality was evaluated using the D'Agostino and Pearson's omnibus normality test. Implant success and survival rate were evaluated by frequency analysis. The differences between planned and placed implant size was determined by using the paired *t*-test. The analysis was made using the software SPSS[®] version 28.0 for windows (IBM Corp., Armonk, NY, USA).

Statistical significance was considered for *p*-values <0.05.

Results

A total of 20 ZIs were placed in 5 patients (1 male and 4 female) with an average age of 62.2 years (range 54-68). The average follow-up time was 15.9 months. The included patients required zygomatic implant prosthetic rehabilitation for edentulism, due to severe maxillae atrophy (3 patients), fibula free flap failure and cleft lip and palate sequelae (2 patients). In all patients four (Quad) zygomatic implants were inserted while for patients A, B and E two additional pterygoid implants were placed. Patient B needed a particular denture prosthesis with a specific rising flanged component, to obliterate oro-nasal communication in cleft lip and palate sequelae. Toronto Bridge prosthetic denture type was used in 4 out of 5 cases. Further details about patient demographics can be found in Table I.

Table I. Demographics of the included patients.

Patient	Age	Sex	Comorbidities	Nature of edentulism	Rehabilitation solution	Prosthesis
A	64	M	Hypertension	Free flap failure	QUAD ZI + 2 pterygoid implants	Toronto Bridge
B	63	F	--	Cleft lip and palate sequelae	QUAD ZI + 2 pterygoid implants	Prosthetic denture with a removable obturator
C	68	F	--	Severe atrophy	QUAD Z	Toronto Bridge
D	62	F	Hypertension	Severe atrophy	QUAD	Toronto Bridge
E	54	F	HIV/HCV	Severe atrophy	QUAD ZI + 2 pterygoid implants	Toronto Bridge

ZI: Zygomatic Implant.

Surgical accuracy values are reported in Table II. No complications were recorded in 4 out of 5 subjects. 19 out of 20 surgically placed zygomatic implants were analyzed (In patient A, ZI was replaced in 1.5 slightly distal in position, compared to the virtual plan, since it didn't reach a steady

anchorage in the preoperative planned position. For this reason, it was not taken into consideration for statistical evaluation).

All the 3 measurements of the 19 placed zygomatic implants were in accordance with the universally agreed values in guided ZI surgery (2.5

Table II. Discrepancies of mean values in the included patients.

Patient	ZI position	Linear distance of implant platform (mm)	Linear distance of implant apex (mm)	Angular deviation of implant axis (°)
A	12	2.94	2.31	1.87
	15	X	X	X
	22	0.88	0.93	0.95
	25	1.26	1.20	1.62
A mean value		1.69	1.48	1.47
B	12	1.76	1.63	2.24
	15	1.91	1.43	0.71
	22	2.60	1.33	0.77
	25	1.12	1.23	3.04
B mean value		1.85	1.40	1.69
C	12	1.23	1.84	2.01
	15	0.65	1.23	2.31
	22	1.15	2.36	0.69
	25	3.23	2.06	1.56
C mean value		1.57	1.87	1.64
D	12	2.01	1.47	1.87
	15	0.99	0.99	4.25
	22	0.86	1.85	1.68
	25	2.9	2.63	1.28
D mean value		1.69	1.73	2.27
E	12	1.49	0.65	1.96
	15	1.23	0.98	0.86
	22	1.41	2.96	1.52
	25	0.54	1.78	1.86
E mean value		1.17	1.59	1.55
Total mean value		1.59	1.62	1.74
Standard deviation		± 0.81	± 0.62	± 0.87

*Values above 2.5 mm for Linear distance of implant platform (mm), and the angular deviation of the implant axis higher than 3° are highlighted in red.

mm for the linear distances and 3° for the angular deviations). Values obtained from this work were as follows:

- Mean linear distance of the implant platform: 1.59 mm;
- Mean linear distance of the implant apex: 1.62 mm;
- Mean angular deviation of the implant axis: 1.74°.

Considering the linear distance of the implant platform evaluation, only 3 out of 19 (16%) ZI had a mean linear distance higher than 2.5 mm; 11 out of 19 zygomatic implant (58%) had a mean linear distance between 1 mm and 2.5 mm, and 5 (26%) had a value inferior to 1 mm.

Considering implant apex mean distance, in only 2 cases (11%) there was a linear distance higher than 2.5 mm; 13 cases (68%) presented a mean value between 1 mm and 2.5 mm and the remaining 4 cases (21%) had a value inferior to 1 mm.

The angular deviation of the implant axis was higher than 3° only in 2 out of 19 implant (11%). As shown in Table III, no statistically significant differences were found on different implant subgroups distribution (anterior vs. posterior; left vs. right; < 45 length vs. > 45 length).

The results of this report were then compared with the ones proposed by Testori et al⁴⁶, where different guided surgical systems were evaluated in terms of accuracy and precision. This comparison pointed out two main factors:

- No substantial differences were recorded between the standard approaches and the zygomatic guided prosthetic surgery in terms of linear distance values.
- Despite ZI presents an almost four times longer structure, they had an angular deviation inferior to the traditional implant (1.74° vs. 3.26°).

The evaluation of the results regarding the match between digitally planned implant components + MUA and the rehabilitative procedure performed in the surgery room can be find in Table IV.

Final position was modified in only one zygomatic implant (right posterior, patient A) because of the absence of a steady bone anchorage; consequently, in order to favor the following rehabilitative prosthetic steps, it was necessary to modify two MUAs, compared to the digital preoperative planning. The matching rate between virtual planning and surgical outcome was demonstrated to be of 95% and 90%, considering respectively zygomatic implant and MUA.

In addition to the failure of a steady bone anchorage in ZI (A patient ZI position #15), the anterior maxillary aspect fracture during D patient ZI position #12 placement occurred, which did not affect the results of both surgical procedures and the immediately prosthetic loading. Considering the prosthetic denture loading, in 3 patients the temporary denture was placed on day 0; in patient B and C the temporary prosthetic denture was delivered on day 1 and day 4, in conformity with the mean time of the immediate loading on zygomatic fixture reported by literature, which varies from 1 to 3 days after surgery.

Currently, only two cases of mucositis were registered, precisely on D patient ZI position #12 and E patient ZI position #22 implants, probably caused by the bulkiness of the temporary denture; in fact, once the definitive denture was placed, providing a better oral hygiene, an improving in terms of inflammation was noticed.

Every treated patient received the definitive denture based on zygomatic fixture almost 6 months after the surgical procedure, after the reaching of complete healing of intra-oral tissue and osseointegration. There were no severe

Table III. Discrepancies mean values in the subgroups.

	N° of ZI	Linear distance of implant platform (mm)	Linear distance of implant apex (mm)	Angular deviation of implant axis (°)
Anterior ZI	10	1.63	1.73	1.56
Posterior ZI	9	1.54	1.50	1.94
	<i>p</i> < 0.05	No	No	No
Right ZI	9	1.58	1.39	2.01
Left ZI	10	1.60	1.83	1.50
	<i>p</i> < 0.05	No	No	No
ZI Length ≤ 45 mm	11	1.58	1.55	1.91
ZI Length > 45 mm	8	1.59	1.73	1.50
	<i>p</i> < 0.05	No	No	No

Table IV. Comparison of digitally planned and surgically placed implant results.

Patient	Implant position	Implant length planned, mm	Implant length placed, mm	Multi-unit abutment planned, degrees	Multi-unit abutment placed, degrees
A	12	55	55	45	45
	15	40	42.5*	45	52*
	22	55	55	52	52
	25	42.5	42.5	45	52*
B	12	55	55	45	45
	15	52.5	52.5	45	45
	22	45	45	45	45
	25	40	40	45	45
C	12	52.5	52.5	45	45
	15	40	40	52	52
	22	50	50	45	45
	25	42.5	42.5	30	30
D	12	52.5	52.5	52	52
	15	42.5	42.5	45	45
	22	47.5	47.5	45	45
	25	32.5	32.5	45	45
E	12	45	45	45	45
	15	35	35	45	45
	22	42.5	42.5	45	45
	25	30	30	30	30

*Values different from the planned.

post-operative complications which precluded the prosthetic loading, survival or osseointegration of the implants. Clinical results of the included patients who underwent surgical procedure for guided ZI prosthetic rehabilitation are shown in Table V. According to the results, the survival and success rates for the zygomatic implants placed

with the aid of EZgoma[®] inverted support technique were 100%.

Discussions

On the base of the data collected in this study, the aim of a guided surgical technique may im-

Table V. Clinical results of included patients.

Patient	Implant position	Follow-up, months	Intra-operative complications	Prosthetic load, days after surgery	Post-operative complications
A	12	18	No	0	No
	15	18	Torque < 40 N	0	No
	22	18	No	0	No
	25	18	No	0	No
B	12	17	No	1	No
	15	17	No	1	No
	22	17	No	1	No
	25	17	No	1	No
C	12	15	No	4	No
	15	15	No	4	No
	22	15	No	4	No
	25	15	No	4	No
D	12	13	Fracture of the anterior wall of the maxillary sinus	0	Mucositis
	15	13	No	0	No
	22	13	No	0	No
	25	13	No	0	No
E	12	12	No	0	No
	15	12	No	0	No
	22	12	No	0	Mucositis
	25	12	No	0	No

prove the surgical results and rehabilitative protocol in terms of accuracy and precision. Several papers sustain the necessity of a preoperatively defined, minimal invasive, rapid, reliable, and reproducible guided surgery^{39,46-48}. However, considering the clinical and post-operative results currently presented, there is no universal agreement and consensus in terms of precision and replicability.

Chrcanovic et al⁴¹, who firstly published experimental results during his study based on cadavers' zygomatic implant-guided surgery, reported a clear difference regarding angular deviation between virtual plan and actual surgical results, from 8° to 11°. Moreover, considering that the mean length of the ZI is 45 mm, the implant apex value of the surgical procedure can involve a linear mismatch superior to 1 cm compared with the virtual plan. Another drawback in guided surgical type proposed by Chrcanovic is the effort in maintaining the bur and drill control during their milling path to the zygomatic bone, since the surgical mask can only check the early-stage position on the alveolar bone ridge^{41,49}. To avoid this problem, Chow et al⁵⁰ proposed a double surgical guide, divided into a mucosa-supported part with two cylindrical bushes and another one that, once steady and fixed on the previous one, is able to control the bur apex after antrostomy occurred. However, the oral cavity dimensions do not allow two surgical guides and results in terms of accuracy could be negatively influenced by this reason.

Rinaldi et al⁵¹ placed 10 ZI with a specific plastic surgical guide, reporting that linear deviations between the virtual planning and the actual implant position ranged from 2 mm to 3 mm with angular deviations ranging from 1.88 to 4.55 degrees. Up to date, no zygomatic guided surgical technique, was able to afford the universally agreed values in guide zygomatic implant surgery, that has been introduced (2.5 mm for the linear distances and 3° for the angular deviations⁴²). Consequently, none of the existing techniques represented so far, is a reliable, surgically comfortable, minimal invasive and a rapid solution. The surgical guide presented in this pilot study reached the above-mentioned values in 19 out of 20 zygomatic implants. This goal was achieved thanks to the presence of a special and specific kit, that focused all its features to work comfortably in the oral cavity narrow space, reducing, at the same time, oral tissues impairment. Although one zygomatic implant did not reach a primary steady anchorage, the other 19 ZIs were comfortably placed, without any type of intra – or post – operative complications. The final mean angular deviation <

2° made the inverted support technique viable, allowing the drills and burs to work coaxially during the zygomatic path preparation.

During the virtual planning, the mean linear difference of ZI apex, approximately of 1.62 mm, should be considered: when two implants per side are planned, the anterior one could be placed very close to the orbital recess. In this study, no orbital damages occurred. The linear difference of 1.59 mm at the implant platform level represents a great success, enabling the immediate loading of the ZI directly in operating room. Once fixed with specific screws, the surgical guide provides a reliable positioning path, ensuring the oral tissue protection from drills and burs and guaranteeing mini – invasive features. Virtual preoperative planning and actual surgical results matching confirms the reliability of CAS planning also in terms of materials, implants, and MUA. In this work, only two MUAs (A15-A25) were modified to reach the prosthetic parallelism, since a different zygomatic implant length was necessary.

As described in literature^{16,52}, the zygomatic implant failure generally occurs in the early six months after the procedure, while other complications, like sinusitis, mucositis or oroantral fistula may arise later, and for this reason, a thorough follow up is mandatory. Especially, mucositis cases are quite frequent since (in addition to surgical trauma, inducing an oral tissue remodeling) in the early post-operative phase, the food remnants can enter and remain in the zygomatic implant connection, causing a mucosal irritation. In this study, two ZIs developed mucositis because in the early post-operative period, during the final denture contouring, due to improper oral hygiene. However, there was no need of additional surgical intervention, as the modifications of dentures flanges and surface that were applied, improved the alveolar ridge-implant-denture relationship by reducing mucosal irritation and meal trapping.

Conclusions

Even though multiple accurate theories and classifications have been described, maxillary atrophies development is still unpredictable: the main factor that affects the alveolar ridge reshaping is the modification of the occlusal and masticatory action, resulting to dental loss. Zygomatic implant surgery, with or without the aid of a preoperative virtual planning, currently allows to solve several issues that were only par-

tially faced by other previous prosthetic reconstructive options. According to the encouraging results of this study (in terms of precision and accuracy, meeting traditional guided prosthetic surgery requests, the high success and survival rate combined with a low percentage of complications) showed that CAD/CAM zygomatic oral rehabilitation surgery is a reliable, efficient, rapid, ergonomic, and safe surgical protocol, that can guarantee satisfying and functional and aesthetic results, reducing treatment time and the need of prosthetic refinement procedures.

The limited sample number is one of the limitations of this work, however this pilot study should be considered as a preliminary introduction and description of a guided surgical technique, which might be a valid and safe alternative in patients with severely atrophic maxillary bone that do not have much option for oral rehabilitation.

Conflict of Interest

The authors declare no potential conflicts of interest with respect to the authorship and/or publication of this article.

Acknowledgements

None.

Availability of Data and Materials

Data is available upon request.

Funding

This study was funded by Italian Ministry of Health - Current research IRCCS.

Ethics Approval

Institutional review board approval of the Orthopedic Institute Galeazzi unit of University of Milan was obtained for retrospective studies on implants with number 2552377-L2058.

Informed Consent

The patients signed the informed consent before the study.

Authors' Contribution

A.R.B., F. Z., F.Ga., F.Go., P.B., M.D.F., C. M., F. Gr. and A. B. G. conceived and designed the analysis. Databases were searched and data was collected by F.Go., A.R.B., P.B. and M.D.F. Maxillofacial surgical interventions were per-

formed by F.Gr. and A.R.B. All the authors contributed on analysis and interpretation of data for the work. A.R.B., F. Z., F.Ga., F.Go., P.B., M.D.F. drafted the work and wrote the manuscript with input from all authors. A.B., A.R.B., C.M., G.B., A.R., D.S.R., M.R.D.P., M.D.F., C.M., A.B.G. revised the work critically for intellectual content. Integrity of the work was appropriately investigated and resolved by all authors. All authors contributed and approved equally to the final version of the manuscript.

References

- 1) Calandriello R, Tomates M. Simplified treatment of the atrophic posterior maxilla via immediate/early function and tilted implants: a prospective 1-year clinical study. *J Clin Implant Dent Relat Res* 2005; 7: 51-62.
- 2) Maló P, de Araújo NM, Rangert B. Short implants placed one-stage in maxillae and mandibles: a retrospective clinical study with 1 to 9 years of follow-up. *Clin Implant Dent Relat Res* 2007; 9: 15-21.
- 3) Balshi TJ, Wolfinger G, Balshi SF II. Analysis of 356 pterygomaxillary implants in edentulous arches for fixed prosthesis anchorage. *Int J Oral Maxillofac Implants* 1999; 14: 398-406.
- 4) Kahnberg KE, Ekestubbe A, Grondahl K, Nilsson P, Hirsch JM. Sinus lifting procedure. I. One-stage surgery with bone transplant and implants. *Clin Oral Implant Res* 2001; 12: 479-487.
- 5) Clayman L. Implant reconstruction of the bone-grafted maxilla: review of the literature and presentation of 8 cases. *J Oral Maxillofac Surg* 2006; 64: 674-682.
- 6) Becktor JP, Isaksson S, Sennerby L. Survival Analysis of Endosseous Implants in Grafted and Nongrafted Edentulous Maxillae. *Int J Oral Maxillofac Implants* 2004; 19: 107-115.
- 7) Aghaloo TL, Misch C, Lin GH, Iacono VJ, Wang HL. Bone Augmentation of the Edentulous Maxilla for Implant Placement: A Systematic Review. *Int J Oral Maxillofac Implants* 2016; 31: 19-30.
- 8) Von Arx T, Buser D. Horizontal ridge augmentation using autogenous block grafts and the guided bone regeneration technique with collagen membranes: a clinical study with 42 patients. *Clinical Oral Implants Research* 2006; 17: 359-366.
- 9) Nguyen TTH, Eo MY, Kuk TS, Myoung H, Kim SM. Rehabilitation of atrophic jaw using iliac onlay bone graft combined with dental implants. *Int J Implant Dent* 2019; 5: 11.
- 10) Aparicio C, Manresa C, Francisco K, Claros P, Aláñez J, González-Martín O, Albrektsson T. Zygomatic implants: indications, techniques and outcomes, and the zygomatic success code. *Periodontol* 2000 2014; 66: 41-58.
- 11) Kaing L, Grubor D, Chandu A. Assessment of bone grafts placed within an oral and maxillofacial training program for implant rehabilitation. *Aust Dent J* 2011; 56: 406-411.

- 12) Klijn RJ, Meijer GJ, Bronkhorst EM, Jansen. Sinus floor augmentation surgery using autologous bone grafts from various donor sites: a meta-analysis of the total bone volume. *Tissue Eng Part B Rev* 2010; 16: 295-303.
- 13) Blanc O, Shilo D, Weitman E, Capucha T, Rachimiel A. Extramaxillary zygomatic implants: an alternative approach for the reconstruction of the atrophic maxilla. *Ann Maxillofac Surg* 2020; 10: 127-132.
- 14) Leonard I, Linkow, Raphaël Cherchève. Theories and techniques of oral implantology. Mosby, 1970.
- 15) Brånemark PI, Grondahl K, Öhrnell LO, Nilsson P, Petruson B, Svensson B, Engstrand P, Nånberg U. Zygoma fixture in the management of advanced atrophy of the maxilla: technique and long-term results. *Scand J Plast Reconstr Surg Hand Surg* 2004; 38: 70-85.
- 16) Chrcanovic BR, Albrektsson T, Wennerberg A. Survival and Complications of Zygomatic Implants: An Updated Systematic Review. *J Oral Maxillofac Surg* 2016; 74: 1949-1964.
- 17) Brånemark PI. Surgery and fixture installation: zygomaticus fixture clinical procedures. Nobel Biocare, 1998.
- 18) Urgell JP, Revilla Gutiérrez V, Gay Escoda C. Rehabilitation of atrophic maxilla: A review of 101 zygomatic implants. *Med Oral Patol Oral Cir Bucal* 2008; 13: 363-370.
- 19) Reichert TE, Kunkel M, Wahlmann U, Wagner W. Das Zygoma-Implantat—Indikationen und erste klinische Erfahrungen. *Z Zahnärztl Implantol* 1999; 15: 65-70.
- 20) Boyes-Varley JG, Howes DG, Lownie JF. The zygomaticus implant protocol in the treatment of the severely resorbed maxilla. *SADJ* 2003; 58: 113-114.
- 21) Peñarrocha M, García B, Martí E, Boronat A. Rehabilitation of severely atrophic maxillae with fixed implant-supported prostheses using zygomatic implants placed using the sinus slot technique: clinical report on a series of 21 patients. *Int J Oral Maxillofac Implants* 2007; 22: 645-650.
- 22) Danza M, Grecchi F, Zollino I, Casadio C, Carinci F. Spiral implants bearing full-arch rehabilitation: analysis of clinical outcome. *J Oral Implantol* 2011; 37: 447-455.
- 23) Linkow LI, Winkler S, Shulman M, Dal Carlo L, Pasqualini ME, Rossi F, Nardone M. A New Look at the Blade Implant. *J Oral Implantol* 2016; 42: 373-380.
- 24) Davó R, Bankauskas S, Laurincikas R, Koçyigit ID, Mate Sanchez de Val JE. Clinical performance of zygomatic implants – Retrospective multicenter study. *J Clin Med* 2020; 9: 480.
- 25) Aparicio C, Manresa C, Francisco K, Claros P, Aláñez J, González-Martín O, Albrektsson T. Zygomatic implants: indications, techniques and outcomes, and the zygomatic success code. *Periodontol* 2000 2014; 66: 41-58.
- 26) Aparicio C, Ouazzani W, Aparicio A, Fortes V, Muela R, Pascual A, Codesal M, Barluenga N, Manresa C, Franch M. Extra-sinus zygomatic implants: three year experience from new surgical approach for patients with pronounced buccal concavities for the edentulous maxilla. *Clin Implant Dent Relat Res* 2010; 12: 55-61.
- 27) Boyes-Varley JG, Howes DG, Lownie JF, Blackburn GA. Surgical modifications to the Brånemark zygomaticus protocol in the treatment of the severely resorbed maxilla: a clinical report. *Int J Oral Maxillofac Implants* 2003; 18: 232-237.
- 28) Aparicio C. A proposed classification for zygomatic implant patient based on the zygoma anatomy guided approach (ZAGA): a cross-sectional survey. *Eur J Oral Implantol* 2011; 4: 269-275.
- 29) Aparicio C, Manresa C, Francisco K, Aparicio A, Nunes J, Claros P, Potau JM. Zygomatic implants placed using the zygomatic anatomy-guided approach versus the classical technique: a proposed system to report rhinosinusitis diagnosis. *Clin Implant Dent Relat Res* 2014; 16: 627-642.
- 30) Agliardi EL, Romeo D, Panigatti S, de Araújo Nobre M, Maló P. Immediate full-arch rehabilitation of the severely atrophic maxilla supported by zygomatic implants: a prospective clinical study with minimum follow-up of 6 years. *Int J Oral Maxillofac Surg* 2017; 46: 1592-1599.
- 31) Lombardo G, D'Agostino A, Trevisiol L, Romanelli MG, Mascellaro A, Gomez-Lira M, Pardo A, Favero V, Nocini PF. Clinical, microbiologic and radiologic assessment of soft and hard tissues surrounding zygomatic implants: a retrospective study. *Oral Surg Oral Med Oral Pathol Oral Radiol* 2016; 122: 537-546.
- 32) Pellegrino G, Basile F, Relics D, Ferri A, Grande F, Tarsitano A, Marchetti C. Computer-Aided Rehabilitation Supported by Zygomatic Implants: A Cohort Study Comparing Atrophic with Oncologic Patients after Five Years of Follow-Up. *J Clin Med* 2020; 9: 3254.
- 33) de Oliveira GJPL, Brackmann MS, Trojan LC, Ribeiro Júnior PD, Padovan LEM. Oral Rehabilitation with Zygomatic Implants in a Patient with Cleft Palate. *Case Rep Dent* 2019; 2019: 6591256.
- 34) Nyström E, Lundgren S, Gunne J, Nilson H. Interpositional bone grafting and Le Fort I osteotomy for reconstruction of the atrophic edentulous maxilla. A two-stage technique. *Int J Oral Maxillofac Surg* 1997; 26: 423-427.
- 35) D'haese J, Ackhurst J, Wismeijer D, De Bruyn H, Tahmaseb A. Current state of the art of computer-guided implant surgery. *Periodontol* 2000 2017; 73: 121-133.
- 36) Azari A1, Nikzad S. Computer-assisted implantology: historical background and potential outcomes—a review. *Int J Med Robot* 2008; 4: 95-104.
- 37) Bover-Ramos F, Viña-Almunia J, Cervera-Balaster J, Peñarrocha-Diago M, García-Mira B. Accuracy of Implant Placement with Comput-

- er-Guided Surgery: A systematic review and meta-analysis comparing cadaver, clinical, and in vitro studies. *Int J Oral Maxillofac Implants* 2018; 33: 101-115.
- 38) Marlière DAA, Demétrio MS, Picinini LS, De Oliveira RG, Chaves Netto HDM. Accuracy of computer-guided surgery for dental implant placement in fully edentulous patients: A systematic review. *Eur J Dent* 2018; 12: 153-160.
- 39) Deek NF, Wei FC. Computer-Assisted Surgery for Segmental Mandibular Reconstruction with the Osteoseptocutaneous Fibula Flap: Can We Instigate Ideological and Technological Reforms? *Plast Reconstr Surg* 2016; 137: 963-970.
- 40) Schirotti G, Angiero F, Zangerl A, Benedicenti S, Ferrante F, Widmann G. Accuracy of a flapless protocol for computer-guided zygomatic implant placement in human cadavers: expectations and reality. *Int J Med Robot* 2016; 12: 102-108.
- 41) Chrcanovic BR, Oliveira DR, Custódio AL. Accuracy evaluation of computed tomography-derived stereolithographic surgical guides in zygomatic implant placement in human cadavers. *J Oral Implantol* 2010; 36: 345-355.
- 42) Van Steenberghe D, Malevez C, Van Cleynenbreugel J, Bou Serhal C, Dhoore E, Schutyser F, Suetens P, Jacobs R. Accuracy of drilling guides for transfer from three-dimensional CT-based planning to placement of zygoma implants in human cadavers. *Clin Oral Implants Res* 2003; 14: 131-136.
- 43) Hung KF, Wang F, Wang HW, Zhou WJ, Huang W, Wu YQ. Accuracy of a real-time surgical navigation system for the placement of quad zygomatic implants in the severe atrophic maxilla: A pilot clinical study. *Clin Implant Dent Relat Res* 2017; 19: 458-465.
- 44) Bedrossian E, Bedrossian EA. Prevention and the Management of Complications Using the Zygoma Implant: A Review and Clinical Experiences. *Int J Oral Maxillofac Implants* 2018; 33: 135-145.
- 45) Davó R, Felice P, Pistilli R, Barausse C, Marti-Pages C, Ferrer-Fuertes A, Ippolito DR, Esposito M. Immediately loaded zygomatic implants vs conventional dental implants in augmented atrophic maxillae: 1-year post-loading results from a multicentre randomised controlled trial. *Eur J Oral Implantol* 2018; 11: 145-161.
- 46) Testori T, Robiony M, Parenti A, Luongo G, Rosenfeld AL, Ganz SD, Mandelaris GA, Del Fabbro M. Evaluation of accuracy and precision of a new guided surgery system: a multicenter clinical study. *Int J Periodontics Restorative Dent* 2014; 34: 59-69.
- 47) Ferri A, Varazzani A, Bolzoni AR, Monaca MD, Tarabba F, Tarsitano A, Zavatiero E, Gessaroli M, Copelli C, De Riu G, Baj A. A multicenter survey on computer-aided design and computer-aided manufacturing mandibular reconstruction from Italian community. *Microsurgery* 2019; 39: 673-674.
- 48) Bolzoni AR, Segna E, Beltramini GA, Sweed AH, Gianni AB, Baj A. Computer-Aided Design and Computer-Aided Manufacturing Versus Conventional Free Fibula Flap Reconstruction in Benign Mandibular Lesions: An Italian Cost Analysis. *J Oral Maxillofac Surg* 2020; 78: 1035.e1-1035.e6.
- 49) Watzinger F, Birkfellner W, Wanschitz F, Ziya F, Wagner A, Kremser J, Kainberger F, Huber K, Bergmann H, Ewers R. Placement of endosteal implants in the zygoma after maxillectomy: a Cadaver study using surgical navigation. *Plast Reconstr Surg* 2001; 107: 659-667.
- 50) Chow J. A novel device for template-guided surgery of the zygomatic implants. *Int J Oral Maxillofac Surg* 2016; 45: 1253-1255.
- 51) Rinaldi M, Ganz SD. Computer-Guided Approach for Placement of Zygomatic Implants: Novel Protocol and Surgical Guide. *Compend Contin Educ Dent* 2019; 40: 1-4.
- 52) Goker F, Grecchi F, Grecchi E, Del Fabbro M, Agliardi EL, Buccellato FRP, Greco Lucchina A, Gianni AB, Mortellaro C. Clinical outcomes of fully and partially threaded zygomatic implants in a cohort of patients with minimum 7.5-year follow-up. *Eur Rev Med Pharmacol Sci* 2022; 26 (3 Suppl): 35-44.