

# Hyaluronic acid accelerates re-epithelialization and healing of acute cutaneous wounds

F. DE FRANCESCO<sup>1</sup>, A. SAPAROV<sup>2</sup>, M. RICCIO<sup>1</sup>

<sup>1</sup>Department of Reconstructive Surgery and Hand Surgery, AOU "Ospedali Riuniti", Ancona, Italy

<sup>2</sup>Department of Medicine, School of Medicine, Nazarbayev University, Astana, Kazakhstan

**Abstract. – OBJECTIVE:** Hyaluronic acid has been efficient in ameliorating and supporting recovery in both chronic and acute lesions. The aim of this study was to assess the effectiveness of hyaluronic acid-based cream and gauze pads in cutaneous wounds.

**PATIENTS AND METHODS:** This retrospective and prospective study examines the use of a 0.2% hyaluronic acid cream or gauze-pads application (Connettivina Bio®). 85 patients participated in the study and were affected by wounds of different etiologies, comprising superficial trauma wounds (20), surgical sutures (15), first- and second-degree burns (15), dermabrasions (30) and ulcers of different etiologies (5). We analyzed the healing process in terms of progression and wound quality. Moreover, we performed biopsies (not on all patients) to evaluate the grade of re-epithelialization.

**RESULTS:** We observed a reduction in the mean surface area of the wounds, precisely 456 mm<sup>2</sup> at baseline to 147 mm<sup>2</sup> after six weeks with an average 80% decrease in the wound surface area. No fibrin tissue was observed, and a small amount of exudate was noted in 91% of wounds. Hyaluronic acid cream and gauze-pads-based treatments were well tolerated by patients. All groups showed a decrease of inflammation with a progressive increase of collagen fibers and granulation tissue.

**CONCLUSIONS:** The treatment with hyaluronic acid 0.2% yielded remarkable outcomes in the re-epithelialization of superficial wounds and provided favorable recovery and tolerance for patients.

*Key Words:*

Hyaluronic acid, Wound healing, Skin abrasions, Re-epithelialization, Regenerative medicine, Wound repair, Connettivina Bio®.

## Introduction

Hyaluronic acid (HA) was first identified in 1934 and has been thoroughly investigated since

then<sup>1-3</sup>. HA is a natural polysaccharide and is a key element in the extracellular matrix (ECM) consisting of a linear polysaccharide with alternating units of b-1,4-linked D-glucuronic acid and (b-1,3) N-acetyl-D-glucosamine<sup>4</sup>. HA possesses numerous physiological properties including structural and space-filling functions, lubrication, tissue and ECM water absorption as well as retention ability. It is a biocompatible polymer with several biological functions, such as skin moisturization and anti-wrinkle effects that support the natural healing process<sup>5-8</sup>. Additionally, numerous *in vitro* and *in vivo* studies<sup>9-10</sup> have revealed the wound healing ability of HA by enhancing mesenchymal and epithelial cell migration and differentiation, as well as improving angiogenesis and collagen deposition. Furthermore, HA promotes a favorable wound healing microenvironment with remarkable potential in treating scarring and wound healing overall<sup>11</sup>.

Wound therapy largely depends on different factors, including wound severity and pathophysiological status not to mention the medical condition and the degree of tissue damage concerning each patient. An adequate choice of wound dressing is fundamental towards a favorable therapeutic outcome. Acute wounds may involve healing issues and subsequent acute complications<sup>12</sup>. Wound healing intrinsically occurs in four established and complex phases which are hemostasis, inflammation, proliferation and remodelling<sup>13,14</sup>, involving soluble mediators, ECM formation, and parenchymal cell migration. The wound healing process generally requires prompt pain alleviation and wound closure with an aesthetically appropriate scar formation. Wound healing entails recovery of the skin barrier as well as restoration of an internal homeostasis, decreasing, besides, risks of infection and secondary complications. A perpetuation of the healing process and subsequent chronic wound development are indicators

of inadequate wound recovery and inevitably imply scar tissue generation.

HA has yielded positive outcomes in chronic wounds. However, few studies have revealed its benefits in relation to excoriations, skin abrasions and acute lesions even in cases of less complex wounds. This study investigated the healing process and wound quality in patients treated with HA-based cream or gauze-pads applications.

## Patients and Methods

We conducted a single-center, observational and retrospective study from January 2018 to December 2021 in outpatients affected by acute wounds to investigate the effectiveness of a 0.2% hyaluronic acid cream and dressing gauze pads (Fidia Farmaceutici, Abano Terme, Italy) during wound recovery. The study was conducted according to the Declaration of Helsinki and to the Guidelines for Good Clinical Practice. The study protocol was authorized by the Marche Regional Ethics Committee (CERM-Italy) (765/2022).

### *Patient Characteristics and Clinical Investigation*

A total of 85 patients, aged 18 years or over were included in the study suffering from wounds of different etiologies, precisely, superficial trauma wounds (20), surgical wounds (15), first- and second-degree burns (15), dermabrasions (30) and ulcers of different etiologies (5).

The wounds were treated with low molecular weight (200 kDa) hyaluronic acid (Connettivina Bio<sup>®</sup>, Fidia Farmaceutici SpA, Abano Terme, Italy) cream or gauze-pads. The treating physician determined the type of therapy depending on wound type and depth, ulcer expansion and etiology. The depth of the ulcers treated with the gauze-pads ranged from 0.1 to 1 cm, while the depth of those treated with the cream ranged from 1 to 1.3 cm.

The same therapeutic protocol was administered to all patients: the wound was disinfected, cleansed with saline solution and covered with hyaluronic acid 0.2% cream or gauze pads. Dressings were changed every day. Patients were followed up twice a week at our clinic where wounds were treated and observed for wound characterization, size, edges, exudate and peri-wound appearance. The treatment was administered until the wound was clean and granulating. No advanced dressing was applied, and total

wound healing was considered on completion of the normal re-epithelization process.

### *Assessment Methods*

During each visit, wound size and wound quality were evaluated. Changes in wound size are difficult to measure by length and width due to the irregular shape of the wounds; hence, we measured the surface area in cm<sup>2</sup> using squared transparent paper on which we traced the wound area with indelible markers (Oxford Health, NHS Foundation Trust guidelines). Wound quality was monitored for occurrences of eczema/dermatitis, black eschar, fibrin, scarring, resurfacing epithelium, degree of exudate as well as peri-wound appearance. Moreover, episodes of pain, bleeding and adherence were evaluated on dressing removal.

### *Wound Biopsies*

A total of 15 biopsies were performed during local anesthesia using a 2-mm biopsy punch (Kai Europe GmbH, Solingen, Germany). The biopsies were then stored in a 10% buffered formalin solution for histological and histomorphometric analysis.

### *Histological and Histomorphometric Evaluation*

All specimens were sectioned (5µm) and stained with hematoxylin-eosin for histological examination. The specimens were assessed by two masked technicians via light microscopy (Nikon Eclipse 600, Milan, Italy) and NIS-Elements Microscope Imaging Software (Nikon) to observe the cellular response in relation to fibrosis, inflammation and neovascularization. We examined three slides per sample using light microscopy at 20x for initial magnification. Moreover, each slide contained three sections of a specimen and we examined five fields per tissue section. A semi-quantitative investigation was conducted for specific cell types: Polymorphic Nuclear Cells, each cell contains a nucleus lobed into segments and cytoplasmic granules, i.e., granulocytes; phagocytic cells which are large mononuclear cells, i.e., macrophages and monocyte-derived giant cells; non-phagocytic cells defined as small mononuclear cells, i.e., lymphocytes, plasma cells and mast cells; elastic and collagen fibers; endothelial cells; fibroblasts. Blind assessment was conducted throughout the procedures and scoring was considered accordingly to absence (score 0), scarce presence (score 1), moderate presence (score 2), and profuse pres-

ence (score 3). Three evaluations were carried out and values were expressed as follows: mean ± Standard Deviation.

**Statistical Analysis**

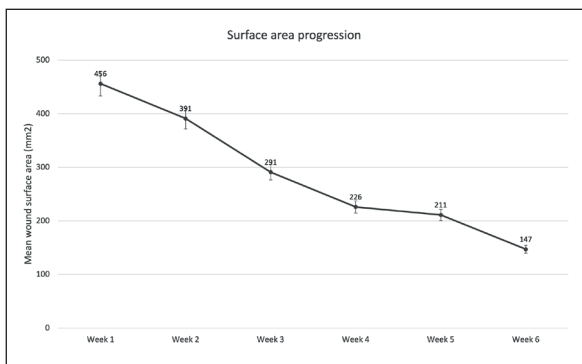
Values were indicated as the mean standard error. Least square linear regression was conducted for assessment using a computer-aided statistics program SPSS 16.0 software, (SPSS Inc., Chicago, IL, USA). A  $p > 0.05$  was intended as statistically significant. The statistical analysis software (SPSS) was used to conduct the two-tailed Student  $t$ -test along with the Kolmogorov-Smirnov test.

**Results**

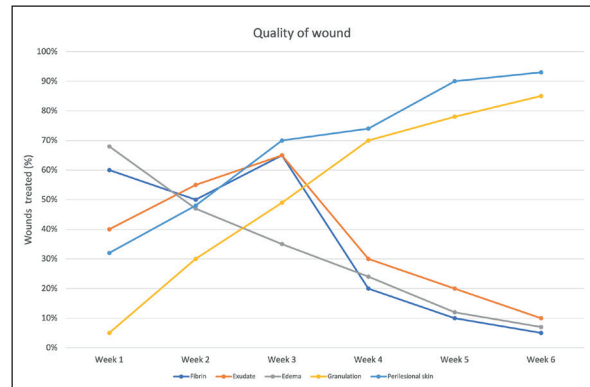
Eighty-five patients participated in our study. Type of wounds included superficial trauma wounds (20), surgical wounds (15), first- and second-degree burns (15), dermabrasions (30) and ulcers of different etiologies (5). Most patients presented upper and lower limb wounds and other sites comprising the chest, back, buttocks and neck.

**Re-Epithelization of Wound Healing**

At baseline, the mean wounds area measured 456 mm<sup>2</sup> with the smallest wound measuring 100 mm<sup>2</sup> in area and the largest having an area of 1200 mm<sup>2</sup>. A mean time of seven days was noted between wound occurrence and start of treatment with hyaluronic acid 0.2%. A decrease in the mean wound area was noted from 456 mm<sup>2</sup> to 226 mm<sup>2</sup> after four weeks accounting for an average reduction of 80% in the wound area (Figure 1). After six weeks, 95% of wounds healed and



**Figure 1.** Progression of wound healing during the first six weeks after application of hyaluronic acid cream or dressing, as measured by the mean wound surface area.



**Figure 2.** Evaluation of the quality of wounds healing during the first six weeks after application of hyaluronic acid cream or dressing.

treatment was suspended. Additional treatment for complete healing was required for only 5% of wounds.

**Quality of Wound Healing**

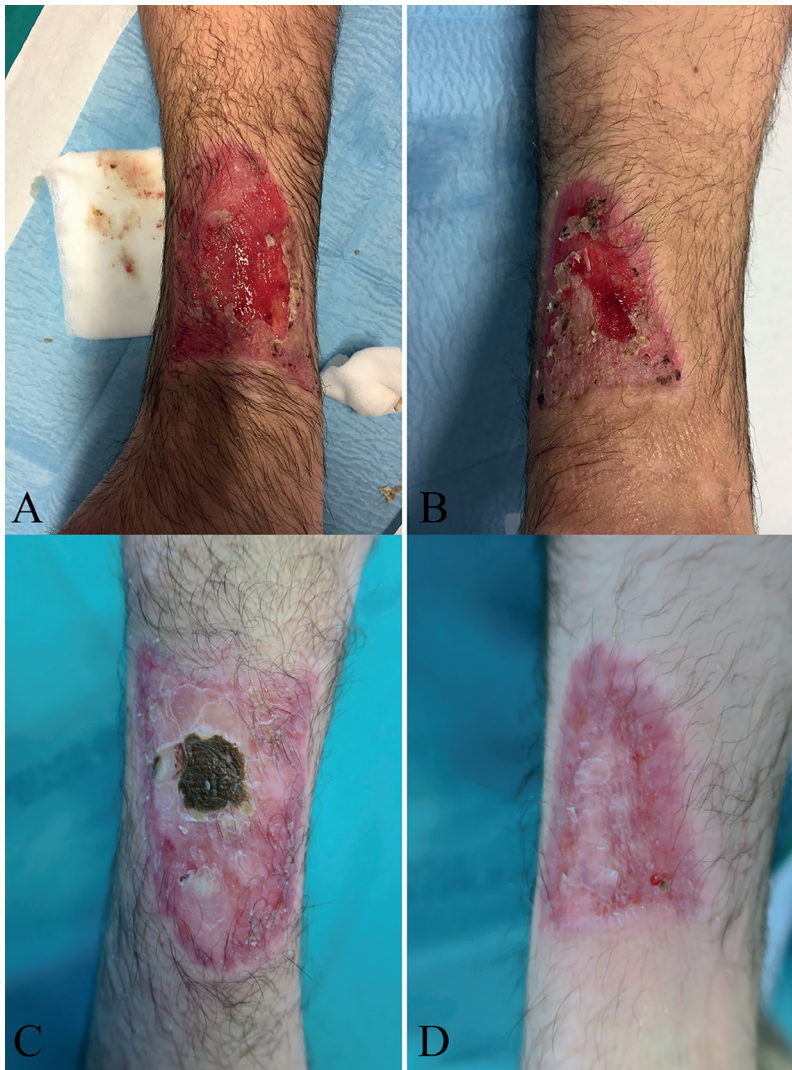
No fibrin was noted in 95% of wounds and little fibrin was present in 5% of wounds. 90% of wounds showed no exudate and little exudate was observed in 10% of wounds.

On peri-wound examination, normal skin appearance increased from a percentage of 32% to 70% at baseline after two weeks. Other wounds presented edematous skin and a macerated inflammatory response. However, after six weeks, peri-wound skin was normal in appearance regarding 93% of cases and the remaining wounds (7%) presented with scarce fibrin or scarce exudate. In particular, fibrin and exudate progressively decreased, after three weeks, until to 5% (fibrin) and 10% (exudate). Complete evaluation of wound quality following each assessment is presented in Figure 2.

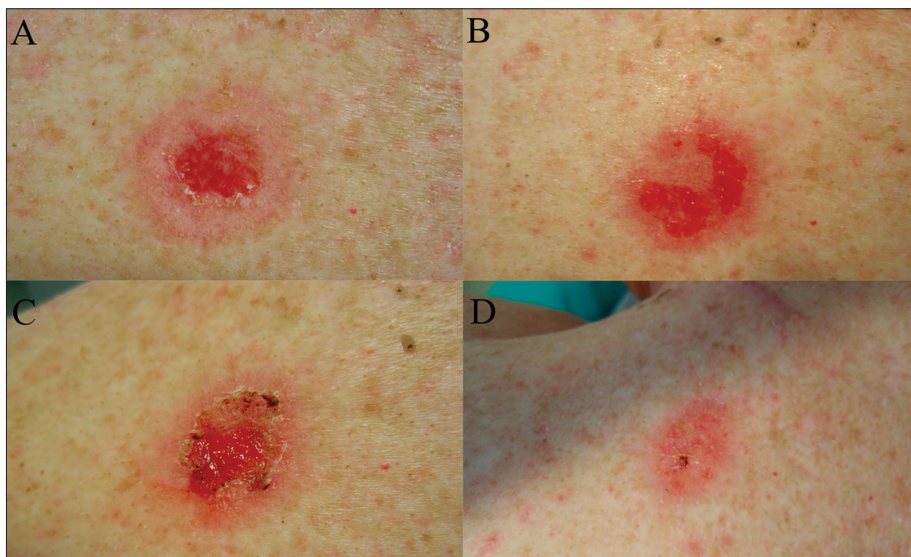
Figures 3, 4 and 5 show a moist, healing wound with no evidence of excess moisture at the end of second week of observation with a reduction of wound area after six week.

Considering complete healing within the study timeframe, 66% of wounds were described by the investigators as “very good” and 22% as “good” healing outcomes. Assessments of dressing change in terms of easy removal, bleeding, adherence and pain are exhibited in Figure 6. Patients treated with cream demonstrated greater tolerability than those treated with gauze in terms of dressing adherence and pain.

Patients satisfactorily tolerated the 0.2% HA dressing and cream formulation. Redness, prur-

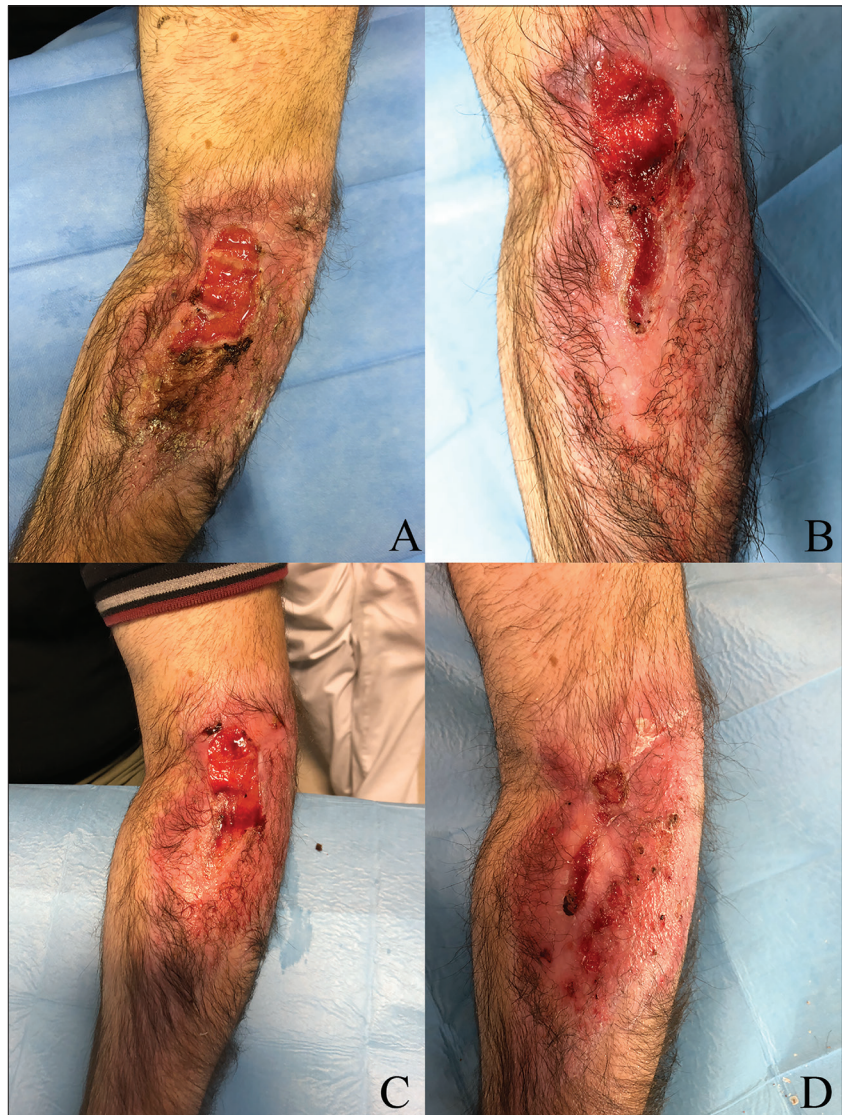

**Figure 3.** Post traumatic wound in 54-year-old patient. **A**, pre-treatment. **B**, after two weeks. **C**, after four weeks. **D**, wound healing after six weeks.



**Figure 4.** Post cryotherapy wound in 62-year-old patient. **A**, pre-treatment. **B**, after one week. **C**, after two weeks. **D**, wound healing after four weeks.

**Figure 5.** Post burn wound in 41-year-old patient. **A**, pre-treatment. **B**, after two weeks. **C**, after four weeks. **D**, wound healing after six weeks.

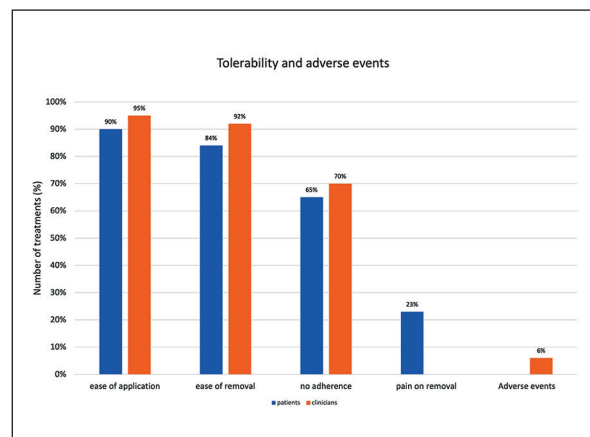


ritus and irritation in the perilesional area was observed in 6% of patients and no patient complained of wound pain.

The selection of treatment type between cream and dressing was made according to wound type as described in the Patients and Methods section. No significant differences in healing progression were noted for each treatment application in either patient group, who had a remarkable reduction in the mean wound area compared to baseline after the first six weeks. Furthermore, no significant differences were observed as regards tolerance or acceptance/satisfaction on behalf of the patients.

#### *Histological and histomorphometric evaluation*

Hematoxylin and eosin staining as well as histological and histomorphometric analysis of



**Figure 6.** Evaluation of the overall use of hyaluronic acid cream or dressing, as assessed by medical doctors and patients.

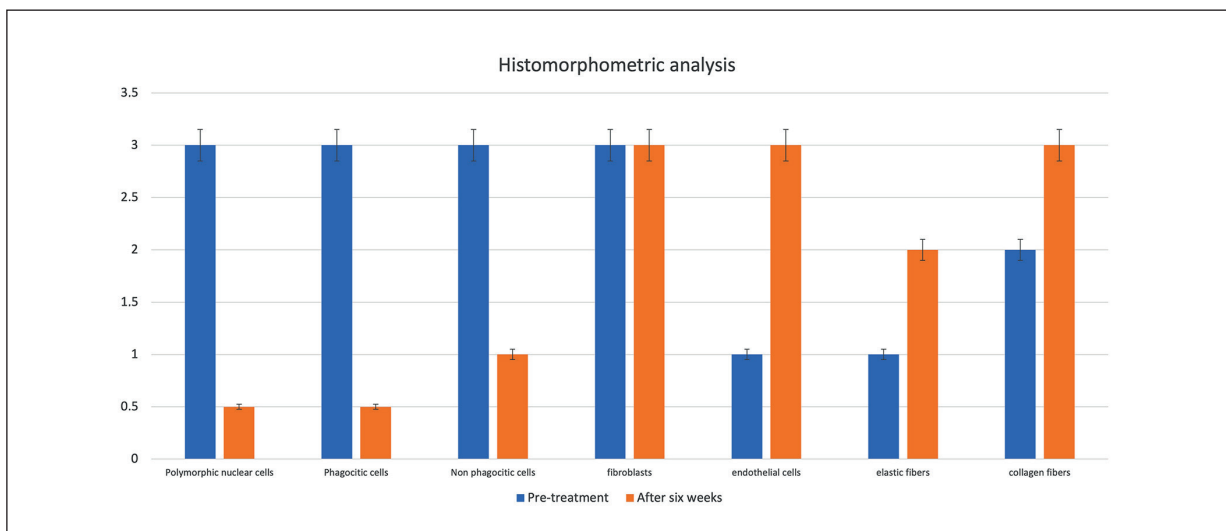
pre- and post-treatment lesions were conducted. Regarding epidermal thickness, the amount of keratinocyte layers tended to rise leading to a more consistent and resistant re-epithelialization. At baseline, the majority of cells in the wound were red blood cells and inflammatory cells: high infiltration of granulocytes, macrophages, polymorphic nuclear cells (PMNs) and non-polymorphic nuclear cells, few fibroblasts, few elastic fibers and few collagen fibers were present. In the post-treatment biopsy analysis, a visible dermal scar was noted containing few remaining inflammatory cells, numerous fibroblast cells, elastic and collagen fibers as well as few PMNs and non-phagocytic cells (Figure 7).

### Discussion

Wound closure and the functional and morphological recovery are key factors in wound treatment<sup>15</sup>. Therapeutic options for primary intention wound healing, including superficial trauma wounds, dermabrasions, and burns are based on pain reduction and retaining the moisture status of the wound. Few studies have assessed acute wounds *in vivo* and *in vitro*<sup>16,17</sup>. Herein, we demonstrate the effectiveness of 0.2% hyaluronic acid-based cream and gauze-pads, revealing its benefits in the healing process. The healing process initiates immediately after a skin injury, restoring the skin tissue architecture as

well as stopping bleeding. This procedure occurs through platelets releasing a substantial quantity of HA with a high molecular weight (HMW-HA) and promotes the deposition of fibrinogen and the formation of an initial clot. In addition, HA is a key element of edema fluid and indirectly stimulates the recruitment of neutrophils cells, which is an integral part of debris phagocytosis and of necrotic tissue and the consequent release of tumor necrosis factor-alpha (TNF- $\alpha$ ), IL-1b and IL-8. Furthermore, the secretion of inflammatory cytokines will favor the fragmentation of HMW-HA into low molecular weight LMW-HA, contributing towards leucocyte and monocyte recruitment. Besides, LMW-HA and fibronectin support the invasion and proliferation of fibroblasts, an essential process in the deposition of collagen for the wound. Noteworthy is the molecular weight of HA in wound regeneration and prompt re-epithelialization. HA produces different effects depending on its molecular weight being also demonstrated by several clinical studies<sup>18</sup>. In fact, it has been shown that low/medium molecular weight HA promotes wound repair from the earliest stages, while HMW-HA has no short-term effects, probably due to its higher initial viscosity<sup>18</sup>.

After six weeks, an average reduction of 80% in the wound surface area was observed, together with an increase of fibronectin and collagen, which is most likely related to rapid re-epithelialization. Some recent studies on animal models



**Figure 7.** Signs of inflammatory condition during the first six weeks after application of hyaluronic acid cream of dressing. After treatment: few infiltrations of granulocytes, macrophages, polymorphic nuclear cells (PMNs) and non-polymorphic nuclear cells, high fibroblasts and endothelial cells, few elastic fiber, and high collagen fibers were present.

has revealed similar outcomes concerning re-epithelialization<sup>5,19,20</sup>. Moreover, a meta-analysis by Voigt and Driver<sup>21</sup> demonstrated the mostly positive effect of HA in healing of wounds of various etiologies. In particular, some cited trials showed that topical HA improves healing rates in terms of complete healing or a reduction of wound size.

Our study has demonstrated that wounds treated with topical HA favor the natural re-epithelialization process, by maintaining a moist wound environment that facilitates the wound healing process by preventing tissue dehydration and cell death, accelerating angiogenesis, increasing the breakdown of fibrin and necrotic tissue.

The histomorphometry analysis highlighted a relevant concentration of PMNs and non-phagocytic cells in early granulation tissue. Conversely, with the progression of ulcer healing, HA has a role as moderator of inflammation. Our results showed that the use of exogenous HA had a positive effect on re-epithelialization. These results supported the hypothesis that HA stimulated migration and proliferation of keratinocytes<sup>22-24</sup>.

The clinical trial demonstrated that applications of HA cream or gauze-pads aided in wound healing as shown by a reduced wound surface area of 80% at six weeks and a reduced surface area of 95% after eight weeks. As for the healing quality, we observed 95% of wounds lacking in fibrin and 90% devoid of exudate. Such favorable outcomes regarding quality of healing may be due to HA indirect activity during the re-epithelialization process in which keratinocytes are readily proliferated and dermal collagen is remodeled thus interfering with the inflammatory response. To date, various HA-based wound dressings are applied in a clinical context owing to the specific hygroscopic, rheologic and viscoelastic properties<sup>25-27</sup>. HA provides a temporary structure in the early stages of the wound to facilitate the diffusion of nutritional supplies and allows the control of hydration during wound repair and inflammatory process<sup>28,29</sup>.

Our findings may be limited by the absence of a control standard wound application and by the retrospective nature of the investigations. Additionally, the efficacy of HA may be questioned due to the different wound types chosen for the indicated study. However, considering the wounds described herein, HA cream and gauze-pads treatment provide a humid environment, thus protecting it from abrasion, friction and drying promoting the healing of acute wounds of

various etiologies. In conclusion, exogenous topical HA treatment enhances healing by stimulating of matrix deposition and reducing inflammation, by maintaining a moist wound environment. The beneficial effects of a moist environment include prevention of tissue dehydration and cell death, acceleration of angiogenesis, increased breakdown of dead tissue and fibrin, potentiating cell-cell interaction, and, in addition, significant pain reduction.

## Conclusions

HA is usually applied in an ample variety of therapeutic applications<sup>30</sup>, as well as osteoarthritis, ophthalmic surgery, cosmetic application and tissue engineering. It may be administered by intradermal injections or topically. HA ointments are safe and effective above all for skin repair, thanks to its moist environment which favors the management of exudate and facilitates the exchange of O<sub>2</sub> and nutrients, as well as enhancing local cell migration and proliferation. It also reduces inflammation by reducing inflammatory cells thereby improving wound re-epithelialization and granulation, which are of utmost importance to improve skin repair.

In conclusion, wounds treated with topical HA favor the natural re-epithelialization process, by maintaining a moist wound environment that facilitates the wound healing process by preventing tissue dehydration and cell death, accelerating angiogenesis, increasing the breakdown of fibrin and necrotic tissue.

---

### Conflict of Interest

The Authors declare that they have no conflict of interests.

---

### Acknowledgements

The authors are grateful to Giuseppina Caraglia, mother-tongue expert, University of Naples "Vanvitelli" for her technical expertise.

---

### Ethics Approval

The present retrospective study was approved by Marche Region Ethics Committee (CERM – Italy) (765/2021).

---

### Informed Consent

All participants provided relevant informed consent for retrospective enrollment of the study.

### Consent for Publication

Written informed consent for publication of clinical details and clinical images were obtained from the patients. A copy of the consent forms is available for review by the Editor of this journal.

### Availability of Data and Materials

All data generated or analyzed during this study are included in this published article [and its supplementary information files].

### Funding

Not applicable.

### Authors' Contributions

FDF has designed the study and written the paper, FDF, MR has provided the data and supervised the study; FDF, AS reviewed the work and produced the final draft.

### ORCID ID

Francesco De Francesco: <https://orcid.org/0000-0003-2977-7828>; Arman Saparov: <https://orcid.org/0000-0002-4407-1236>; Michele Riccio: <https://orcid.org/0000-0001-5554-4759>.

## References

- 1) Fallacara A, Baldini E, Manfredini S, Vertuani S. Hyaluronic acid in the third millennium. *Polymers (Basel)* 2018; 10: 701.
- 2) Meyer K, Palmer JW. The polysaccharide of the vitreous humor. *J Biol Chem* 1934; 107: 629-634.
- 3) Lierova A, Kasparova J, Filipova A, Cizkova J, Korecka L, Mannova N, Bilkova Z, Sinkorova Z. Hyaluronic acid: known for almost a century, but still in vogue. *Pharmaceutics* 2022; 14: 838.
- 4) Dicker KT, Gurski LA, Pradhan-Bhatt S, Witt RL, Farach-Carson MC, Jia X. Hyaluronan: a simple polysaccharide with diverse biological functions. *Acta Biomater* 2014; 10: 1558-1570.
- 5) Gupta RC, Lall R, Srivastava A, Sinha A. Hyaluronic acid: molecular mechanisms and therapeutic trajectory. *Front Vet Sci* 2019; 6: 192.
- 6) Papakonstantinou E, Roth M, Karakiulakis G. Hyaluronic acid: a key molecule in skin aging. *Dermatoendocrinol* 2012; 4: 253-258.
- 7) Marinho A, Nunes C, Reis S. Hyaluronic acid: a key ingredient in the therapy of inflammation. *Biomolecules* 2021; 11: 1518.
- 8) Laurent TC, Laurent UB, Fraser JR. The structure and function of hyaluronan: an overview. *Immunol Cell Biol* 1996; 74: A1-7.
- 9) Ferroni L, Gardin C, D'Amora U, Calzà L, Ronca A, Tremoli E, Ambrosio L, Zavan B. Exosomes of mesenchymal stem cells delivered from methacrylated hyaluronic acid patch improve the regenerative properties of endothelial and dermal cells. *Biomater Adv* 2022; 139: 213000.
- 10) Abatangelo G, Vindigni V, Avruscio G, Pandis L, Brun P. Hyaluronic acid: redefining its role. *Cells* 2020; 9: 1743.
- 11) Hussain Z, Thu EH, Katas H, Bukhari SNA. Hyaluronic acid-based biomaterials: a versatile and smart approach to tissue regeneration and treating traumatic, surgical, and chronic wounds. *Polymer Reviews* 2017; 57: 594-630.
- 12) Demidova-Rice TN, Hamblin MR, Herman IM. Acute and Impaired wound healing: pathophysiology and current methods for drug delivery, Part 1: normal and chronic wounds: biology, causes, and approaches to care. *Adv Skin Wound Care* 2012; 25: 304-314.
- 13) Tejiram S, Kavalukas SL, Shupp JW, Barbul A. Wound healing. *Wound healing biomaterials* 2016; 1: 3-39.
- 14) Thiruvoth FM, Mohapatra DP, Kumar D, Chittooria SRK, Nandhagopal V. Current concepts in the physiology of adult wound healing. *Plast Aesthet Res* 2015; 2: 250.
- 15) Eming SA, Martin P, Tomic-Canic M. Wound repair and regeneration: Mechanisms, signaling, and translation. *Sci Transl Med* 2014; 6: 265sr6.
- 16) Ubbink DT, Brolmann FE, Go PMNYH, Vermeulen H. Evidence-based care of acute wounds: a perspective. *Adv Wound Care (New Rochelle)* 2015; 4: 286-294.
- 17) Lee CK, Hansen SL. Management of Acute Wounds. *Surg Clin North Am* 2009; 89: 659-676
- 18) D'Agostino A, Stellavato A, Busico T, Papa A, Tirino V, Papaccio G, La Gatta A, De Rosa M, Schiraldi C. In vitro analysis of the effects on wound healing of high- and low-molecular weight chains of hyaluronan and their hybrid H-HA/L-HA complexes. *BMC Cell Biology* 2015; 16: 19.
- 19) Leite MN, Cipriani Frade MA. Efficacy of 0.2% hyaluronic acid in the healing of skin abrasions in rats. *Heliyon* 2021; 7: e07572.
- 20) Turley EA, Torrance J. Localization of hyaluronate and hyaluronate-binding protein on motile and non-motile fibroblasts. *Exp Cell Res* 1985; 161: 17-28.
- 21) Voigt J, Driver VR. Hyaluronic acid derivatives and their healing effect on burns, epithelial surgical wounds, and chronic wounds: A systematic review and meta-analysis of randomized controlled trials. *Wound Rep Regen* 2012; 20: 317-331.
- 22) Marinho A, Nunes C, Reis S. Hyaluronic acid: a key ingredient in the therapy of inflammation. *Biomolecules* 2021; 11: 1518.
- 23) Kawano Y, Patrulea V, Sublet E, Borchard G, Iyoda T, Kageyama R, Morita A, Seino S, Yoshida H,



- Jordan O, Hanawa T. Wound healing promotion by hyaluronic acid: effect of molecular weight on gene expression and in vivo wound closure. *Pharmaceuticals (Basel)* 2021; 14: 301.
- 24) Gao Y, Sun Y, Yang H, Qiu P, Cong Z, Zou Y, Song L, Guo J, Anastassiades TP. A low molecular weight hyaluronic acid derivative accelerates excisional wound healing by modulating pro-inflammation, promoting epithelialization and neo-vascularization, and remodeling collagen. *Int J Mol Sci* 2019; 20: 3722.
- 25) Graca MFP, Miguel SP, Cabral CSD, Correia IJ. Hyaluronic acid-based wound dressings: a review. *Carbohydrate polymers* 2020; 241: 116364.
- 26) Cortes H, Caballero-Floran IH, Mendoza-Munoz N, Cordova-Villanueva EN, Escutia-Guadarrama L, Figueroa-Gonzalez G, Reyes-Hernandez OD, Gonzalez-Del Carmen M, Varela-Cardoso M, Magana JJ, Floran B, Del Prado-Audelo ML, Leyva-Gomez G. Hyaluronic acid in wound dressings. *Cell Mol Biol (Noisy-le-grand)* 2020; 66: 191-198.
- 27) Yang H, Song L, Zou Y, Sun D, Wang L, Yu Z, Guo J. Role of hyaluronic acids and potential as regenerative biomaterials in wound healing. *ACS Appl Bio Mater* 2021; 4: 311-324.
- 28) Chen WVJ, Abatangelo G. Function of hyaluronan in wound repair. *Wound Rep Regen* 1999; 7: 79-89.
- 29) Bourguignon LYW, Ramez M, Gilad E, Singleton PA, Man MQ, Crumrine DA, Elias PM, Feingold KR. Hyaluronan-CD44 interaction stimulates keratinocyte differentiation, lamellar body formation/secretion, and permeability barrier homeostasis. *J Invest Dermatol* 2006; 126: 1356-1365.
- 30) Ibraheem W, Jedaiba WH, Alnami AM, Hussain Baiti LA, Ali Manqari SM, Bhati A, Almarghani A, Assaggaf M. Efficacy of hyaluronic acid gel and spray in healing of extraction wound: a randomized controlled study. *Eur Rev Med Pharmacol Sci* 2022; 26: 3444-3449.